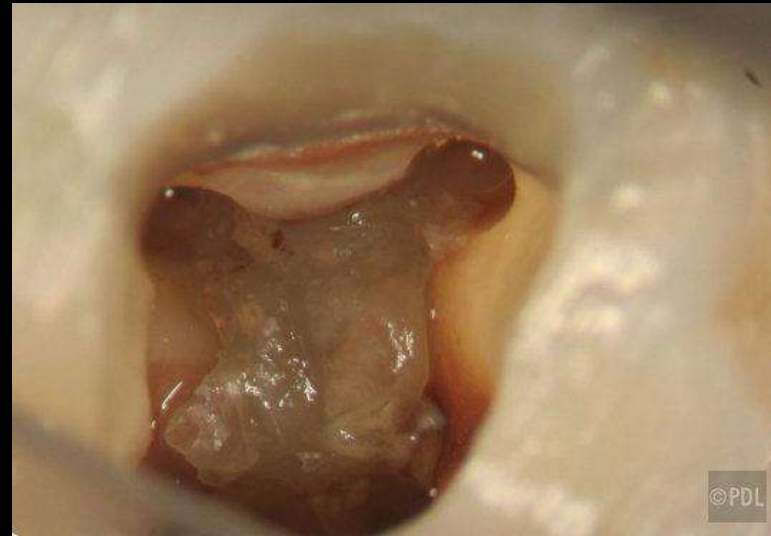
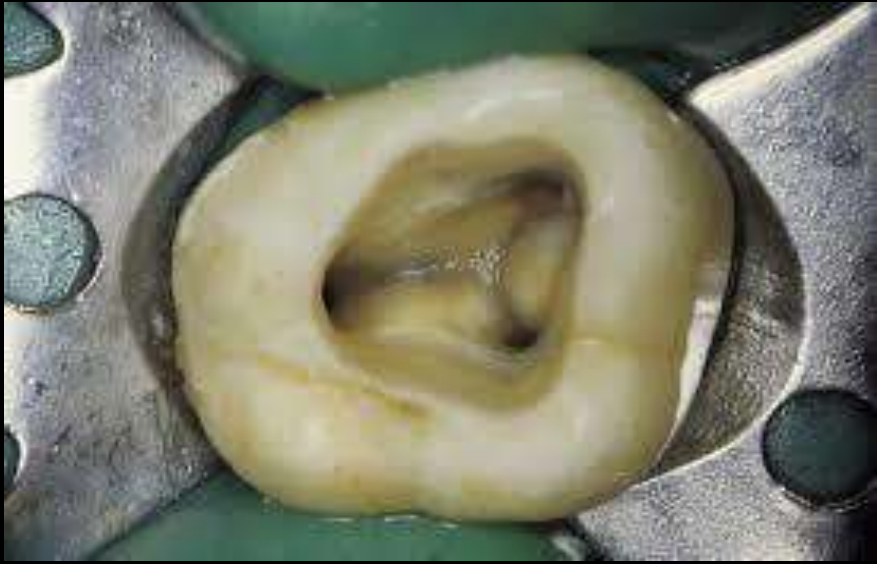


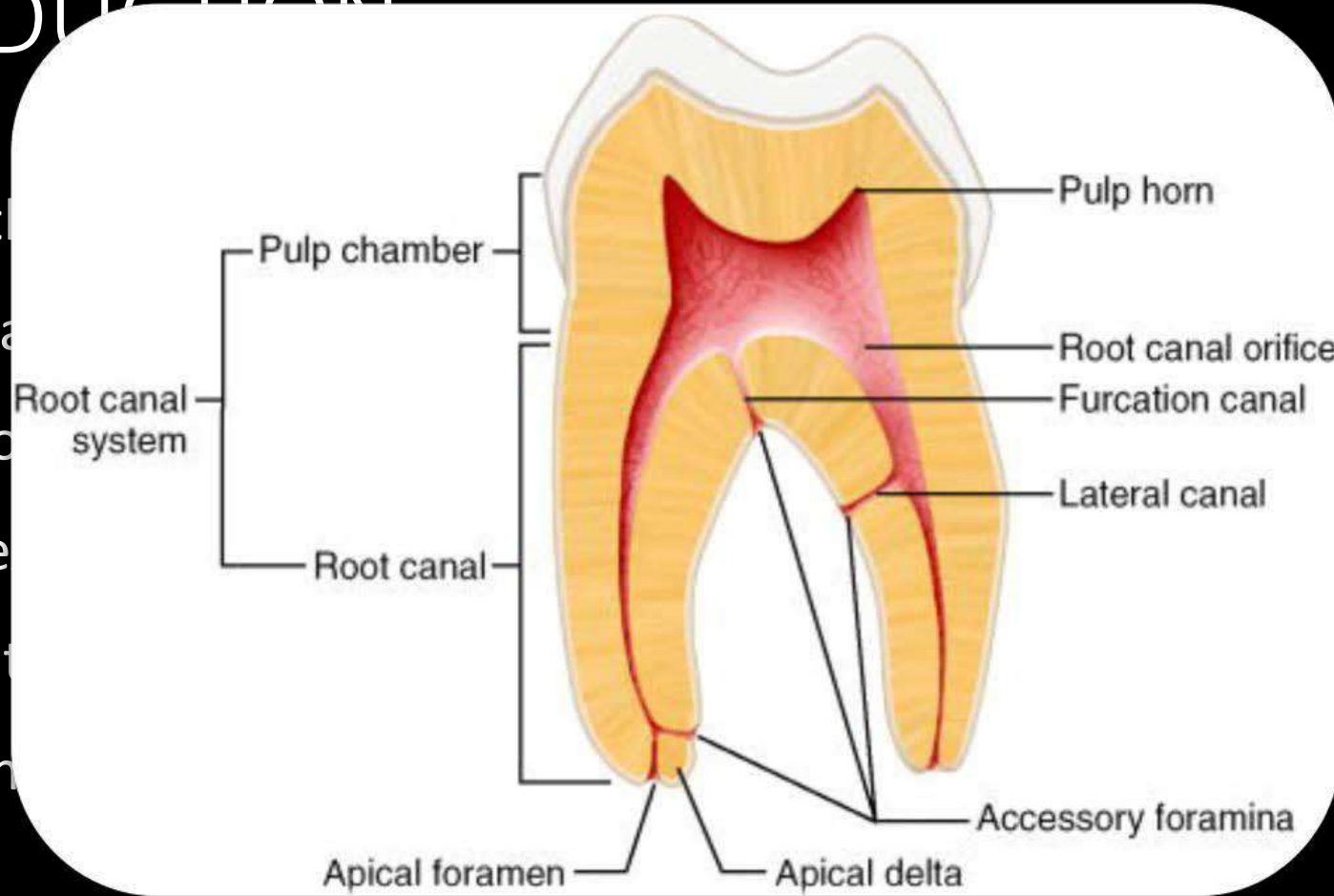
INTERNAL ANATOMY OF TEETH

CONTENTS

- Introduction
- Pulp chamber anatomy
- Apical foramen
- Accessory foramen
- Apical constriction
- Isthmus
- C-shape canal
- Root canal and classification of root canal systems
- Anatomy of individual tooth
- Developmental Disturbances
- Conclusion
- References

INTRODUCTION

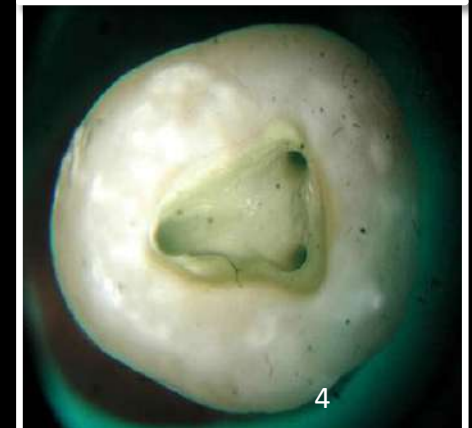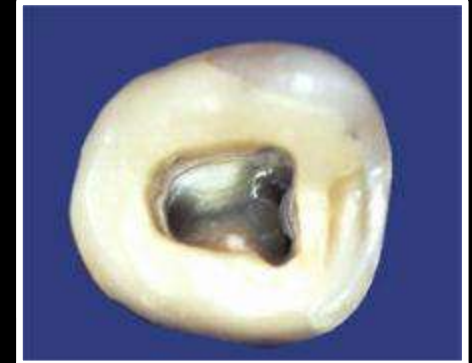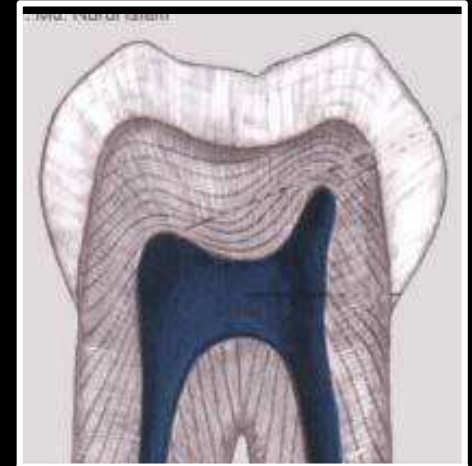
- Anatomy is the study of the structure of the body and its parts.
- Of all the phases of dental development, the root development are significant.



ost
oot
eth

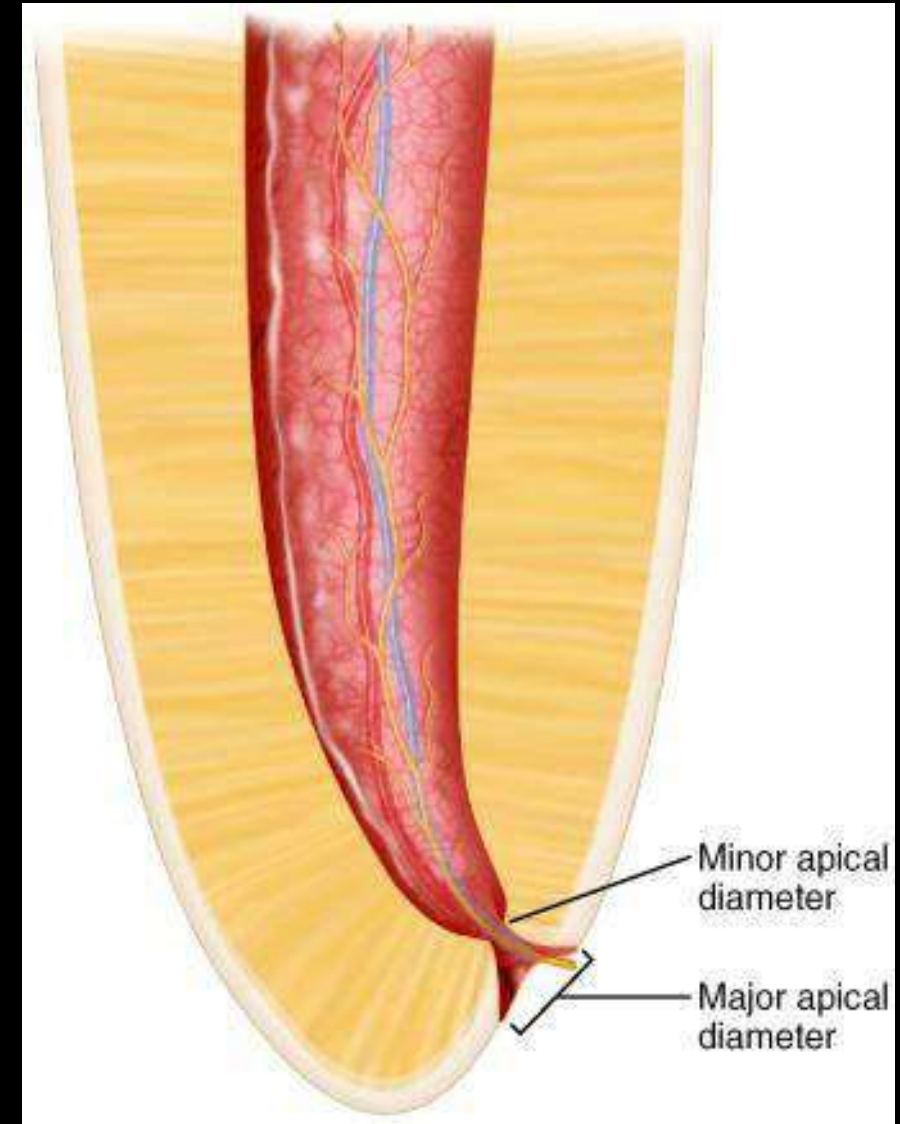
PULP CHAMBER

- **Roof of pulp chamber**
 - Dentin covering the pulp chamber occlusally or incisally.
- **Pulp horn**
 - Accentuation of the roof of the pulp chamber directly under a cusp or developmental lobe.
- **Floor of pulp chamber**
 - Runs parallel to the roof and consists of dentin bounding the pulp chamber near the cervical area of the tooth.
- **Canal orifices**
 - Openings in the floor of pulp chamber leading in to root canals



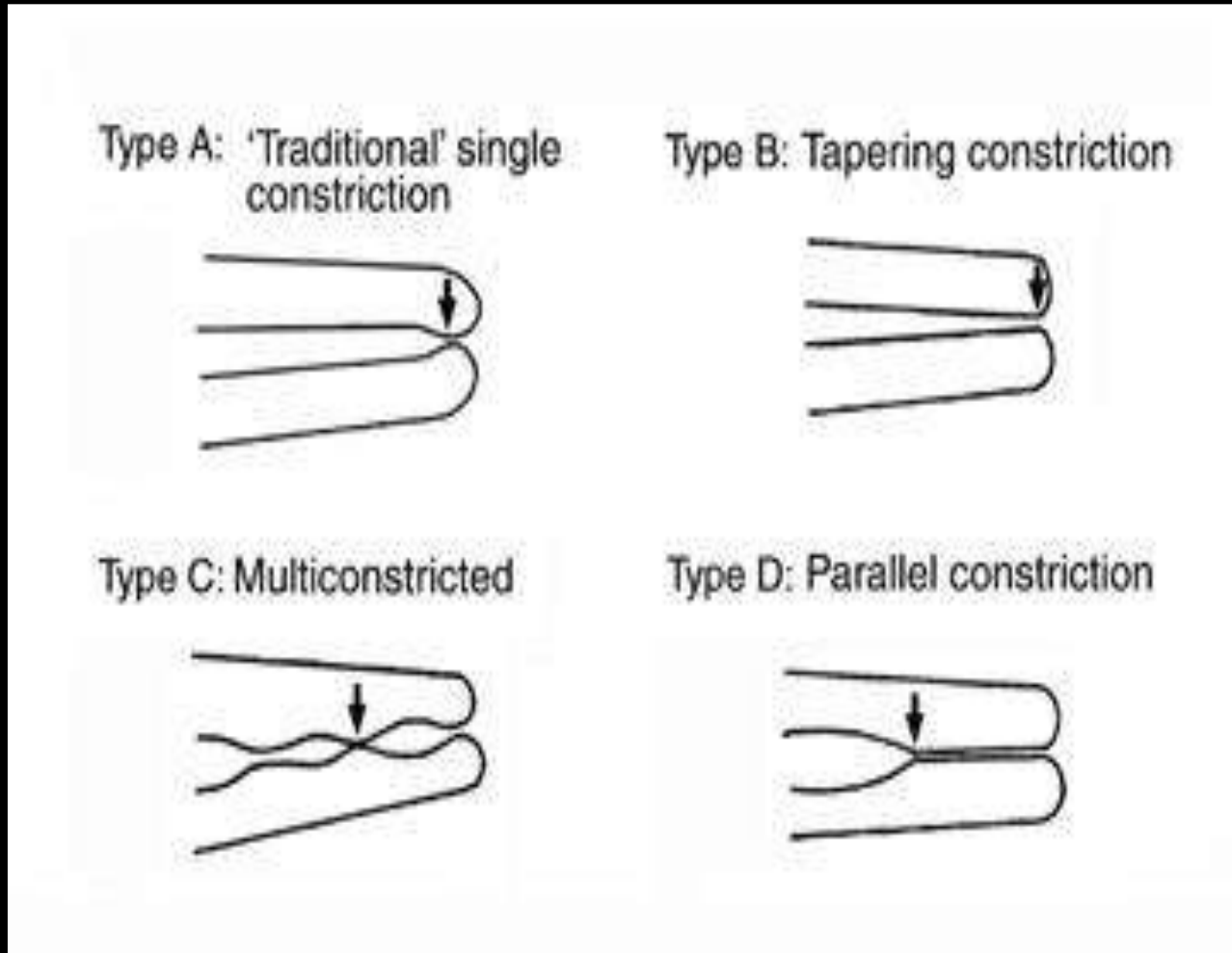
Apical Constriction (Minor Apical Diameter)

- Part of root canal with the smallest diameter
- Reference point for apical termination
- “**Physiologic foramen**”
- Distance ranges from **0.5mm -1.5mm** inside the apical foramen



- Narrowest diameter of the canal is definitely not at the site of exiting of the canal from the tooth but usually occurs within the dentin, just prior to the initial layers of cementum
- **Kuttler et al** referred to this position as the minor diameter of the canal
- The diameter of the canal at the site of exiting from the tooth (major diameter) was found to be approximately twice as wide as minor diameter.

Classification by Dummer et al 1984

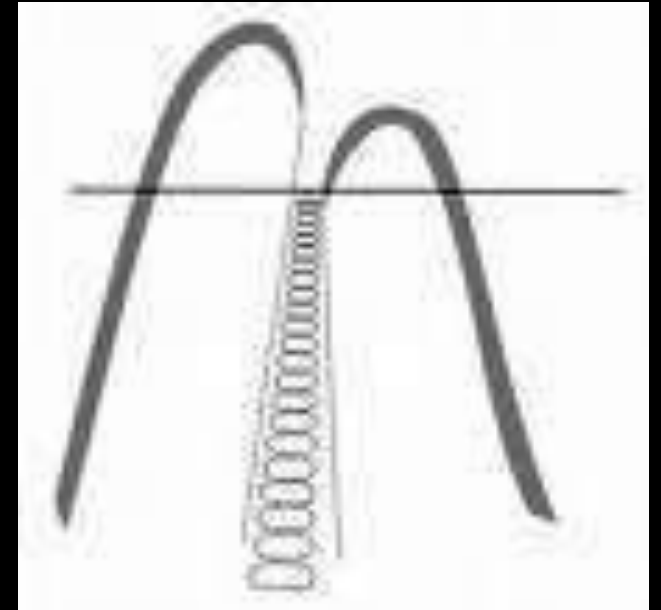


- Clinically and radiographically, locating the apical constriction and foramen was nearly impossible!!
- In response, many anatomic studies dedicated their work to determine the location of constriction and foramen in relation to the apex.
- Mean distance from apical constriction to apex (AC-A) was 1 mm (0–2 mm, range of 2 standard deviations [SDs])
- From apical foramen to apex (AF-A) was 0.5 mm (0–1.5 mm, range of 2 SDs).

- Sjögren et al.(1990) stated that instrumentation to the AC resulted in 90% healing in infected teeth.
- Kuttler et al.(1955) stated that all root canal procedures should terminate 0.5 mm short of the AF, as this point is considered to be the nearest to the AC.
- To remain close to the AC, a range of 0.5-1.5 mm short of the radiographic apex was recommended as an appropriate working length depending on the specific root being treated

Clinical Significance

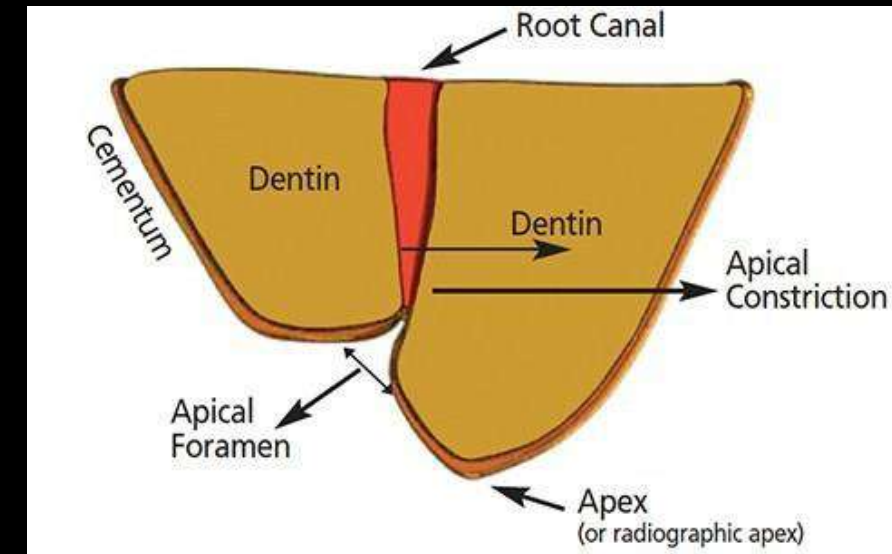
- Canal preparation & obturation should **terminate** at minor diameter
- Provide a bottle neck area during obturation – rapid development of Apical dentin matrix
- **Retaining** filling material & sealers within the canal
- **Pain free treatment** can be done without damaging periapical tissue



Apical foramen



- Apical foramen (AF) Circumference or rounded edge, like a funnel or crater, that differentiates the termination of the cemental canal from the exterior surface of the root.(Cohen)
- Canal widens From AC or Minor Diameter;
- Shape between AC & AF has been described as
 - Funnel shaped
 - Hyperbolic (Morning glory)
- Average **0.4 – 0.7 mm** away from the anatomic apex



EXIT OF APICAL FORAMEN

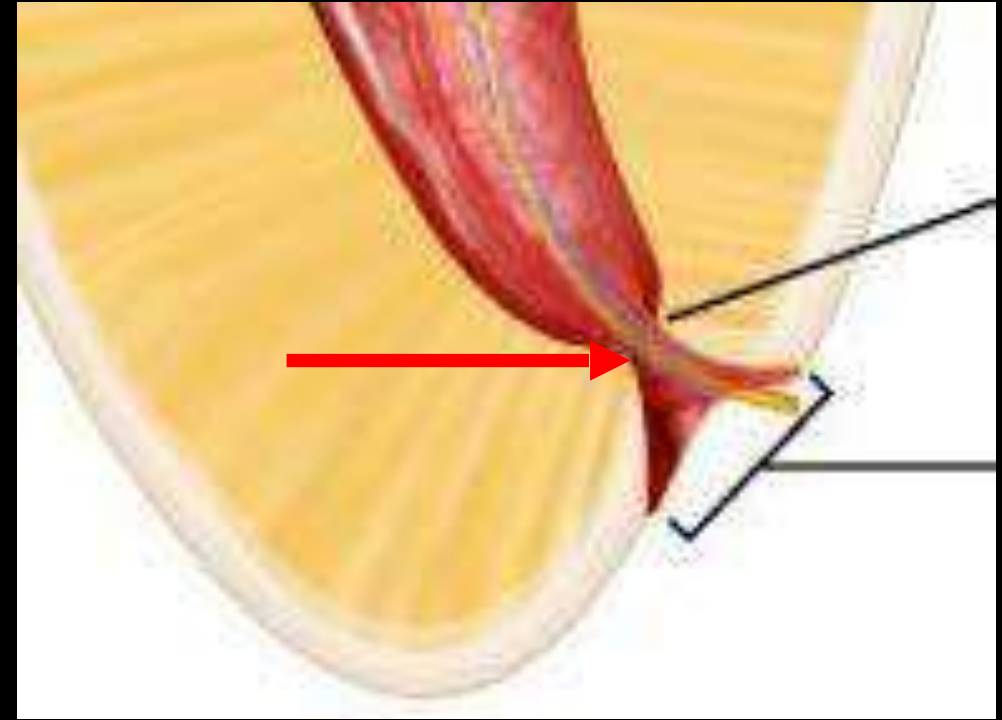
- Doesn't normally exit at the anatomic apex but is offset 0.3 – 0.5 mm
- Both root apex & AF of central incisors & canine showed disto-labial displacement
- Lateral incisor – distolingual displacement (Mizutani et al)

SIGNIFICANCE

- Inadequate knowledge and mismanagement of apical foramen may affect long and short term success of RCT

Cementodentinal Junction

- Point in the canal where cementum meets dentin
- Not the same as the apical constriction
- SMULSON et al observed that CDJ is appx 1mm from the apical foramen

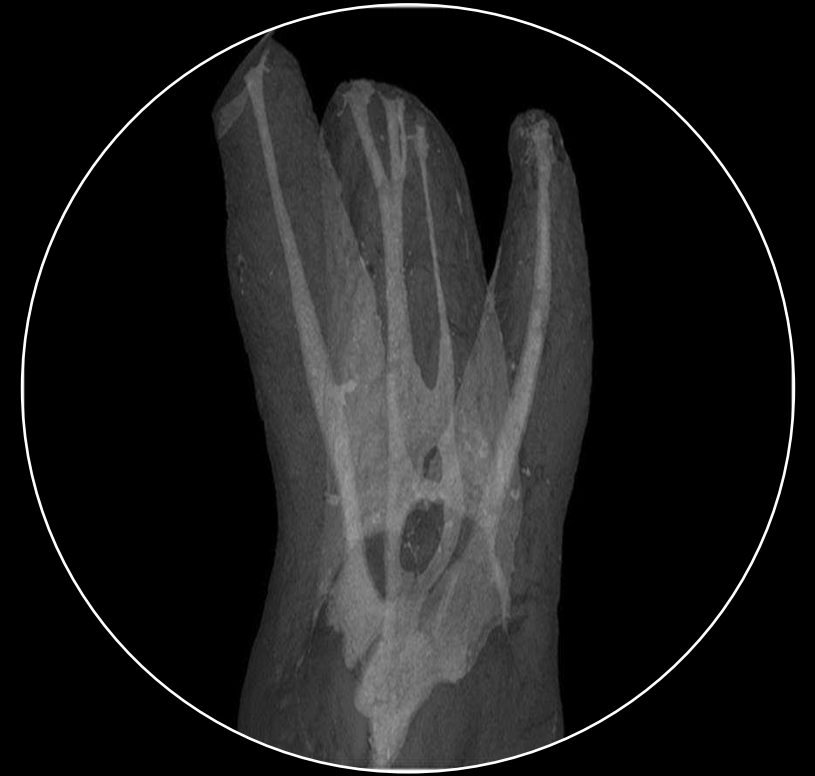

Significance

- Theoretically, the CDJ is the appropriate apical limit for root canal treatment
- Clinically impossible to identify
- As at this point the area of contact between the periradicular tissues and root canal filling material is likely to be minimal
- Therefore, it cannot be an ideal landmark to use clinically as the end-point for root canal preparation and filling.

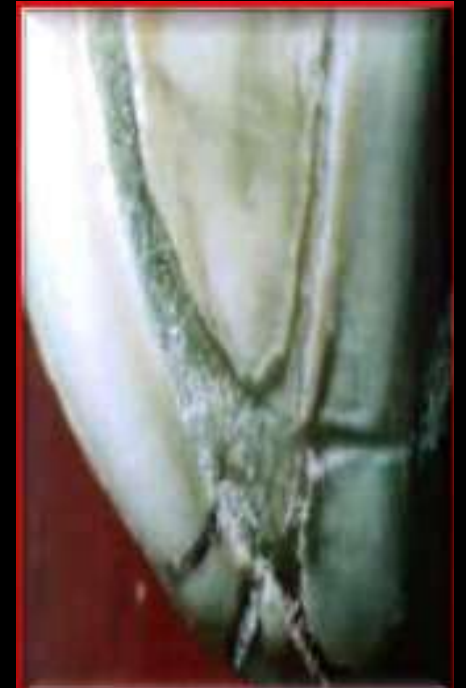- **Apical Delta :**

- Describes the primary or secondary canal that terminates short of the apex with lateral canals fanning out from this point to the end of root surface.
- Apical deltas are multiple accessory canals that branch out from the main canal at or near the root apex



Clinical significance

- No. of accessory canals – not a significant factor in success of endodontic therapy
- Following endodontic therapy in teeth with vital pulps they become obliterated by the deposition of cementum
- In non-vital teeth, inflammatory tissue will get resorbed and replaced with un-inflamed connective tissue



- De-Deus et al. ([1975](#))

Lateral canal - Main canal to the periodontal ligament (mainly in the body of the root)

Secondary canal - Main canal to the periodontal ligament in the apical region

Accessory canal - Derived from the secondary canal branching off to the periodontal ligament in the apical region.

Accessory Canals:

- Minute canals that extend in a horizontal, vertical, or lateral direction from the pulp to the periodontium.
 - 73.5% - apical third
 - 11.4% - middle third
 - 15.1% - cervical third.

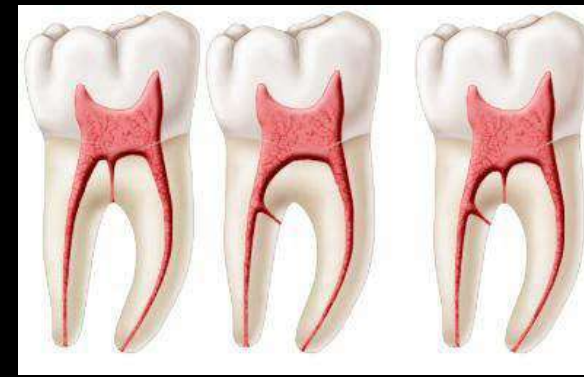- Cohen

- Contain connective tissue and vessels but do not supply the pulp with collateral circulation.
- Formed by the entrapment of periodontal vessels in Hertwig's epithelial root sheath during calcification.

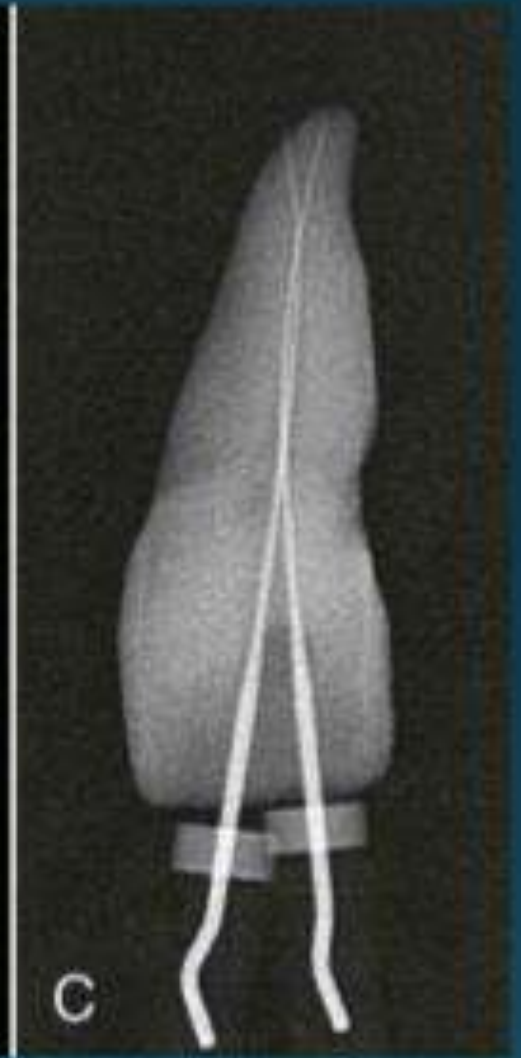
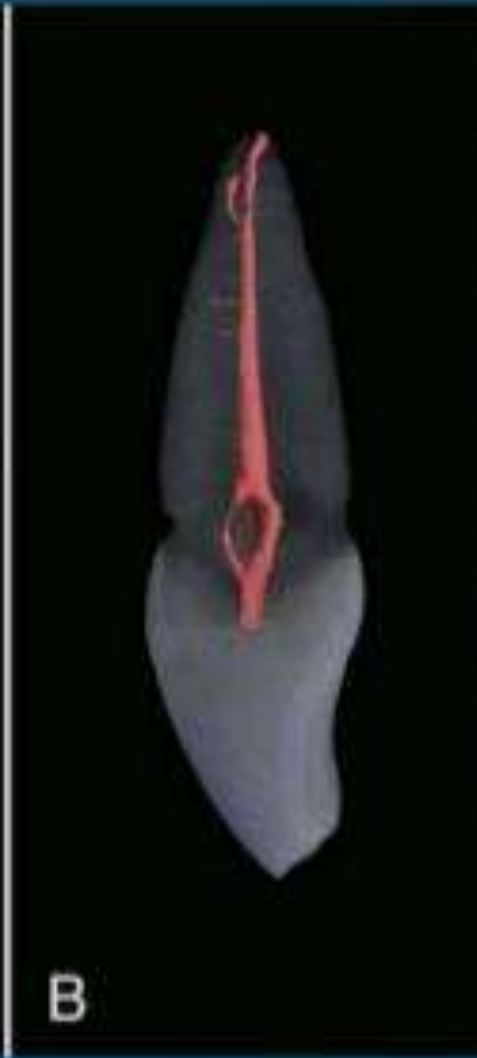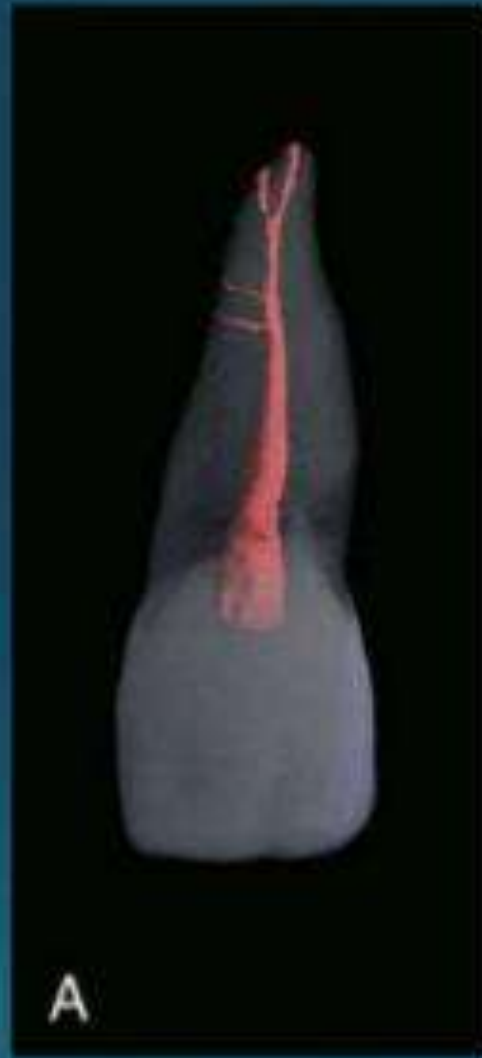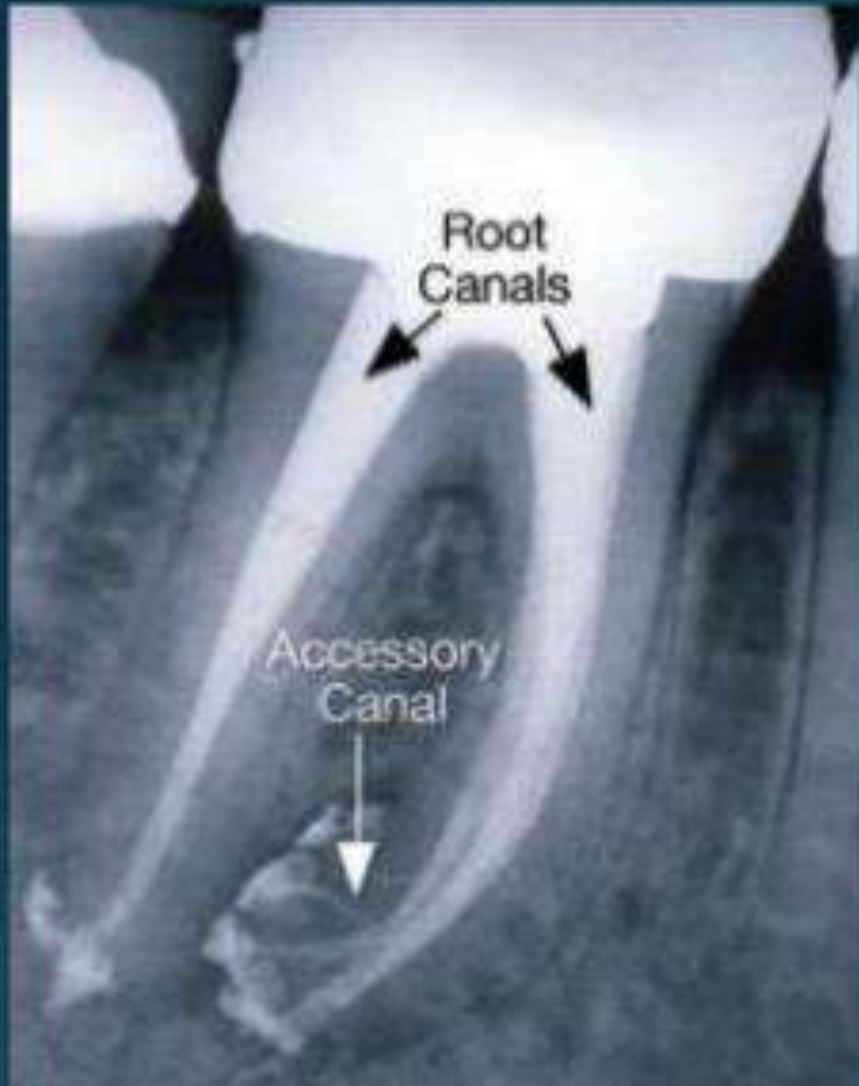
- Grossman



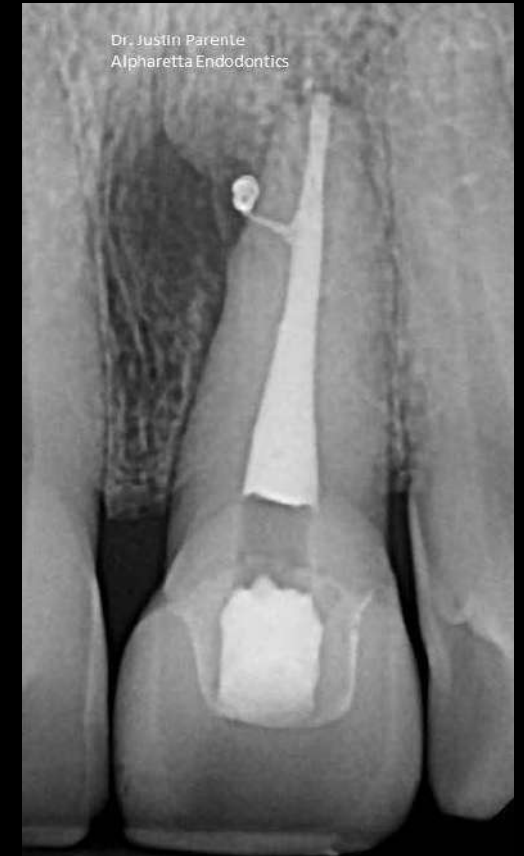
* Lateral canals are more common in bifurcation and trifurcation region of molars -cohen



- A. In **13%** a single **furcation canal** extends from the pulp chamber to the intraradicular region.
- B. In **23%** **lateral canals** extends from the **coronal third** (**80%** extend from the **distal root** canal).
- C. About **10%** have both **lateral and furcation canals**

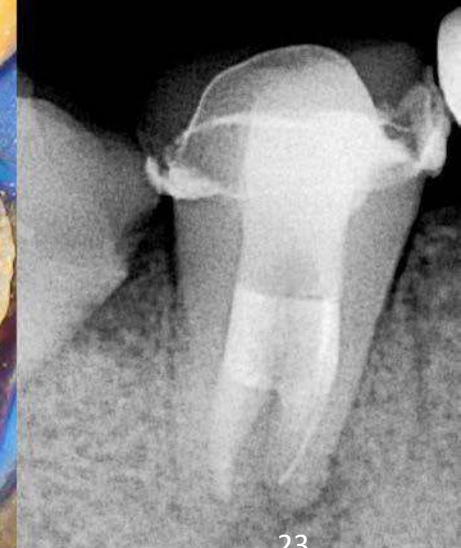
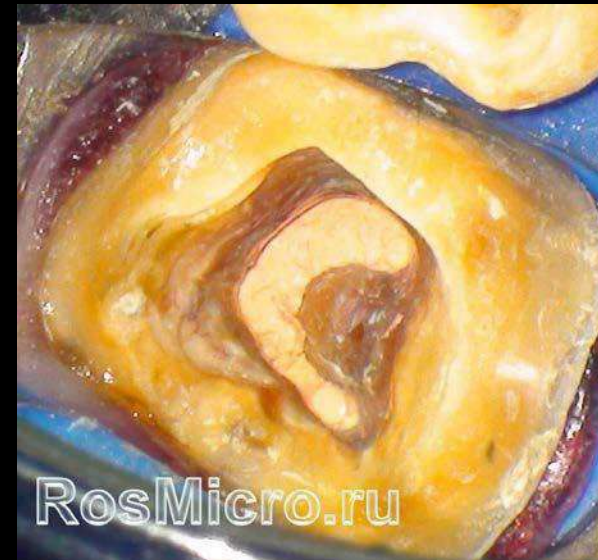
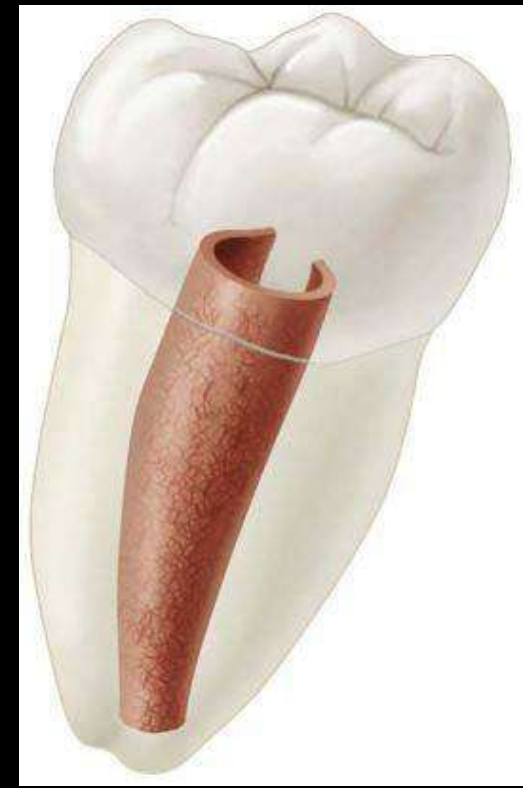- Green et al (1955) referred to ‘**accessory apical foramina**’ for those within 3.5 mm of the apex (more than three accessory foramina were considered as ‘multiple foramina’).
- Foramina located beyond this limit were referred to as ‘**lateral canal foramina**’



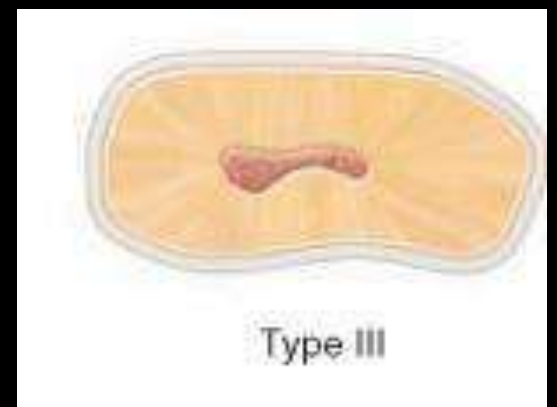
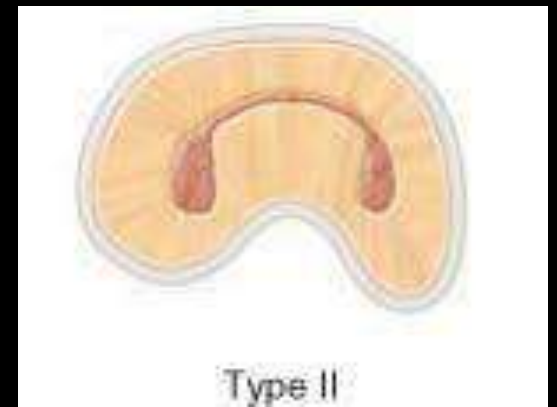
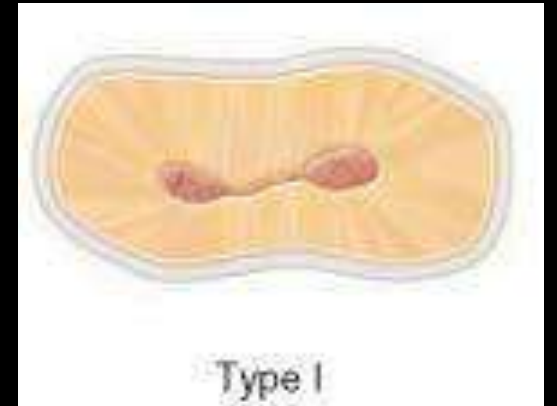
Canal Isthmus

- Narrow, ribbon-shaped communication between two root canals that contains pulp or pulpally derived tissue.
- It was found that the percentage of occurrence of isthmus increases continuously for every 1mm from the apex for the first 4mm.



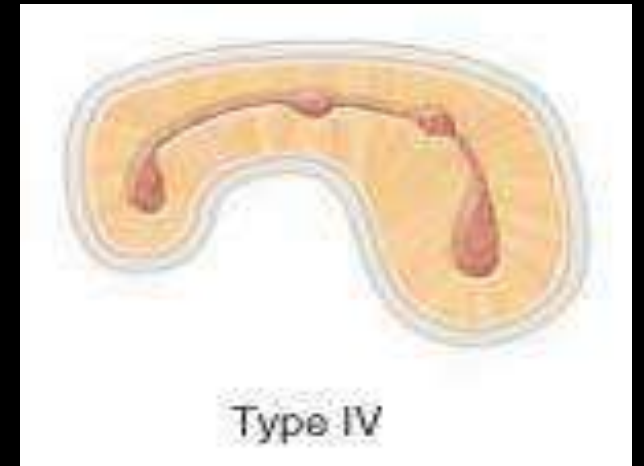
Types

- **Type I**
Incomplete isthmus; faint communication between two canals.
- **Type II**
Characterized by two canals with definite connection between them.
- **Type III**
Very short complete isthmus between two canals.



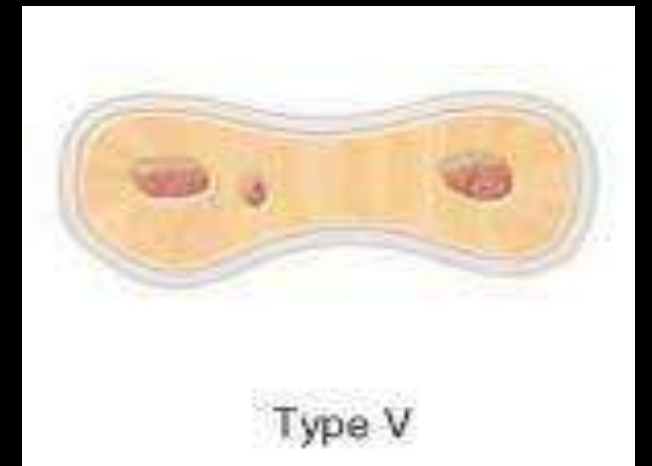
- **Type IV**

Complete or incomplete isthmus between two or more canals.



- **Type V**

Marked by two or three canal openings without visible connections




According to Melton et al (1991)


Category 1 : Continuous C-shaped canal from pulp chamber to apex



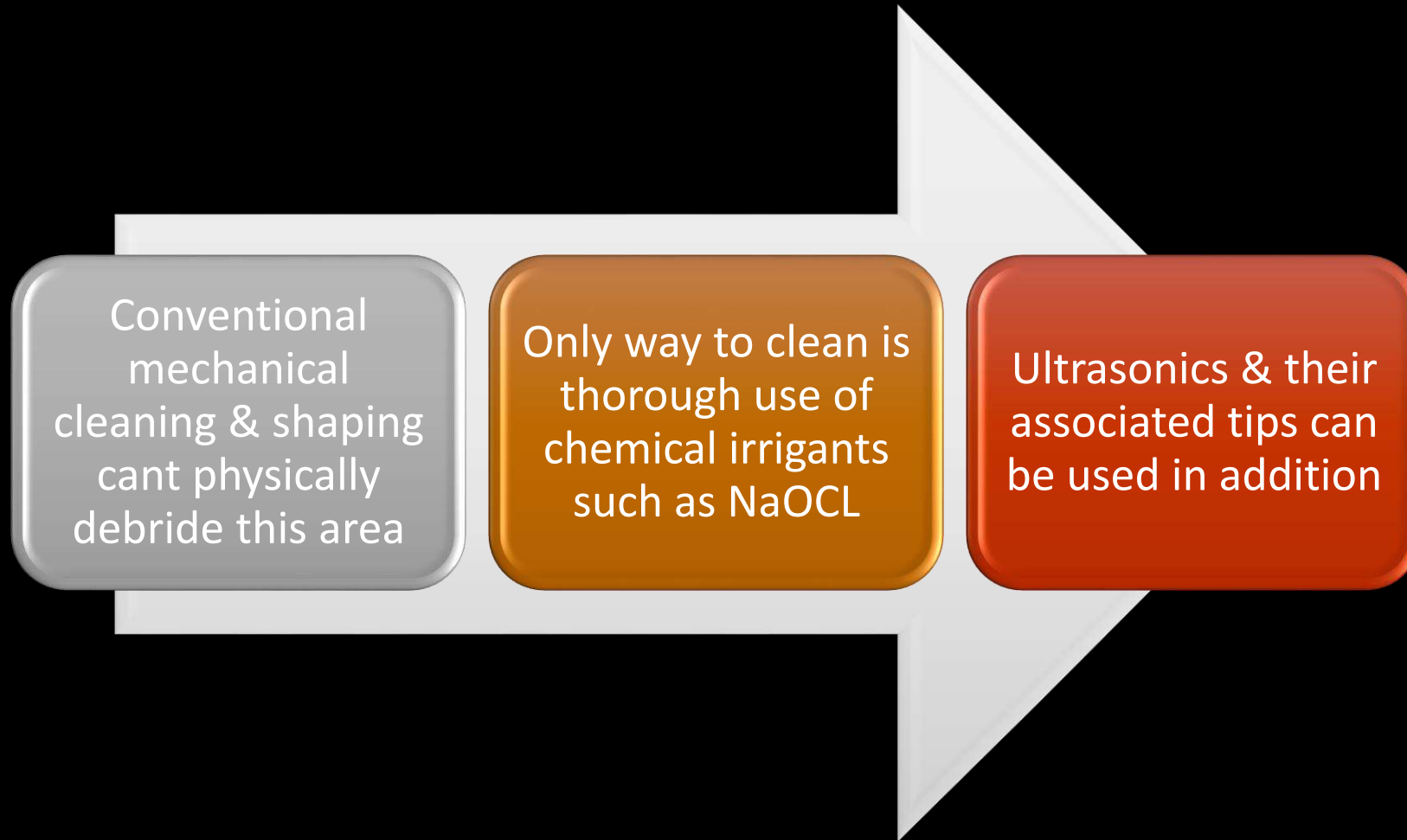
Category 2 : One canal was separated by dentin from the C-shaped canal (semi colon)

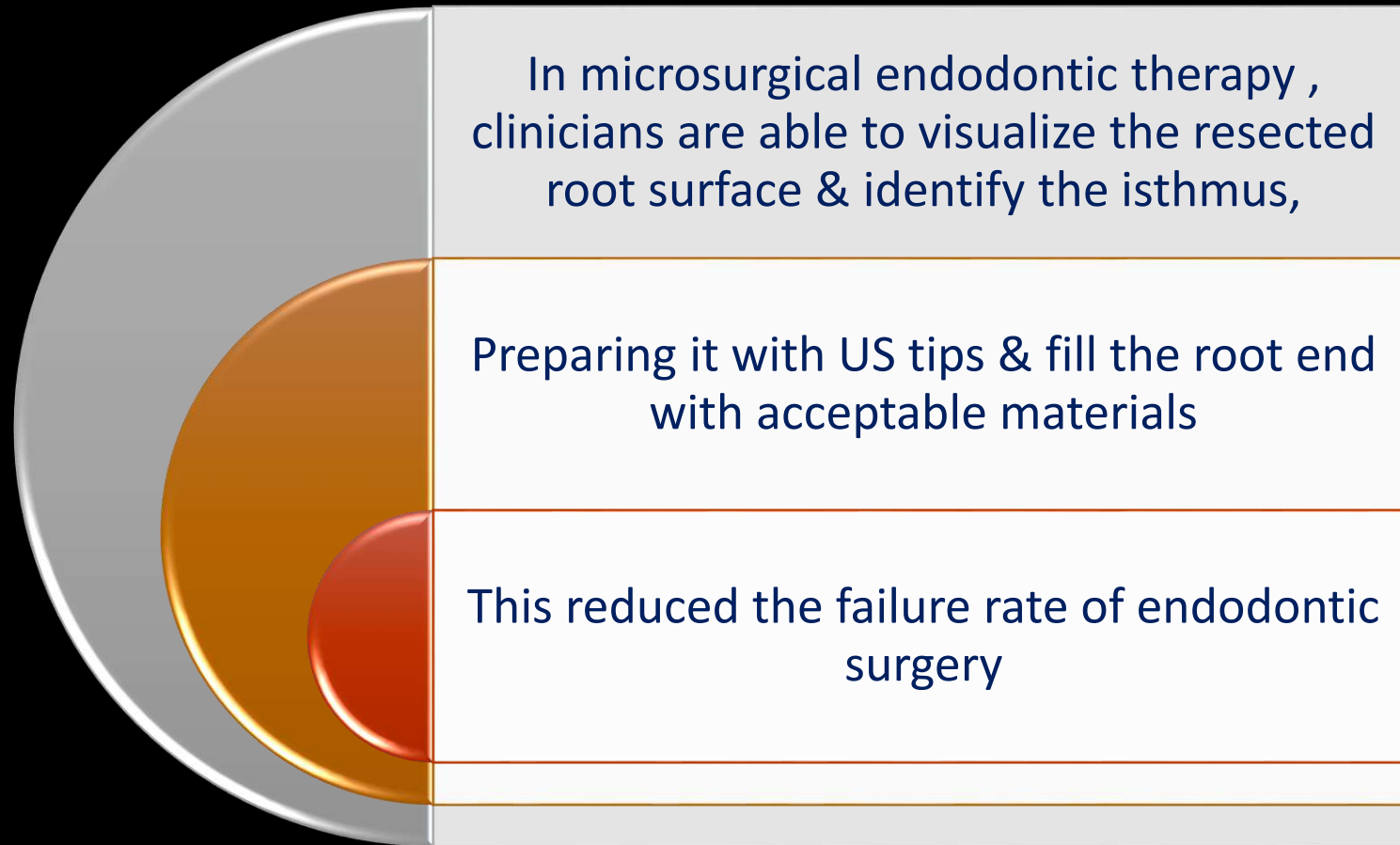


Category 3 : C-shaped orifice with 2 or more distinct and separate canals



Clinical significance

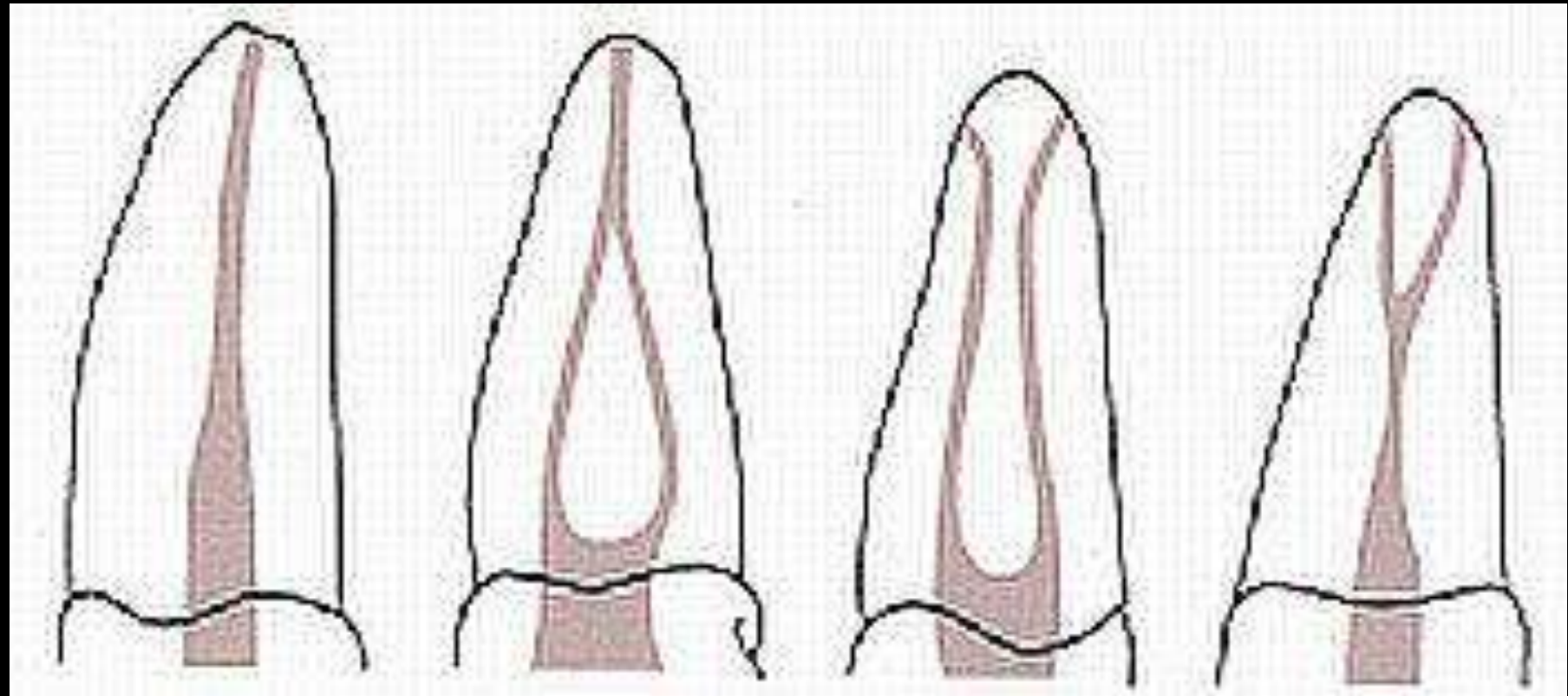






CLASSIFICATION OF ROOT CANAL SYSTEM

According to Weine et al.(1969)



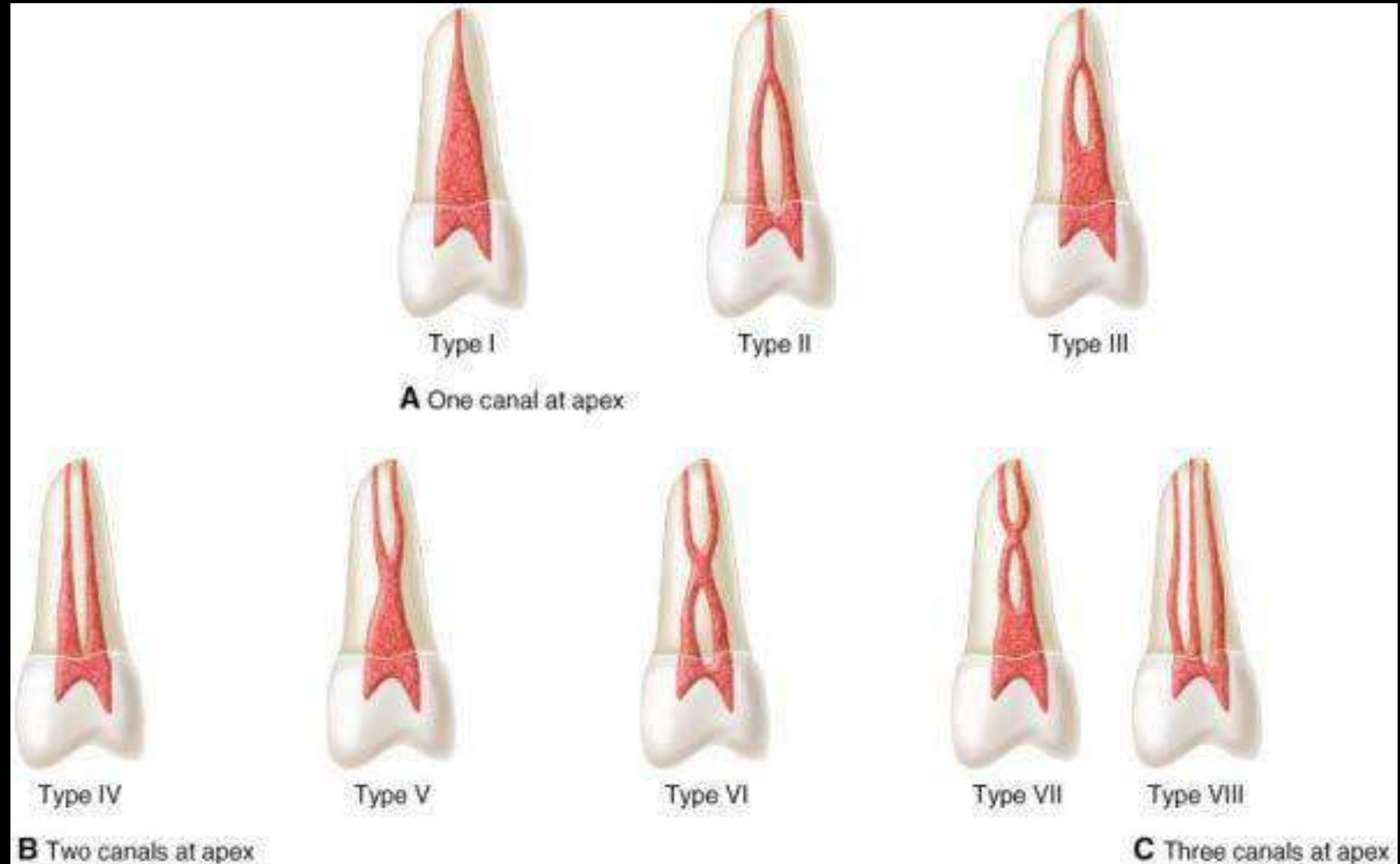
Type I

Type II

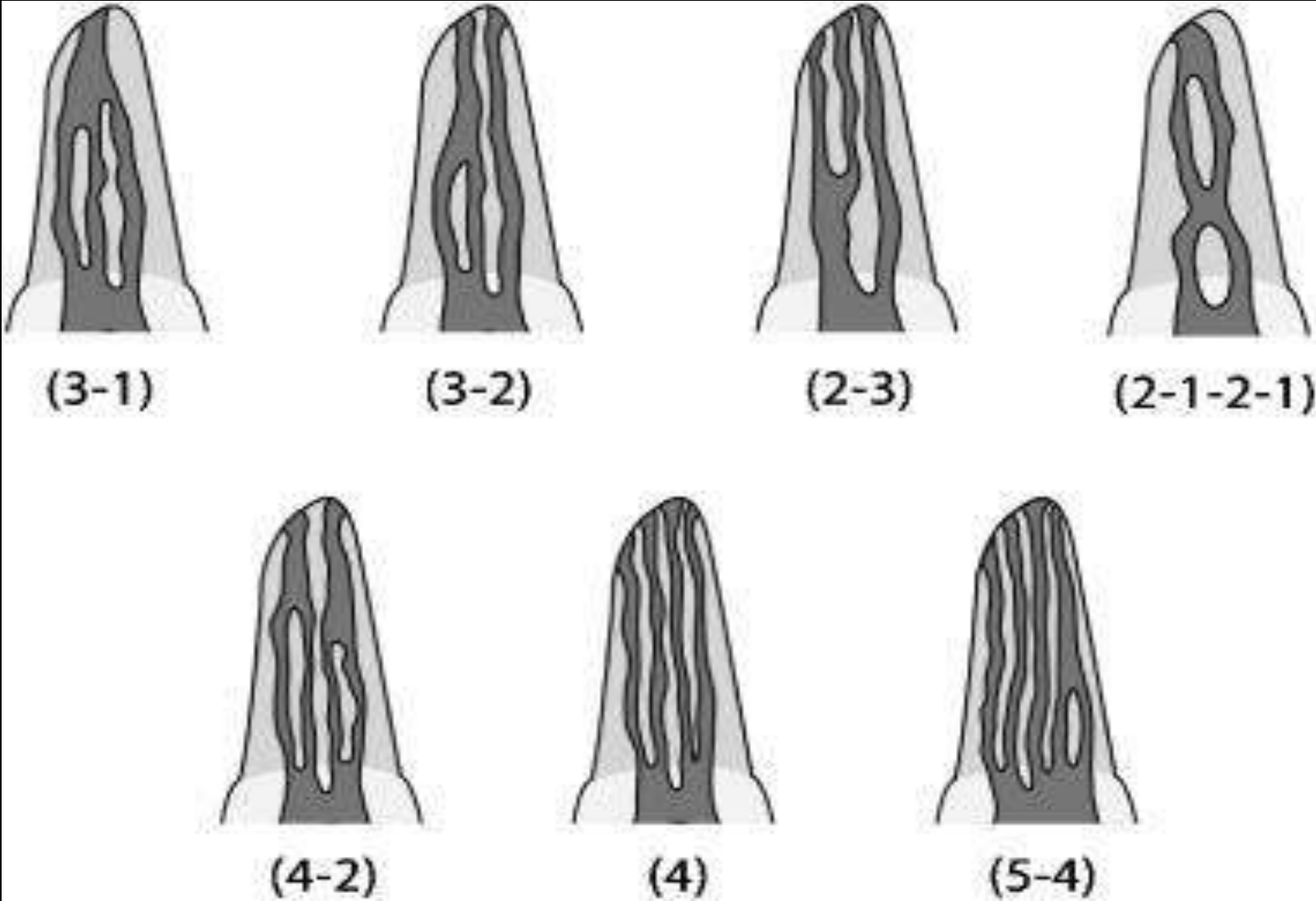
Type III

Type IV

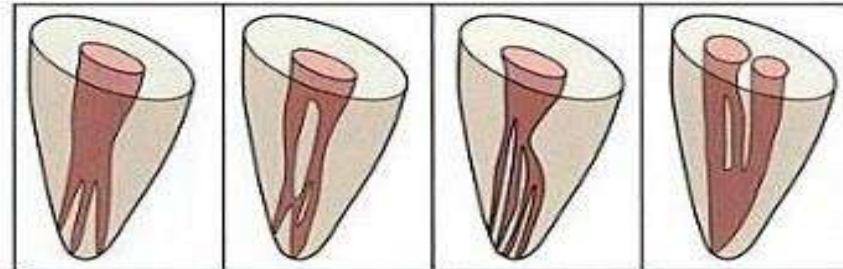
According to Vertucci et al.(1984)



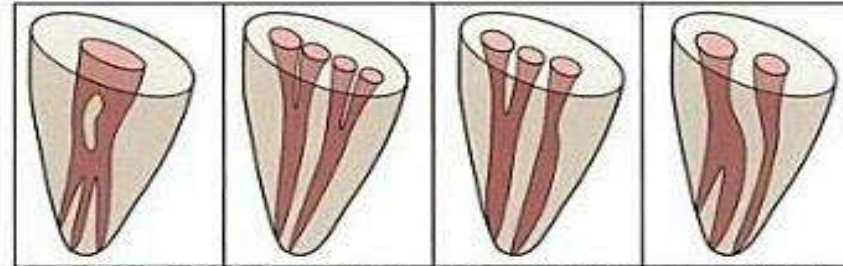
According to Gulabiwala et al.(2001)



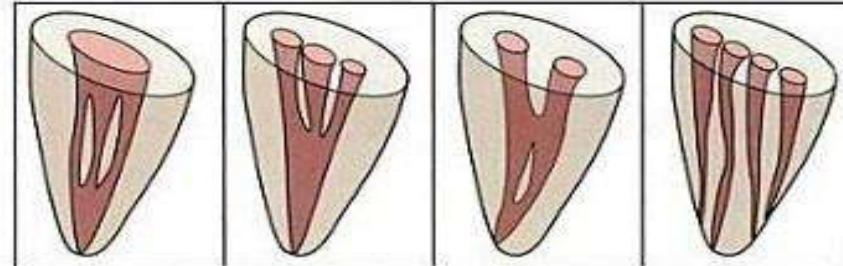
Sert and Bayirli classification(2004)



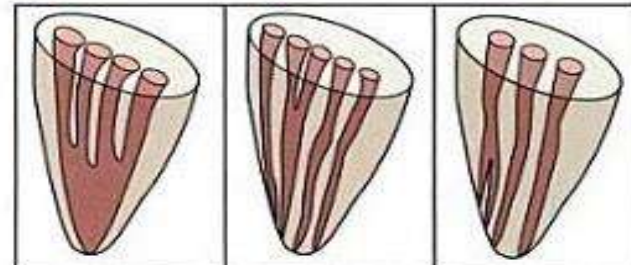
Type IX (1-3) Type X (1-2-3-2) Type XI (1-2-3-4) Type XII (2-3-1)



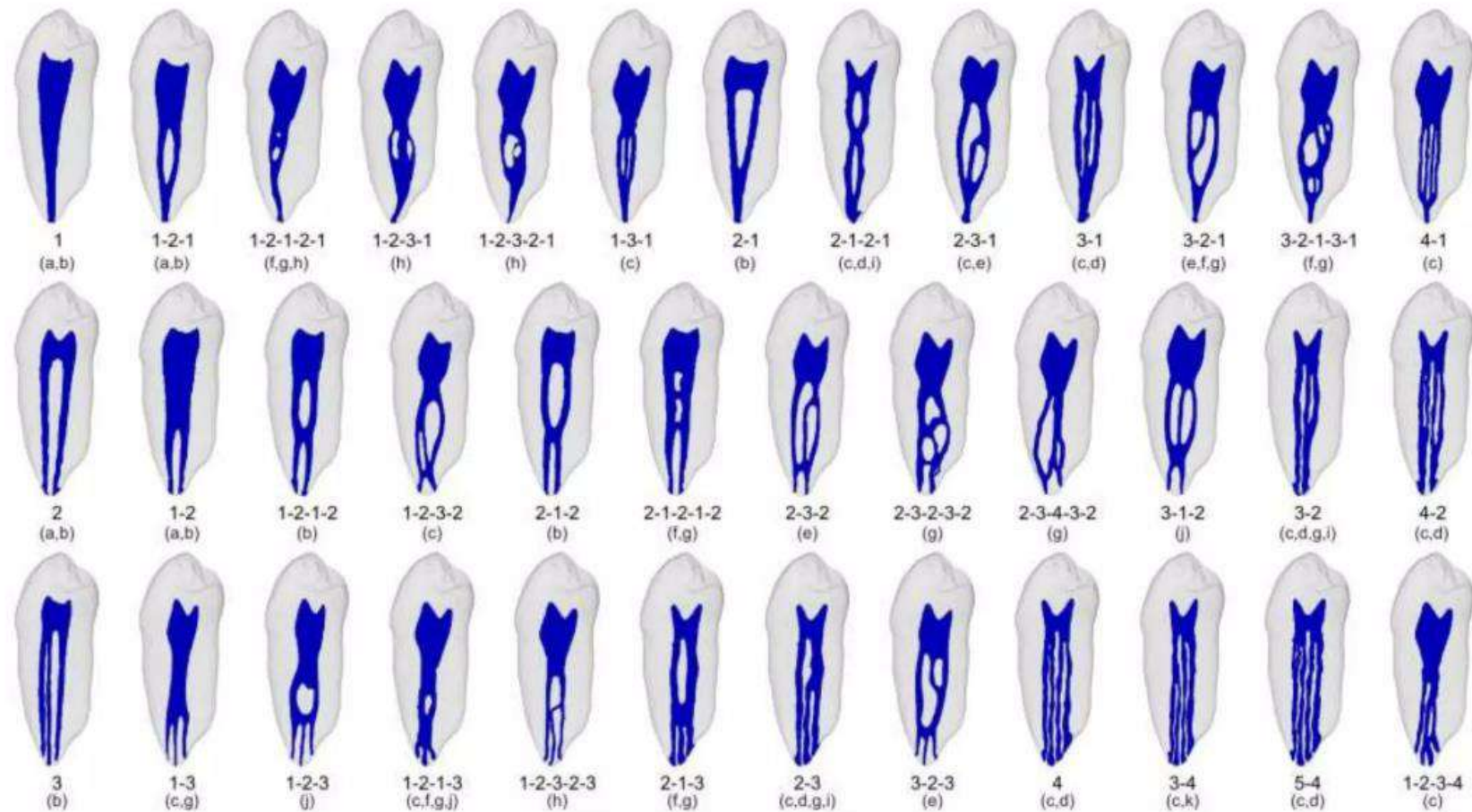
Type XIII (1-2-1-3) Type XIV (4-2) Type XV (3-2) Type XVI (2-3)



Type XVII (1-3-1) Type XVIII (3-1) Type XIX (2-1-2-1) Type XX (4)



Type XXI (4-1) Type XXII (5-4) Type XXIII (3-4)



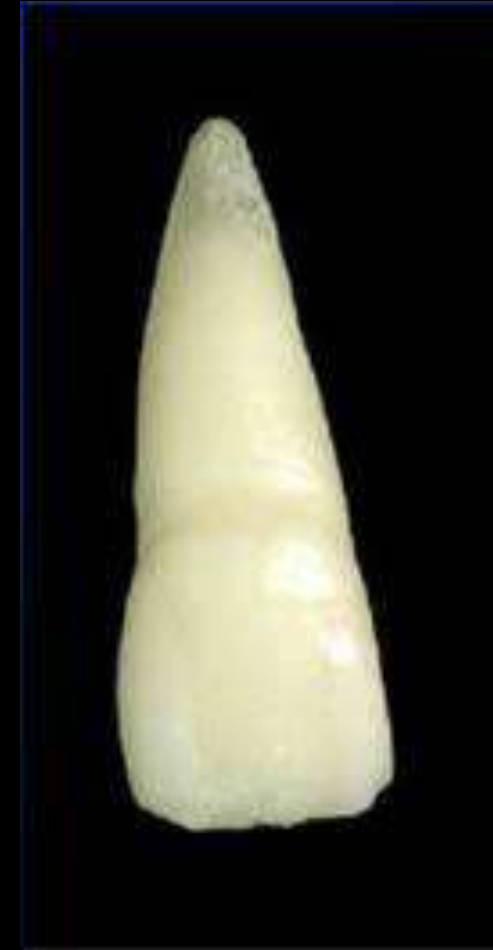Recently, based on previous reports and anatomical studies using micro-CT technology, **Versiani & Ordinola-Zapata (2015)** were able to identify **37 types of root canal configuration**.

Anatomy of teeth

Maxillary Central Incisor

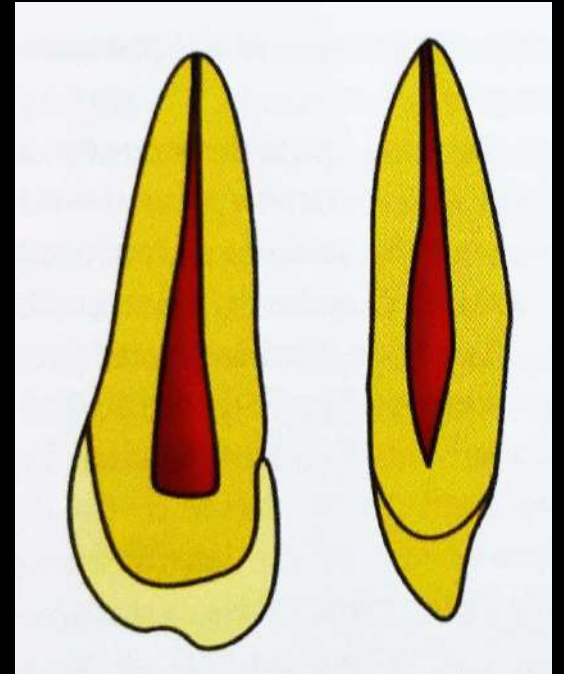
- Single rooted, straight root trunk
- Triangular / ovoid in cross section, tapers towards lingual
- Single root canal system
- Mid root and apical lateral canals are common
- Root apex & apical foramen are located distolabially.

Av. Tooth Length	23.5 mm
Av. Crown Length	10.5 mm
Av. Root Length	13 mm



PULP CHAMBER

- Located in the centre of crown equidistant from dentinal walls
- Broad mesiodistally – broadest part incisally
- Follows contours of crown & has 3 pulp horns which correspond to mammelons



Cross-Section

- | | |
|------------|-----------------------|
| • Cervical | Large in young |
| • Middle | Ovoid to round shaped |
| • Apical | Round shaped |




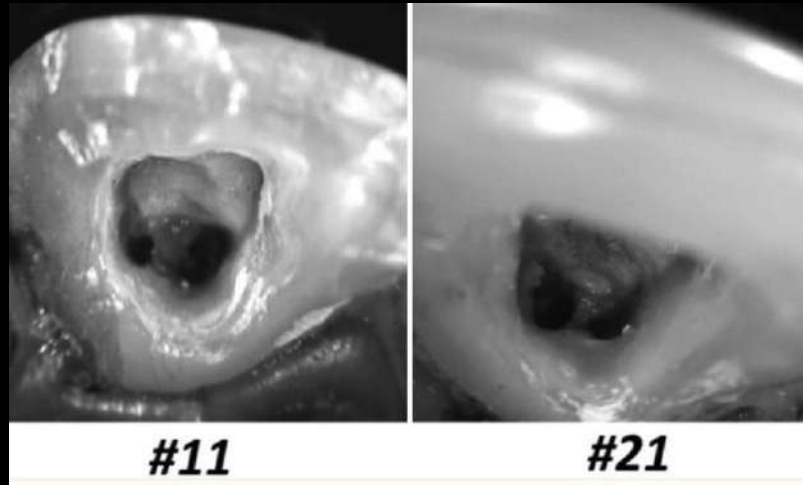
TABLE 1-2 Root Number in the Maxillary Central Incisor

Maxillary Central Incisors	No. of teeth in studies	1 Root	
		%	No. of teeth
Total number of root studies ^{5,7,11,14,31,78,99}	7	100	892

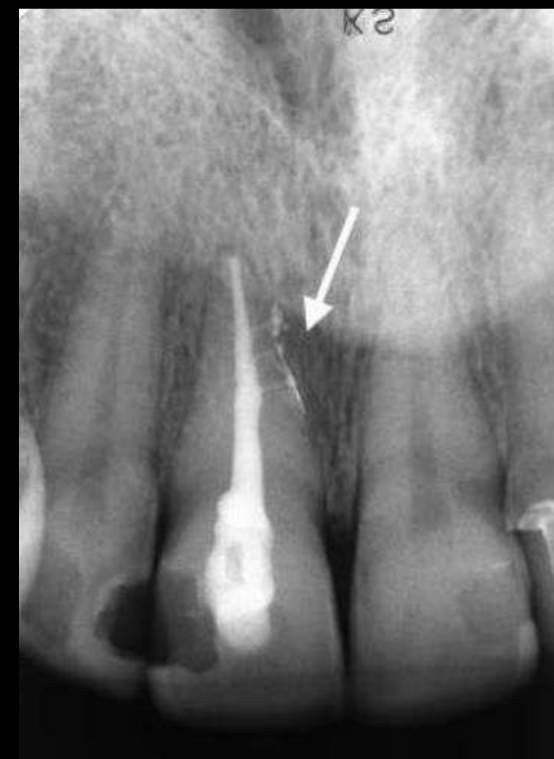
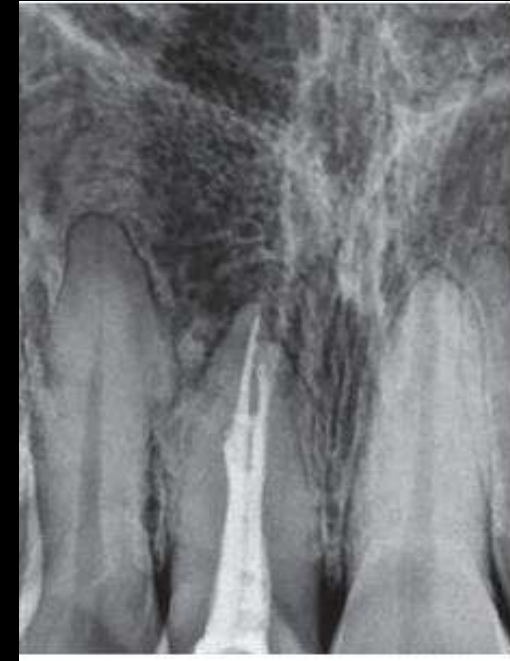
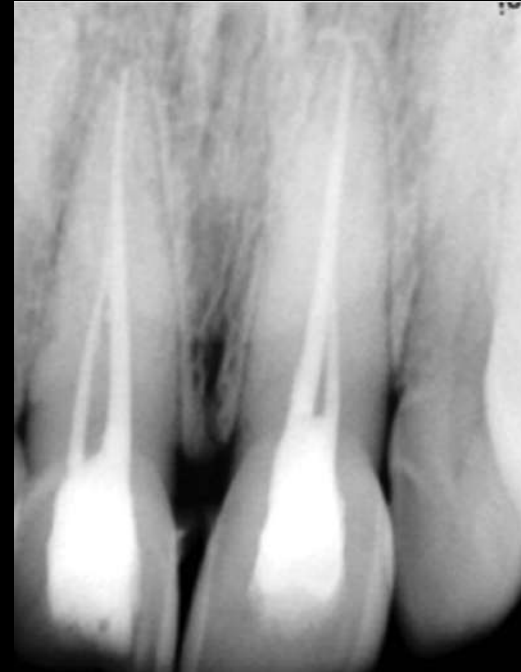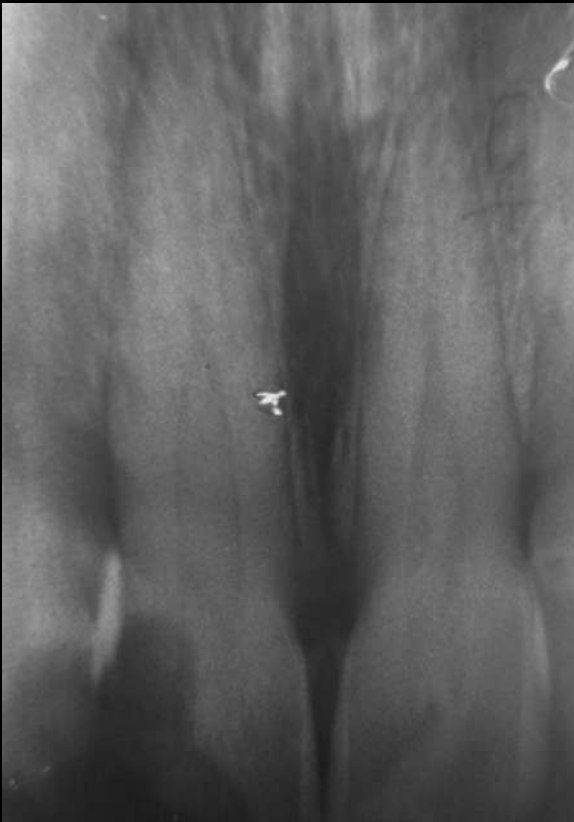TABLE 1-3 Main and Apical Canal Number of the Maxillary Central Incisor

Maxillary Central Incisors	No. of teeth in studies	1 canal		2 or more canals		1 canal at apex		2 or more canals at apex	
		%	No. of teeth	%	No. of teeth	%	No. of teeth	%	No. of teeth
Total number of canal studies ^{5,7,11,14,31,78,99,194}	8	99.2	2416	0.8	19	99.7	758	0.3	2
Total number of canal apices studies	5		760						

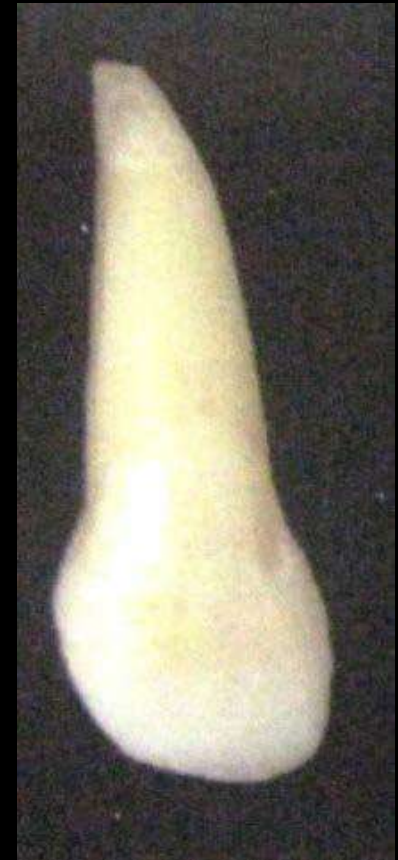

Kavitha M, Gokul K, Ramaprabha B, Lakshmi A. Bilateral presence of two root canals in maxillary central incisors: A rare case study. Contemp Clin Dent. 2014 Apr;5(2):282-6.

Maxillary Lateral Incisor


- Single rooted
- Root trunk smaller than central incisor
- Circular / ovoid in cross section, tapers towards lingual
- Single root canal system
- Root apex & apical foramen are displaced distolingually.

Av. Tooth Length	22.5 mm
Av. Crown Length	9 mm
Av. Root Length	13 mm



PULP CHAMBER

- Similar to maxillary central incisor (smaller)
- 2 pulp horns corresponding to developmental mammelons



Cross-Section

- | | |
|------------|--|
| • Cervical | Slightly ovoid becomes progressively round |
| • Middle | Slightly ovoid to round |
| • Apical | Round |


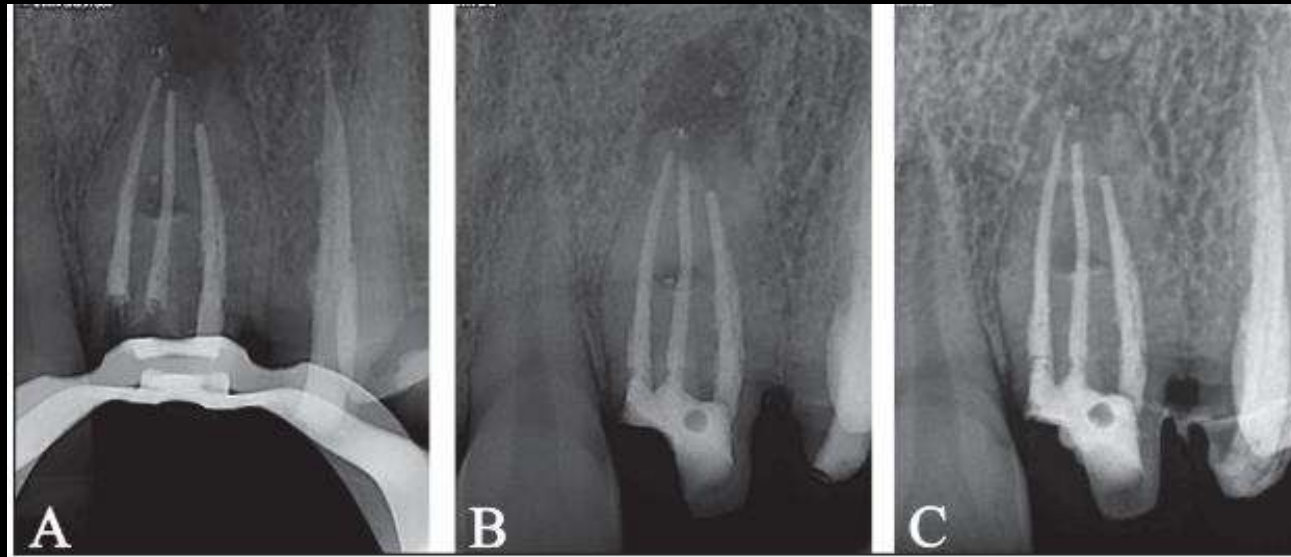
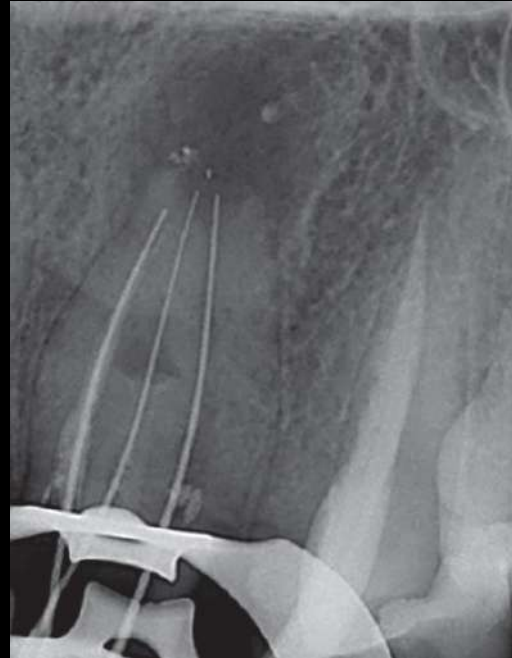


TABLE 1-5 Root Number in the Maxillary Lateral Incisor				
Maxillary Lateral Incisors Reference	No. of teeth in studies	1 Root		
		%	No. of Teeth	
Total number of root studies ^{5,7,11,14,31,78,298}	7	827	100	827

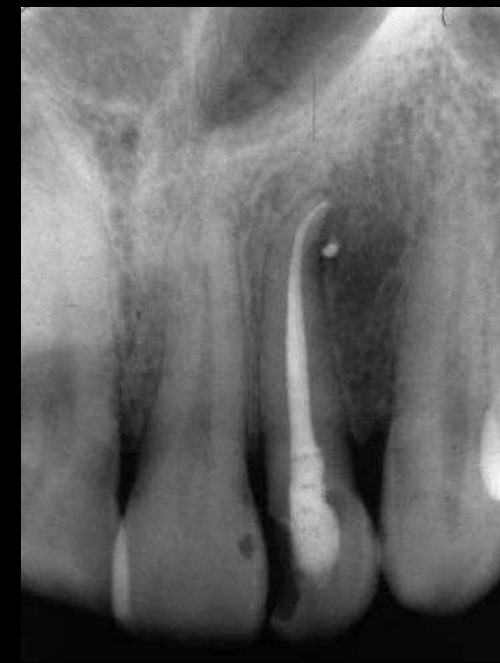

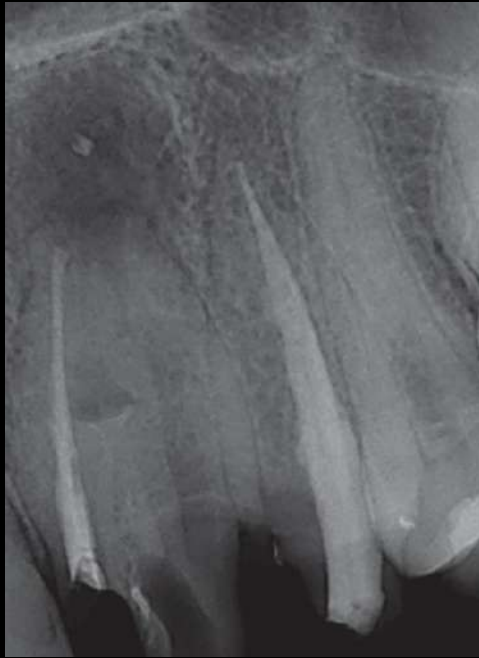TABLE 1-6 Main and Apical Canal Number of the Maxillary Lateral Incisor										
Maxillary Lateral Incisors References	No. of teeth in studies	1 canal		2 or more canals		1 canal at apex		2 or more canals at apex		
		%	No. of Teeth	%	No. of Teeth	%	No. of Teeth	%	No. of Teeth	
Total number of canal studies ^{5,7,11,14,31,78,194,298}	8	2331	97.4	2271	2.6	91				
Total number of canal apices studies	6	795					98.6	784	1.4	11



Maxillary Canine


- Single rooted, largest tooth in dentition
- Root is wider labiolingually
- Developmental depressions present in mesial & distal surfaces
- Ovoid in cross section
- Usually single root canal system
- Root apex & apical foramen are displaced distolabially.

Av. Tooth Length	26 mm
Av. Crown Length	10 mm
Av. Root Length	17 mm



PULP CHAMBER

- Triangular in shape with apex towards single cusp & broad base in cervical third of crown
- Mesiodistally : narrow resembling a flame



Cross-Section

- | | |
|------------|------------------------------------|
| • Cervical | Slightly ovoid |
| • Middle | Canal is smaller and remains ovoid |
| • Apical | Round |




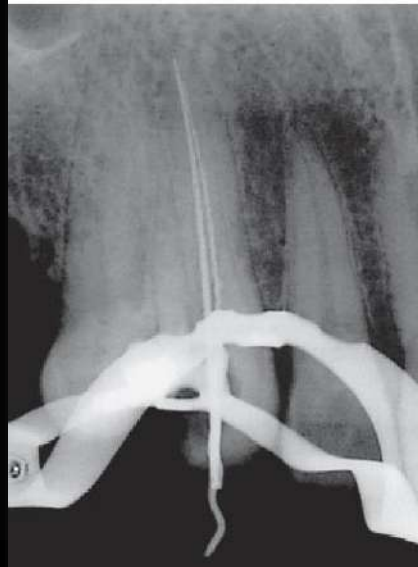
TABLE 1-8 Root Number in the Maxillary Canine

Maxillary canines references	No. of teeth in studies	1 Root		
		%	No. of Teeth	
Total number of root studies ^{5,7,11,14,31,78,298}	7	842	100	842

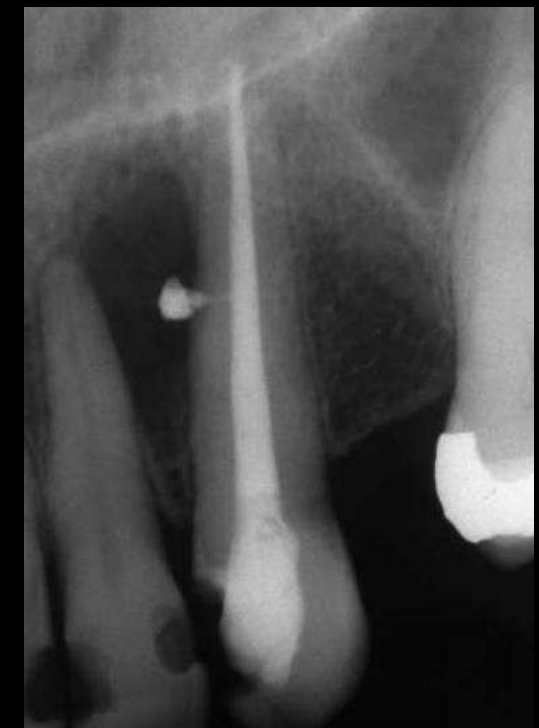
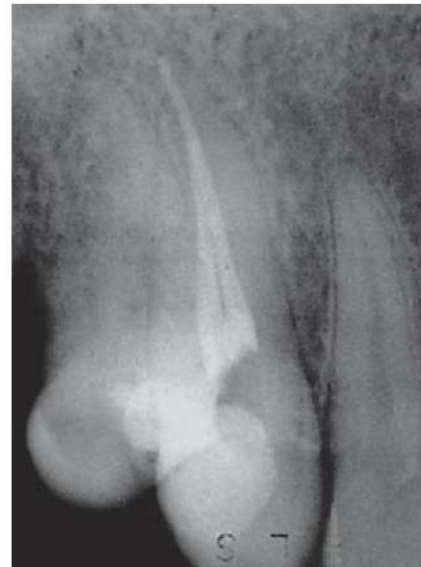
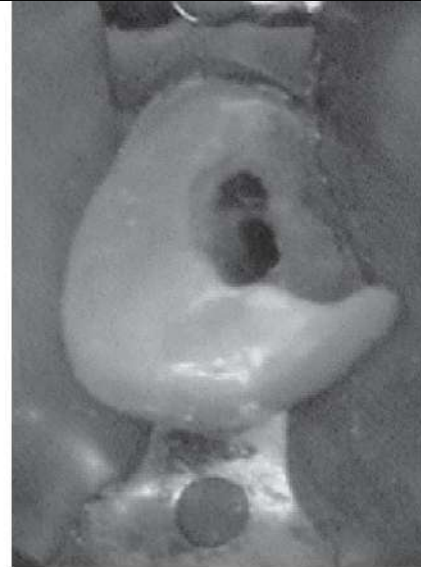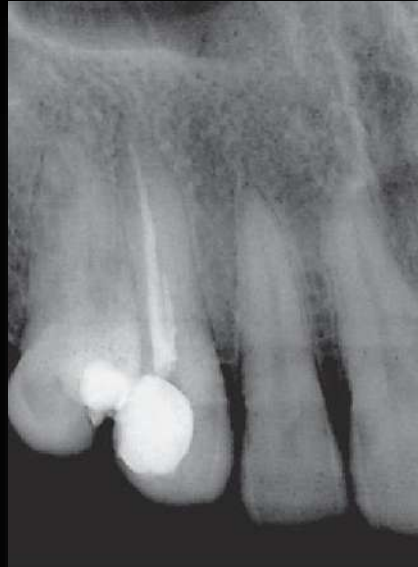TABLE 1-9 Main and Apical Canal Number of the Maxillary Canine

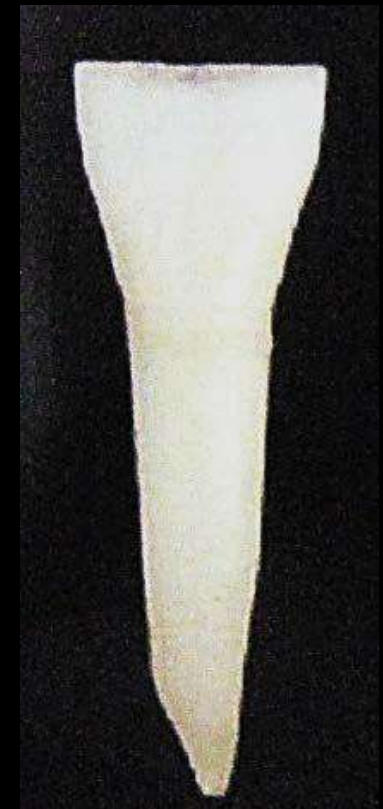Maxillary Canines References	No. of teeth in studies	1 canal		2 or more canals		1 canal at apex		2 or more canals at apex		
		%	No. of Teeth	%	No. of Teeth	%	No. of Teeth	%	No. of Teeth	
Total number of canal studies ^{5,7,11,14,31,78,141,194,298}	9	2615	95.30	2492	4.70	123				
Total number of canal apices studies	5	745					98.02	1039	1.98	21



Mandibular Central Incisor

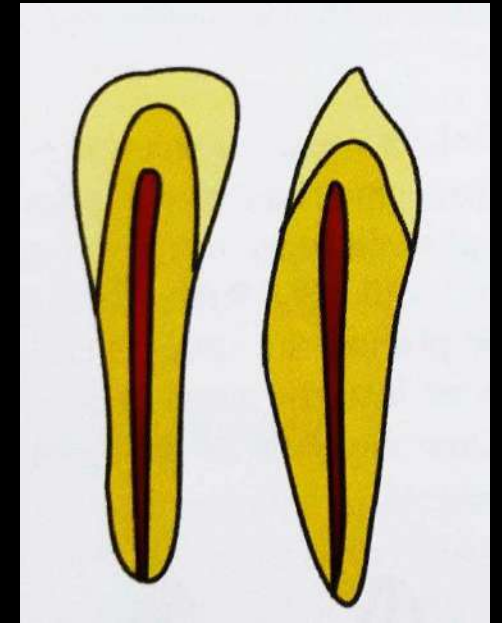
- Single rooted
- Broader labiolingually than mesiodistally
- Developmental depressions present in mesial & distal root surfaces
- Ovoid to hourglass in cross section
- Usually single root canal system, ovoid/ribbon

Av. Tooth Length	20.8 mm
Av. Crown Length	9 mm
Av. Root Length	12.5 mm



PULP CHAMBER

- Small & flat – mesiodistally
- Wide labiolingually
- Tapers incisally



Cross-Section

- | | |
|------------|----------------|
| • Cervical | Slightly ovoid |
| • Middle | Round |
| • Apical | Round |


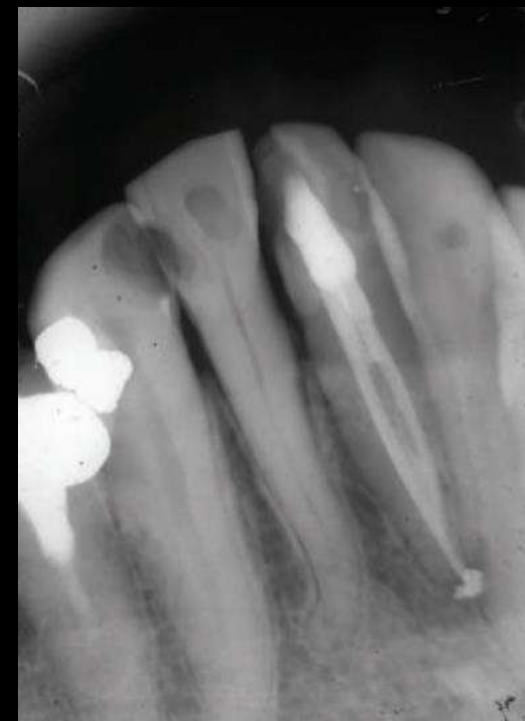


TABLE 1-25 Root Number in the Mandibular Central Incisor

Mandibular Central Incisors References	No. of teeth in studies	1 root		2 roots	
		%	No. of Teeth	%	No. of Teeth
Total number of teeth in root studies ^{5,7,11,31,187,586,587,588}	8	3286	100	3286	0

TABLE 1-26 Main and Apical Canal Number of the Mandibular Central Incisor

Mandibular Central Incisors References	No. of Teeth in Studies	1 canal		2 canals		> 2 canals		1 apical foramen		2 or more apical foramina	
		%	No. of Teeth	%	No. of Teeth	%	No. of Teeth	%	No. of Teeth	%	No. of Teeth
Total number of canal studies ^{5,7,11,31,168,186,187,194,586,587,588,591-597}	18	7455	81.1	6043	18.8	1399	0.2	13			
Total number of canal apices studies	12	4412						96.5	4256	3.5	156

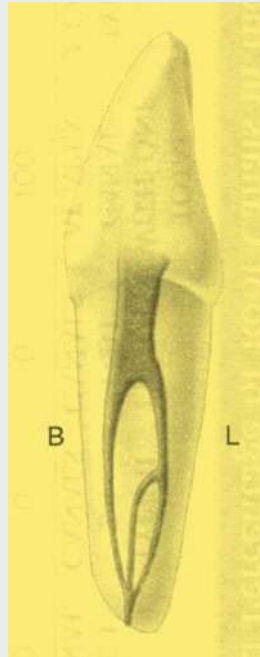


Additional Canal Configurations – Mandibular Incisors

By Kartal et al

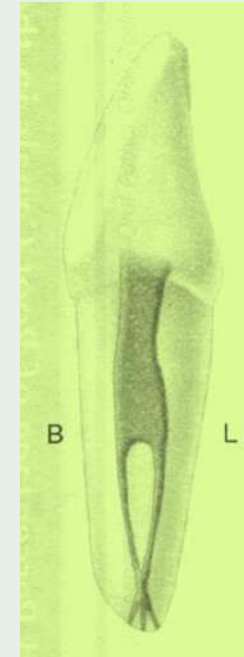
Type I

- Two separate canals extended from the pulp chamber to midroot
- Lingual canal divided into two
- All three canals joined in the apical third of the root and exited as one canal



Type II

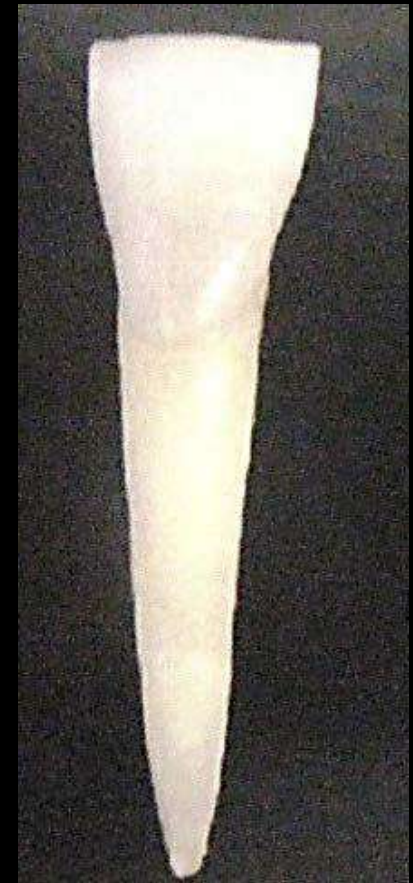- One canal left the pulp chamber
- Divided into two in the middle third of the root, then rejoined to form one canal,
- Which again split and exited as three separate canals with separate foramina



Mandibular Lateral Incisor

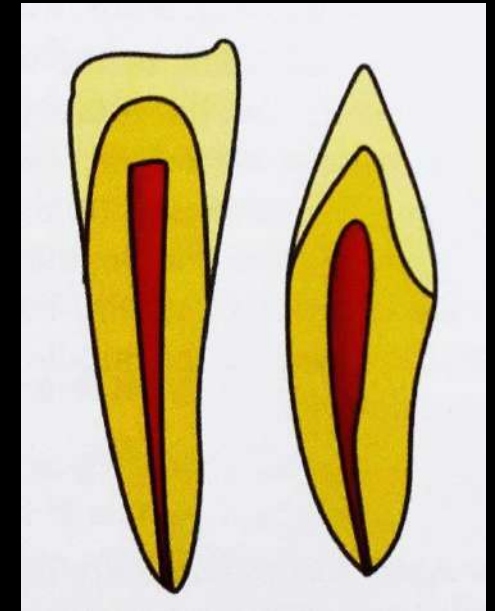
- Similar to Central Incisor
- Major difference is incisal edge anatomy
- Slight angulation to mesiolabial & distolingual of crown
- Usually single root canal system, round/ribbon shaped

Av. Tooth Length	22.6 mm
Av. Crown Length	9.5 mm
Av. Root Length	14 mm



PULP CHAMBER

- Similar to central incisor but slightly larger dimension
- Small & flat – mesiodistally
- Wide labiolingually
- Tapers incisally



Cross-Section

- | | |
|------------|----------------|
| • Cervical | Slightly ovoid |
| • Middle | Round |
| • Apical | Round |

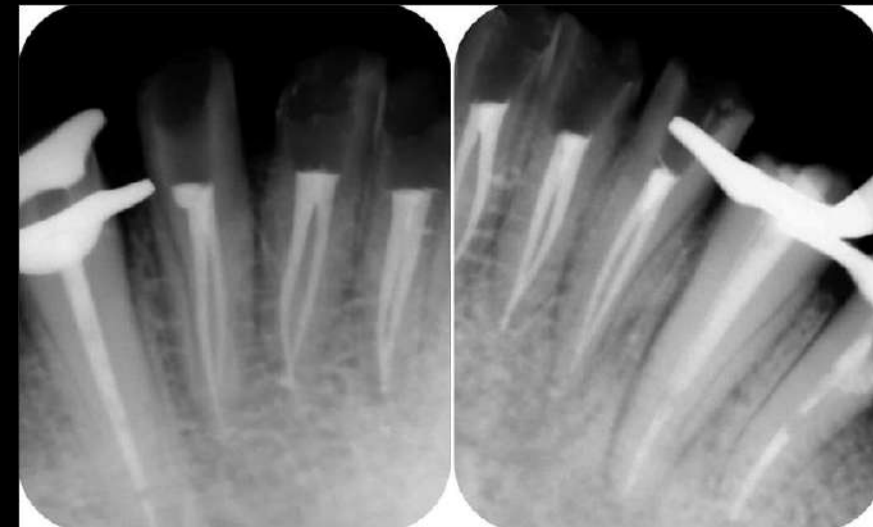
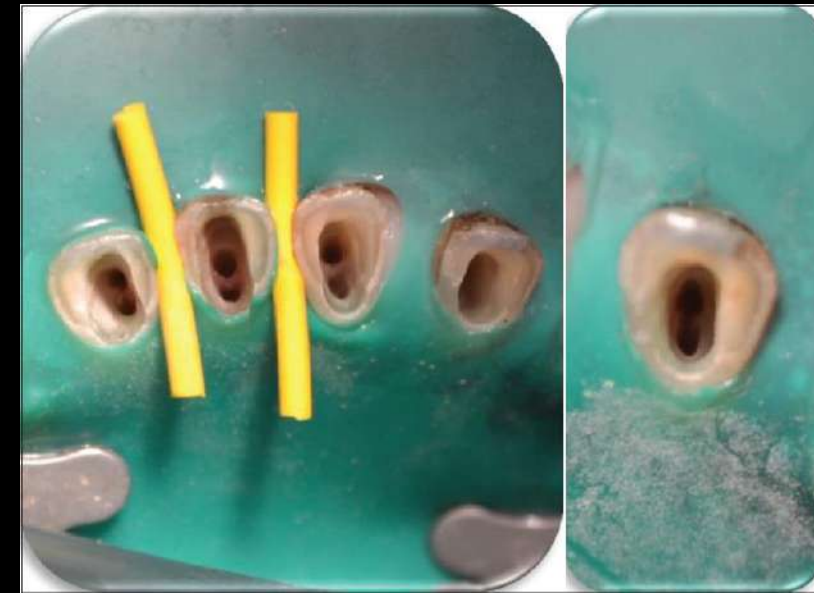

TABLE 1-28 Root Number in the Mandibular Lateral Incisor

Mandibular Lateral Incisors References	No. of teeth in studies			1 root	
				%	No. of Teeth
Total number of teeth in root studies ^{5,7,11,31,187,586-588}	8	3266	100		3258

TABLE 1-29 Main and Apical Canal Number of the Mandibular Lateral Incisor

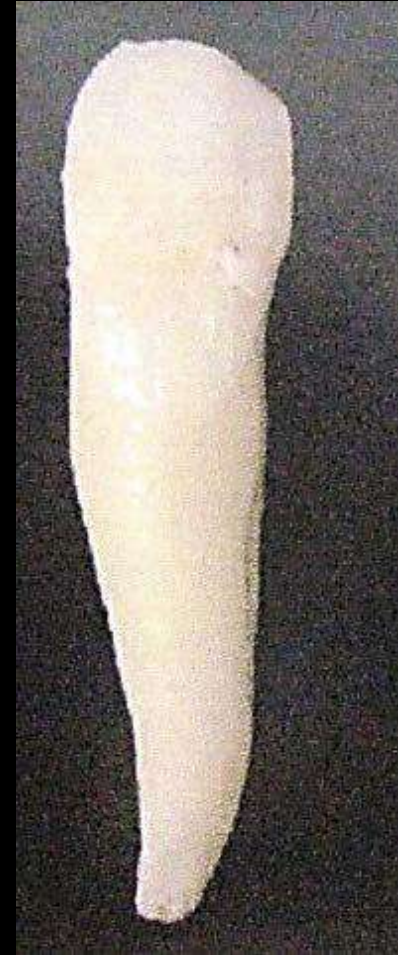Mandibular Lateral Incisors References	No. of teeth in studies	1 canal		2 canals		> 2 canals		1 apical foramen		2 apical foramina	
		%	No. of Teeth	%	No. of Teeth	%	No. of Teeth	%	No. of Teeth	%	No. of Teeth
Total number of canal studies ^{5,7,11, 31,168,186,187,194, 586-588,591-597}	18	7200	75.4	5427	24.6	1770	0.04	3			
Total number of canal apices studies	12	4374						95.8	4190	4.2	184



Mandibular Canine

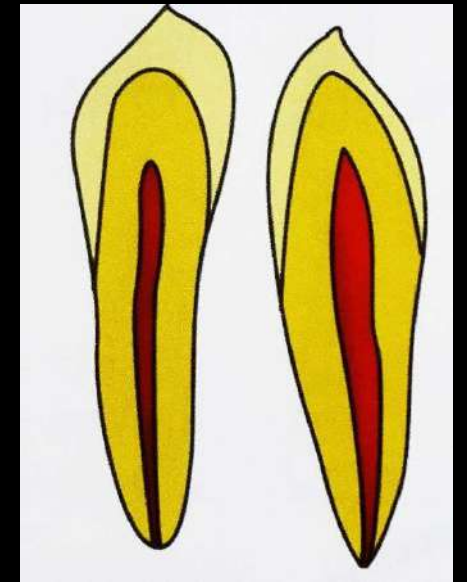
- Single rooted
- Broader labiolingually
- Developmental depressions are present in mesial and distal root surface.
- Usually single canal system

Av. Tooth Length	25 mm
Av. Crown Length	11 mm
Av. Root Length	16 mm




PULP CHAMBER

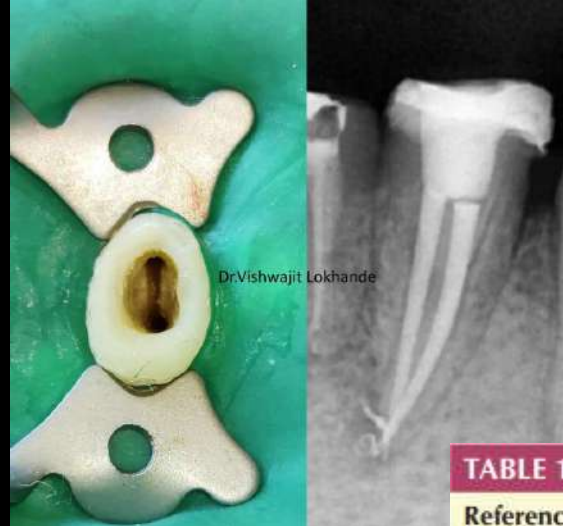- Resembles maxillary canine but smaller
- Narrow mesiodistally
- One pulp horn



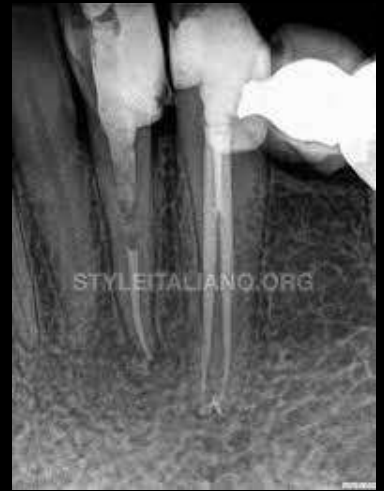Cross-Section

- | | |
|------------|-----------------|
| • Cervical | Ovoid |
| • Middle | Ovoid (smaller) |
| • Apical | Round |





DrVishwajit Lokhande



STYLEITALIANO.ORG

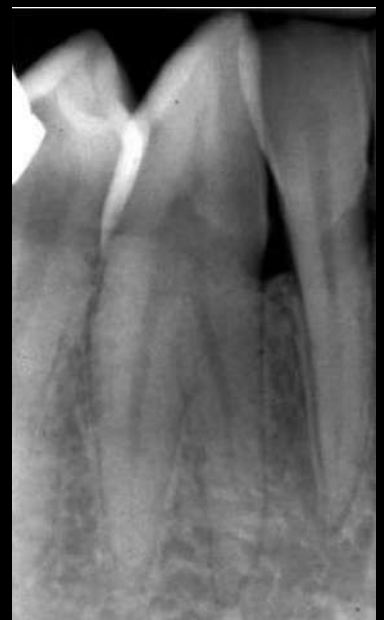

TABLE 1-31 Root Number in the Mandibular Canine

References	No. of teeth in study	1 root		2 roots		
		%	No. of Teeth	%	No. of Teeth	
Total number of teeth in root studies ^{5,85,401,586,619}	5	8356	95.4	7975	4.6	381

TABLE 1-32 Main and Apical Canal Number of the Mandibular Canine


Mandibular Canines References	No. of teeth in study	1 canal		2 or more canals		1 canal at apex		2 or more canals at apex	
		%	No. of Teeth	%	No. of Teeth	%	No. of Teeth	%	No. of Teeth
Total number of canal studies ^{5,7,11,14,31,85,131,141,168,194,409,586,594,596}	14	6081	90.5	5502	9.5	579			
Total number of canal apices studies	8	3058				97.9	2995	2.1	63



Maxillary 1st Premolar

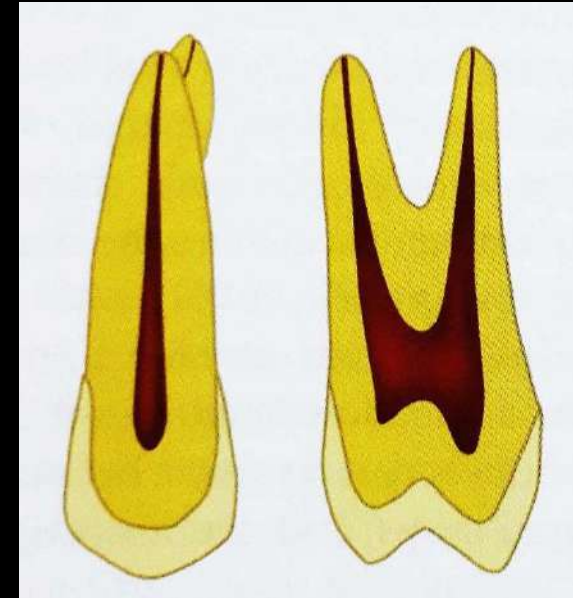
- Prominent developmental depressions on mesial and distal root surfaces (mesial root concavity more prominent)
- Broader buccopalatally & narrow mesiodistally
- Kidney shaped cross section at CEJ

Av. Tooth Length	21.5 mm
Av. Crown Length	8.5 mm
Av. Root Length	14 mm




PULP CHAMBER

- Narrow mesiodistally, wider buccopalatally
- Pulp horn under each cusp, buccal pulp horn more prominent
- Floor is convex
- 2 canal orifices (lies deep in coronal third of root below cervical line)



Cross-Section

- | | |
|------------|-------|
| • Cervical | Ovoid |
| • Middle | Round |
| • Apical | Round |



- FENESTRATION OF BUCCAL ROOT
- DEPRESSION
- DIVERGENCE AND PARALLELISM

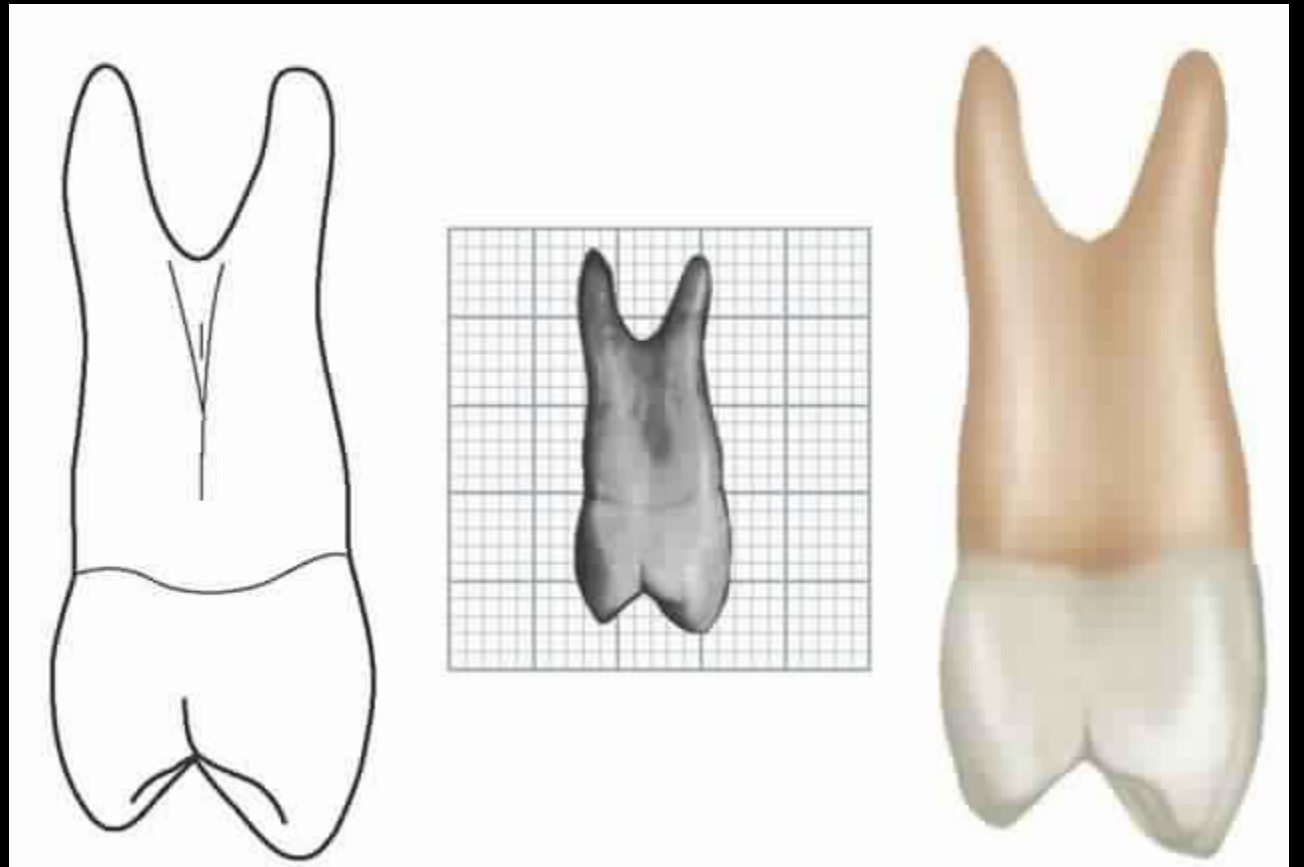


TABLE 1-11 Root Number in the Maxillary First Premolar

Maxillary First Premolars References	No. of teeth in studies	1 Root		2 Roots		3 Roots		>3 roots		
		%	No. of Teeth	%	No. of Teeth	%	No. of Teeth	%	No. of Teeth	
Total number of root studies (all studies)	18	7628	53.2	4055	45.6	3480	1.2	93	0.0	0
Total number of root studies (Non-Asian and NA Native populations) ^{5,7,6,8,8,89,103,109,113,125,135,407-410}	13	2647	37.0	978	60.8	1608	2.3	61	0.0	0
Total number of root studies (Asian and NA Native populations) ^{54,69,94,180,138}	5	4981	61.8	3077	37.6	1872	0.6	32	0.0	0

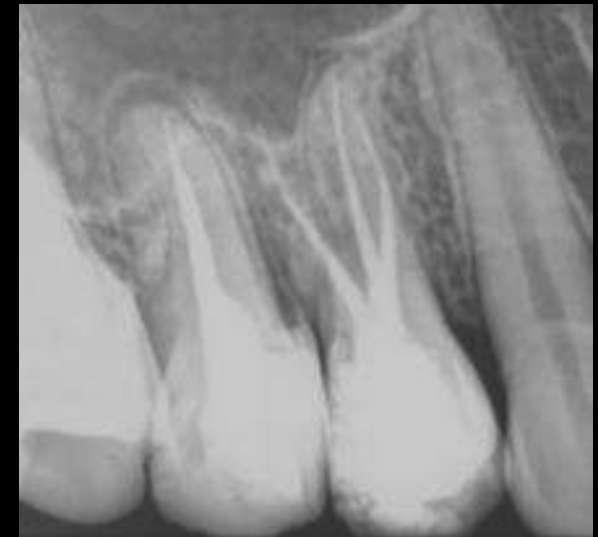
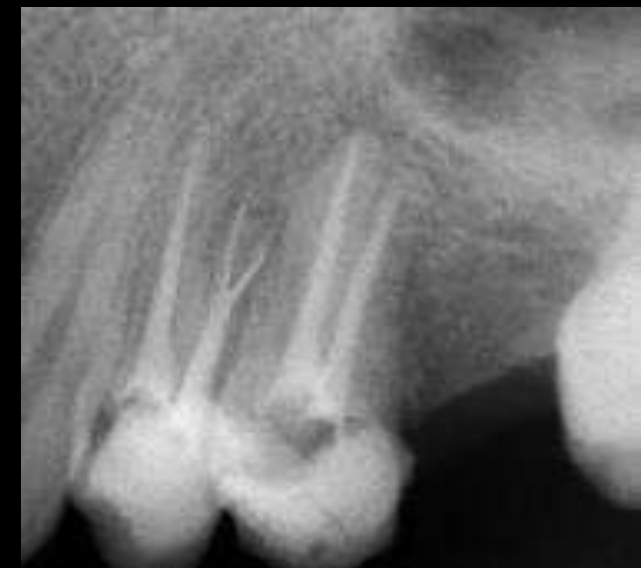
TABLE 1-12 Main and Apical Canal Number of the Maxillary First Premolar

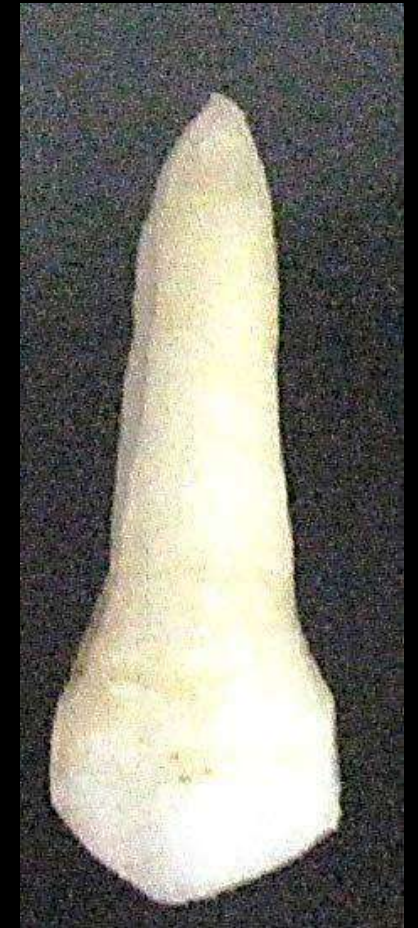Maxillary First Premolars References	No. of teeth in study	1 canal		2 canals		3 canals		Other canal configura- tions		1 canal at apex		2 canals at apex		3 canals at apex		Other con- figurations at apex	
		%	No. of Teeth	%	No. of Teeth	%	No. of Teeth	%	No. of Teeth	%	No. of Teeth	%	No. of Teeth	%	No. of Teeth	%	No. of Teeth
Total number of canal studies (all studies)	21	6618	16.0	1061	80.8	5348	1.3	89	1.8	120							
Total number of canal apices studies (all studies)	11	2429								24.2	587	73.6	1787	0.5	11	0.2	4
Total number of root studies (Non-Asian and NA Native populations) ^{5,7, 8,11,31,76,88,89, 103,109,113,135, 167,185,408-410}	17	5044	10.4	526	86.3	4353	1.6	83	1.6	82							
Total number of root studies (Asian and NA Native popula- tions) ^{54,69,78,94}	4	1574	34.0	535	63.2	995	0.4	6	2.4	38							



Maxillary 2nd Premolar

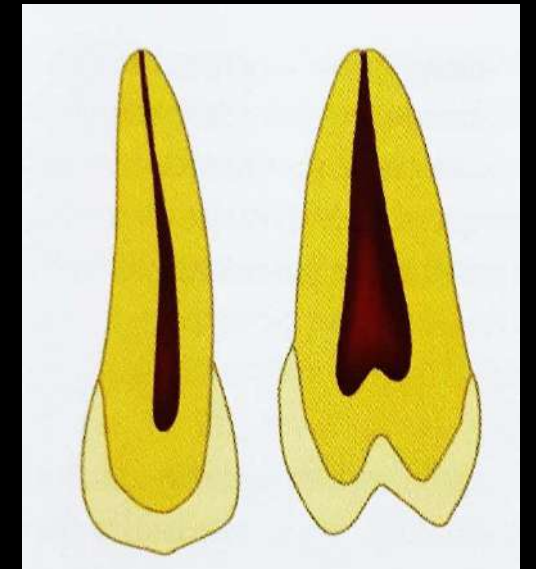
- Single rooted form – most common
- Broader buccopalatally & narrow mesiodistally
- Prominent developmental depressions on mesial and distal root surfaces
- Single canal system – 50.3%

Av. Tooth Length	21.6 mm
Av. Crown Length	8.5 mm
Av. Root Length	14 mm



PULP CHAMBER

- Narrow mesiodistally
- Wider buccopalatally than Maxillary 1st premolar
- Pulp horn under each cusp, buccal pulp horn more prominent



Cross-Section

- | | |
|------------|-------|
| • Cervical | Ovoid |
| • Middle | Round |
| • Apical | Round |




TABLE 1-14 Root Number in the Maxillary Second Premolar

Maxillary Second Premolars References	No. of teeth in studies	1 Root		2 Roots		3 Roots		
		%	No. of teeth	%	No. of teeth	%	No. of teeth	
Total number of root studies ^{35,43,87,138,387,408,410,431}	8	9033	91.5	8263	8.4	756	0.2	14

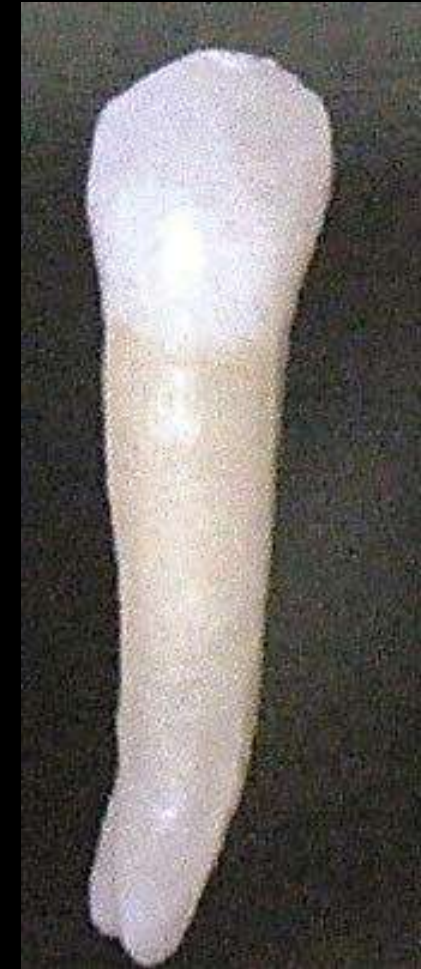TABLE 1-15 Main and Apical Canal Number of the Maxillary Second Premolar

Maxillary Second Premolars References	No. of teeth in studies	1 canal		2 canals		3 canals		Other canal configurations		1 canal at apex		2 or more canals at apex		
		%	No. of teeth	%	No. of teeth	%	No. of teeth	%	No. of teeth	%	No. of teeth	%	No. of teeth	
Total number of canal studies ^{7,11,14, 31,78,80,87,89, 167,185,408-410, 431,433}	16	4829	51.8	2502	46.2	2233	0.8	38	2.0	56				
Total number of canal apices studies	12	2470									63.6	1571	36.0	890

Mandibular 1st PREMOLAR

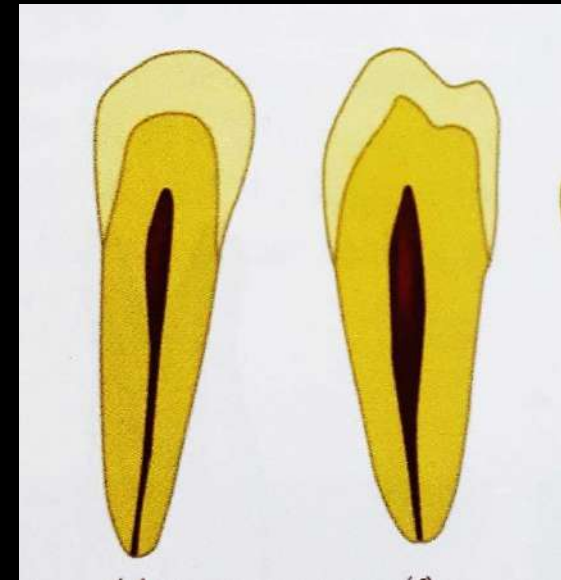
- Single rooted
- Broader buccolingually
- Developmental depressions on distal root surface is deeper than mesial surface
- Ovoid / hourglass shape in cross section

Av. Tooth Length	21.9 mm
Av. Crown Length	8.5 mm
Av. Root Length	14 mm



PULP CHAMBER

- Narrow mesiodistally
- Wider buccolingually with prominent buccal pulp horn
- Prominent buccal cusp & small lingual cusp



Cross-Section

- | | |
|------------|--------------------------------|
| • Cervical | Very narrow and ovoid |
| • Middle | 2 branches of canals are Round |
| • Apical | Round |

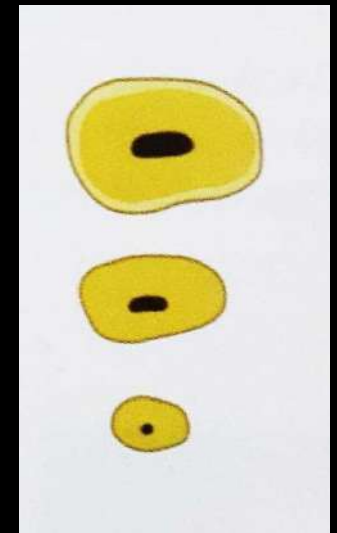


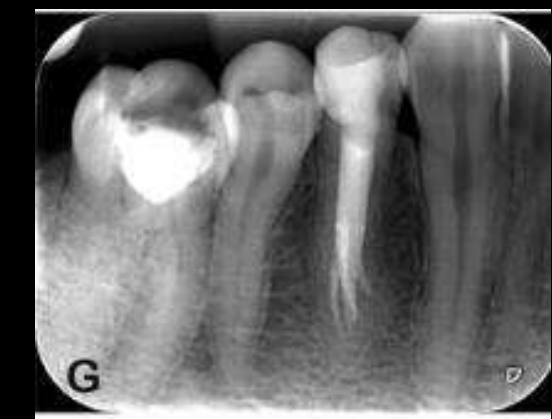TABLE 1-34 Root Number in the Mandibular First Premolar

References	No. of teeth in study	1 Root		2 Roots		3 Roots		4 Roots	
		%	No. of Teeth	%	No. of Teeth	%	No. of Teeth	%	No. of Teeth
Total number of teeth in root studies ^{5,7,11,11,100,108,114,120,121,129,177,178,408,635,636,637}	15 6348	97.1	6163	2.7	173	0.2	10	0.0	2


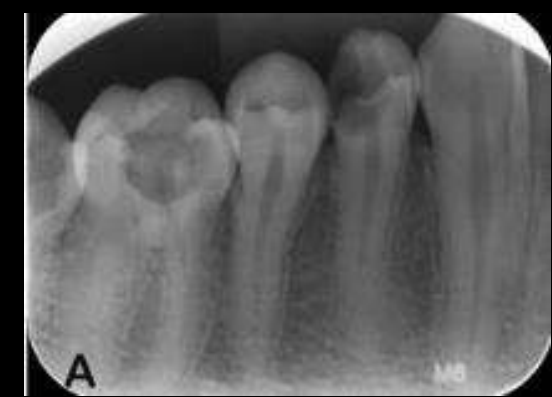


TABLE 1-35 Main and Apical Canal Number of the Mandibular First Premolar

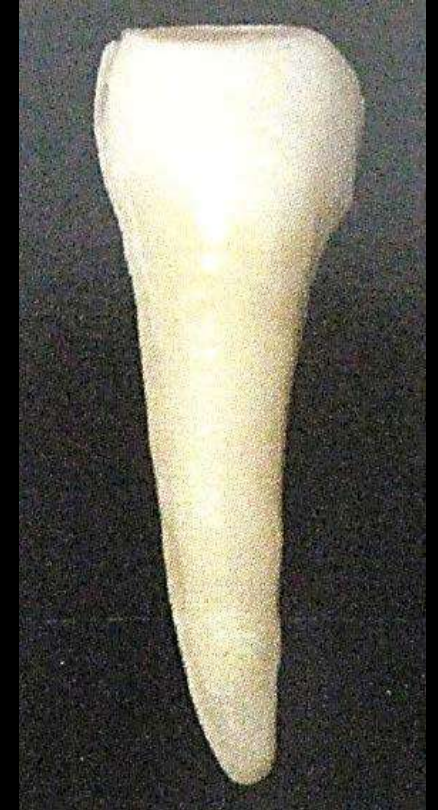Mandibular First Premolars References	No. of teeth in study	1 canal		2 or more canals		1 canal at apex		2 or more canals at apex	
		%	No. of Teeth	%	No. of Teeth	%	No. of Teeth	%	No. of Teeth
Total number of canal studies ^{5,7,11,22,31,56,68,75,100,102,108,114,117,120,121,124,126,129,149,156,177,178,185,408,409,410,596,635,646}	29 8538	77.3	6601	22.7	1937				
Total number of canal apices studies	20 4651					76.7	3568	23.3	1083



Mandibular 2nd Premolar

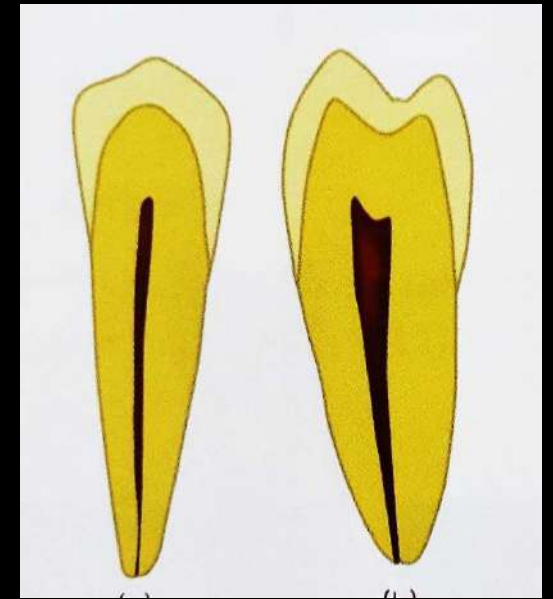
- Single rooted
- Mesial surface of root is flat / convex
- Developmental depressions on distal root surface
- Ovoid in cross section

Av. Tooth Length	22.3 mm
Av. Crown Length	8 mm
Av. Root Length	14.5 mm



PULP CHAMBER

- Narrow mesiodistally
- Wider buccolingually
- Prominent Lingual pulp horn



Cross-Section

- | | |
|------------|-----------------------|
| • Cervical | Very narrow and ovoid |
| • Middle | Less ovoid |
| • Apical | Round |

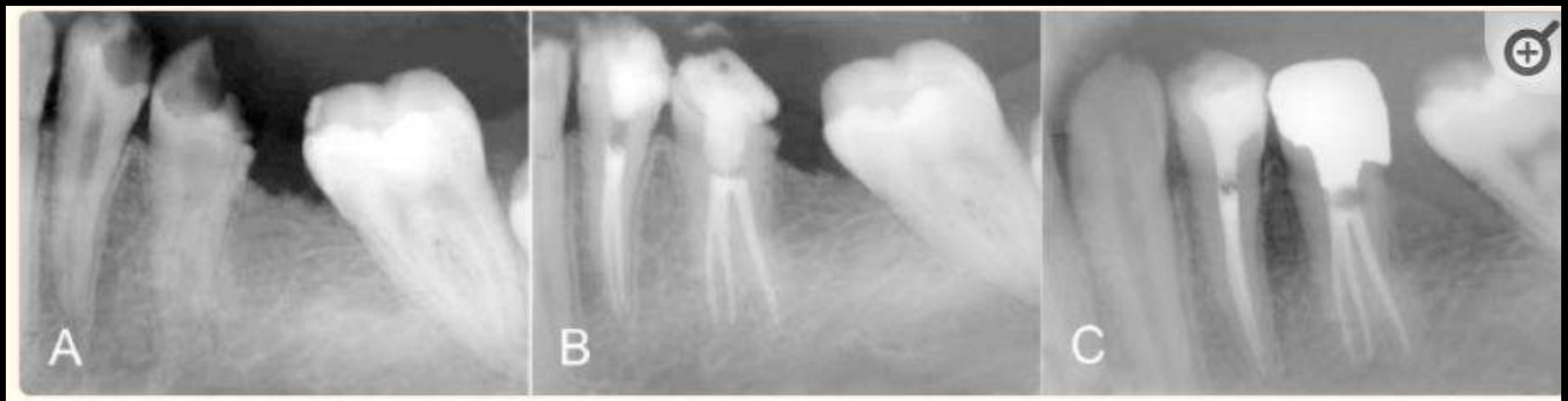
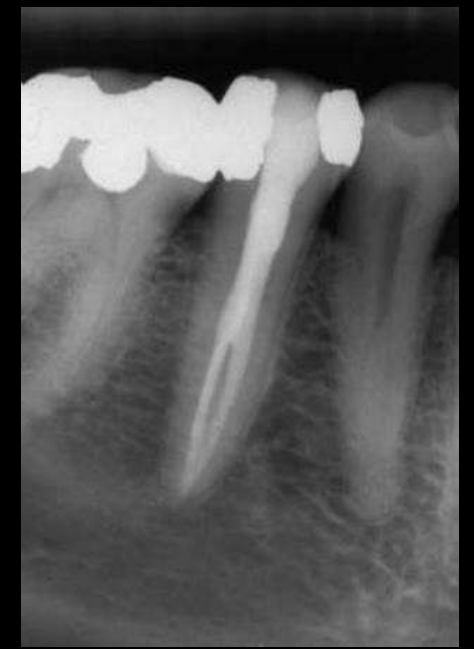

TABLE 1-37 Root Number in the Mandibular Second Premolar

References	No. of teeth in study		1 Root		2 Roots		3 Roots	
			%	No. of Teeth	%	No. of Teeth	%	No. of Teeth
Total number of teeth in root studies ^{5,7,11,99,100,102,108,114,130,177,408,635,646,667}	14	5055	99.4	5026	0.5	23	0.1	6

TABLE 1-38 Main and Apical Canal Number of the Mandibular Second Premolar

References	No. of teeth in study		1 canal		2 or more canals		1 canal at apex		2 or more canals at apex	
			%	No. of Teeth	%	No. of Teeth	%	No. of Teeth	%	No. of Teeth
Total number of canal studies ^{5,7,11,31,75,90,99,100,102,108,114,130,177,185,408,409,596,635,646}	19	5521	91.3	5043	8.7	478				
Total number of canal apices studies	14	3123					90.6	2828	9.4	295



Maxillary 1st

Molar

- **Mesiobuccal Root :**

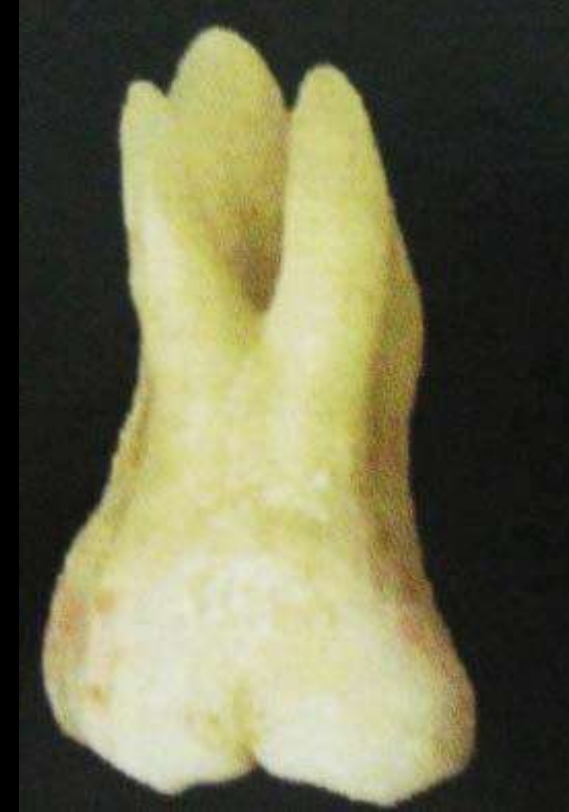- Broad buccolingually
- Developmental depressions in both mesial & distal root surfaces

- **Distobuccal Root :**

- Round / ovoid in cross section

- **Palatal Root :**

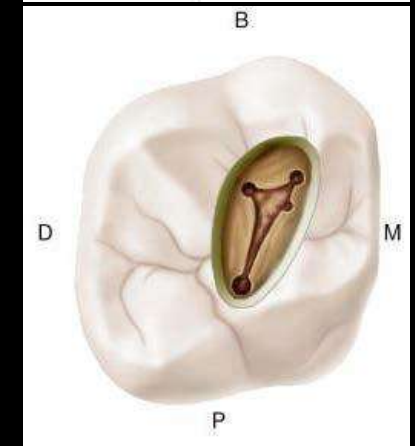
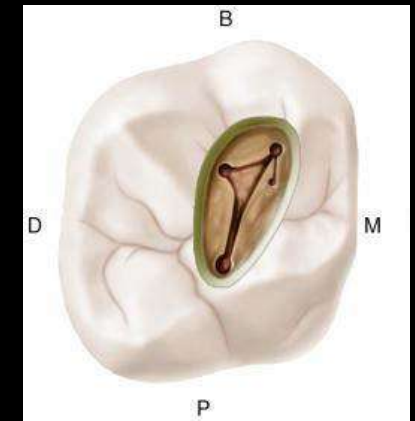
- Broad mesiodistally
- Ovoid in cross section
- Buccal curvature at the apical third



Av. Tooth Length	21.3 mm
Av. Crown Length	7.5 mm
Av. Root Length	13 mm

PULP CHAMBER

- Largest in the arch
- 4 pulp horns : MB, MP, DB, DP
- Roof – Rhomboidal in shape
- Roof converges, lingual wall disappears and forms a triangular form
- Anatomic dark lines in the floor connect the orifices
- Orifices are located in the 3 angles of the floor



Canal System

Mesiobuccal Root

- Have distal curvature – 78%
- Straight – 21%
- Bayonet – 1%
- Narrowest of 3 canals
- Apical foramen centrally located

Distobuccal Root

- Small
- Straight – 54%
- Distal curve – 17%
- Mesial curve – 19%
- Bayonet – 10%
- Apical foramen centrally located

Palatal Root

- Largest root & diameter, ovoid mesiodistally, tapers apically
- May curve buccally in the apical third

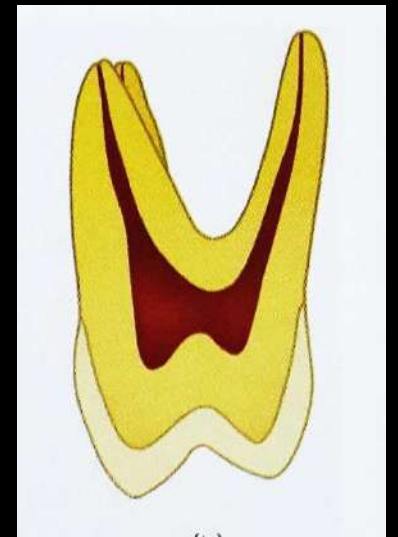

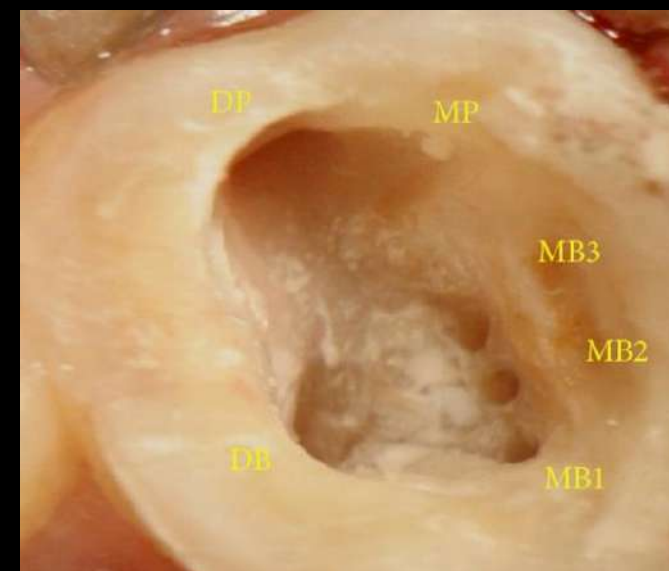
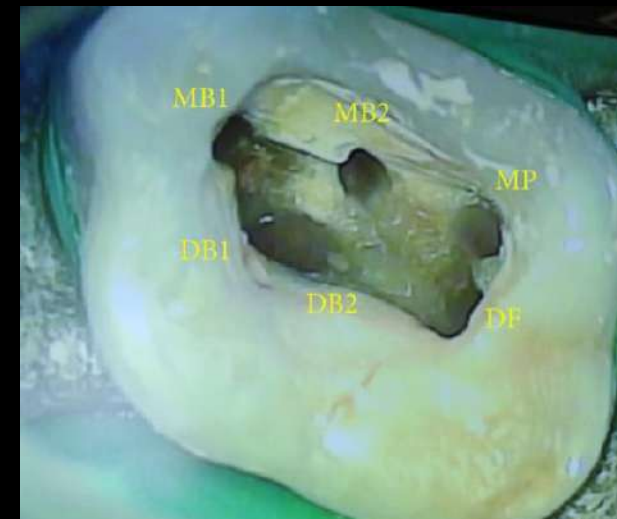

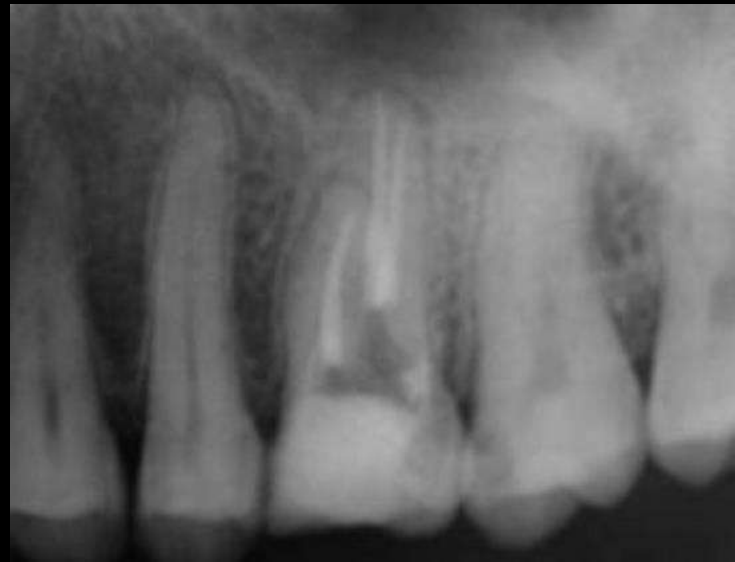
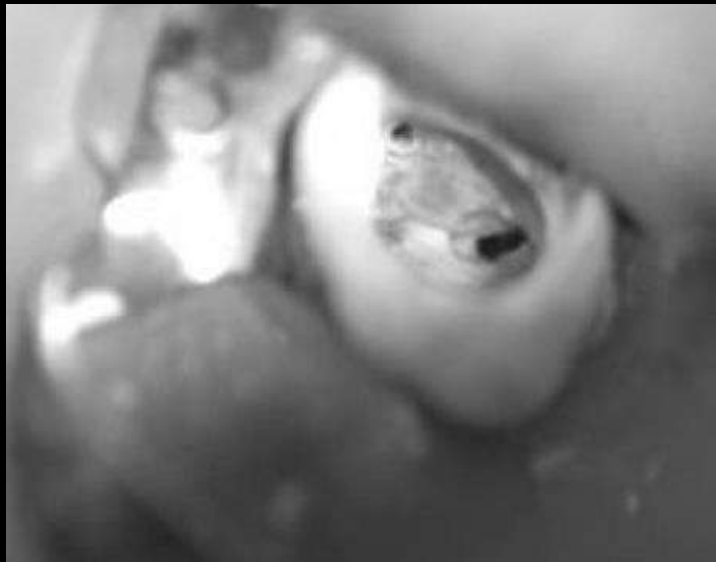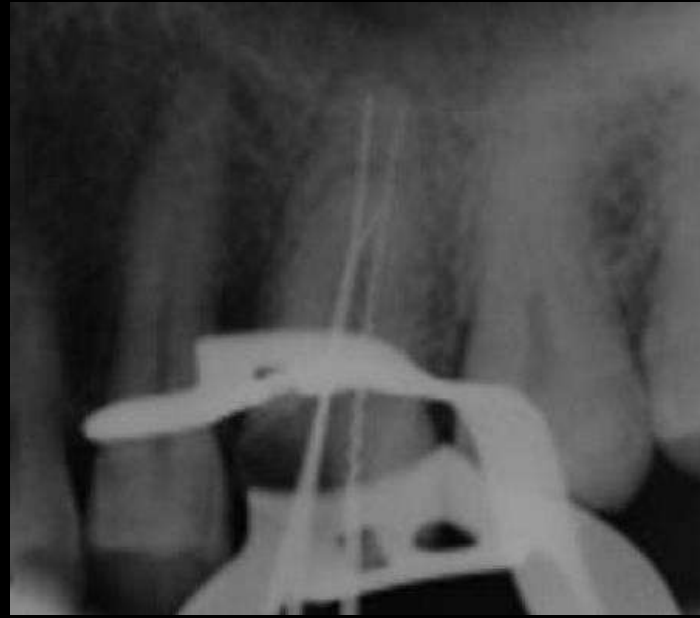
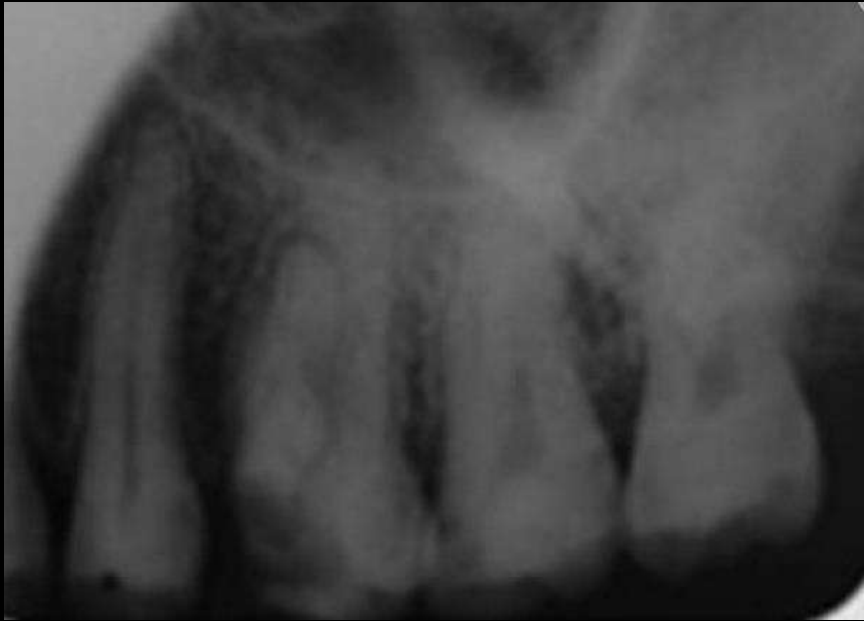TABLE 1-17 Root Number in the Maxillary First Molar

Maxillary First Molars References	No. of teeth in studies	1 Root %		2 Roots %		3 Roots %		
		%	No. of Teeth	%	No. of Teeth	%	No. of Teeth	
Total number of teeth in root studies ^{5,18,19,23,107,142,171,174,175,182,184,193}	12	2744	0.15	4	2.1	58	97.7	2682

TABLE 1-19 Main and Apical Canal Number of the Maxillary First Molar

Mesio Buccal Root of the Maxillary First Molar Number of Canals and apices References		No. of teeth in studies	1 canal		2 or more canals		1 canal at apex		2 or more canals at apex	
			%	No. of teeth	%	No. of teeth	%	No. of teeth	%	No. of teeth
Total number of canal studies (lab studies) ^{7-11,14,18,19,23,27,31,58,63,73,78,81, 106,107,122,127,132,133,139,143,148,152,157, 158,451-458}	41	5083	36.0	1828	64.0	3255				
Total number of canal apices studies (lab studies)	27	2956					60.6	1790	39.4	1166
Total number of canal studies (clinical studies) ^{12,25-28,30,64,127,170-172,174, 175,182-184,188,189,193,197,198,408, 459-461}	30	9263	43.2	3998	56.8	5265				
Total number of canal apices studies (clinical studies)	11	4883					58.7	2865	41.3	2018
Total number of canal studies (all studies)	71	14346	40.6	5826	59.4	8520				
Total number of canal apices studies (all studies)	38	7839					59.4	4655	40.6	3184
Distobuccal Root of the Maxillary First Molar Number of Canals and Apices (clinical and laboratory studies) References										
Total number of canal studies (all studies) ^{7,8,11,14,18,19,23,31,63,78,81, 107,127,171,174,175,182,184,189,193,408, 456-458,460}	26	5758	98.8	5687	1.2	71				
Total number of canal apices studies (all studies)	16	3540					98.5	3487	1.5	53
Palatal Root of the Maxillary First Molar Number of Canals and Apices (clinical and laboratory studies) References										
Total number of canal studies (all studies) ^{7,8,11,14,18,19,23,31,63,78,81,107,127, 171,174,175,182,184,189,193,408,456-460}	26	5758	99.3	5717	0.7	41				
Total number of canal apices studies (all studies)	16	3540					99.1	3507	0.9	33



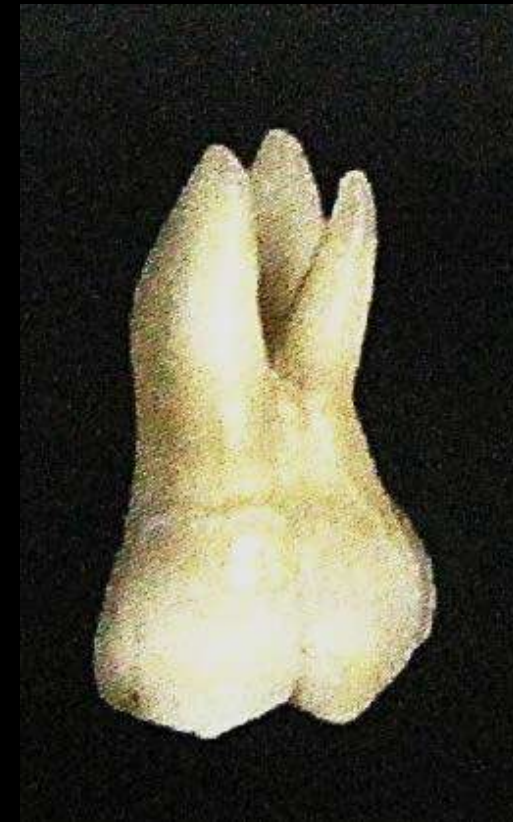

Atash biz Yeganeh, L., Adel, M., Vahedi, R., & Tofangchiha, M. (2012). *Endodontic Management of a Maxillary First Molar with Two Palatal Canals and a Single Buccal Canal: A Case Report. Case Reports in Dentistry, 2012, 1-4.*

Maxillary 2nd Molar

- Similar to maxillary 1st molar
- Roots have a distal inclination
- Normally has 3 roots
- Roots tends to close together, higher tendency towards fusion of 2/3 roots

Av. Tooth Length	17.1 mm
Av. Crown Length	7 mm
Av. Root Length	12 mm



PULP CHAMBER

- Similar to maxillary 1st molar, except narrower mesiodistally
- Roof – Rhomboidal in shape
- Floor – obtuse triangle
- Mesio Buccal and distobuccal canals closer together

Canal System

Mesio Buccal Root

- Broad buccolingually
- Prominent depression in mesial and distal surfaces
- 1 or 2 canals

Distobuccal Root

- Rounded / ovoid, single canal
- Orifice appears on same line joining mesio Buccal & palatal canals

Palatal Root

- Broad mesiodistally
- Ovoid, Single canal

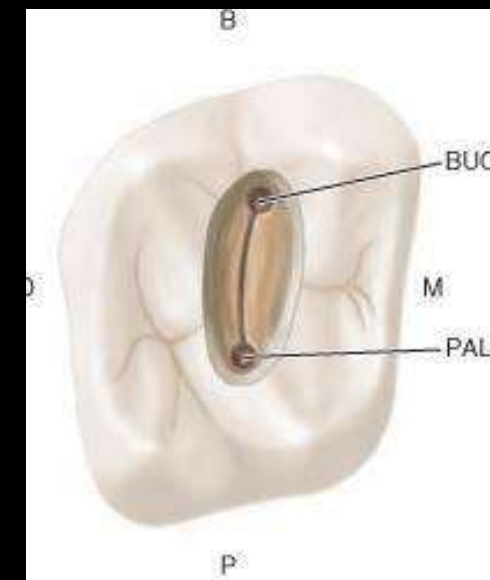
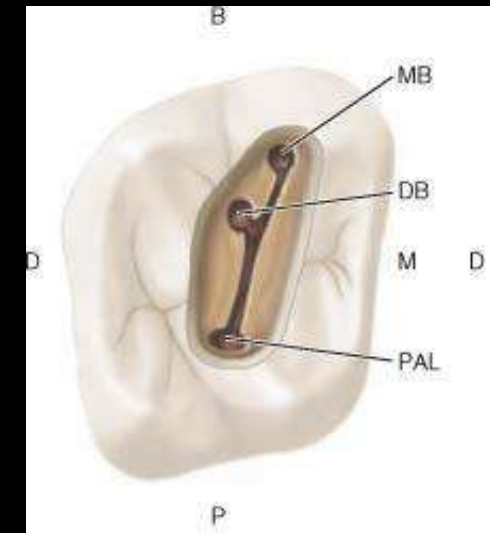


TABLE 1-21 Root Number in the Maxillary Second Molar

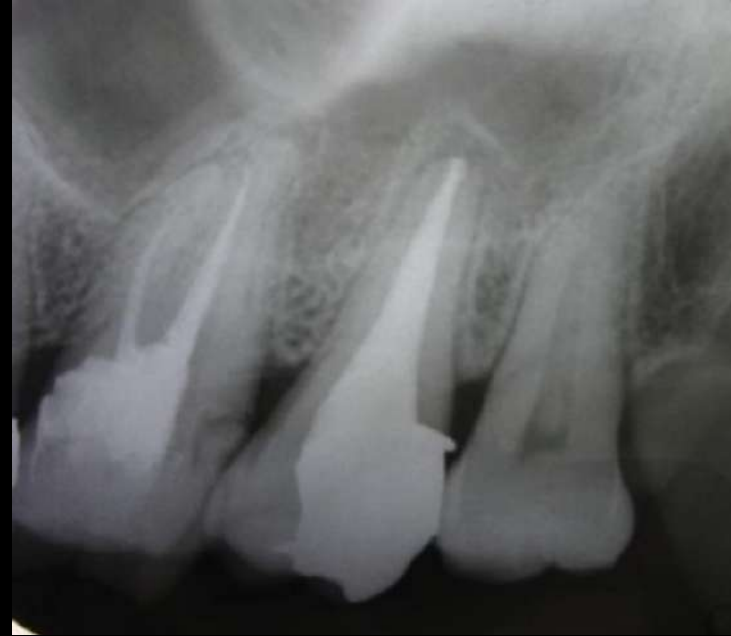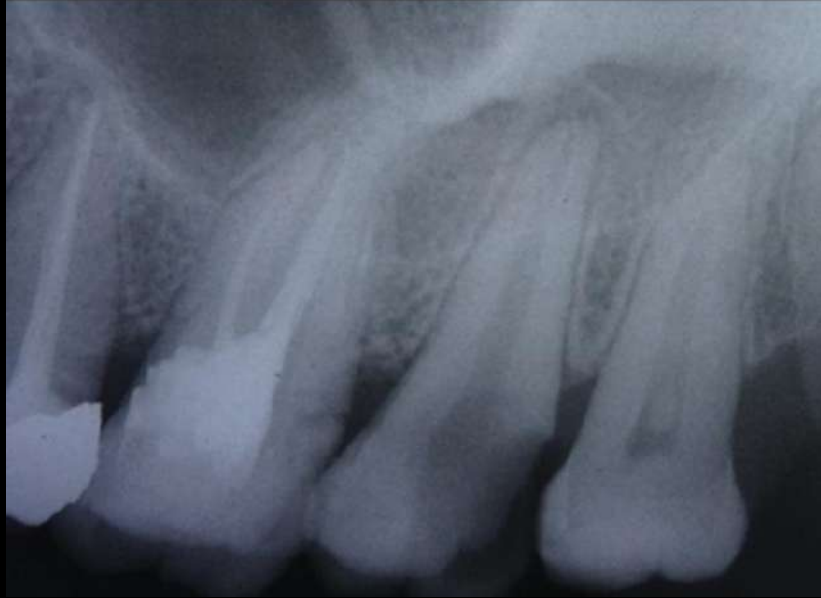Maxillary Second Molars Reference	No. of teeth in study	1 Root		2 Roots		3 Roots		4 Roots	
		%	No. of Teeth	%	No. of Teeth	%	No. of Teeth	%	No. of Teeth
Total number of teeth in root studies ^{5,18,142,175,182,184,189,547}	9 2845	4.4	124	9.0	255	85.8	2442	0.8	24

TABLE 1-22 Incidence of Fused Roots in the Maxillary Second Molar

Maxillary Second Molars References	No. of teeth in study	Total Incidence of Fused Roots	
		%	No. of Teeth
Total number of teeth in fused root studies ^{18,20-22,147,165,182,448,449}	9	26.4	647

TABLE 1-23 Main and Apical Canal Number of the Maxillary Second Molar

Mesiobuccal Root Maxillary Second Molars (3-rooted teeth) References	No. of teeth in studies	1 canal		2 or more canals		1 canal at apex		2 or more canals at apex	
		%	No. of Teeth	%	No. of Teeth	%	No. of Teeth	%	No. of Teeth
Total number of canal studies ^{7,8,11,12,14,18,26,31,63,64,74,78,132,139,175,182,183,184,189,192,408,451,453,456,460,548}	27 5016	54.8%	2748	45.2%	2268				
Total number of canal apices studies	18 2254					64.7%	1458	35.3%	796
Distobuccal Root Maxillary Second Molars (3-rooted teeth) References									
Total number of canal studies ^{7,8,11,14,18,31,63,78,175,182,184,189,408,456,460,548}	16 3085	99.6%	3074	0.36%	11				
Total number of canal apices studies	10 1200					99.75%	1197	0.25%	3
Palatal Root Maxillary Second Molars (3-rooted teeth) References									
Total number of canal studies ^{7,8,11,14,18,31,63,78,175,182,184,189,408,456,460}	15 3035	99.8	3030	0.2	5				
Total number of canal apices studies	9 1150					99.8	1148	0.2	2



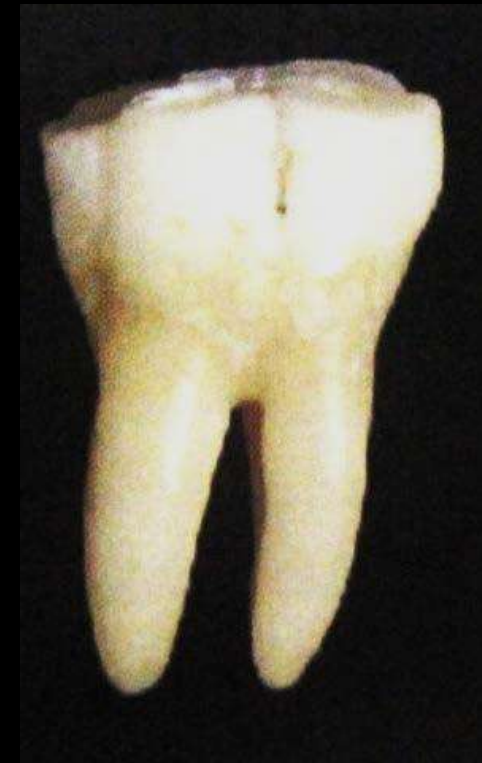Mittal N, Parashar V, Patel PS. Endodontic Management of Maxillary Second Molar Tooth with a Single Root and Single Canal. Case Rep Dent. 2020 Feb 1;2020:2829304.

Mandibular 1st Molar

- Typically 2 rooted
- Roots are broader buccolingually which are widely separated
- Mesial & distal roots separated with a furcation level
 - Buccally – 3mm
 - Lingually – 4mm
- Mesial root concavities on both mesial and distal surfaces
- Distal root – ovoid in cross section

Av. Tooth Length	21.9 mm
Av. Crown Length	7.5 mm
Av. Root Length	14 mm

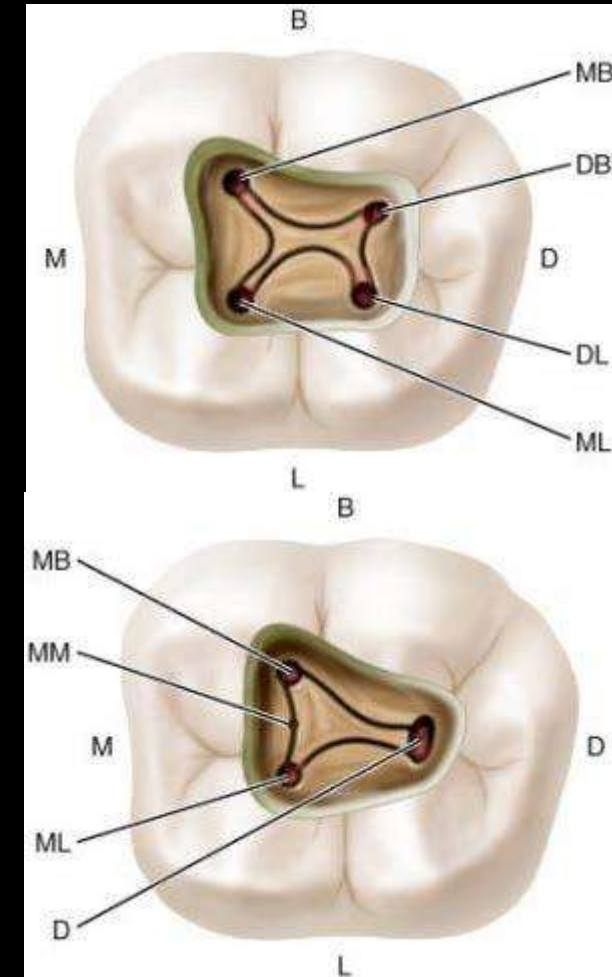
Endodontic Therapy – Franklin S. Weine (6th Edition)



Mandibular 1st Molar

PULP CHAMBER

- 4 pulp horns : MB, ML, DB, DL
- 3 distinct orifices : MB, ML & distal
- Roof – Rectangular in shape
- Walls converge to form a rhomboidal floor
- Pulp horns recede with age and so decrease in chamber size
- Roof is located on the cervical 3rd of the crown just above the cervix of tooth, floor is located on cervical third of root



Canal System

Normally 2 mesial and 1 distal canal

Mesial Root

- 2 canals exit in 2 foramina – 41%
- 2 canals exit in 1 foramina – 28%
- 2 canals form 1 canal & bifurcate & exit in 2 foramina – 13%
- 1 canal in 1 foramina – 12%
- 1 canal bifurcates & exits in 2 foramina – 8%
- Rare cases – 3 canals exit in 3 foramina (3rd canal is the middle mesial canal)

Distal Root

- 1 canal exiting in 1 foramen – 70%
- 2 canals exiting in 1 foramen – 15%
- 1 canal bifurcating & exiting in 2 foramina – 8%
- 2 canals in 2 foramina – 5%

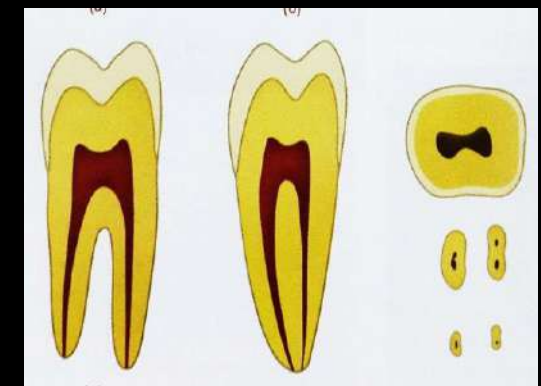
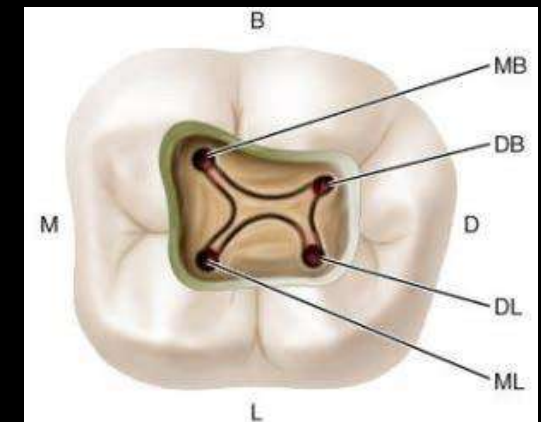
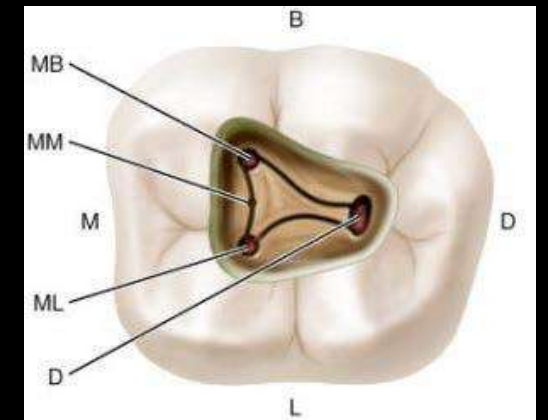
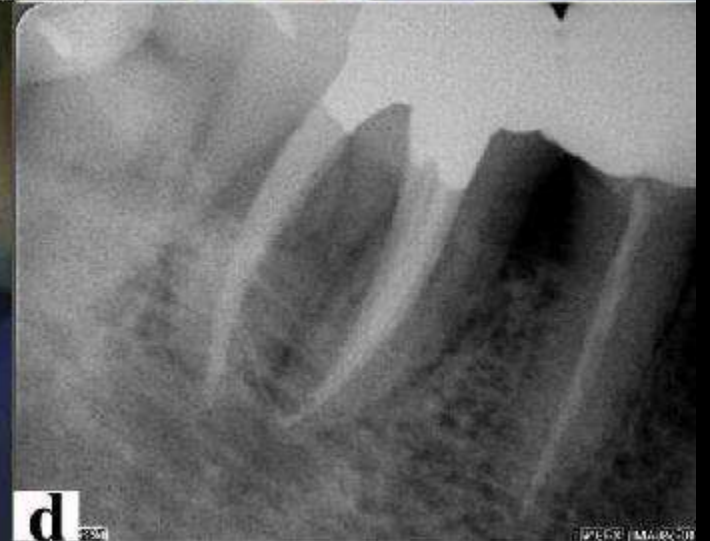
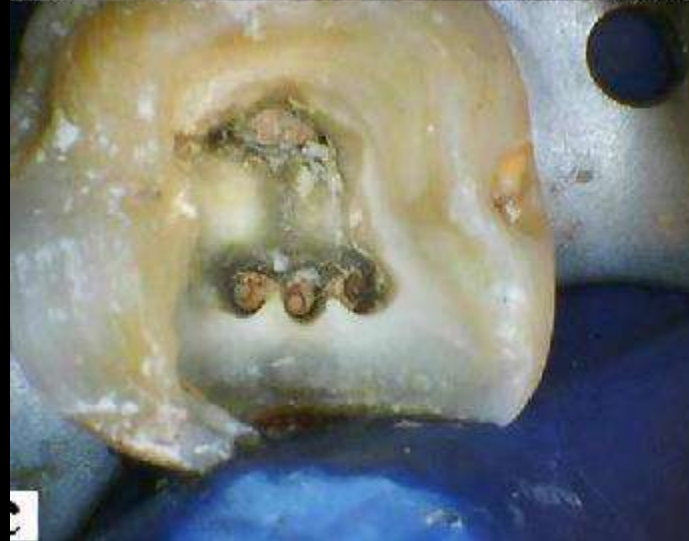
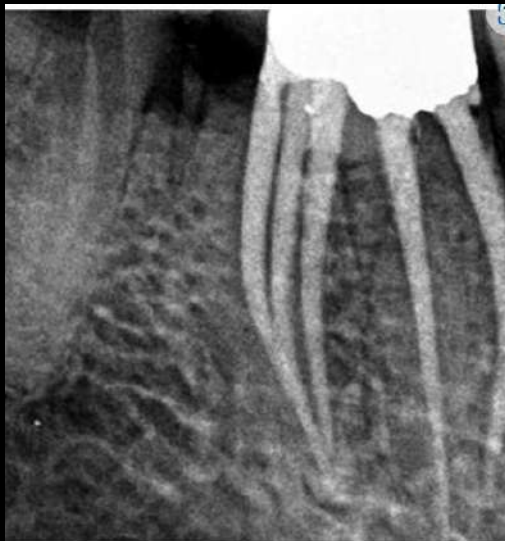
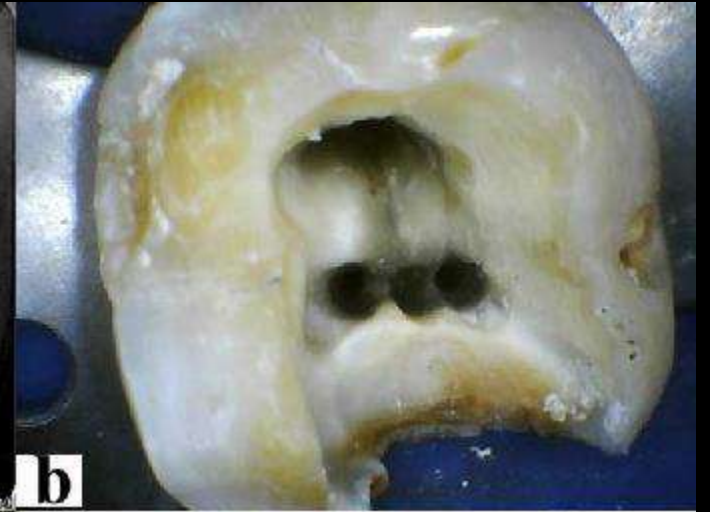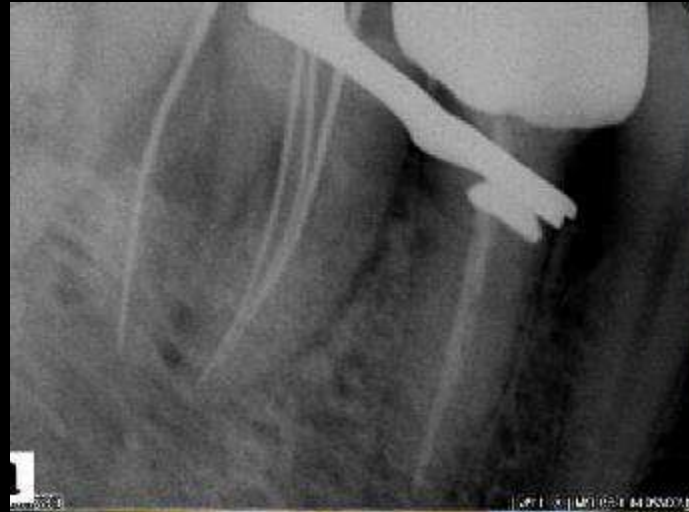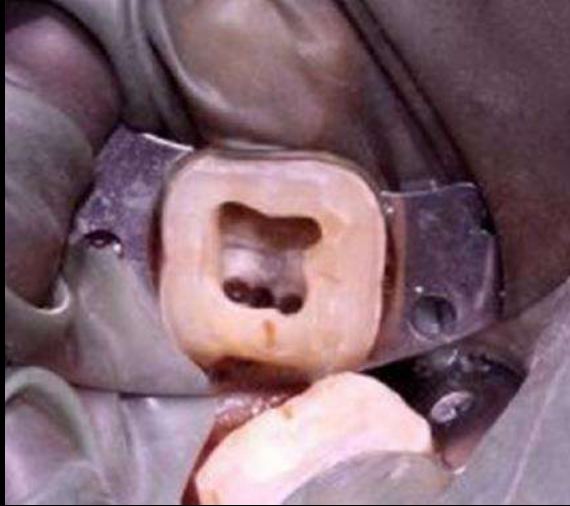TABLE 1-42 Main and Apical Canal Number of the 3-rooted Mandibular First Molar

Mesial Root References	Number of teeth in study		1 canal		2 or more canals	
			%	No. of Teeth	%	No. of Teeth
Total number of canal studies ^{91,92,110, 190,714}	5	724	2.2	16	97.8	708
Total number of canal apices studies	4	545				
Distobuccal Root References	No. of teeth in study		1 canal		2 or more canals	
			%	No. of Teeth	%	No. of Teeth
Total number of canal studies ^{91,92,110, 190,714}	5	724	98.6	714	1.4	10
Total number of canal apices studies	4	545				
Distolingual Root References	Number of teeth in study		1 canal		2 or more canals	
			%	No. of Teeth	%	No. of Teeth
Total number of canal studies ^{91,92,110,116, 190,714}	6	732	100	732	0	0
Total number of canal apices studies	5	553				

TABLE 1-41 Main and Apical Canal Number of the 2-rooted Mandibular First Molar

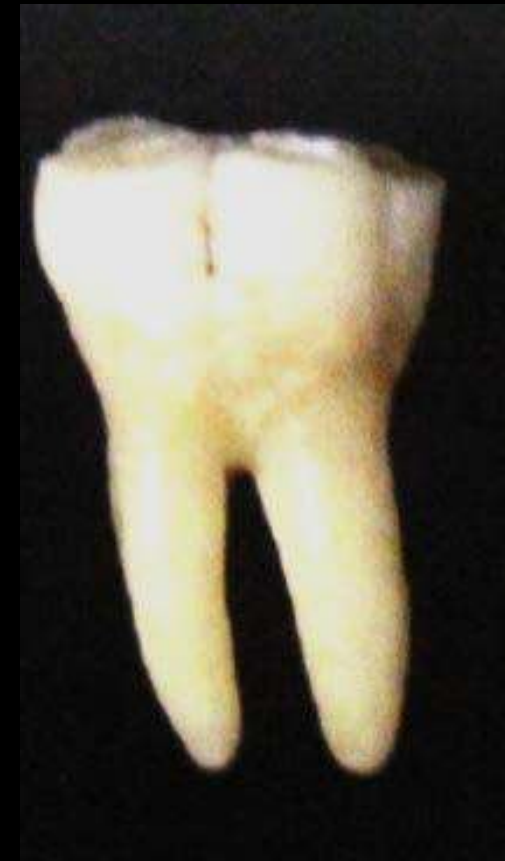Mesial Root References	No. of teeth in study		1 canal		2 canals		3 canals	
			%	No. of Teeth	%	No. of Teeth	%	No. of Teeth
Total number of canal studies ^{7- 11,14,31,81,84, 91,92,110,128, 134,144,161,166, 190,191,408,452, 460,714}	20	5824	3.2	188	95.6	5567	1.1	66
Total number of canal apices studies	15	3483						
Distal Root References	No. of teeth in study		1 canal		2 or more canals			
			%	No. of Teeth	%	No. of Teeth		
Total number of canal studies ^{7- 11,14,31,81,84,91,92, 110,128,134,144,153, 161,166,171,190, 191,408,460,714}	21	5965	69.3	4131	30.7	1834		
Total number of canal apices studies	16	3657						



Mandibular 2nd Molar

- 2 rooted
- Mesial & distal roots close together
- Roots are broader buccolingually
- More frequently roots are fused

Av. Tooth Length	21.4 mm
Av. Crown Length	7 mm
Av. Root Length	13.5 mm



PULP CHAMBER

- Similar to 1st molar but smaller in size

Canal System

- Mesial root – higher incidence of 1 canal – 14%
- Higher incidence of root fusion
- C-shaped canals are frequent
- In a mandibular second molar with two canals, both orifices are in the mesiodistal midline.
- If two orifices are not directly in the mesiodistal midline, a search should be made for another canal on the opposite side using Krasner and Rankow's laws of anatomy

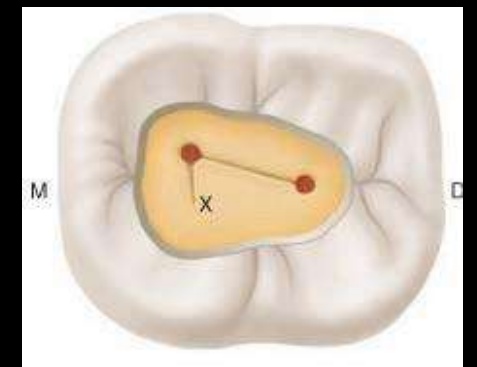
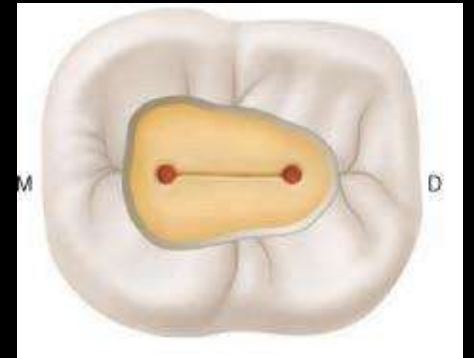
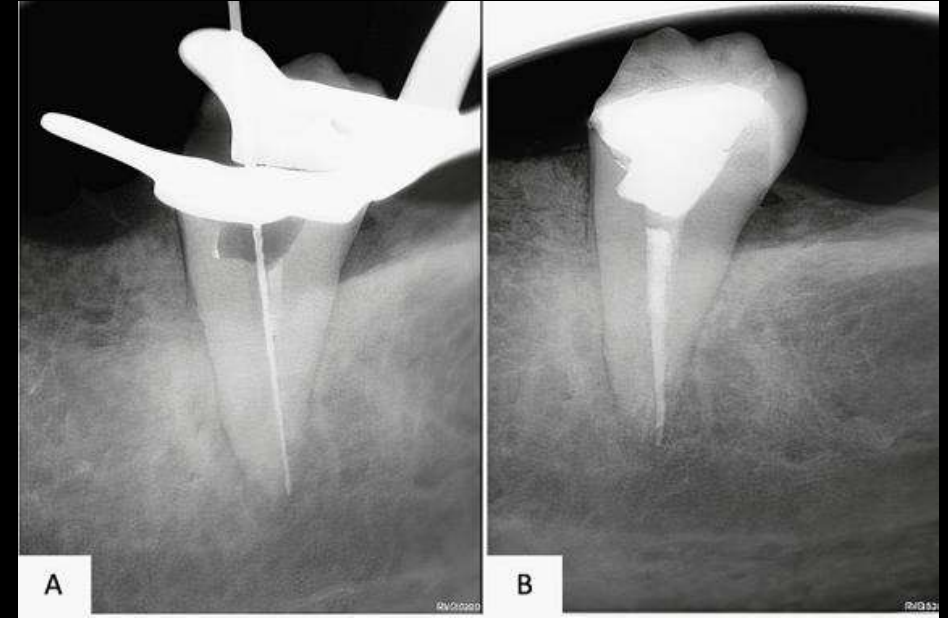
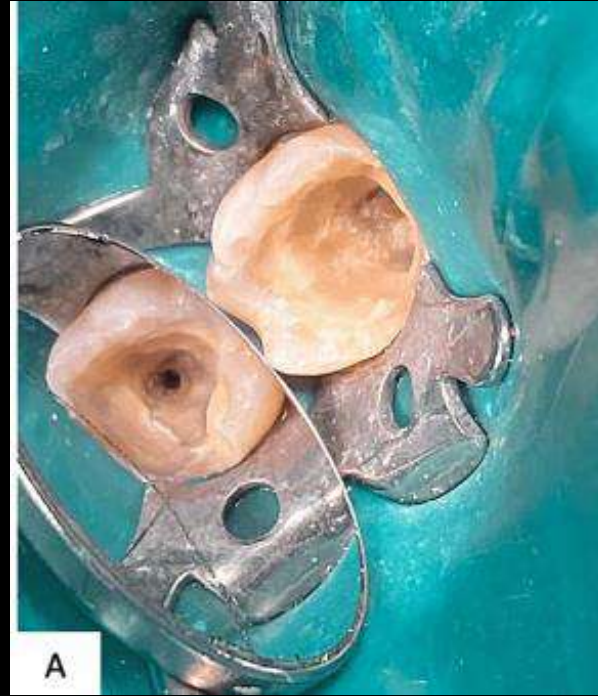
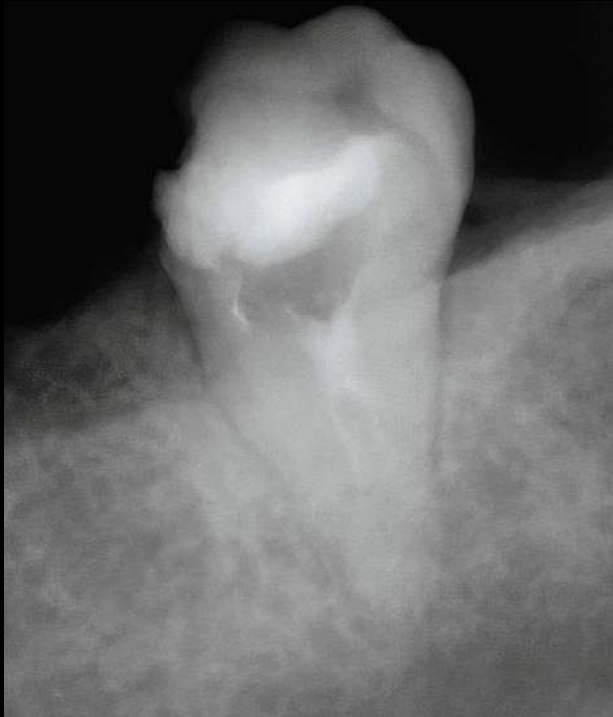
TABLE 1-44 Root Number in the Mandibular Second Molar														
References	No. of teeth in study		1-Fused Roots				2 Roots		3 Roots		4 Roots			
			Total Fused Roots		1 Root (conical)		1 Root (C-shaped)							
			%	No. of Teeth	%	No. of Teeth	%	No. of Teeth	%	No. of Teeth	%	No. of Teeth		
Total number of teeth in studies ⁵ : 36,67,79,84,91,92, 101,104,110,111,118, 119,176,181,408,712, 770,771	19	6210	31.3	1946	1.2	74	2.5	157	67.3	4181	1.3	83	0.0	0

TABLE 1-45 Main and Apical Canal Number of the 2-rooted Mandibular Second Molar										
Mesial Root References	No. of teeth in study		1 canal		2 or more canals		1 canal at apex		2 or more canals at apex	
			%	No. of Teeth	%	No. of Teeth	%	No. of Teeth	%	No. of Teeth
			Total number of canal studies ^{7,11,14, 84,91,9 2,104,110,181,408,460,772}	12	2061	18.1	374	81.9	1687	
Total number of canal apices studies	9	1160					58.0	673	42.0	487
Distal Root References	No. of teeth in study		1 canal		2 or more canals		1 canal at apex		2 or more canals at apex	
			%	No. of Teeth	%	No. of Teeth	%	No. of Teeth	%	No. of Teeth
			Total number of canal studies ^{7,11,14,84,91,92,104,110,181,408,460,771}	12	2061	84.6	1743	15.4	318	
Total number of canal apices studies	9	1160					93.7	1087	6.3	73



Developmental Disturbances OF Teeth

Concrescence

- A cemental fusion of roots of at least two teeth(0.8%)
- Post-inflammatory concrescence:

A carious lesion on the surface of the tooth



Decay extending to the roots of the tooth



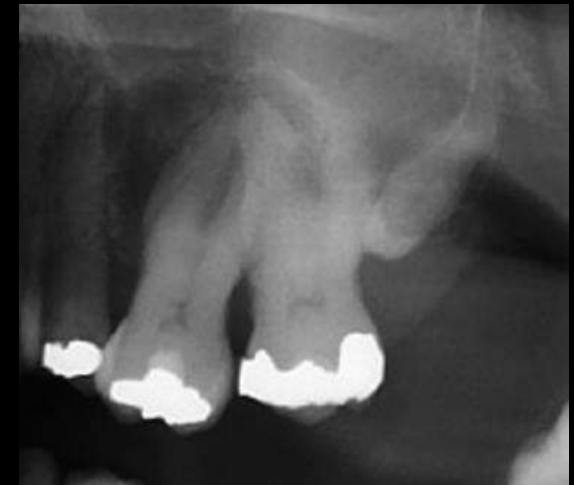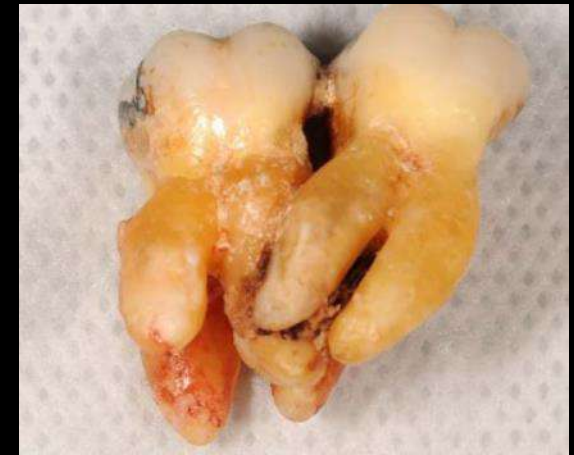Increased pressure in the radicular (pertaining to the roots) region



Bone resorption and excess deposition of cementum



Two adjacent teeth fuse with each other



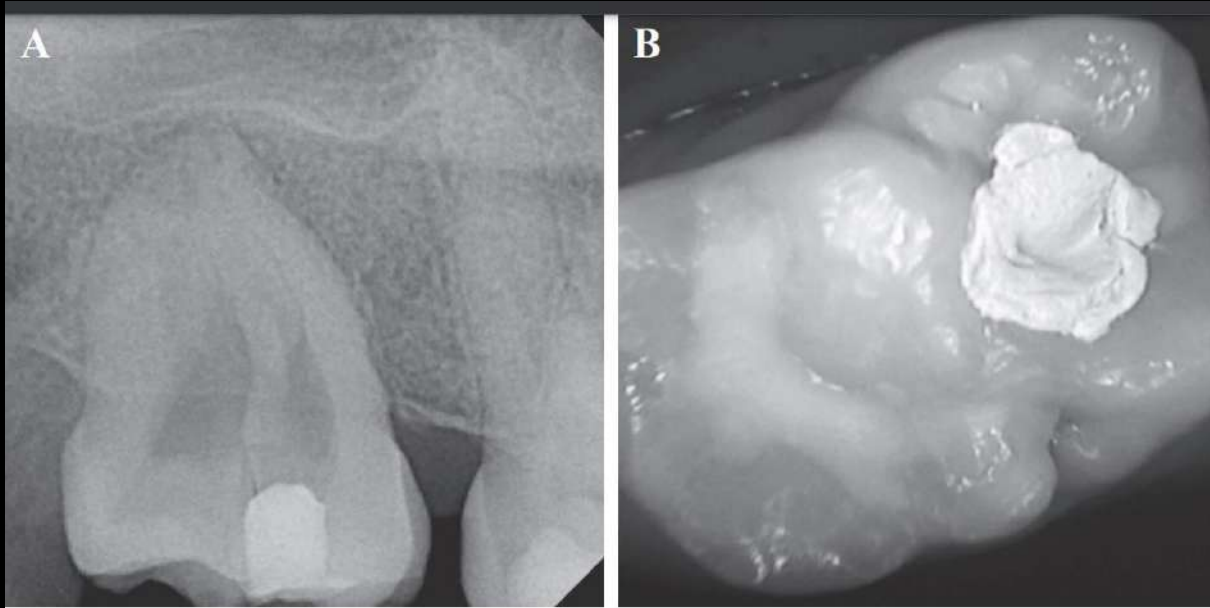


Fig. 1 Preoperative. A. Radiograph of teeth #18 and #17, B. Intraoral occlusal view of teeth #18 (Composite resin filling) and #17 (IRM restoration).

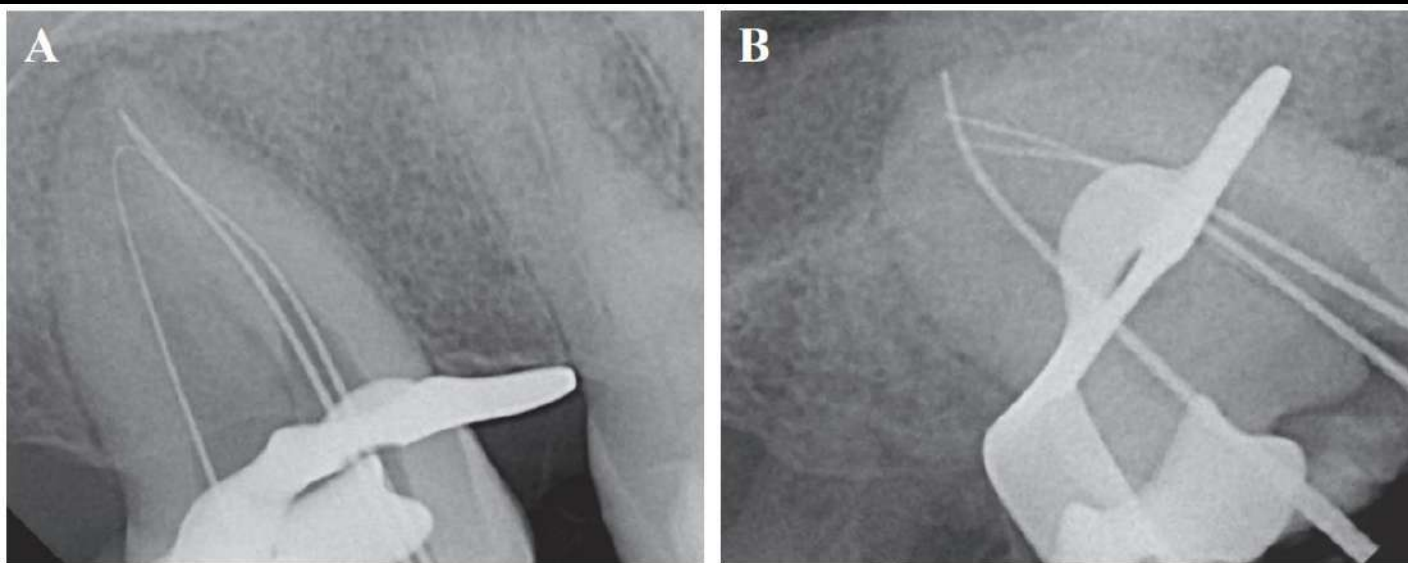
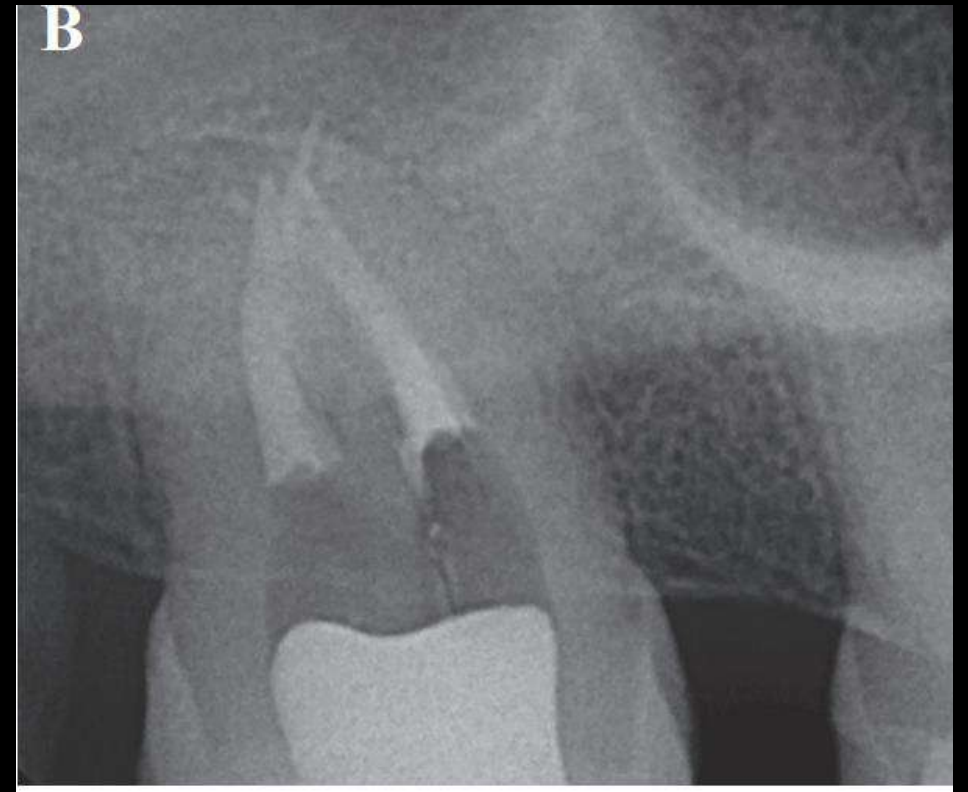
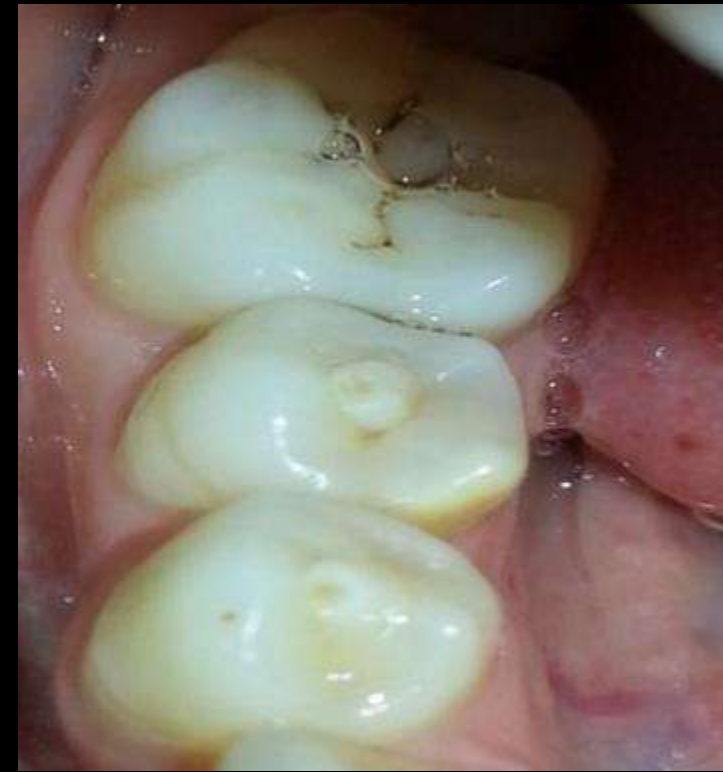

Fig. 2 Measurement films. A. Straight on, B. Mesial shift angulation.

Foran, D., Komabayashi, T., & Lin, L. M. (2012). Concrescence of permanent maxillary second and third molars: case report of non-surgical root canal treatment. *Journal of Oral Science*, 54(1), 133-136.

Dens Evaginatus (DE)

- Presence of an accessory cusp
- Composed of enamel and dentine, usually containing pulp tissue
- Fracture or wear of the tubercle
- Frequently lead to the major complication of pulp necrosis and periapical infection



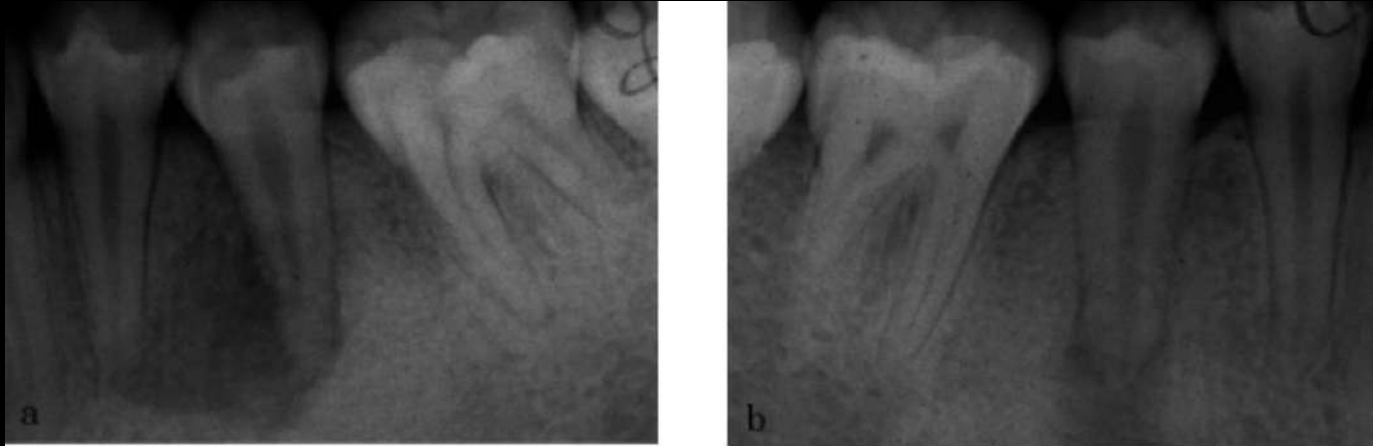
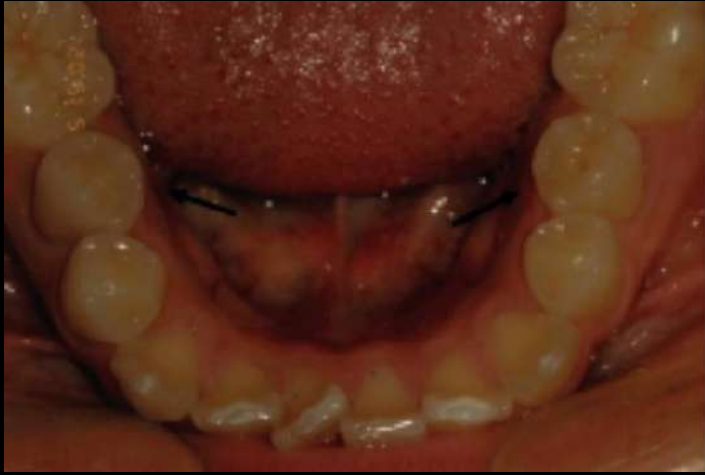
Fig. 3 Preoperative radiographs of the left (a) and right (b) premolars showing dens evaginatus with periapical radiolucency.

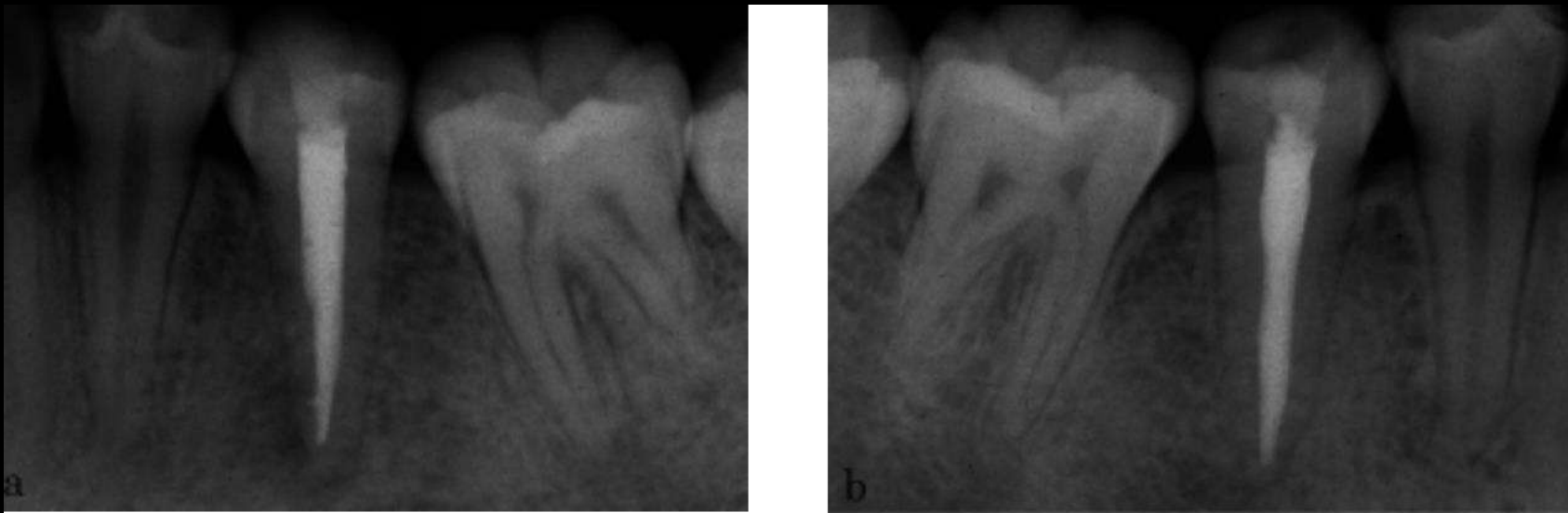
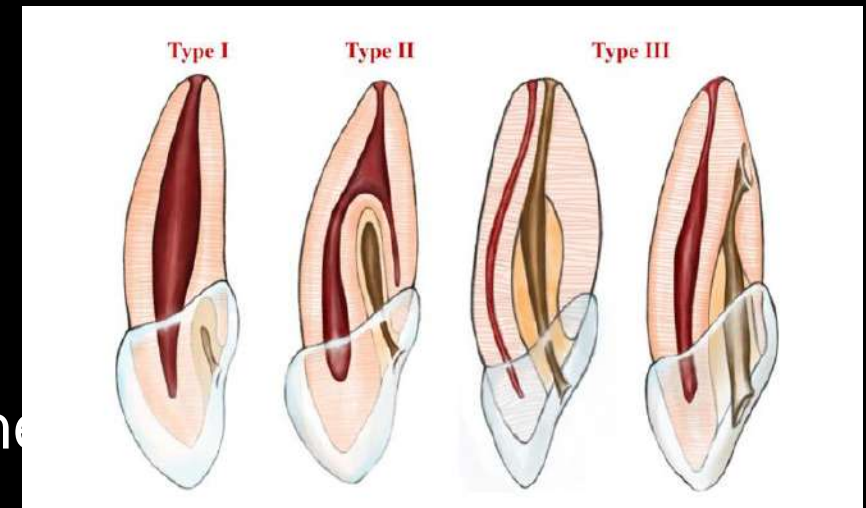
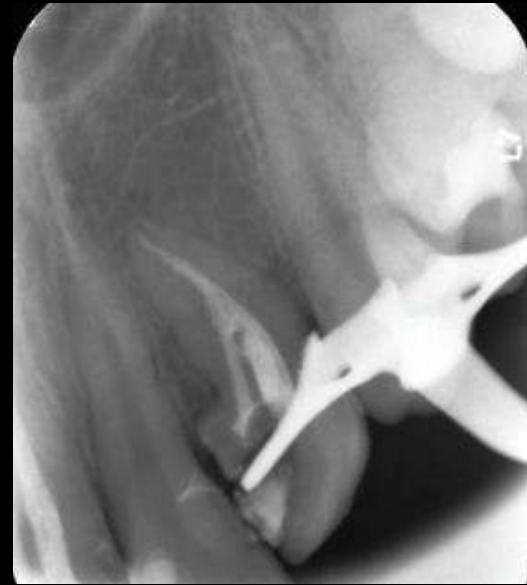
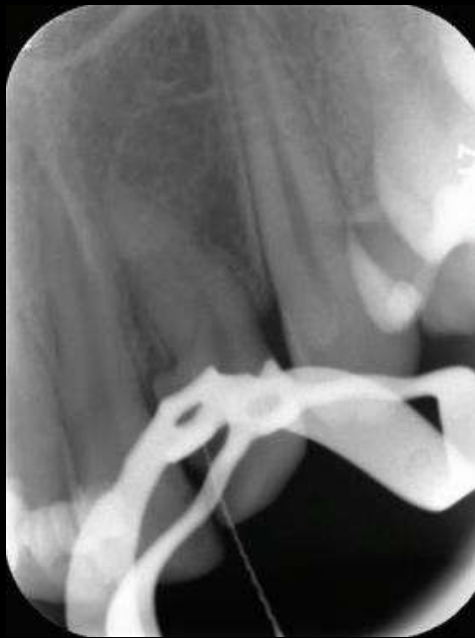
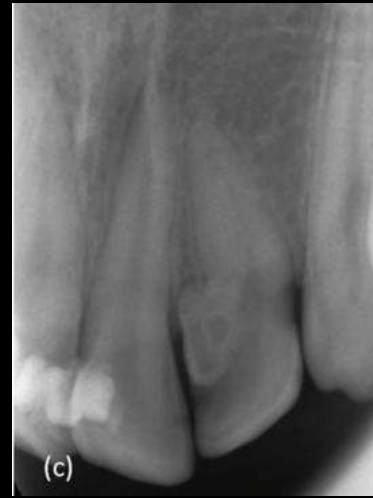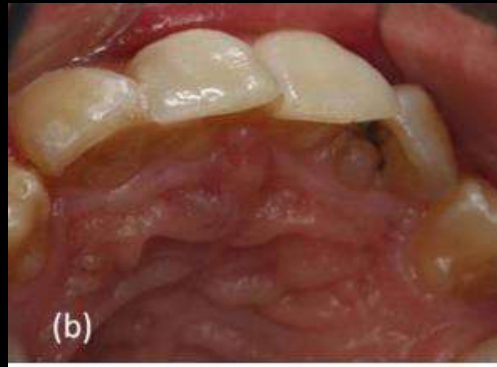Fig. 6 Radiographs immediately after gutta-percha obturation of the left (a) and right (b) premolars.

Dens Invaginatus

- Developmental anomaly that results in an enamel-lined cavity intruding into the crown or root before the mineralization phase
- Typically affects permanent maxillary lateral incisors, central incisors, and premolars





Helvacioğlu-Yigit, D., & Aydemir, S. (2012). Endodontic Treatment of Type II Dens Invaginatus in a Maxillary Lateral Incisor: A Case Report. *Case Reports in Dentistry*, 2012, 1–4.

Gemination

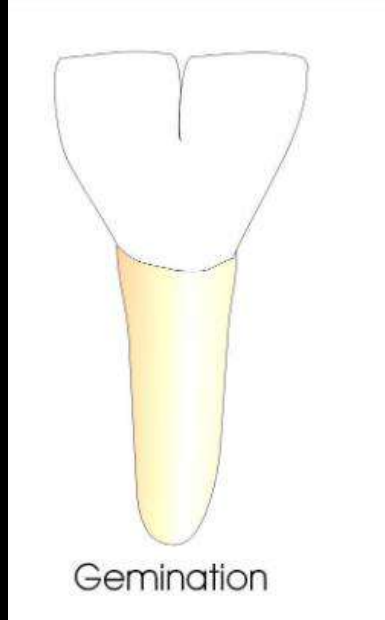
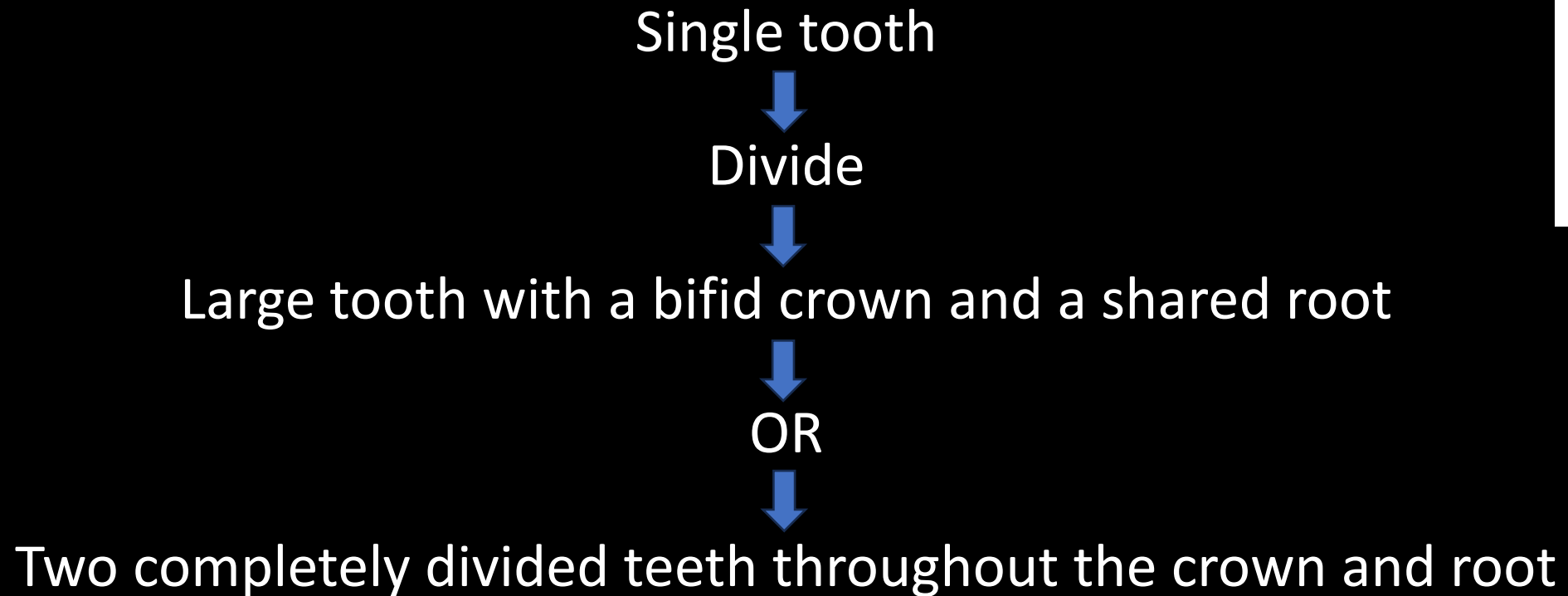
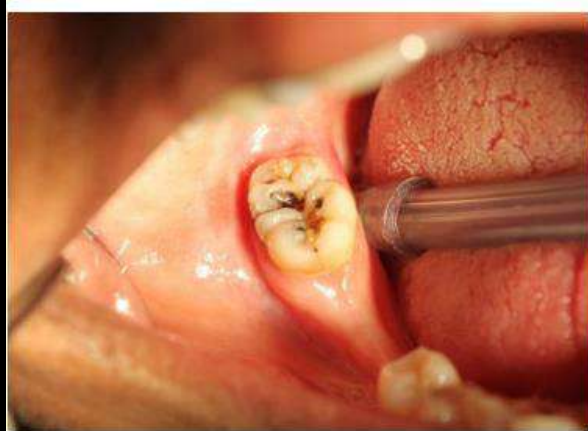



Fig 1: Pre operative photograph.

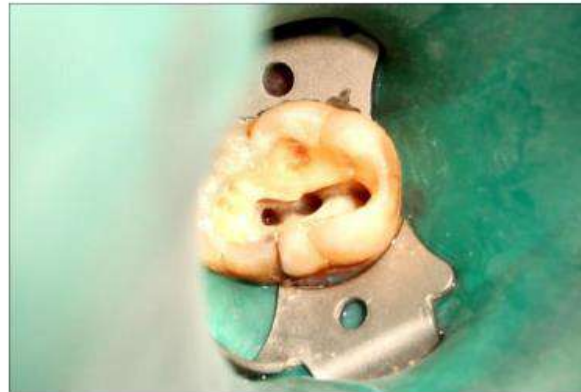

Fig 4: Access opening.

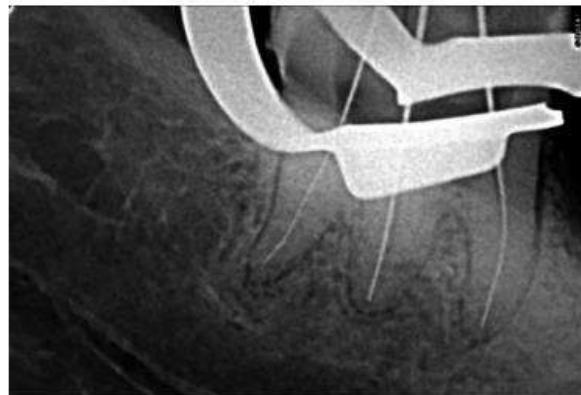
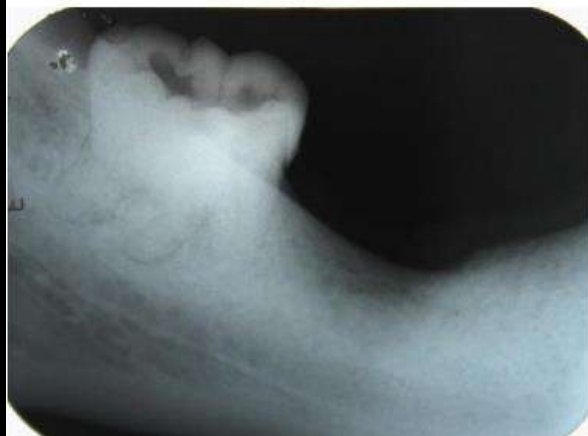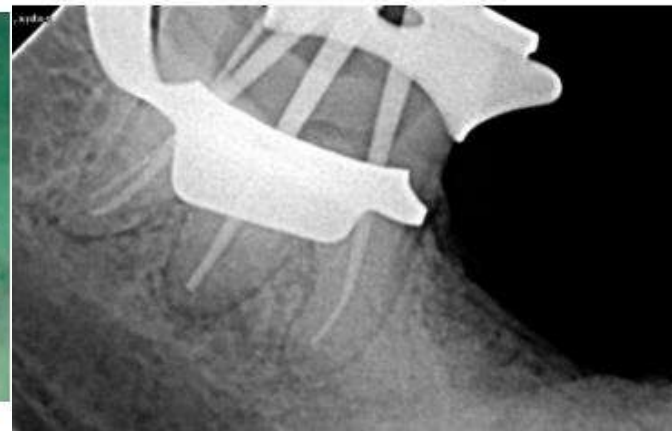

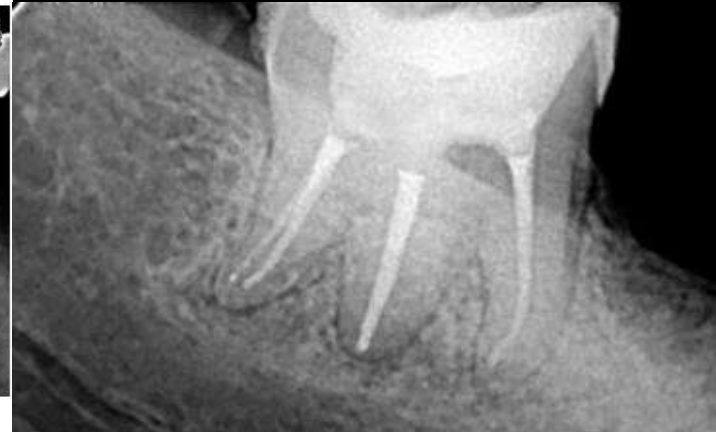

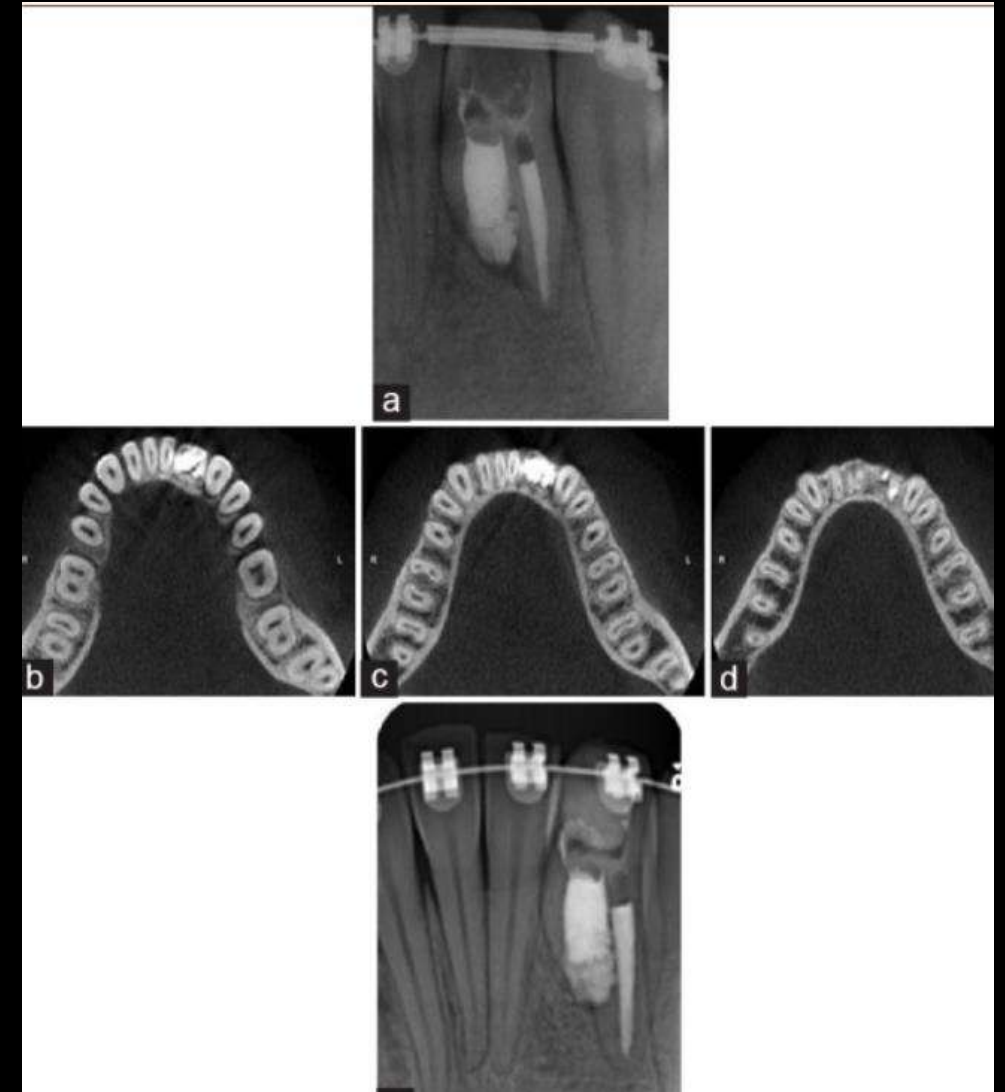
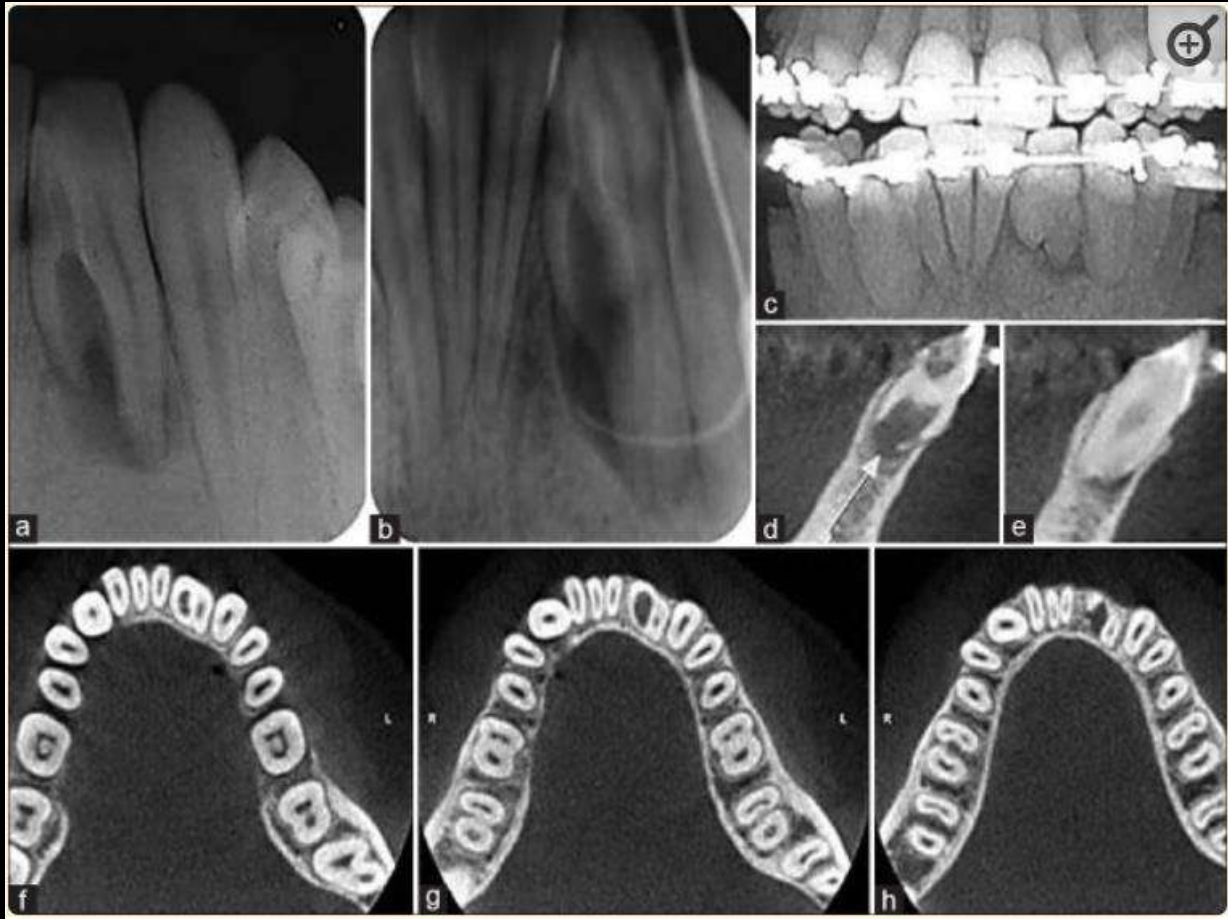
Fig 5: Working length determination.



Fusion

- Union of two dental germs during the developmental stage
- Results from an aberration of both the ectoderm and the mesoderm
- Crowns are fused by the enamel and/or by the dentin
- May show two roots or two root canals in a single root

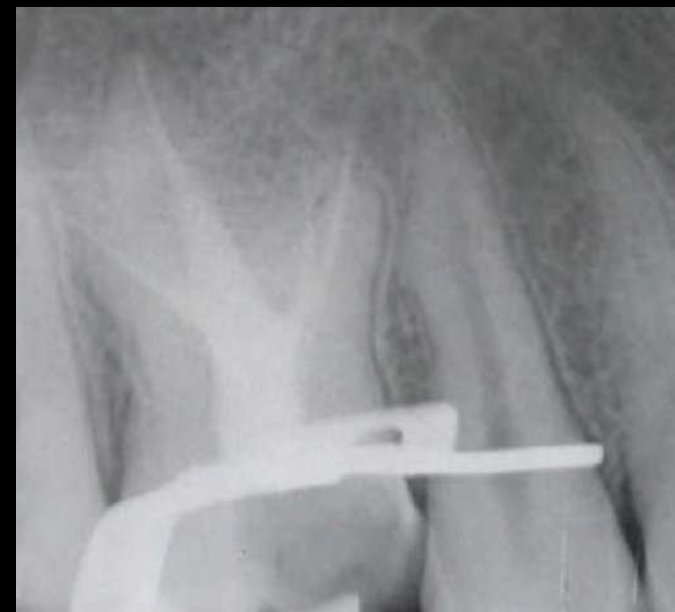
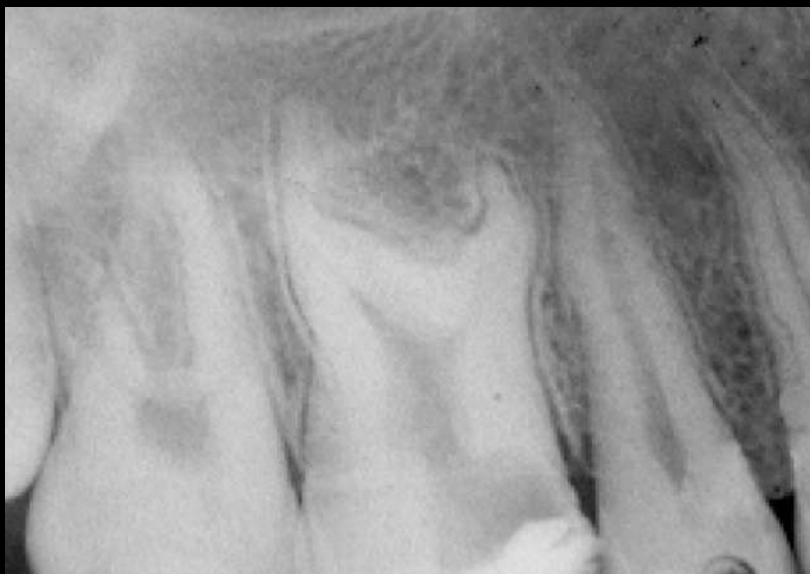


Dorielo MCO, Gonini-Junior A, de Oliveira D, Bordignon RT, Borges AH. Root canal treatment of a fused mandibular incisor using cone-beam computed tomography as a diagnostic aid. *J Conserv Dent.* 2017 Jan-Feb;20(1):58-61.

Taurodontism

- (Bull-like tooth) is a rare morphologic variation which causes the occluso-apical elongation of the chamber, and the reduction of the root size.
- This variation is thought to be caused by the failure of Hertwig's epithelial sheath diaphragm in invagination at the proper horizontal level, resulting in a tooth with short roots, an elongated body, an enlarged pulp chamber, and a normal dentin



Conclusion

- The root apex is morphologically the most complex region, therapeutically a challenging zone and prognostically an important part but unfortunately most obscure and unclear radiographically.
- So endodontist should have detailed knowledge of the anatomic variations and mechanical challenges involved in treatment of apical third of root for effective and efficient management during endodontic therapy

References

- Text book of Endodontics-Ingles(6th edition)
- Grossman's Endodontic Practice (12th Edition)
- Endodontic Therapy – Franklin S. Weine (6th Edition)
- Pathways of pulp –Cohen(11th Edition)
- ElAyouti, A., Hülber-J, M., Judenhofer, M. S., Connert, T., Mannheim, J. G., Löst, C., ... von Ohle, C. (2014). *Apical Constriction: Location and Dimensions in Molars—A Micro-Computed Tomography Study. Journal of Endodontics, 40(8), 1095–1099.*
- Patel S, Rhodes J. A practical guide to endodontic access cavity preparation in molar teeth. *Br Dent J* 2007;203:133–40.

- Nazari S, Mirmotalebi F. Endodontic treatment of a taurodontism tooth: report of a case. Iran Endod J. 2006 Fall;1(3):114-6. Epub 2006 Oct 1.
- Doriello MCO, Gonini-Junior A, de Oliveira D, Bordignon RT, Borges AH. Root canal treatment of a fused mandibular incisor using cone-beam computed tomography as a diagnostic aid. J Conserv Dent. 2017 Jan-Feb;20(1):58-61.
- Singh, Harpreet. (2016). Case Report Endodontic Management of a Geminated Tooth: A Clinical Challenge. 3-8.
- Ahmed, HMA, Dummer, PMH. A new system for classifying tooth, root and canal anomalies. International Endodontic Journal, 51, 389–404, 2018.

THANK YOU