

Joints

- Fibrous joints...5
- Sutures....5
- Synovial joints....5

Definition

- Articulation between 2 or more bones/cartilages
- May or may not be mobile

Classification

Structural
and
Functional

Structural Classification (based on the structural tissue between the bones)

Joints are structurally classified into 3 types:

1. **Fibrous**- which are immovable joints and are for the function of growth.
2. **Cartilaginous** joints- which are of 2 types:
 - Primary cartilaginous (synchondrosis)- immovable-function –growth
 - Secondary cartilaginous(symphysis)-slightly movable joints
3. **Synovial**-freely movable

Functional classification-SAD

- Immovable joints-synarthrosis
- Slightly movable-amphiarthrosis
- Freely movable-diarthrosis

Fibrous joints...(5 marker)

- Definition of joints
- Classification of joints

Fibrous joints (contd)

- Fibrous joints are joints where the bones are united by fibrous tissue
- They are immovable joints (Synarthrosis)
- Basic function of these joints is for growth

Fibrous joints (contd)

Types of fibrous joints:

1. Sutures
2. Gomphosis (peg in a socket)
3. Synostoses

Note: sutures and gomphosis are only found in the head and neck region

Fibrous joints (contd)

Sutures

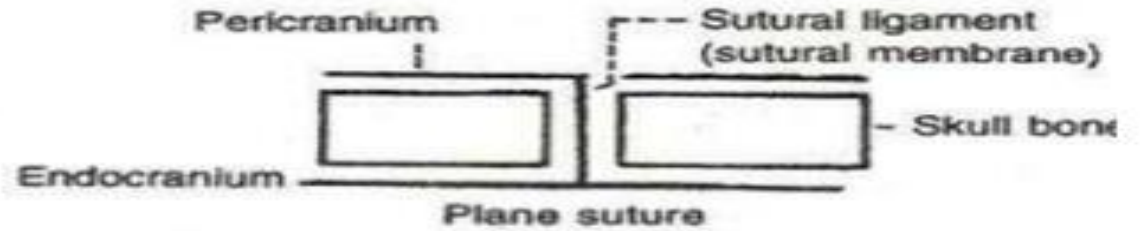
- These are fibrous joints
- Exclusively found in the skull
- Allow growth of the skull (providing space for the growing brain)
- Are obliterated by 30-40 years of age
- Early obliteration leads to cranio stenosis and mental retardation

Fibrous joints (contd)

Types of sutures:

1. **Serrate**....eg saggittal suture
2. **Dentate**....eg coronal suture
3. **Squamous**....eg temporo parietal suture
4. **Plane**....eg palatine suture
5. **Schindylesis** (wedge in a groove)....eg ala of the vomer with the sphenoidal rostrum


TYPES OF SUTURES



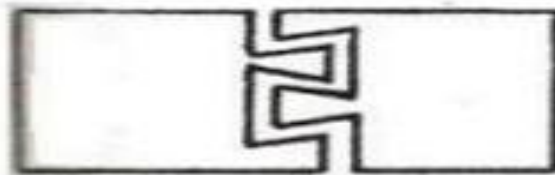(median palatine suture)



(sagittal suture)

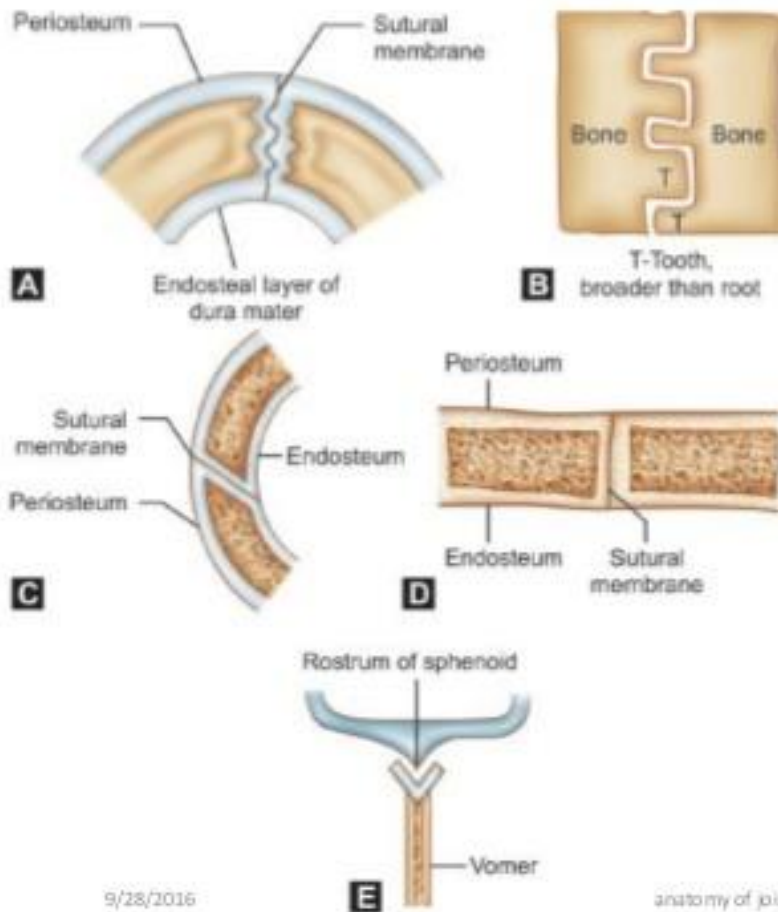


(between temporal & parietal bone)



(lambdoid suture)





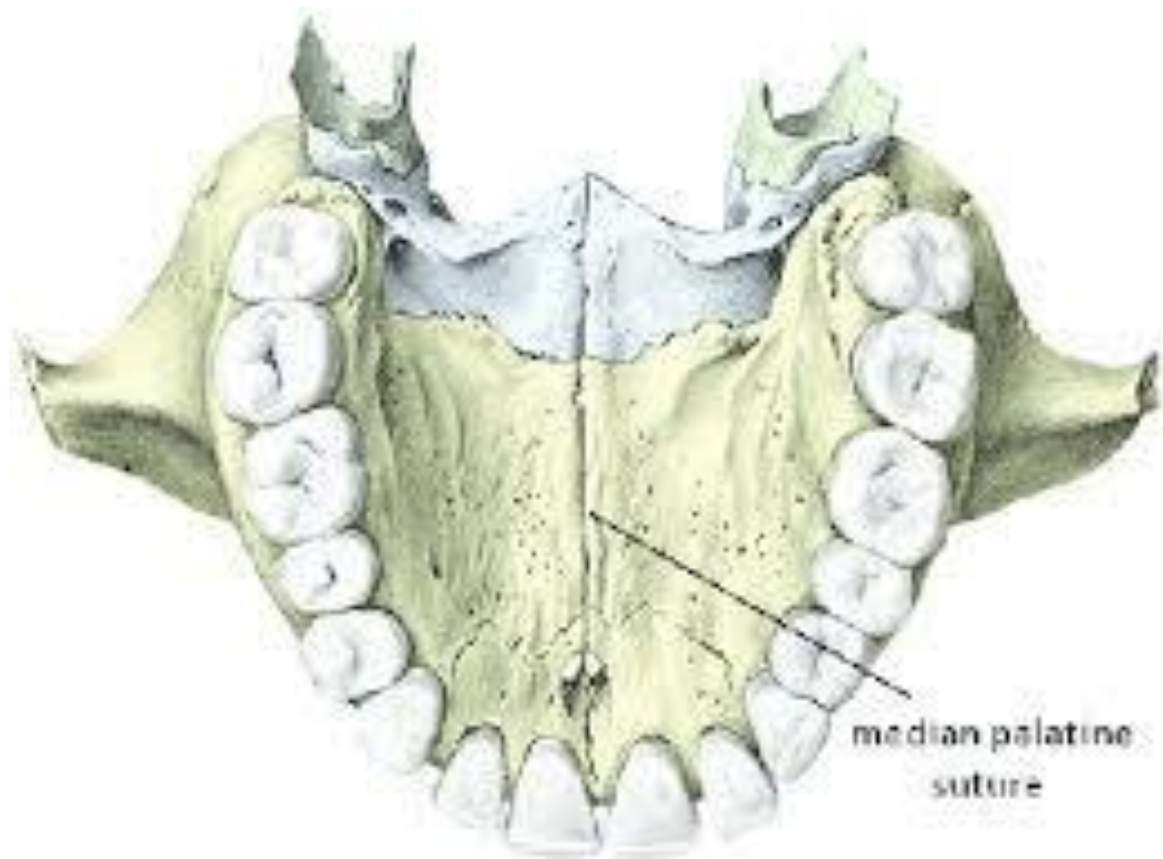
Types of sutural joint

- A. Serrate suture
- B. Denticulate suture
- C. Squamous suture
- D. Plane suture
- E. Schindylesis

Rostrum of sphenoid

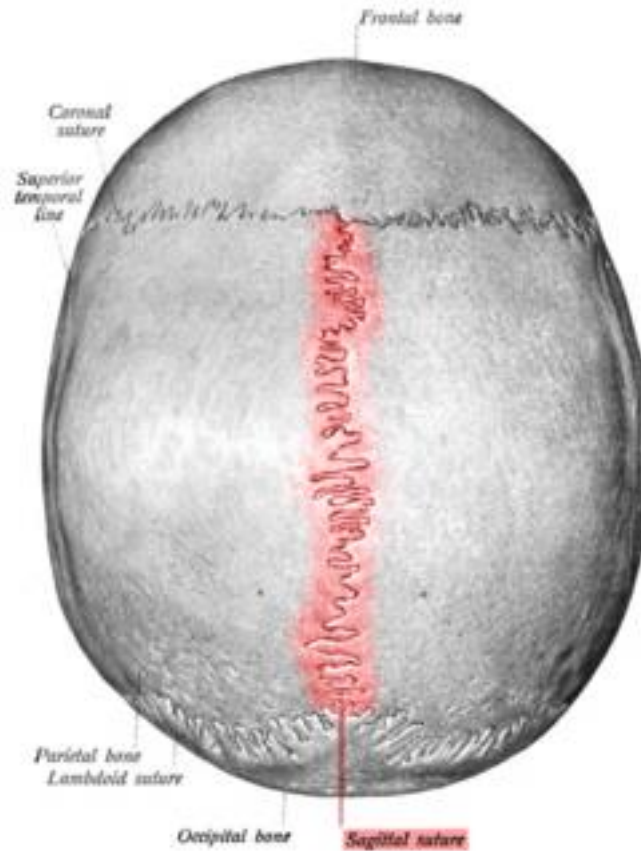


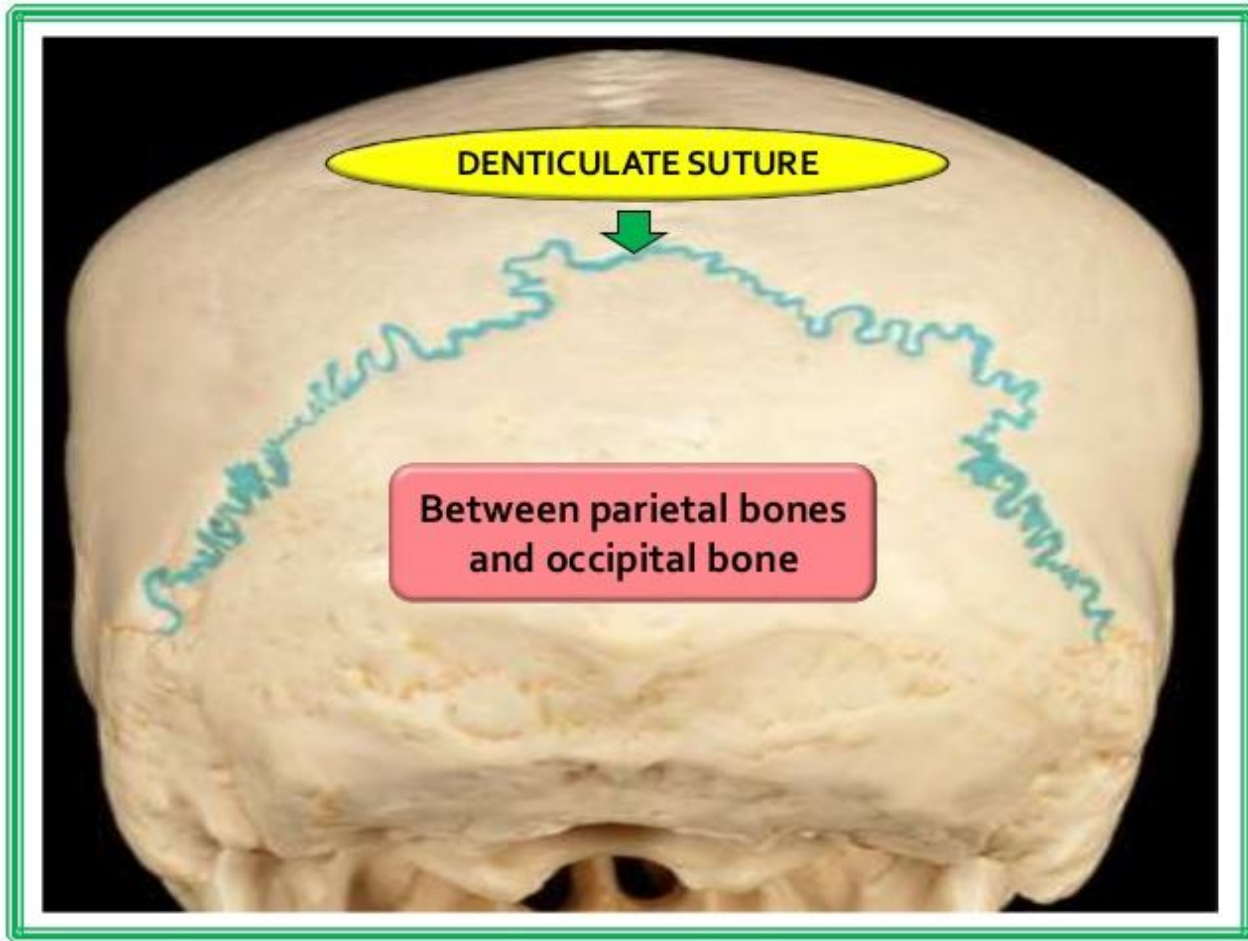
Vomer

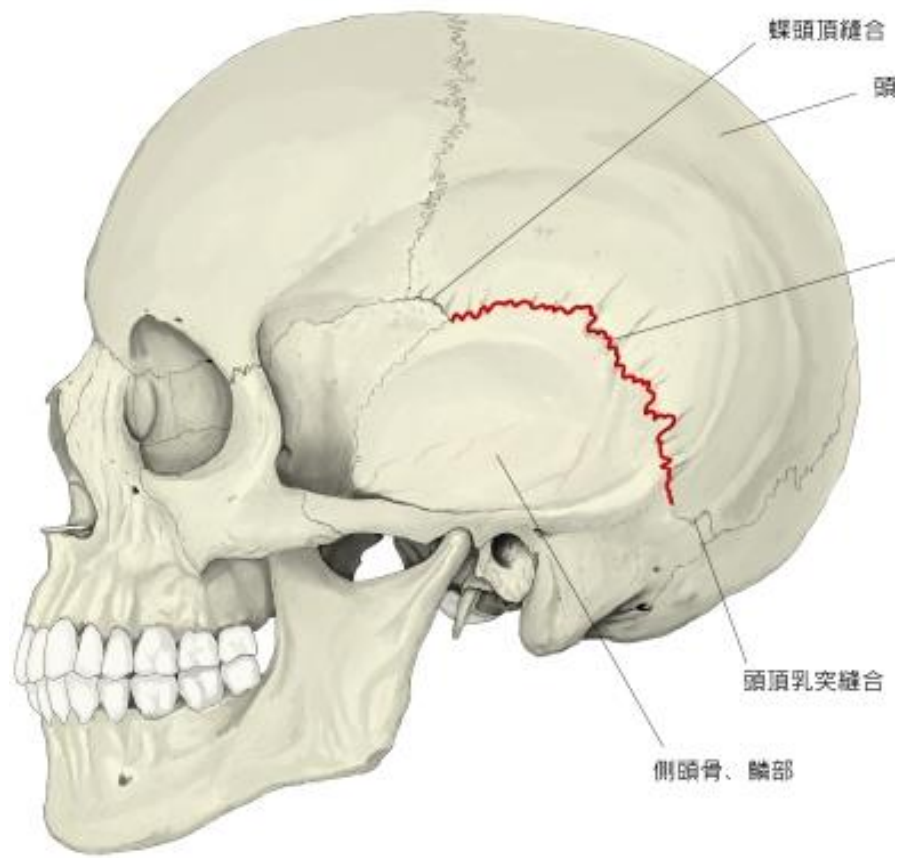


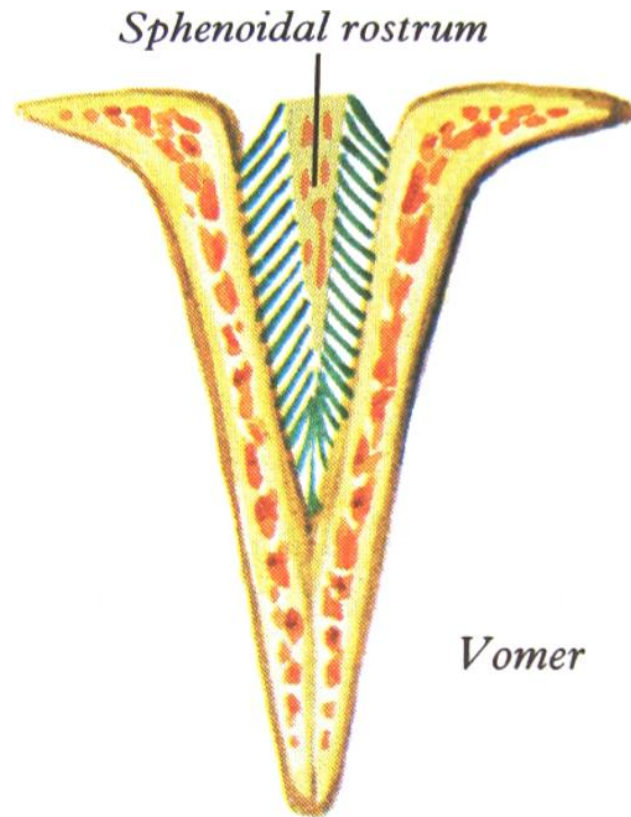
median palatine
suture

Fibrous joints (contd)

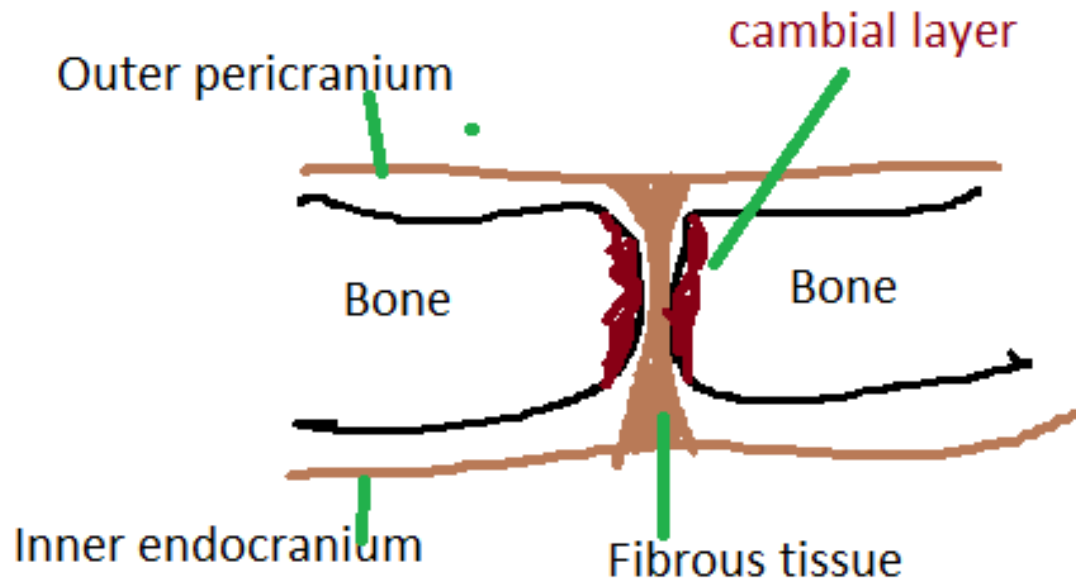




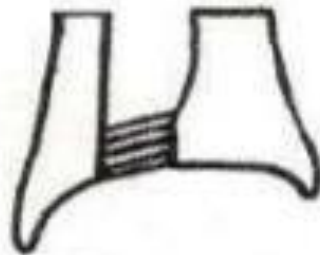




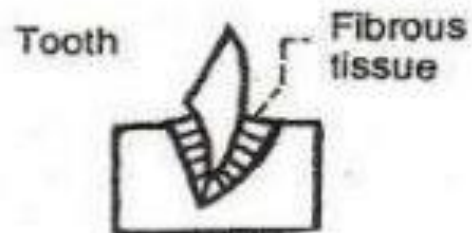
Structure of a sutural joint



Other fibrous joints



Tibiofibular syndesmosis



Gomphosis
(peg and socket joint)

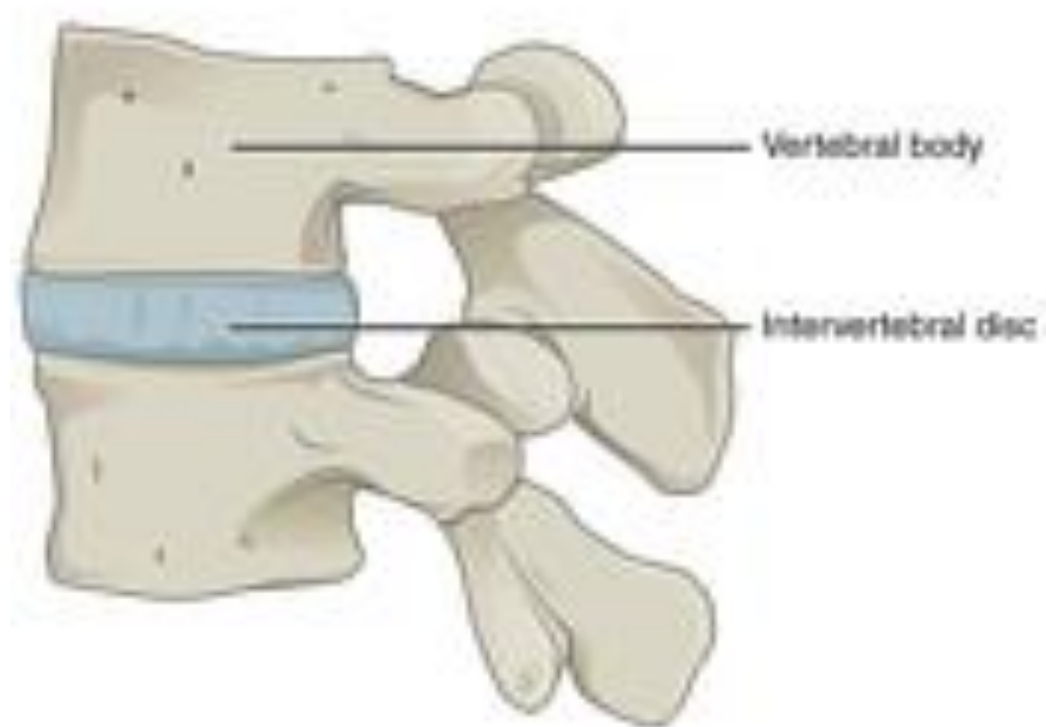
Differences between

Primary cartilaginous joint (synchondrosis)

- Temporary (disappear at around 20-25 years of age)
- Function-growth
- Site-Usually away from the midline , eg epiphyseal growth cartilages
- Structure-Bones are united by a thin plate of hyaline cartilage

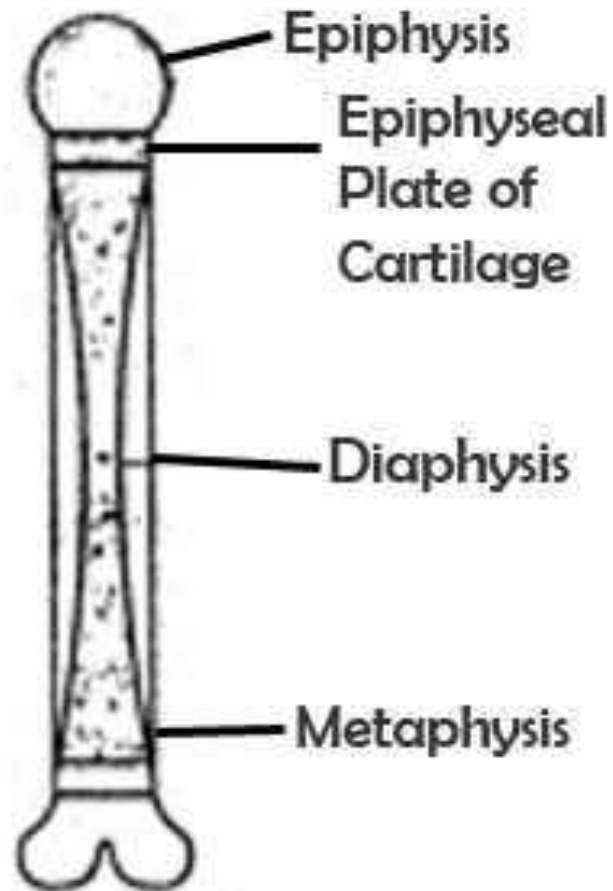
Secondary cartilaginous joint (symphyses)

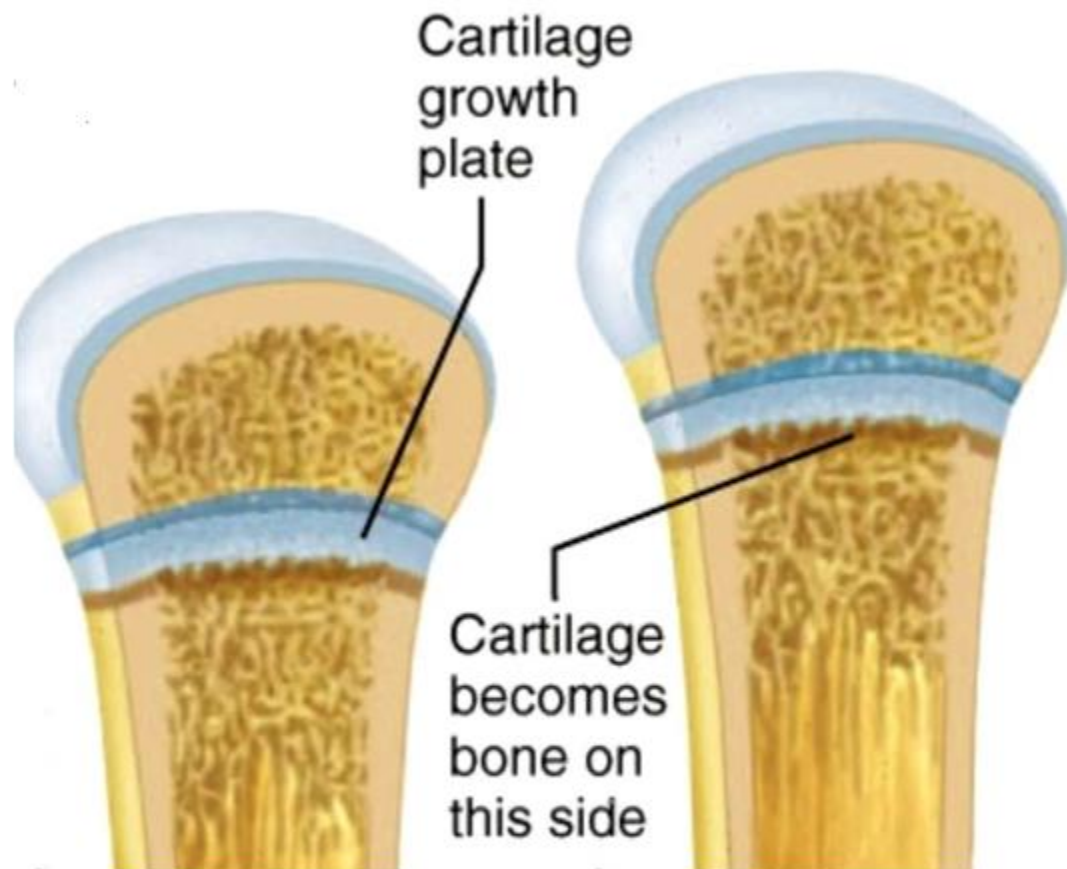
- Permanent
- Function- slight movement
- Site-Usually in the midline , eg pubic symphyses, inter vertebral joints
- Structure-Bones are united by a thick wad of fibro cartilage



Lateral view

Parts of a long bone





Synovial joints

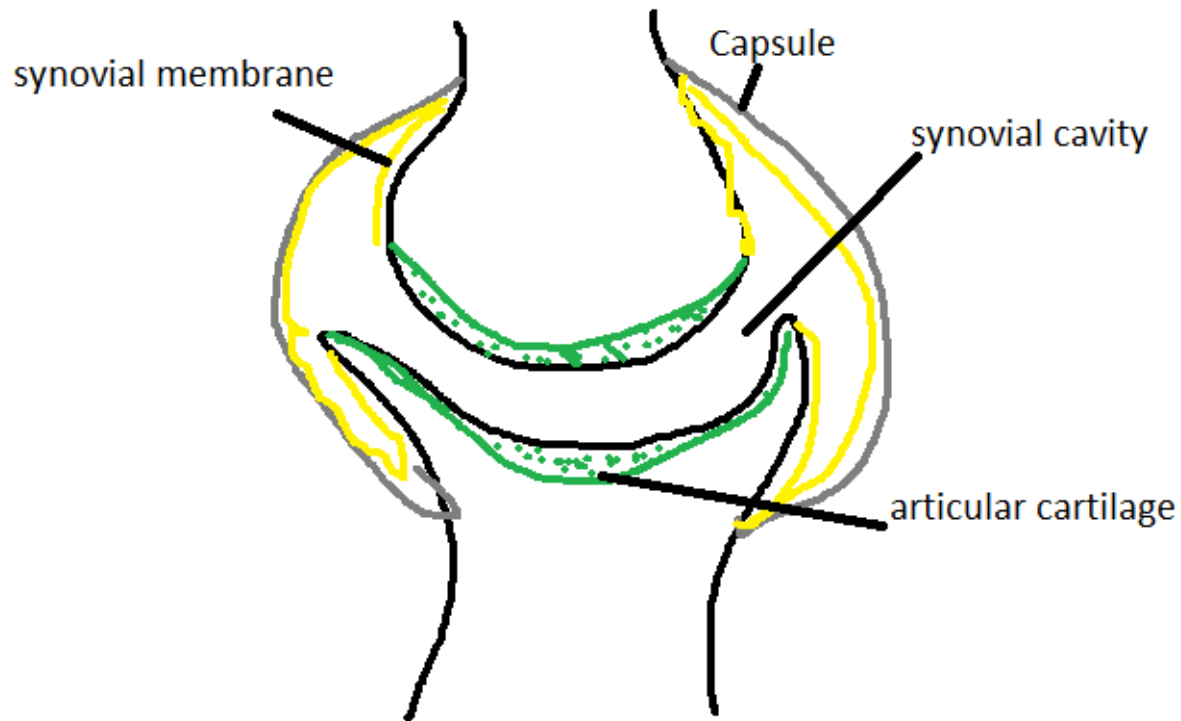
- Definition of joints
- Classification-of joints

- Synovial joints are freely mobile (Diarthrosis)
- Covered by fibrous capsule which is protective, may be thickened to form restraining ligaments and is richly innervated and pain sensitive
- Articular surfaces are reciprocally shaped
- Articular surfaces are lined by articular cartilage
- It is a type of hyaline cartilage
- This cartilage is avascular and non nervous

- Articular cartilage provides a slippery surface for movement
- It also acts as a shock absorber
- It wears down with age
- It gains nutrition by diffusion from the synovial fluid

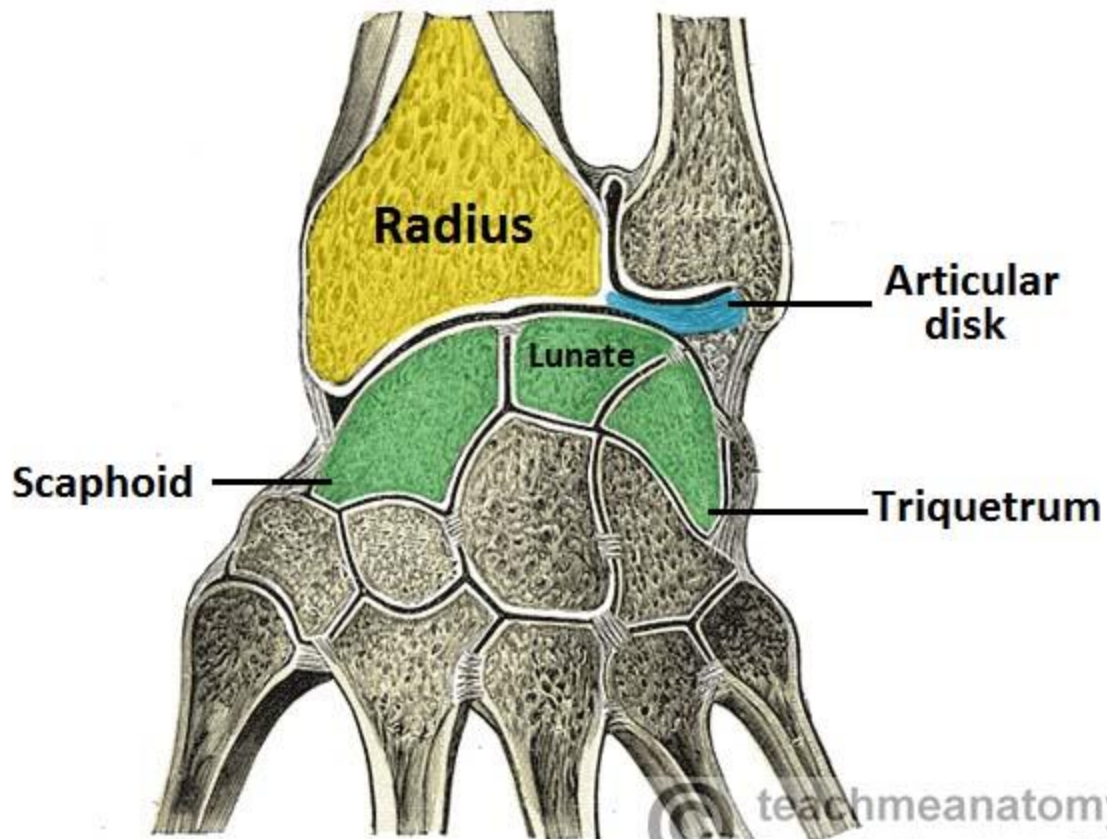
- The joint cavity is lined by synovial membrane except those parts which are lined by articular cartilage
- The synoviocytes line the membrane and produce hyaluronic acid which is an important ingredient of the synovial fluid
- The fluid is thick and viscous and lubricates the joint and nourishes the articular cartilage

Structure of a synovial joint



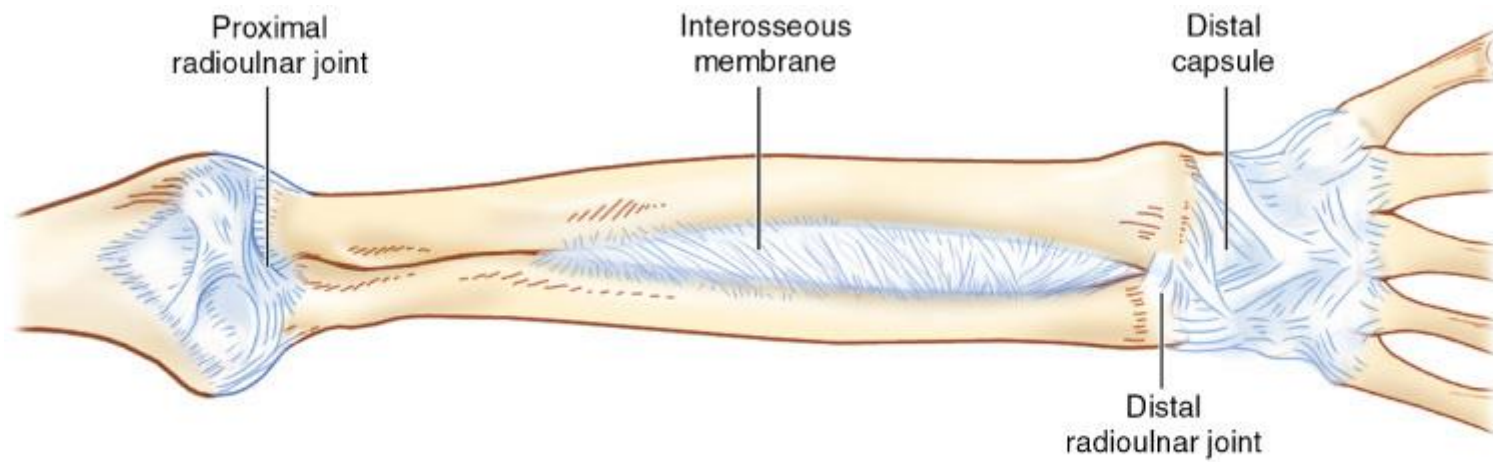
Classification of synovial joints

1. **Plane**-allow gliding movement (eg inter-carpal)
2. **Uniaxial** – movement around only one axis-(eg pivot joints and hinge joints)
3. **Biaxial** - movement around 2axes-(eg condylar joints and ellipsoid joints)
4. **Polyaxial**- movement around many axes-(eg saddle joints and ball and socket joints)



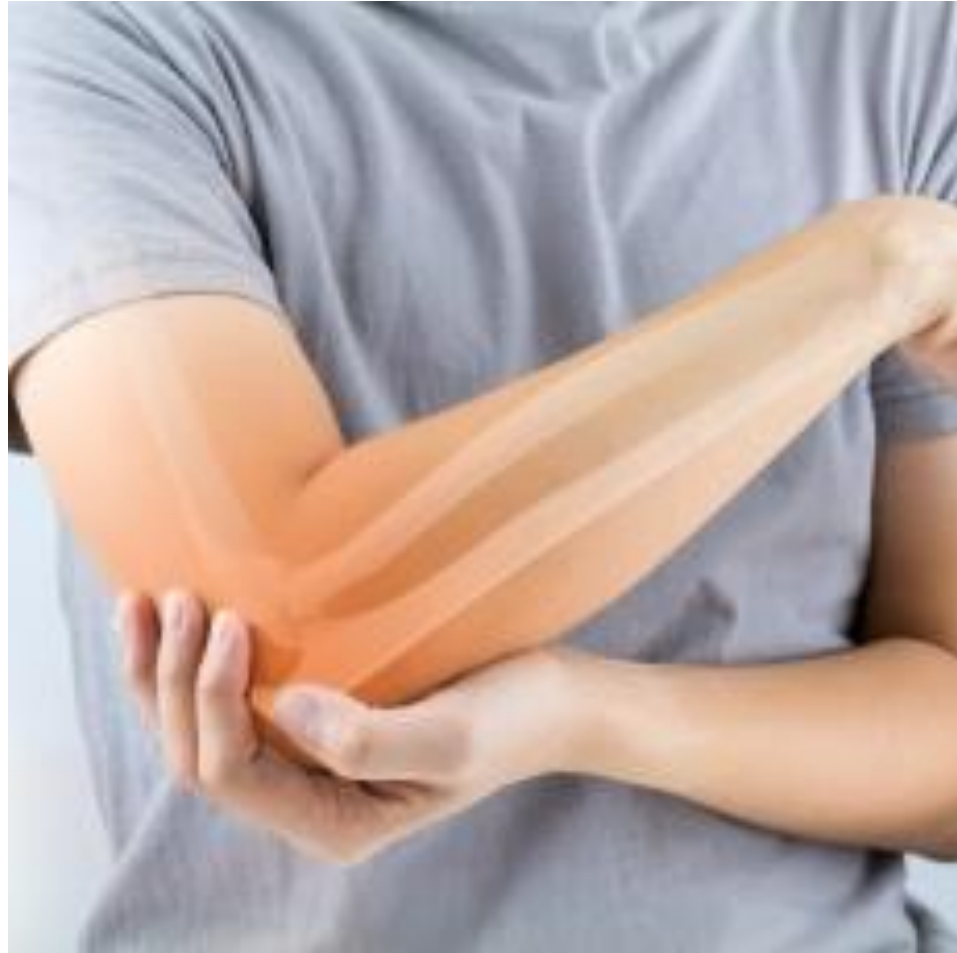teachmeanatomy

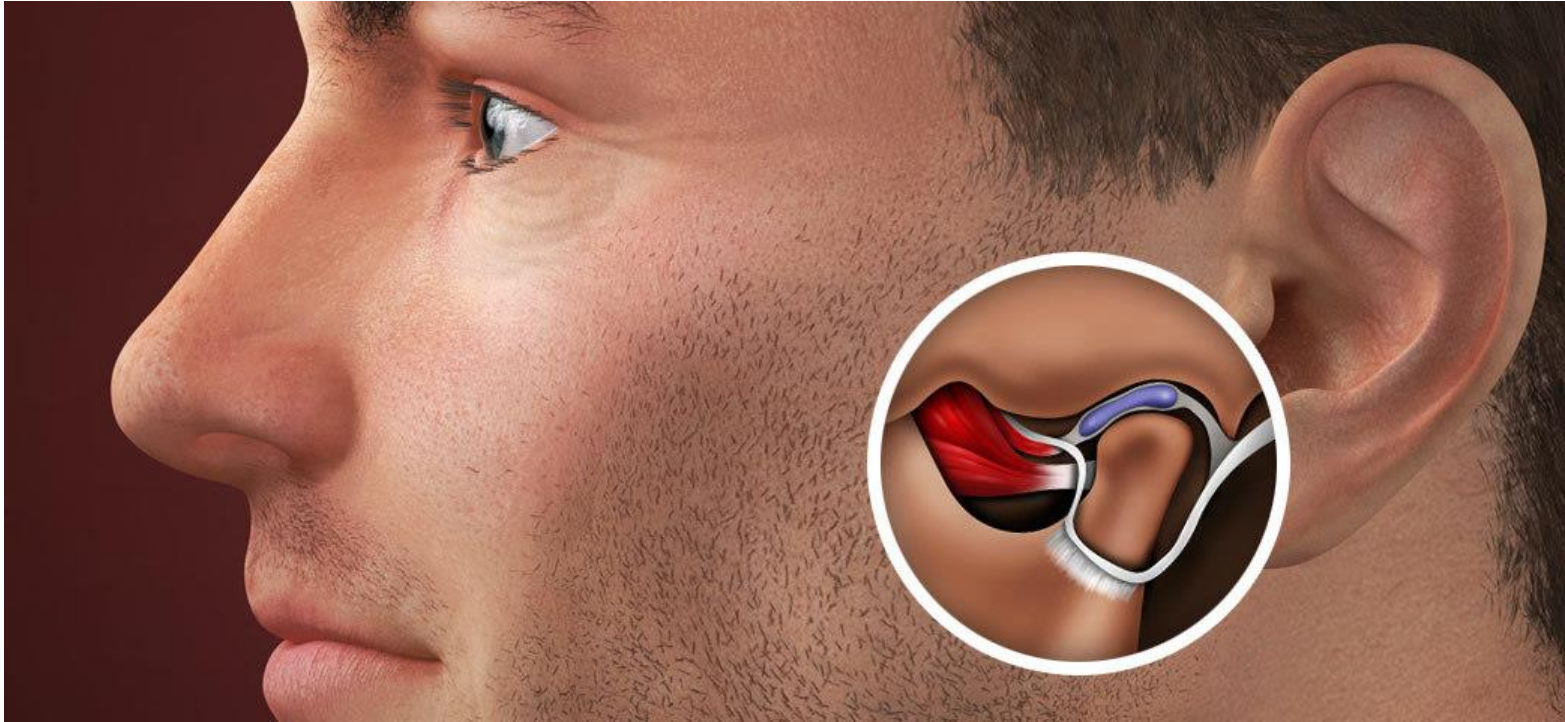
The #1 Applied Human Anatomy Site on the Web.

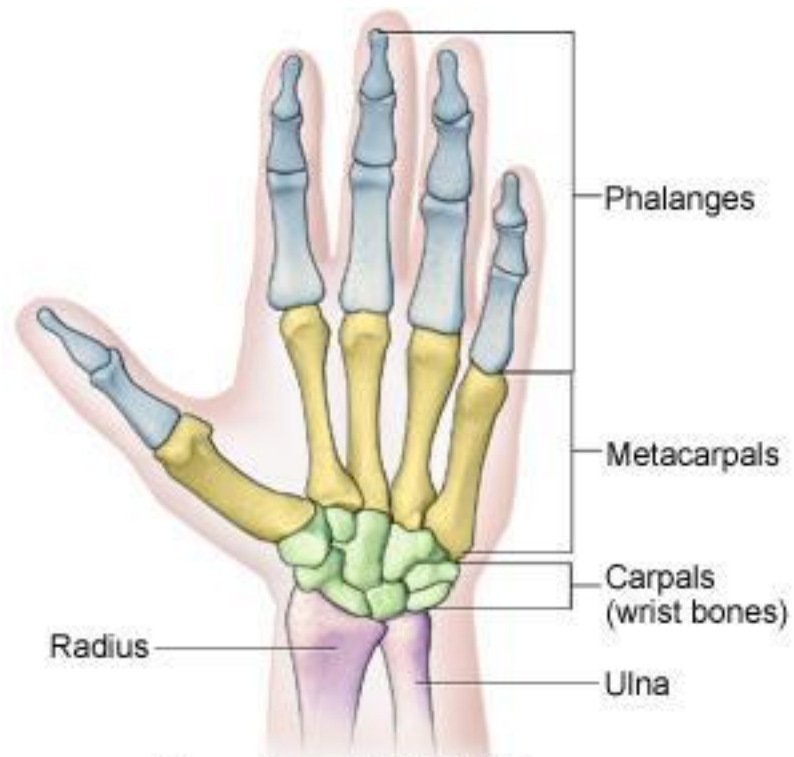

Source: Simon RR, Sherman SC: *Emergency Orthopedics, 6th Edition*:
www.accessemergencymedicine.com


Copyright © The McGraw-Hill Companies, Inc. All rights reserved.

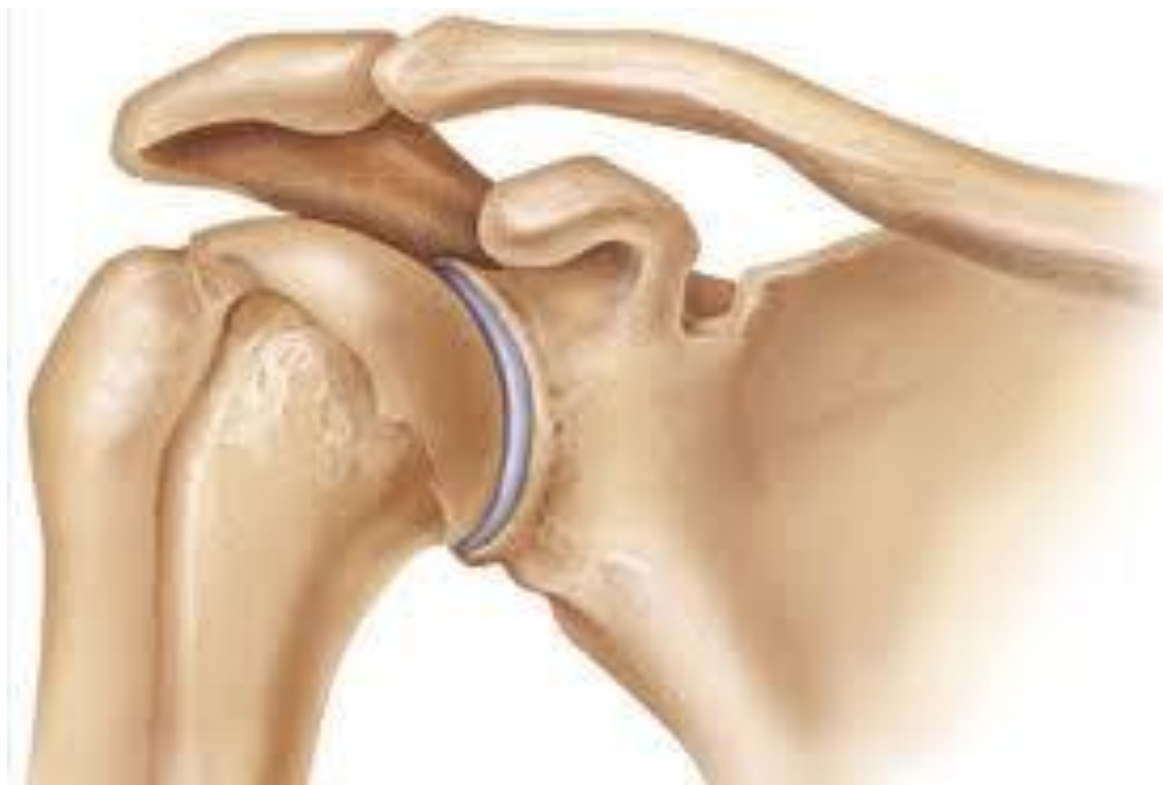





Hand and Wrist Bones





Applied anatomy of synovial joints

- Innervation of synovial joints: Hilton's law states that the nerves that supply the muscles acting on the joint, also supply the joint itself
- Arthritis is painful inflammation of the joint. It could be rheumatoid, rheumatic, degenerative, gouty
- Subluxated joint
- Dislocated joint
- Sprain
- Painless joints as in leprosy