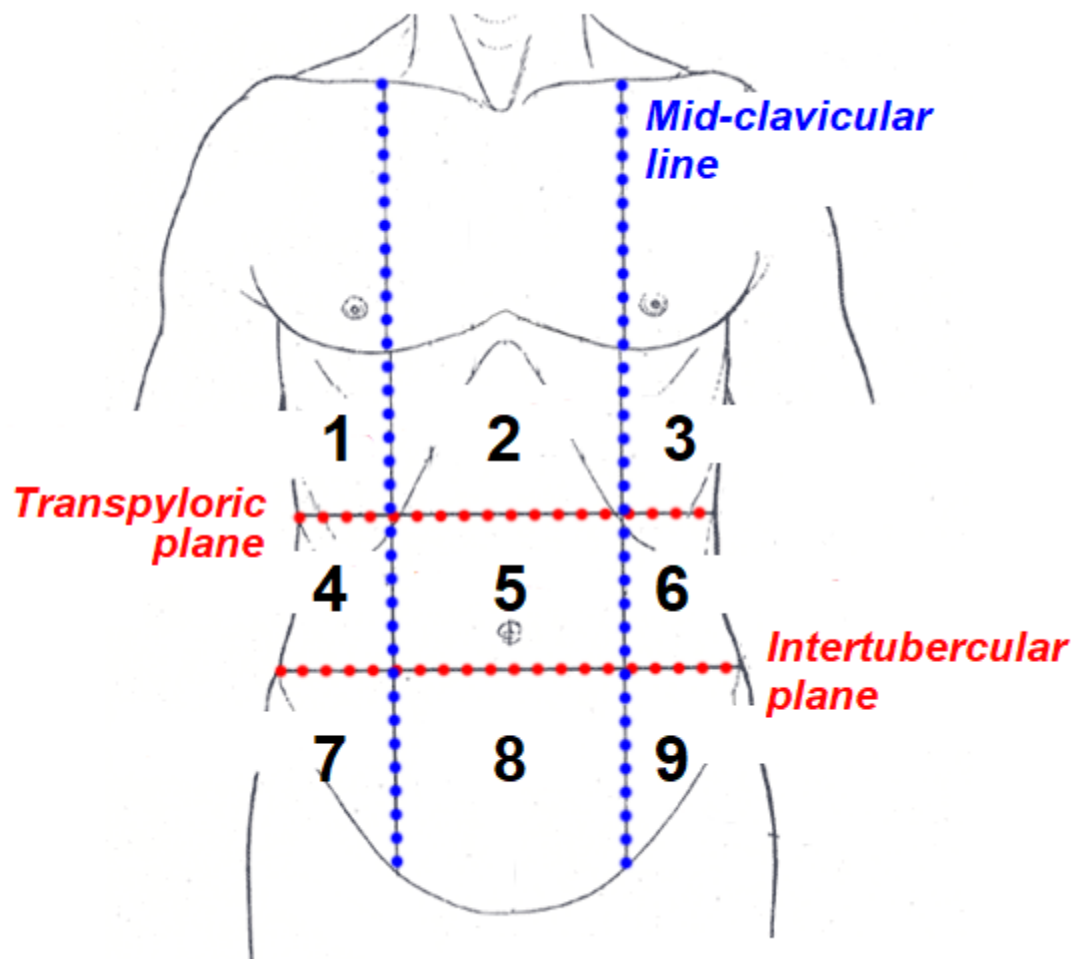
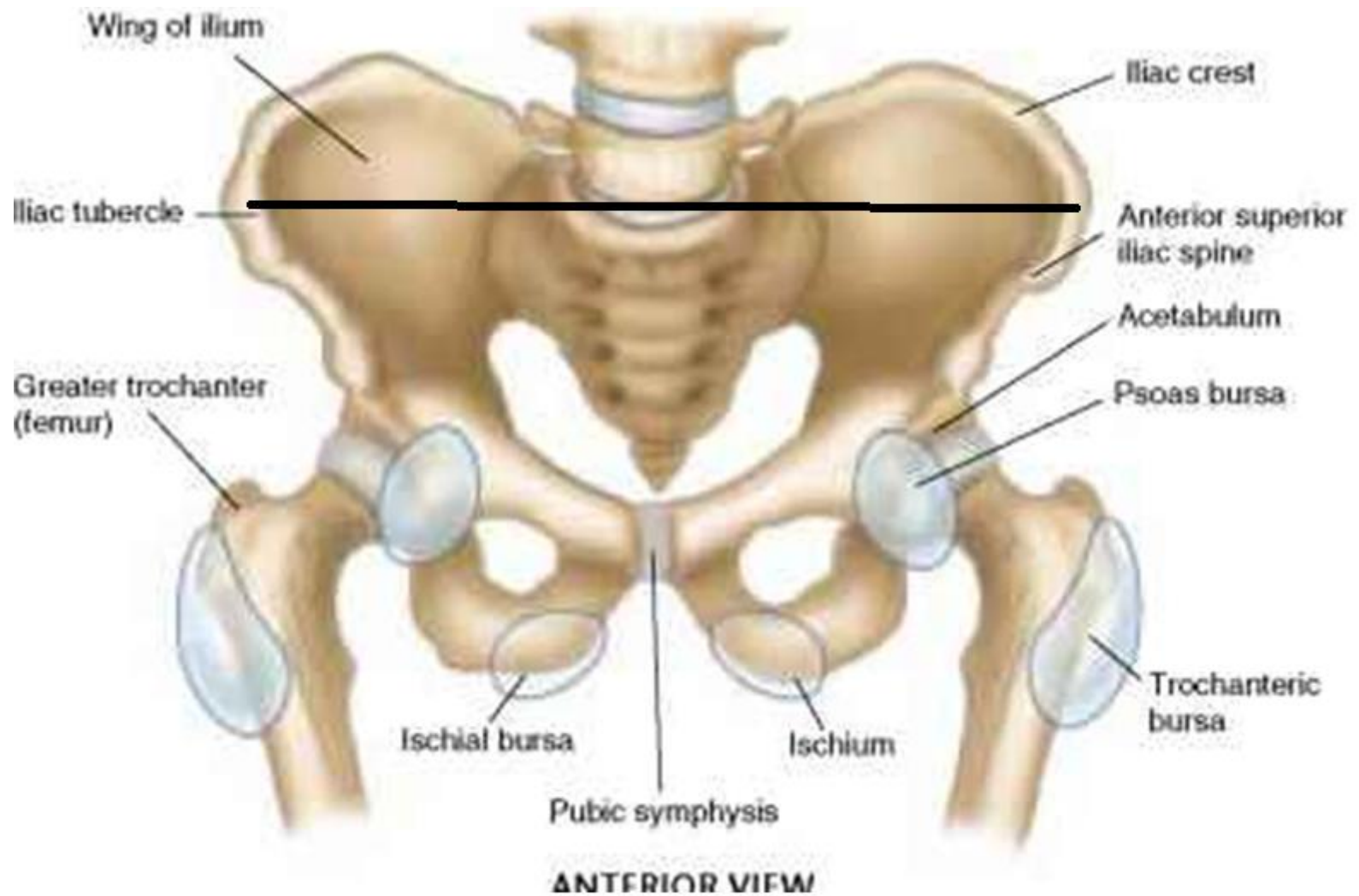


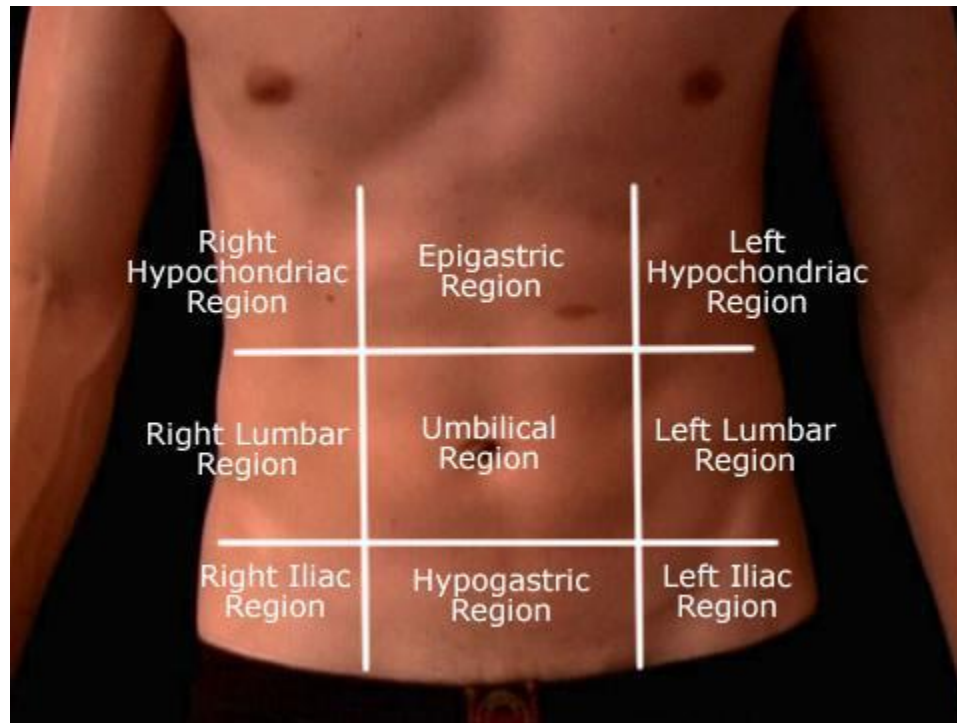
# Anterior Abdominal Wall



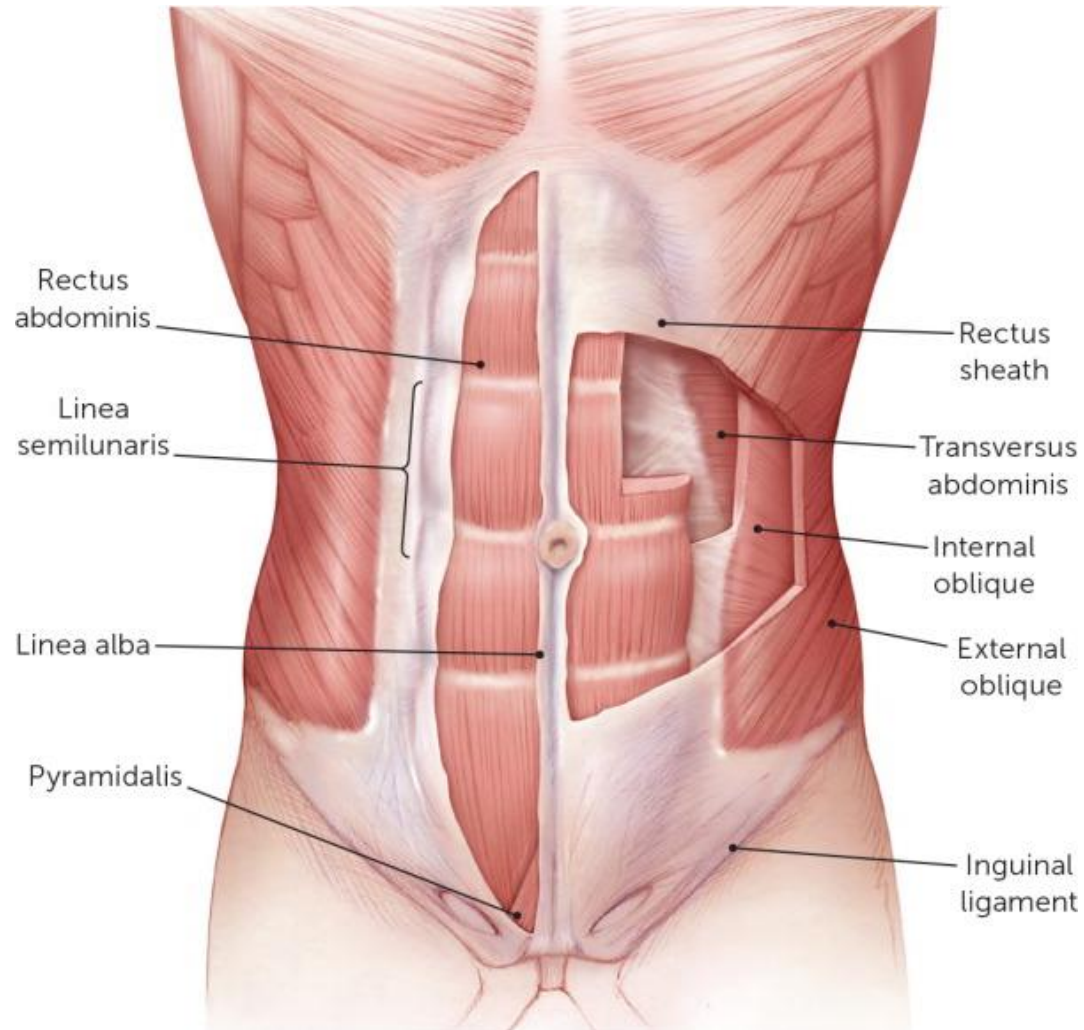
- 1 - Right hypochondrium
- 2 - Epigastrium
- 3 - Left hypochondrium
- 4 - Right flank
- 5 - Umbilical
- 6 - Left flank
- 7 - Right groin
- 8 - Pubic
- 9 - Left groin



# Quadrants of anterior abd wall



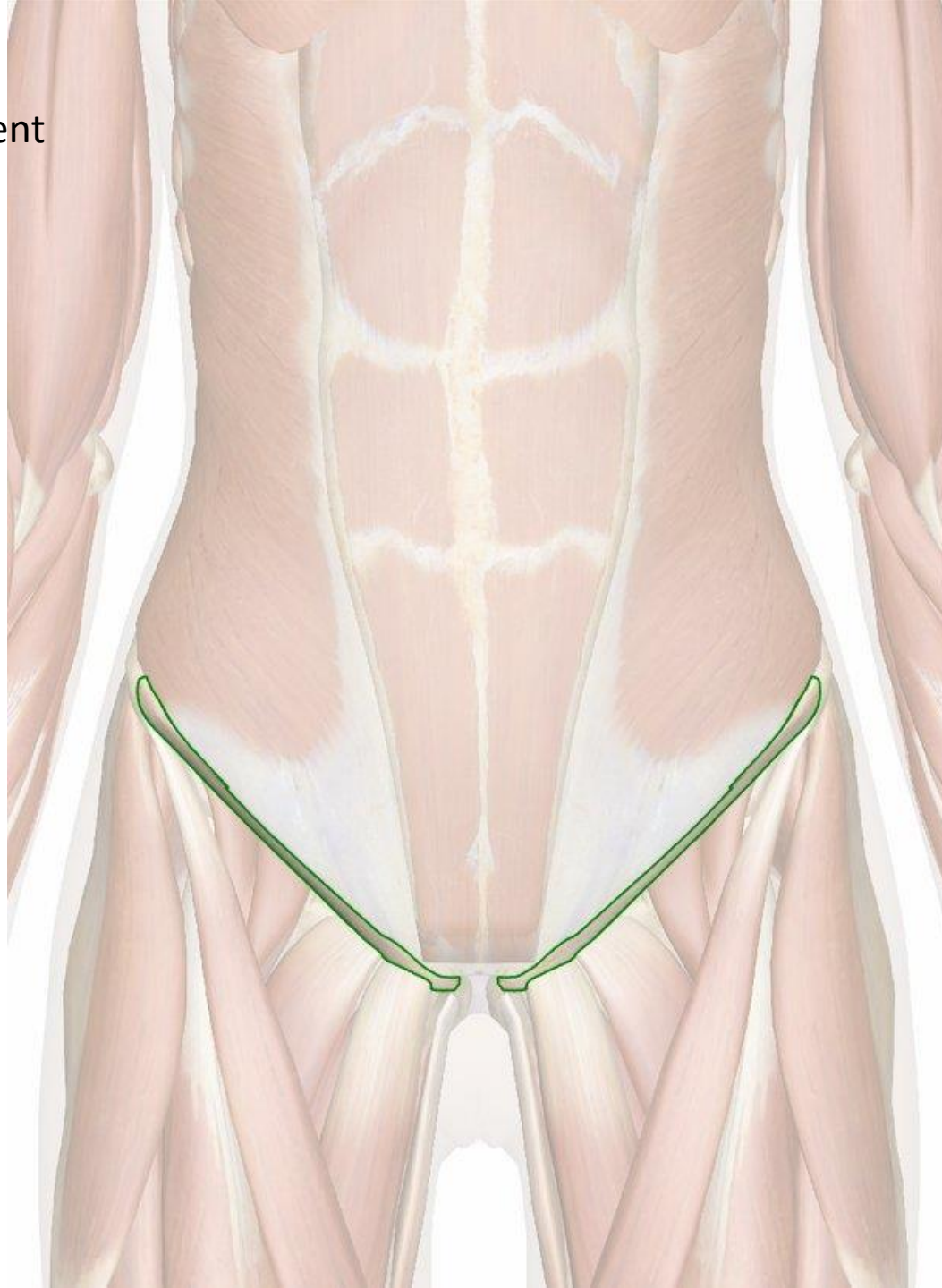# Muscles of anterior abdominal wall

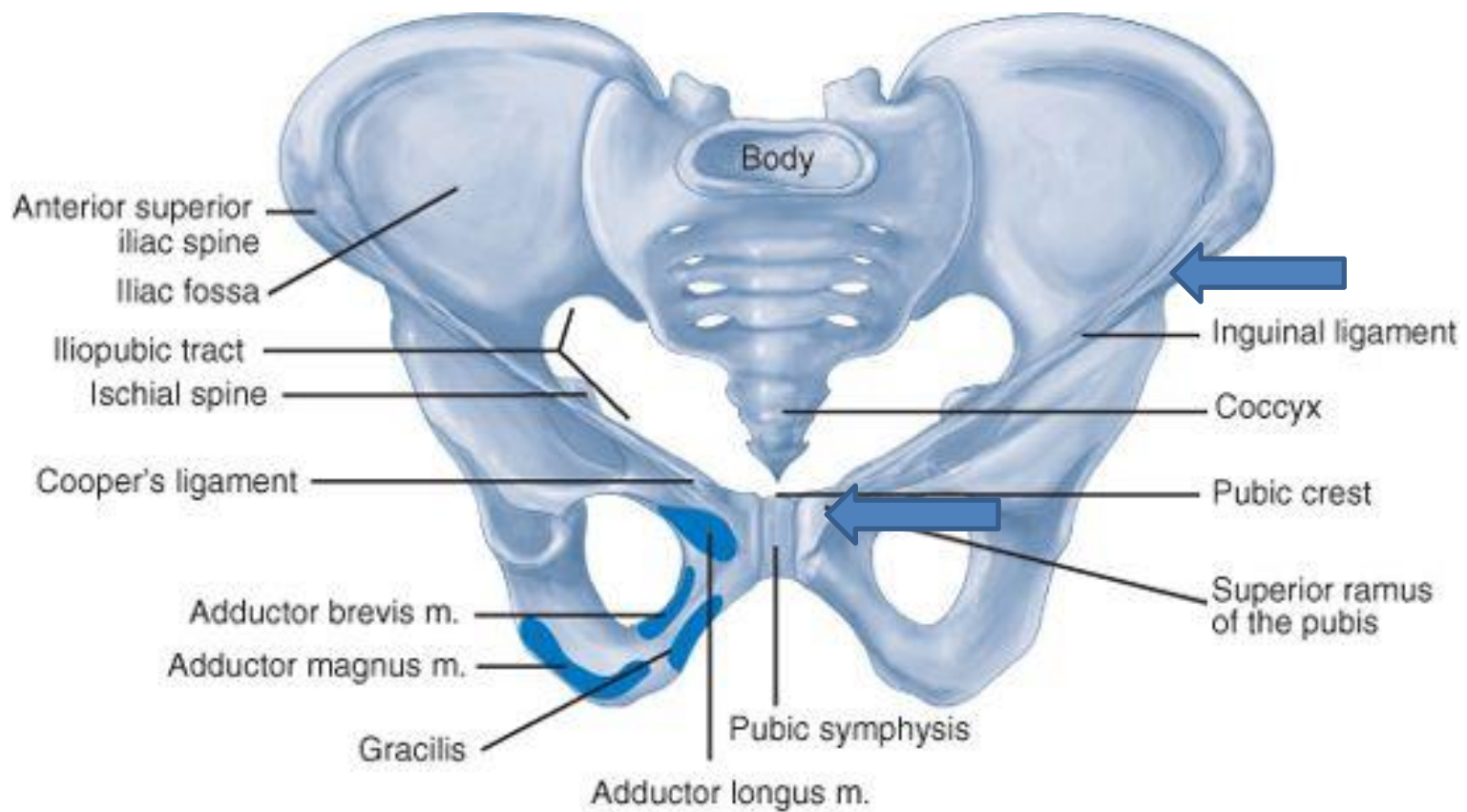


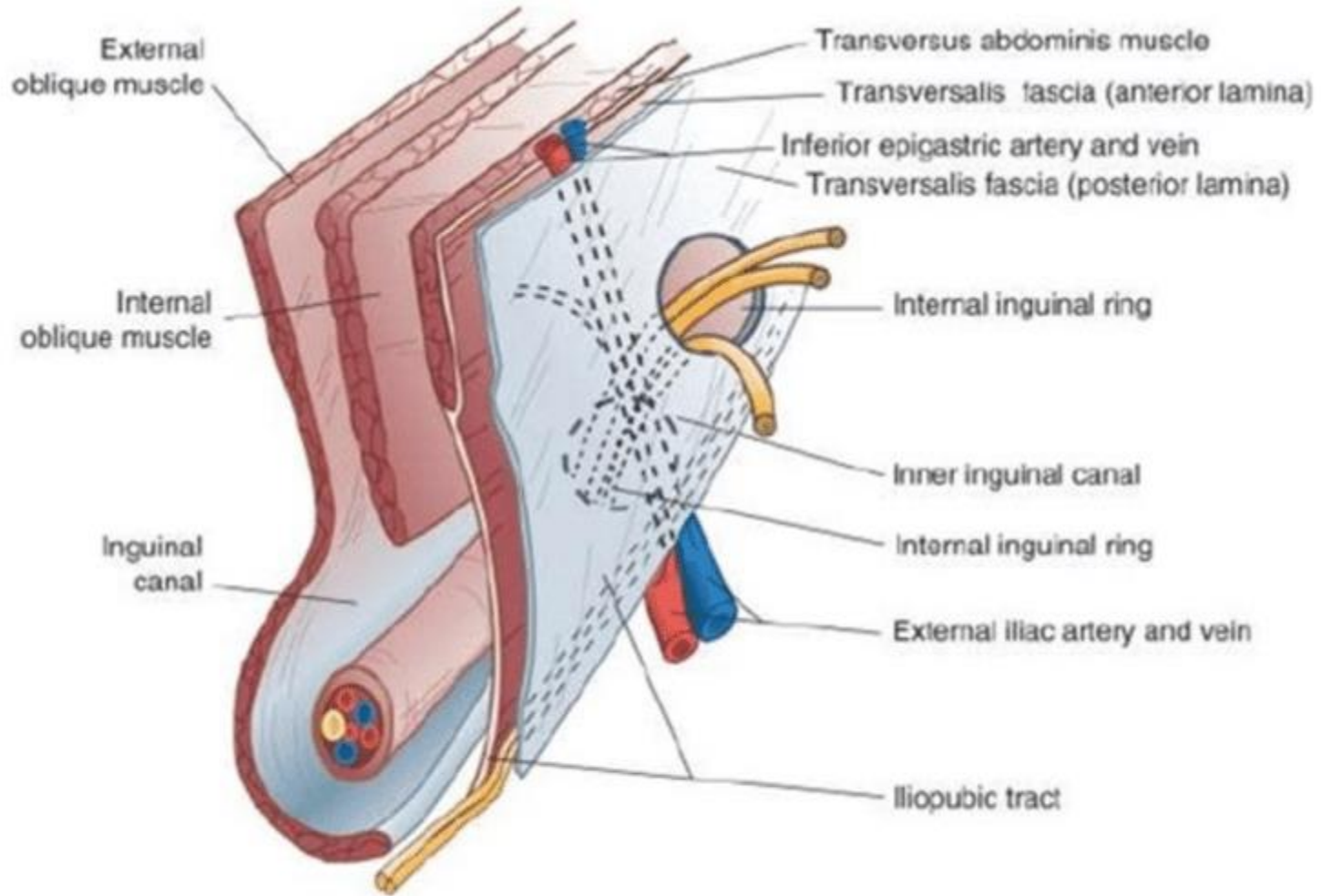
# Muscles of anterior abdominal wall

- External oblique
  - Internal oblique
  - Transversus abdominus
  - Rectus abdominus
- 
- Nerve supply=lower 6 thoracic nerves and 1<sup>st</sup> lumbar nerve

Inguinal ligament







# Functions of muscles of anterior abdominal wall

- Firm and elastic support of abdominal viscera
- By contraction help in expulsive acts of defecation/micturation/ vomiting/ parturition
- In forceful expiration as in coughing/sneezing
- Flexion/ lateral flexion/ rotation of the trunk