

PRE-PROSTHETIC

SURGERY

CONTENTS:

- ◆ INTRODUCTION
- ◆ DEFINITION
- ◆ OBJECTIVES
- ◆ AIMS OF PRE-PROSTHETIC SURGERY
- ◆ CHARACTERISTICS OF IDEAL DENTURE BASE
- ◆ PATIENT EVALUATION AND TREATMENT
PLANNING
- ◆ PRE-PROSTHETIC SURGICAL PROCEDURES
- ◆ CONCLUSION REFERENCES

INTRODUCTION :

Prosthetics is the replacement of missing teeth (lost or congenitally absent) and contiguous oral and maxillofacial tissues, with artificial substitute.

Now, there remains significant number of patients, who can never be made to use dentures effectively, because of

-

- Bone atrophy
- Soft tissue hypertrophy
- or localized soft and hard tissue problems.

In these patients pre-prosthetic surgery offers significant contribution by removing hindrance for prosthesis stability and retention.

It is always hoped that the results of the preprosthetic surgery are acceptable both surgically & prosthodontically. In this vein, the services of an oral and maxillofacial surgeon may be required, especially as the surgical preparation becomes more complicated. In these instances, a team approach is needed with the surgeon and the prosthodontist serving as equal members of the team.

DEFINITION :

- ◆ Pre-prosthetic surgery is carried out to reform/redesign soft/hard tissues, by eliminating biological hindrances to receive comfortable and stable prosthesis.
- ◆ Preprosthetic surgery is defined as surgical procedures designed to facilitate fabrication of a prosthesis or to improve the prognosis of prosthodontic care. (GPT8)

AIMS OF PRE-PROSTHETIC SURGERY :

- ◆ Provide adequate bony tissue support for the placement
- ◆ of complete dentures. Provide adequate soft tissue support, optimal vestibular
- ◆ depth.
- ◆ Elimination of pre-existing bony deformities e.g. tori,
- ◆ prominent mylohyoid ridge, genial tubercle.
- ◆ Correction of maxillary and mandibular ridge
- ◆ relationship.
- ◆ Elimination of pre-existing soft tissue deformities, e.g. epulis, flabby ridges, hyperplastic tissues.
- ◆ Maintain function
- ◆ Esthetics

CHARACTERISTICS OF IDEAL DENTURE BASE :

- ◆ Adequate bony support
- ◆ Soft tissue coverage
- ◆ No undercuts or protuberances
- ◆ No sharp ridges
- ◆ Adequate sulci
- ◆ Absence of peripheral scar bands
- ◆ No muscle fibres to mobilize prosthesis
- ◆ No soft tissue folds/hypertrophies
- ◆ No neoplastic lesions
- ◆ Proper maxillomandibular arch relationships
- ◆ Adequate palatal vault

PATIENT EVALUATION AND TREATMENT

PLANNING :

- ◆ Preprosthetic surgical treatment must begin with a proper case history and physical examination.
- ◆ Special attention should be given to systemic diseases that may be responsible for the severe degree of bone resorption.
- ◆ Esthetic and functional goals of the patient must be assessed carefully.
- ◆ Long term maintenance of the underlying tissues as well as prosthetic appliances should be kept in mind.

PRE-PROSTHETIC SURGICAL PROCEDURES

CAN BE CLASSIFIED AS:

- a) Basic procedures: can be carried out under local anaesthesia on a day care basis.
- b) Advanced surgery procedures: require hospitalization and general anaesthesia.

Procedures are carried out for the following:

1. Alveolar ridge correction
2. Alveolar ridge extension
3. Alveolar ridge augmentation.

I. ALVEOLAR RIDGE CORRECTION

Bony surgeries -

i. Alveolectomy

ii. Alveoloplasty

iii. Elimination of unfavourable undercuts

- Reduction of genial tubercles

- Reduction of mylohyoid ridge

iv. Excision of tori

v. Maxillary tuberosity reduction and exostosis removal.

Soft tissue surgeries-

i. Removal of redundant crestal soft tissues

ii. Frenectomy

iii. Excision of epulis fissurata

iv.: Excision palatal papillary hyperplasia.

BONY SURGERIES

ALVEOLECTOMY :

Surgical removal or trimming of the alveolar process is termed as alveolectomy.

Procedure:

After extraction whenever there is presence of sharp margins at interdental, interseptal or labiobuccal alveolar crest, they should be trimmed with bone ronger or round bur and smoothed with bone file.

ALVEOLOPLASTY :

Alveoloplasty defined as surgical recontouring of the alveolar process.

This procedure is done with the purpose to take care of bony projections, sharp crestal bone or undercuts. Conservation is the key factor in this procedure.

Types:

- a) Simple alveoloplasty
- b) Interseptal alveoloplasty
 - 1) Dean's alveoloplasty
 - 2) Obwegeser's modification
- e) Post-extraction alveoloplasty

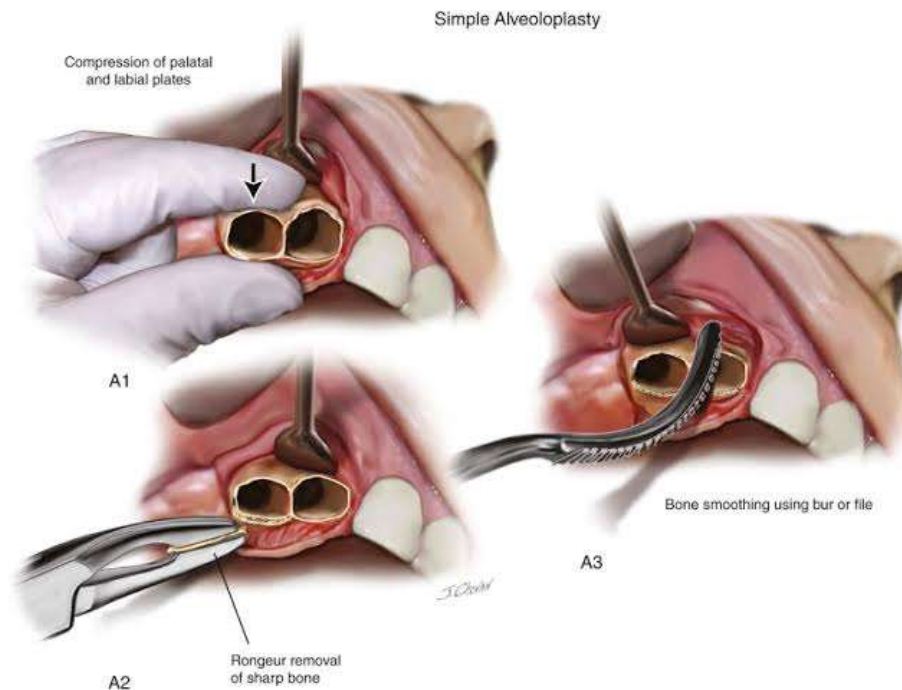
SIMPLE ALVEOLOPLASTY :

Procedure:

- ◆ Bony areas requiring recontouring should be exposed using an envelop type of flap.
- ◆ A mucoperiosteal incision along the crest of the ridge with adequate A-P extension is given
- ◆ Adequate visualization and access to the alveolar ridge obtained
- ◆ Vertical incisions given if necessary
- ◆ Excessive flap reflection may result in devitalized areas of bone which may resorb rapidly after surgery
Recontouring can be accomplished with
- ◆ Rongeur Bone file
- ◆ Bone bur in hand piece

Copious saline irrigation should be done throughout the recontouring procedure to avoid overheating and bone necrosis

After this the edges of the flap are trimmed and then sutured with continuous or noncontinuous sutures.



DEAN'S INTERSEPTAL ALVEOLOPLASTY :

Only done in maxillary anterior region to reduce gross maxillary overjet.

Mostly done immediately after extraction of anterior teeth.

This technique is best used in an area where the ridge is of relative regular contour and adequate height but presents an undercut to the depth of the labial vestibule.

Advantages:

Labial prominence is reduced without reducing the height of the ridge

The periosteal attachment to the bone can be maintained hereby reducing bone resorption

Muscle attachments are left undisturbed

Disadvantage:

Decrease in ridge thickness

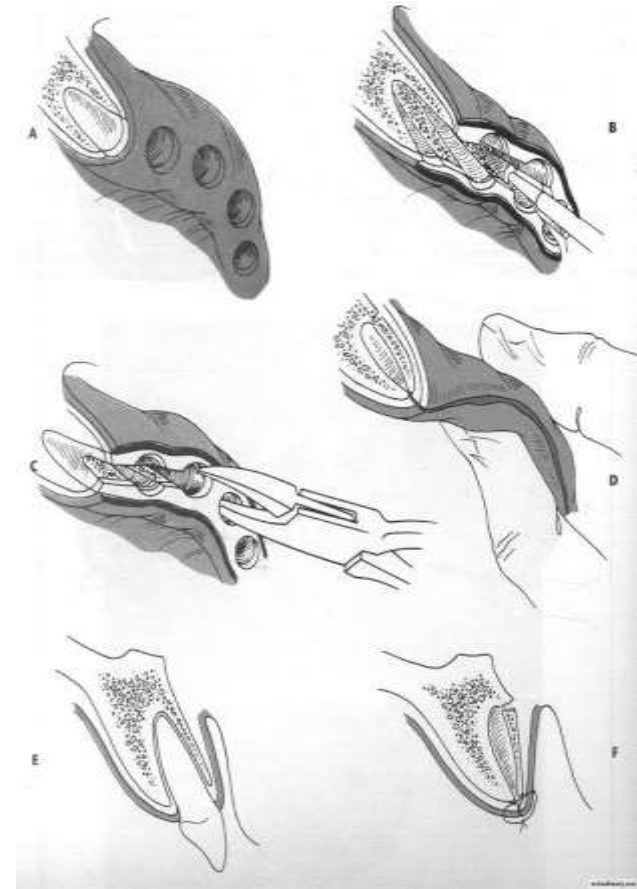
Procedure:

After anterior teeth extraction, Interseptal bone is cut with the bur from canine to canine region.

With the same bur vertical cuts are made only in the labial cortex at distal end of the canine extraction socket bilaterally without perforation of labial mucosa.

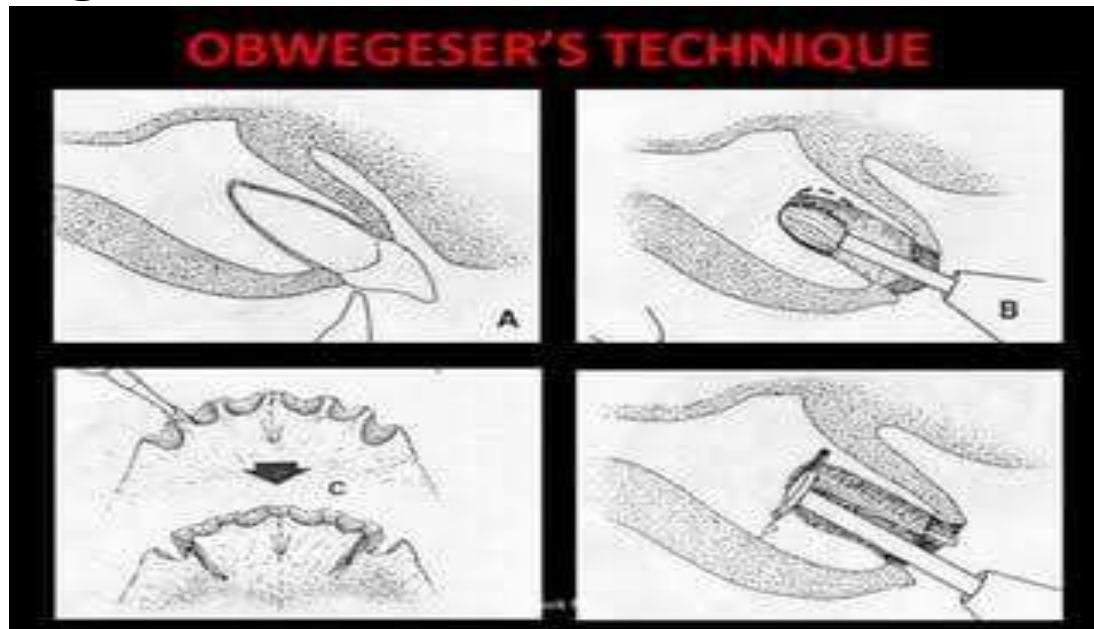
Now labial cortex is fractured with periosteal elevator and compressed into palatal direction in approximation with palatal plate.

After removing any sharp margin, suturing is done.



OBWEGESER'S MODIFICATION OF DEAN'S ALVEOLOPLASTY :

In this both the labial and palatal cortices are repositioned. This is done when the anterior over jet is too gross that can not be reduced by labial plate repositioning.



Procedure-

Procedure is same as dean's alveoloplasty but the only addition is that, here palatal plate is fractured too at its base and repositioned with labial plate in palatal direction.

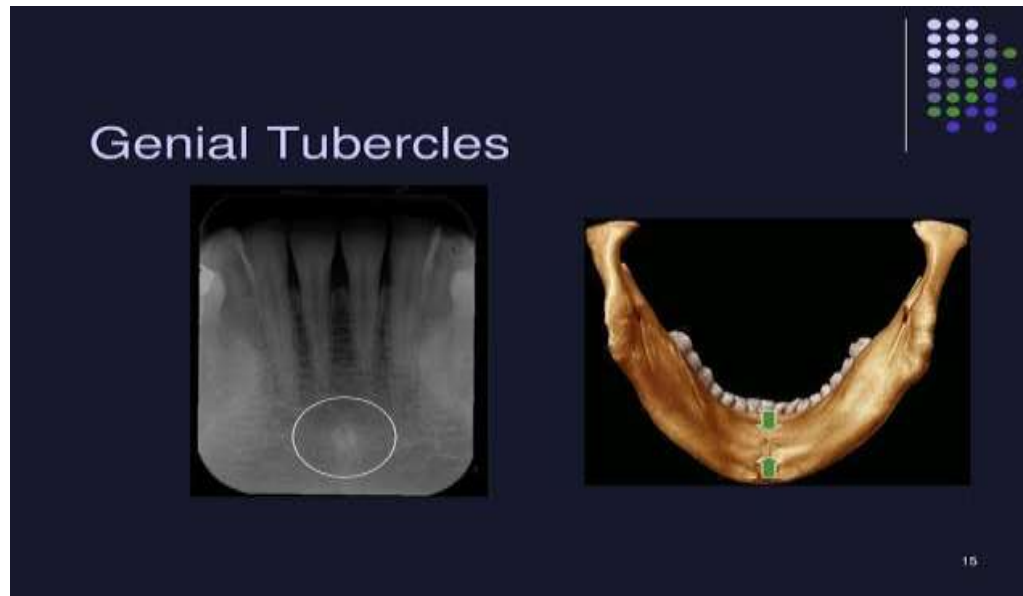ELIMINATION OF UNFAVOURABLE UNDERCUTS

- ◆ Unfavourable undercuts are developed due to severe atrophy of the mandible which hinders in proper denture construction.
- ◆ These undercuts are mostly present on lingual aspect of mandible like genial tubercle prominences, sharp mylohyoid ridge prominences.
- ◆ Most of the times, patient wearing old dentures comes with the complaint of ulceration or inflammation on these lingual prominences,
- ◆ So surgical reduction should be carried out to relieve these undercuts.

REDUCTION OF GENIAL TUBERCLES

Procedure:

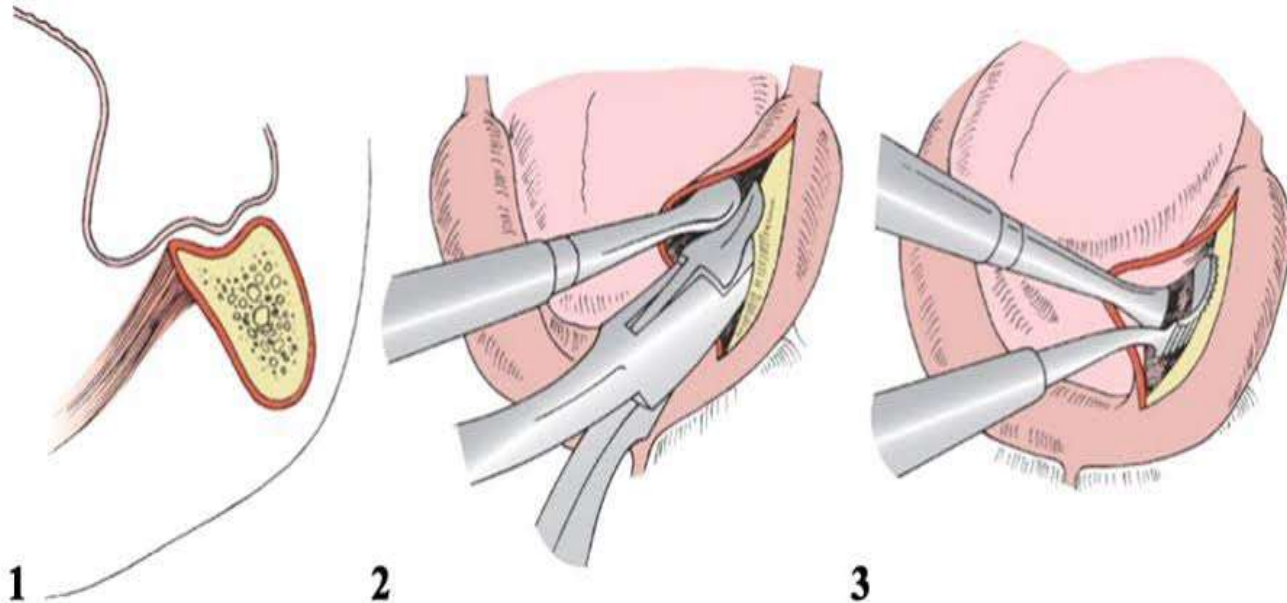
In this procedure lingual flap is reflected in anterior region of mandible and genial tubercles are reduced with the bur. Then Genioglossus muscle is sutured below at geniohyoid tubercle and flap is closed.



REDUCTION OF MYLOHYOID RIDGE

Procedure:

- ◆ Linear incision is made over the crest of the ridge in the posterior aspect of the mandible
- ◆ Full thickness mucoperiosteal flap is elevated to expose the muscles
- ◆ Bone file is used to remove the sharp prominence of the mylohyoid ridge
- ◆ Mylohyoid muscle is sutured below and flap is closed.

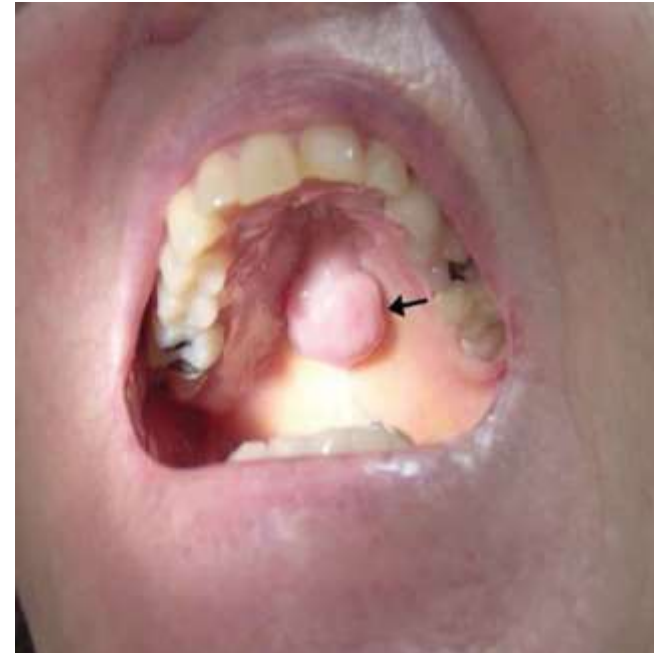

EXCISION OF TORI - PALATAL TORUS

Palatal tori are usually present on the midline of the hard palate. Most palatal tori are less than 2 cm in diameter, but their size can change throughout life.

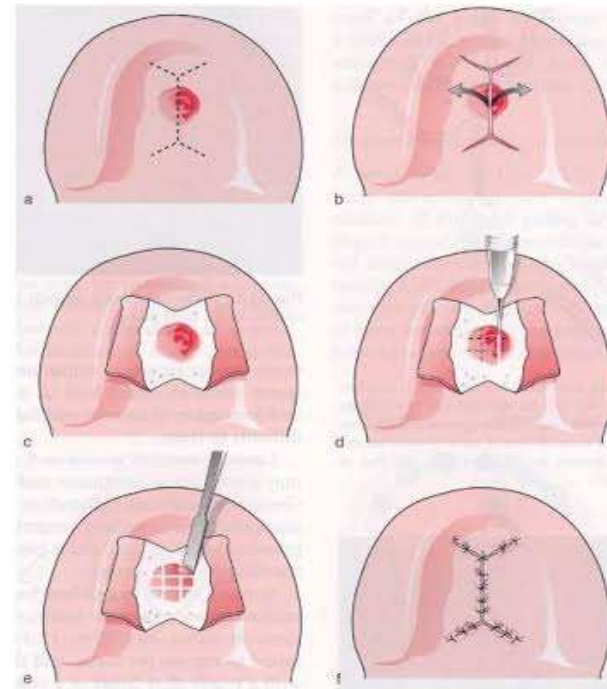
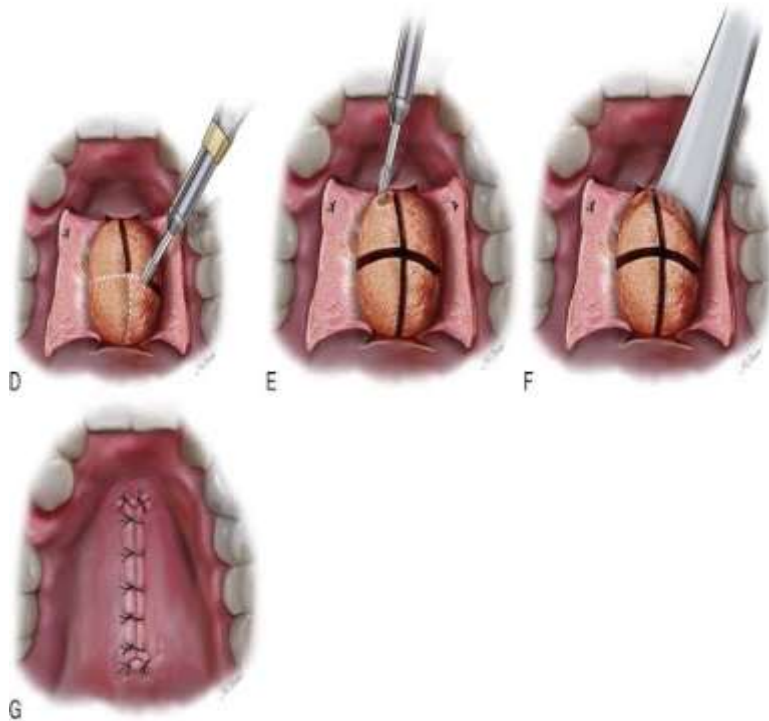
Indication:

- ◆ An extremely large torus filling the palatal vault.
- ◆ A torus that extend beyond the posterior dam area.
- ◆ Traumatized mucosa over the torus.
- ◆ Deep bony undercuts interfering with denture insertion and stability.
- ◆ Interference with function (speech, deglutition).
- ◆ Small tori can be relieved during denture construction but large tori should be surgically removed.



Procedure:

- ◆ In this, midline incision is given in palate and flap is reflected with Y-shaped releasing incisions.
- ◆ Torus is removed by making multiple cuts of it and flap is sutured.
- ◆ A palatal splint is given to prevent hematoma formation.



Removal of Palatal Torus (a),(b) A midline incision is made across the bony mass with lateral extensions anteriorly and posteriorly. (c) The *mucoperiosteal flaps* are reflected to expose the bony mass. (d) A bur is used to divide the *torus* into small pieces. (e) A chisel is used to elevate the small fragments of bone from the hard palate. (f) The wound is debrided and the bone is smoothed with a bur, then sutures are placed to close the wound.

EXCISION OF TORI - MANDIBULAR TORUS

Torus mandibular is an exostosis found on the lingual surface of the mandible opposite the canine and premolars region.

They too interfere with denture retention because of the loss of marginal seal in premolar region.

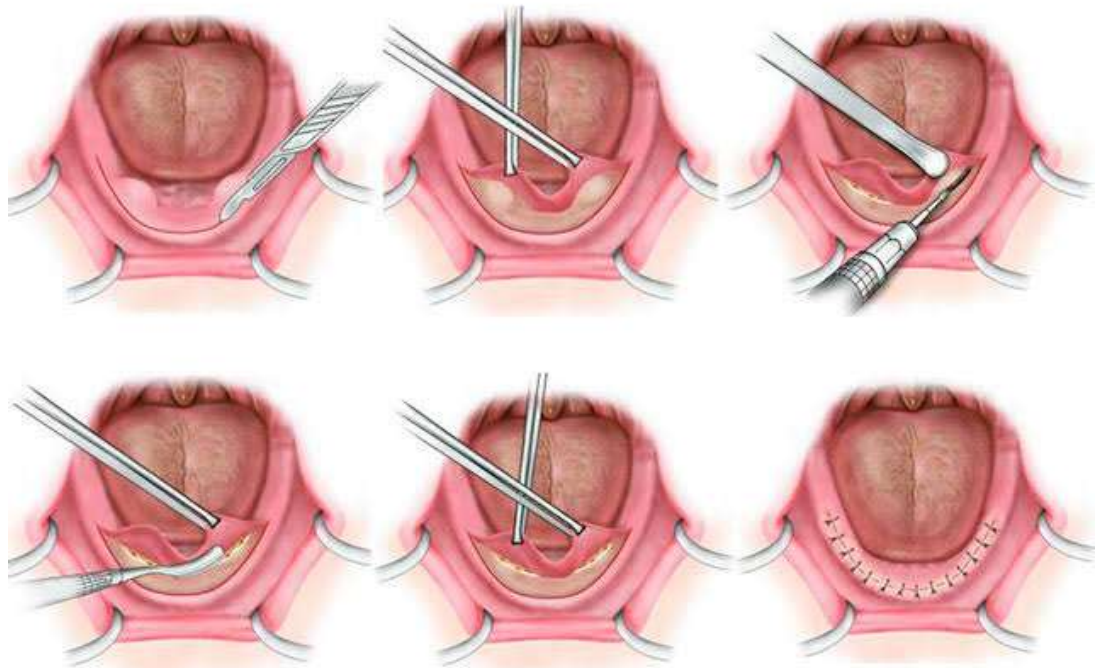
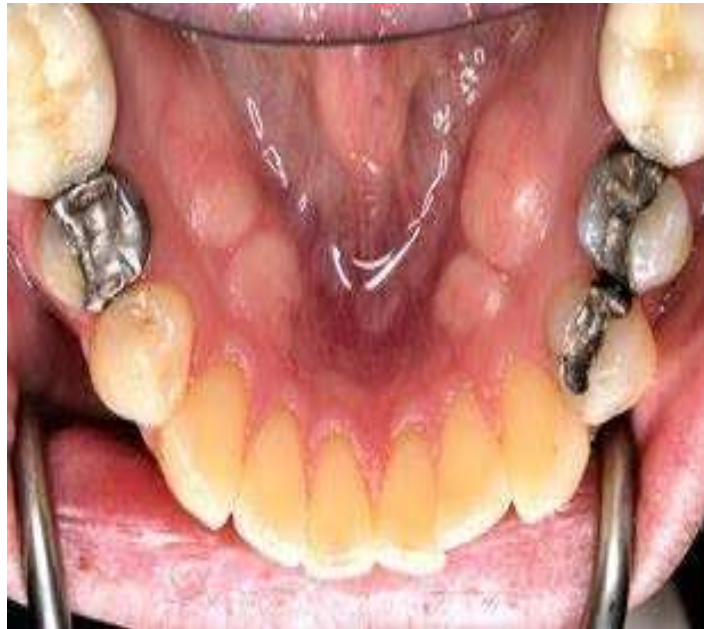Indication:

- ◆ Tori causing lingual undercuts and interfering with lingual flange extension of the planned prosthesis.
- ◆ When the mucosal covering is ulcerated.
- ◆ Large tori interfering with speech and deglutition

Procedure:

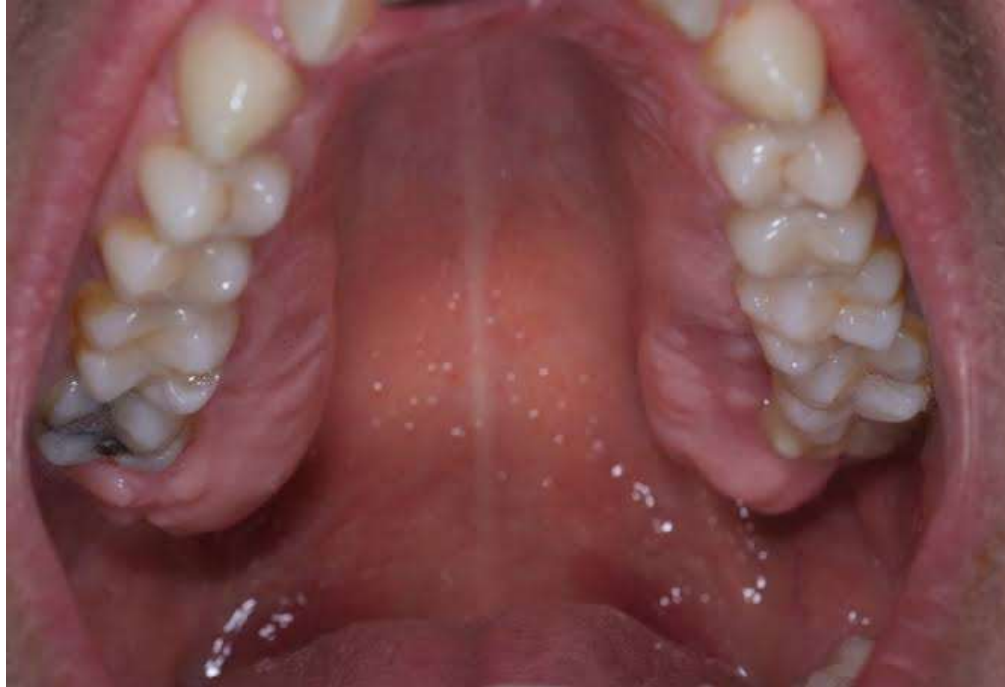- ◆ Bilateral lingual and inferior alveolar anesthesia is given
- ◆ Incision extending from 1 to 1.5cms beyond each tori is given .
- ◆ Always leave behind a band of tissue attached to the midline between the anterior extent of the 2 incisions.
- ◆ When the torus has a small pedunculated base, a mallet and an osteotome is used to cleave the tori from the medial aspect of the mandible
- ◆ The direction of the initial bur is parallel to the medial aspect of the mandible to prevent fracture of the lingual or inferior cortex

- ◆ A bone file is then used to smoothen the lingual cortex
- ◆ Palpation is done to check for proper contour and presence of any undercuts
- ◆ Continuous suturing is done and gauze packs are placed and retained for the next 12 hrs



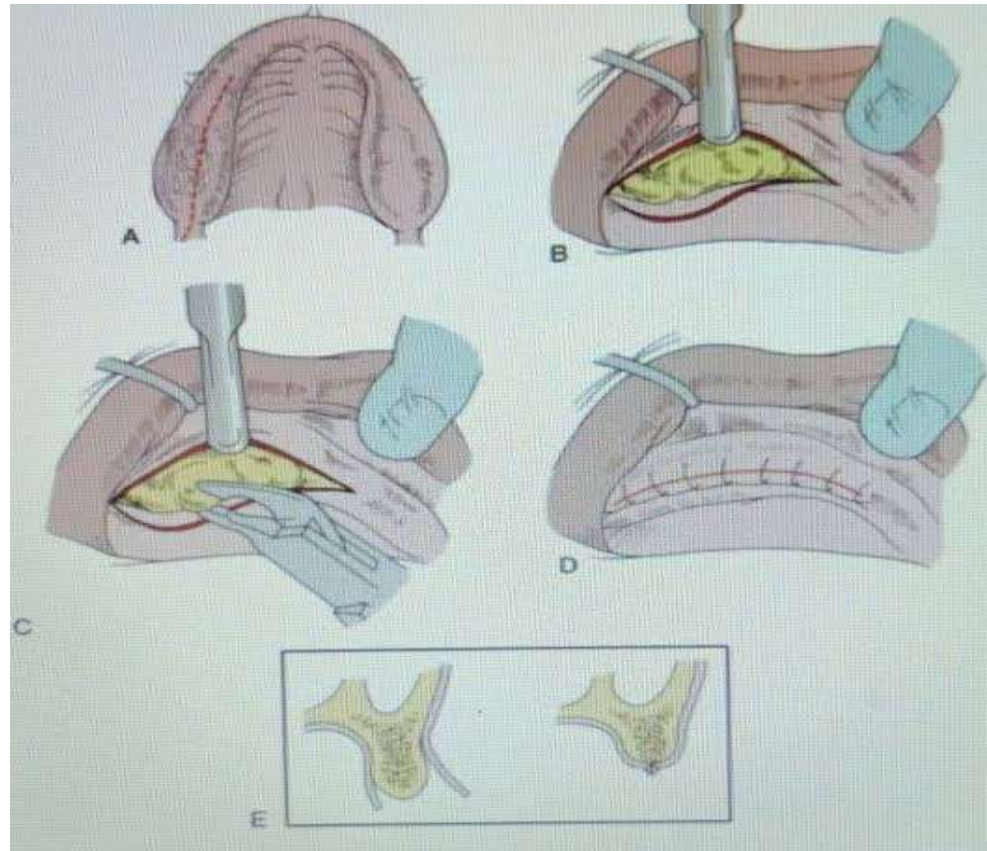
MAXILLARY TUBEROSITY REDUCTION AND EXOSTOSIS REMOVAL

- ◆ The main reason for tubercle overgrowth is extraction of opposing mandibular 3rd molars and subsequent supraeruption of maxillary 3rd molar, where remains as bony overgrowth after maxillary 3rd molar extraction.
- ◆ Maxillary tubercle interfere with denture construction because it decreases inter-arch space.



Procedure:

- ◆ Crestal incision from tuberosity to pre-molar area should be given and hyperplastic soft tissue or bony overgrowth should be removed with the help of chisel, mallet or burs.
- ◆ After desired contour is achieved, the excess soft tissue is trimmed and flap is sutured followed by splint over it.



SOFT-TISSUE

SURGERIES

REDUNDANT CRESTAL SOFT TISSUE

REMOVAL

- ◆ The presence of the fibrous, hyperplastic tissue gives rise to flabby ridge form.
- ◆ These flabby ridges results in unstable base for dentures.
- ◆ In maxilla - enlarged tuberosity
- ◆ In mandible - enlarged retro molar pad
- ◆ Surgical removal is done by particular requirements of the tissue growth.

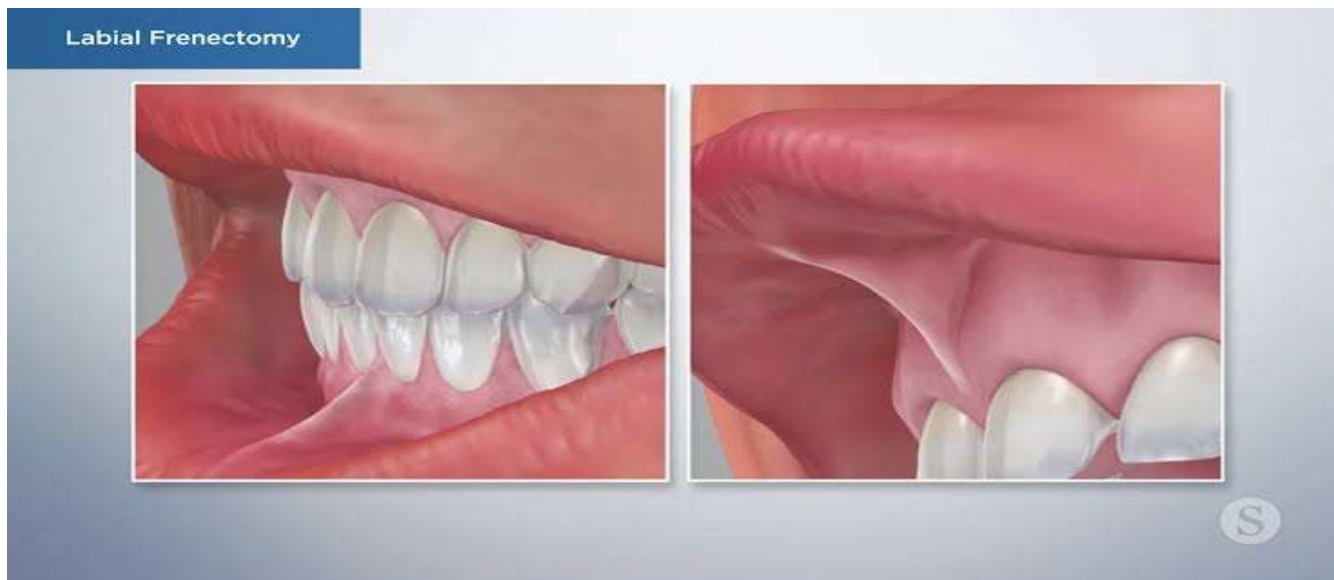FRENECTOMY

- ◆ Many times there is high frenum attached near to the crest of the ridge which may be too broad which interfere in getting proper peripheral seal in denture.
- ◆ Lingual frenum may be too short and attached till the tip of the tongue which interfere with normal tongue movements and causes speech problem to the patient, so surgical correction is advocated in these cases.

LABIAL FRENECTOMY (MAXILLARY)

Procedure-

- Cross-diamond excision:
 - i. This is done when there is lot of tissue is available. Here base n apex of the frenum at the alveolar crest is grasped with haemostat and incision is taken above and below the haemostat.
 - ii. The surgical defect is created by excision of fibrous band. The closure is done by interrupted sutures and small defect at alveolar crest is left to granulate.



- Z-plasty:

- i. This procedure is used when the frenum is broad and the vestibule is short.

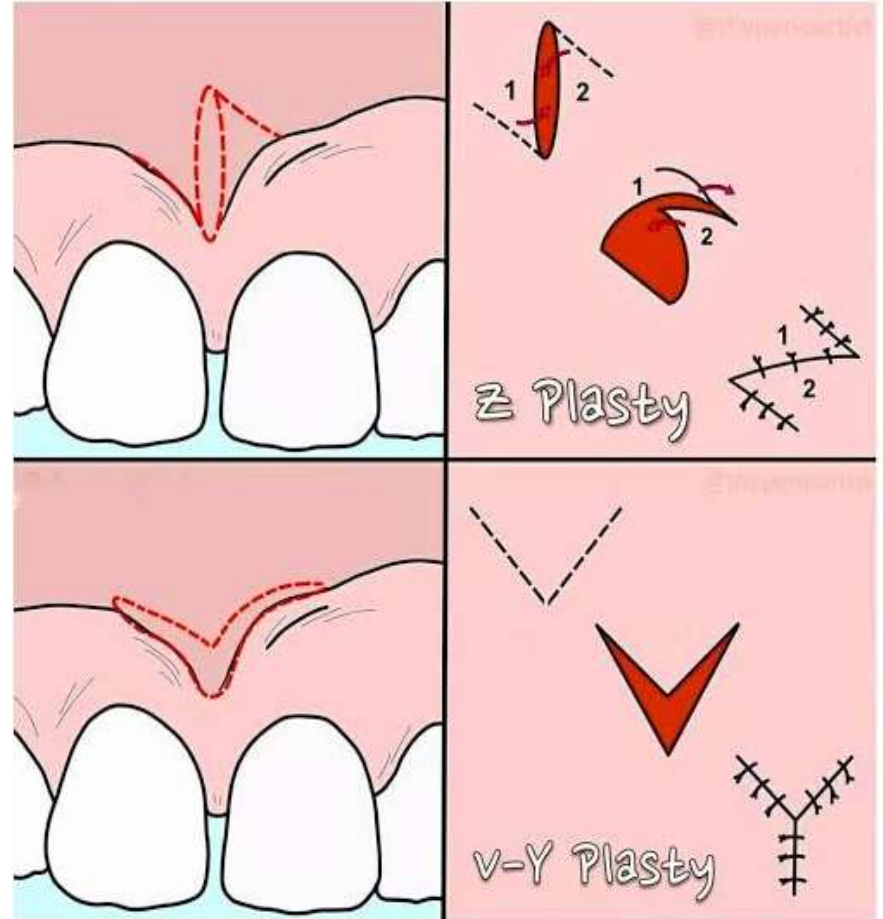
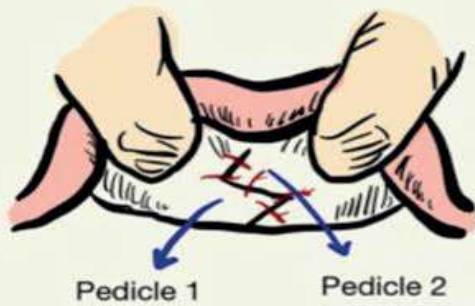
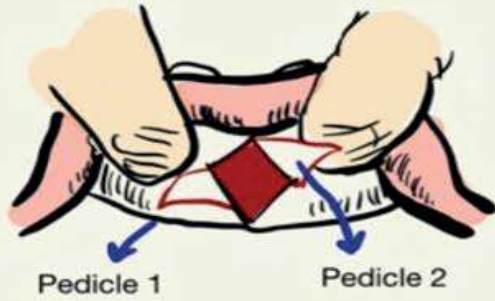
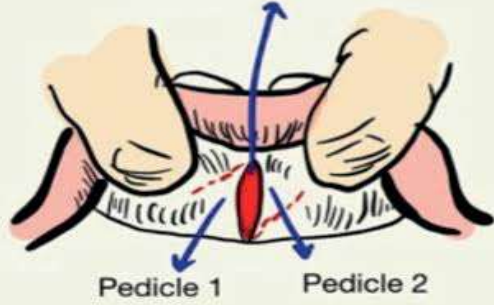
- V-Y incisions:

- i. These incisions are used for lengthening localized area.

- Semi lunar incisions:

- i. These incisions are used for broad premolar and molar region freni.

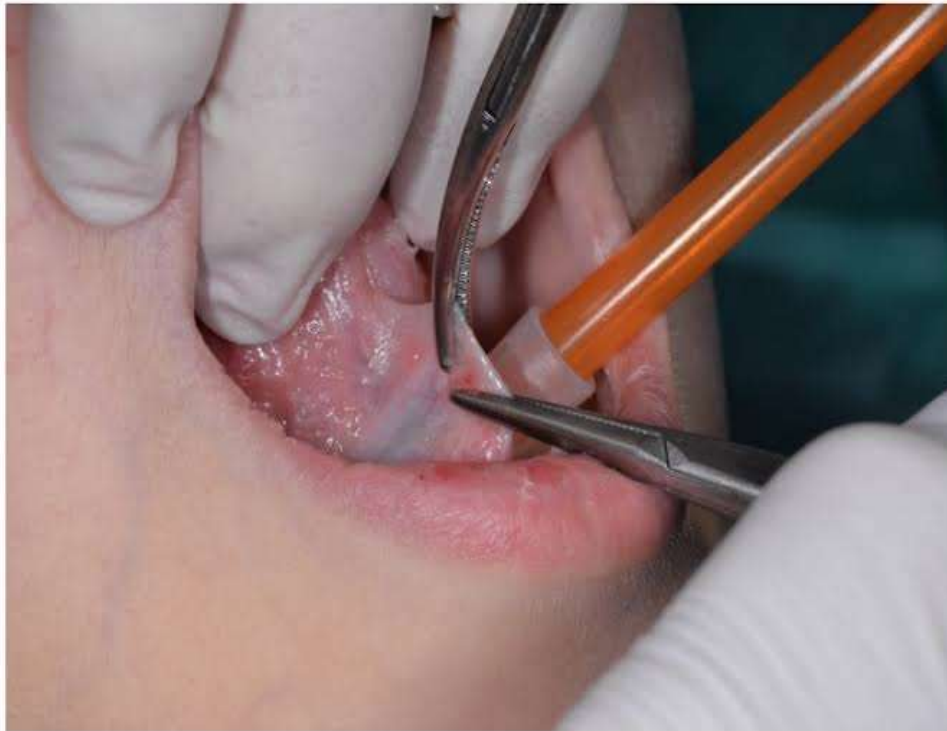Elliptical Incision



LINGUAL FRENECTOMY

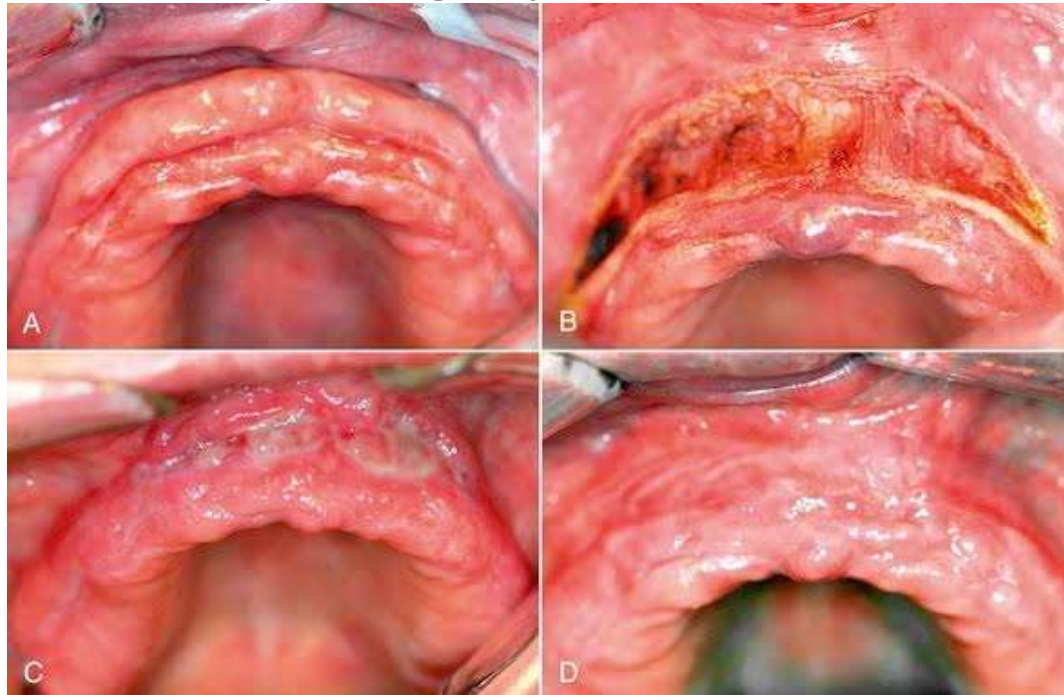
Procedure:

- ◆ Here lingual frenum is reduced by giving cross-diamond incision.
- ◆ After incision sub mucosal dissection is done on either side and vertical suturing is given.



EXCISION OF EPULIS FISSURATUM

- ◆ These are the benign, pedunculated lesions present as excessive or redundant tissue of the vestibule, frequently associated with over extended denture border.
- ◆ These lesions are removed by Sharpe excision, electro cauterization, cryosurgery or laser excision.



EXCISION OF PALATAL PAPILLARY

HYPERPLASIA

- ◆ This happens because of chronic denture irritation, because of ill-fitting dentures.
- ◆ There can be superimposed Candida infection. Denture should be relieved in this region and antifungal agent should be applied.
- ◆ Supraperiosteal excision with a electrocautary can be done.

II. ALVEOLAR RIDGE EXTENSION

- ◆ Whenever there is an inadequate vestibular depth present, (due to mandibular atrophy and high muscle or soft tissue attachment) so to increase retention and stability of denture, deepening of vestibule is considered.
- ◆ Sufficient amount of bone should be present (min 15mm bone height) for alveolar ridge extension/ vestibuloplasty
- ◆ procedure.
- ◆ This procedure can be done in both jaws.

VESTIBULOPLASTY

Labial vestibuloplasty:

For mandibular ridge:

- i. Kazanjian technique (1924).
- ii. Godwin's modification (1947)
- iii. Clark's technique
- iv. Obwegeser's modification (1959)

For maxillary ridge:

- i. Maxillary pocket inlay vestibuloplasty

Lingual vestibuloplasty:

- i. Trauner's technique
- ii. Caldwell's technique

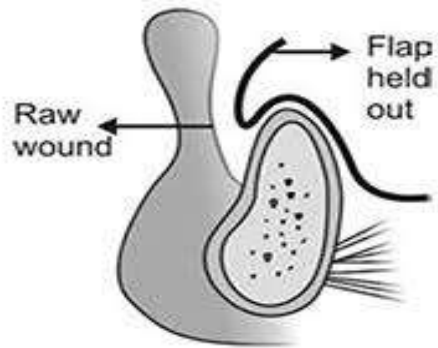
Mental nerve transposition

LABIAL VESTIBULOPLASTY (MANDIBULAR RIDGE)

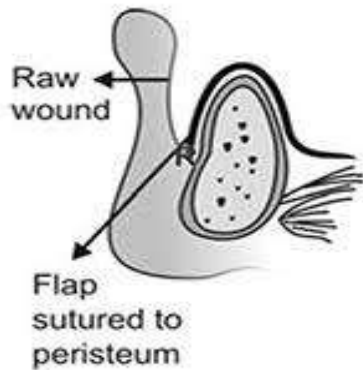
Kazanjian technique: (Lipswitch technique)

- ◆ Mucosal flap from inner aspect of the lower lip is used to increase the vestibular depth in anterior mandibular labial vestibule (premolar to premolar region).
- ◆ Raw area is left on the lip side to be healed by secondary intentions.
- ◆ Periosteum of bone is left intact.
- ◆ Drawback - scaring of mucosa with subsequent decreased flexibility of lower lip.

a. *Transpositional flap
Vestibuloplasty or
Lip Switch
(Kazanjian)*

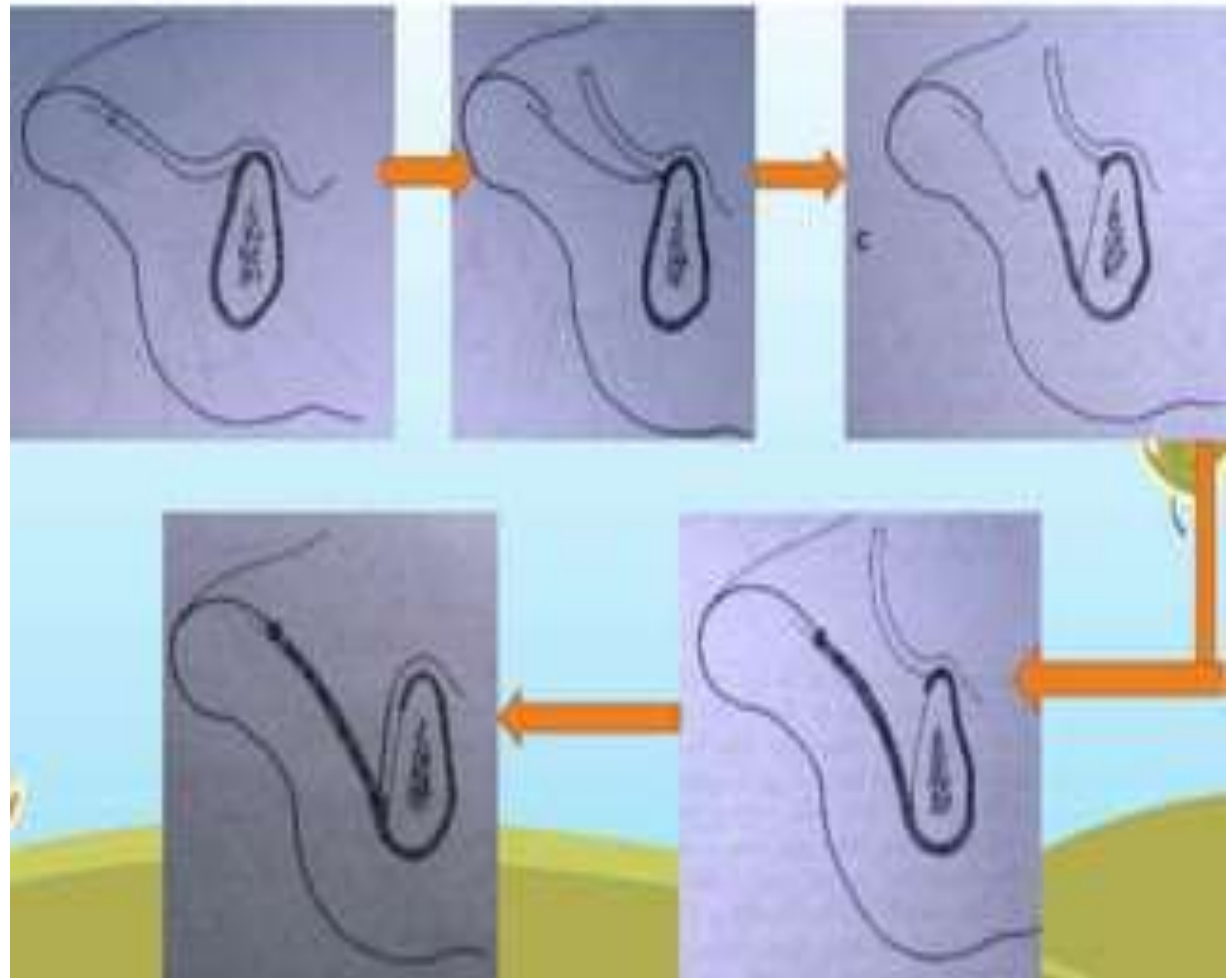


Step 1



Step 2

LIPSWITCH TECHNIQUE

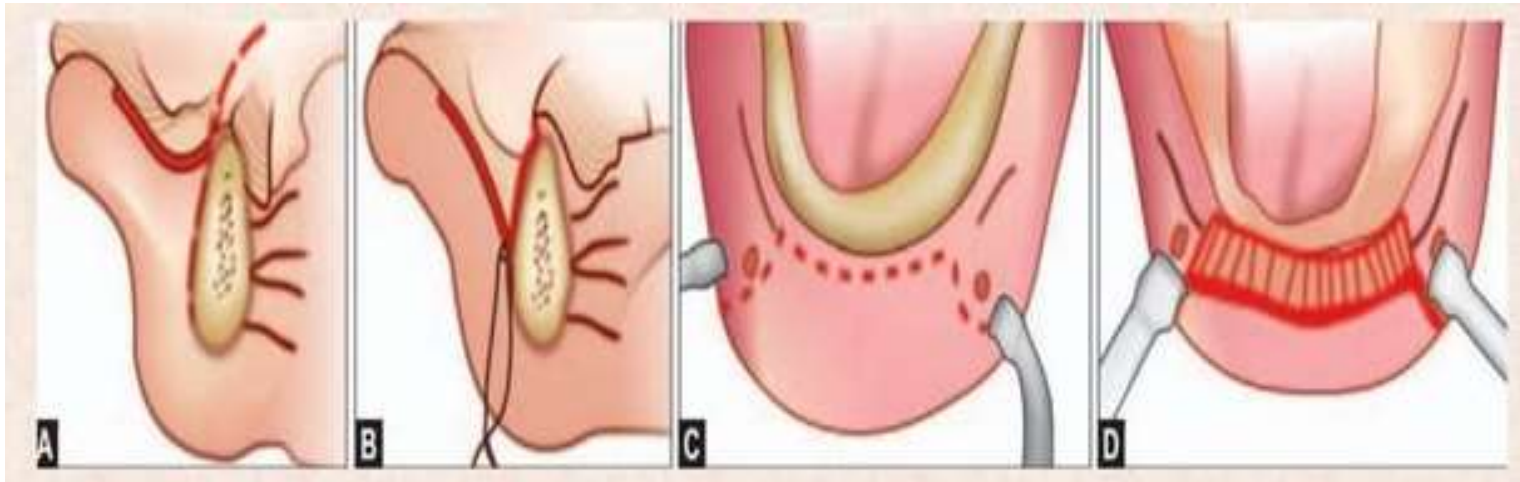


GODWIN'S MODIFICATION:

- ◆ In this procedure, flap is reflected from the inner aspect of the lip till the alveolar crest and periosteum is reflected from crest of the ridge till the desired depth of the vestibule.
- ◆ This periosteum is now sutured to the lip mucosal margin and then lip flap is sutured at the required vestibular depth.
- ◆ Stent or splint is used for adaptation.
- ◆ Advantage: less scaring of the lip mucosa.

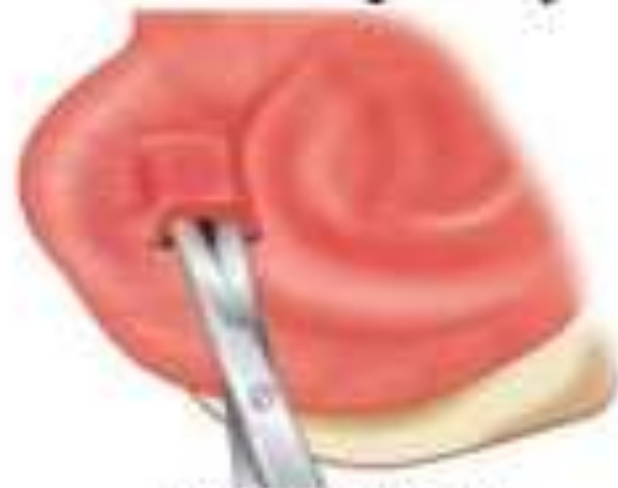CLARK'S TECHNIQUE:

- ◆ Here flap is reflected from alveolar crest till vermilion border of the lip.
- ◆ Supraperiosteal dissection is done till desired vestibular depth and edge of the mobilized flap is pushed into vestibular depth.
- ◆ This flap is held in position with sutures passed through the chin area extraorally and tied around the rubber catheter.
- ◆ Here alveolar bone is covered by periosteum which heals quickly by granulation.

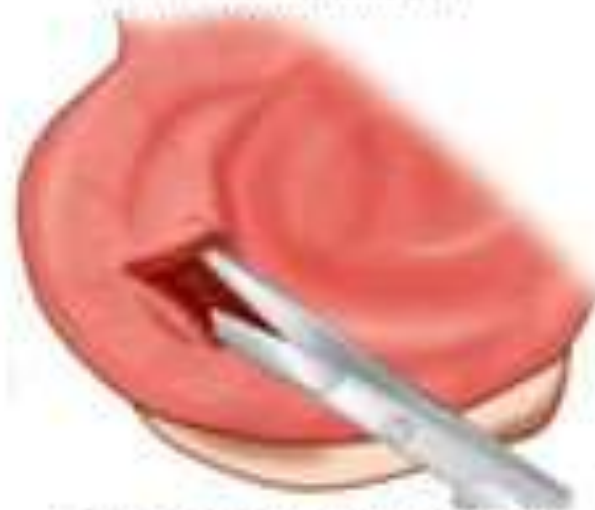

Obwegeser's Submucous Vestibuloplasty

- Macintosh & *Obwegeser* 1959
- Closed submucosal vestibuloplasty
- Applicable to the entire maxillary sulcus and anterior mandibular sulcus
- Can be performed with local anesthesia
- A **vertical incision** is made, extending from the **mucogingival junction**
- **Blunt spreading dissection** carried out
- A tunnel is formed between the mucosa and the submucosa, till zygomatic buttresses on either side



Incision in vestibule



Blunt dissection by scissors;

LABIAL VESTIBULOPLASTY (MAXILLARY RIDGE)

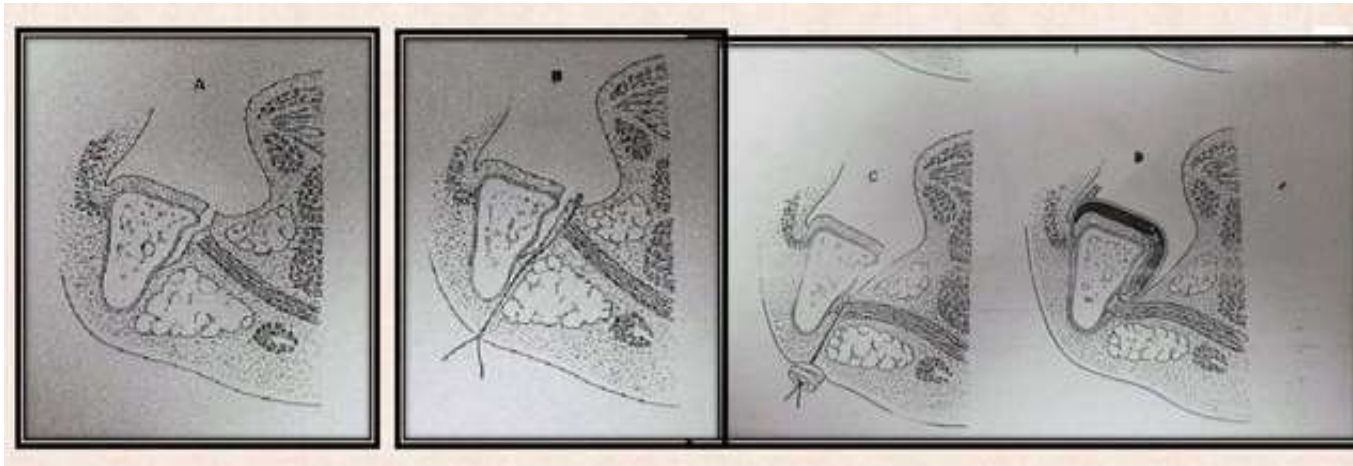
Maxillary pocket-inlay vestibuloplasty:

- ◆ Here incision is made in the vestibule from molar to molar region and supraperiosteal dissection is carried out.
- ◆ Now a split thickness graft is placed on the extended flanges of prefabricated denture and this denture is positioned in extended vestibular depth which is fixed with circumzygomatic wiring.
- ◆ Wound margins are sutured to the graft. New denture will be constructed after 6 weeks.
- ◆ Advantages: Better retention of the dentures.
- ◆ Helps to restore deficiency in the region of nasolabial fold with improved contour.

LINGUAL VESTIBULOPLASTY

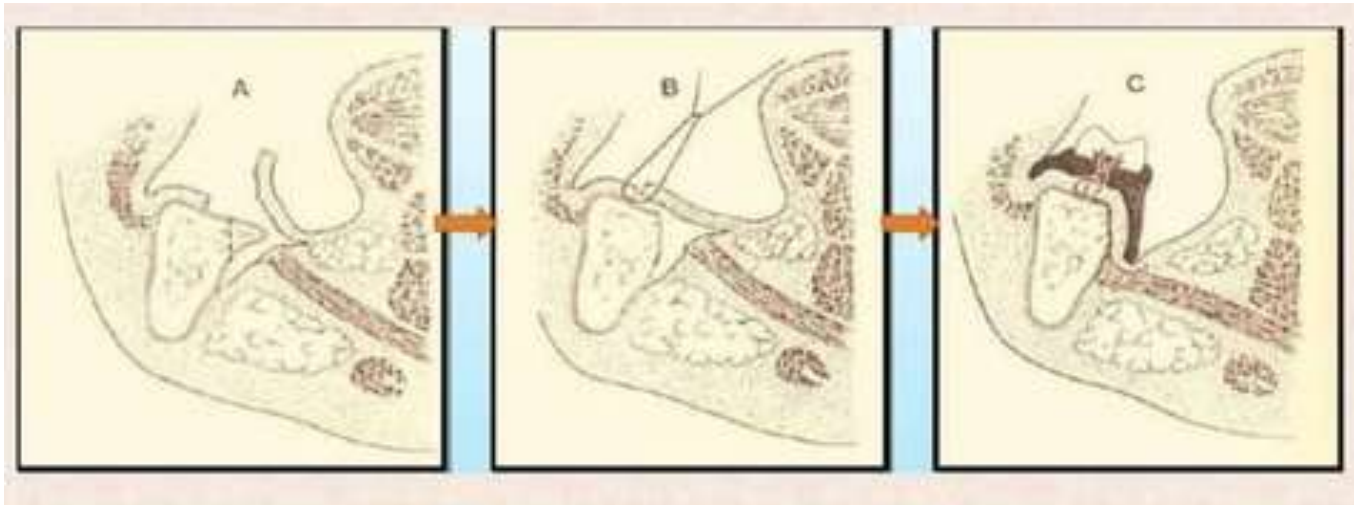
Trauner's Technique:

- ◆ This procedure is used to increase the depth of floor of the mouth in mylohyoid region.
- ◆ Incision is given over lingual side of the alveolar ridge
- ◆ bilaterally in posterior region (2nd molar region). Supraperiosteal dissection is done to identify mylohyoid muscle, which is separated from its attachment and sutured to the new desired vestibular depth.
- ◆ Skin graft is placed and sutured with the prefabricated stent over it.



Caldwell's Technique:

- ◆ Entire lingual mucoperiosteal flap is reflected from molar to molar region.
- ◆ Mylohyoid and genioglossus muscle attachments are dissected and sutured below to the desired depth of the vestibule.
- ◆ Rubber tubing is placed in the lingual vestibule and the flap is held in place at desired vestibular depth which is sutured with the sutures passing extra orally, at inferior border of the mandible.



MENTAL NERVE TRANSPOSITION

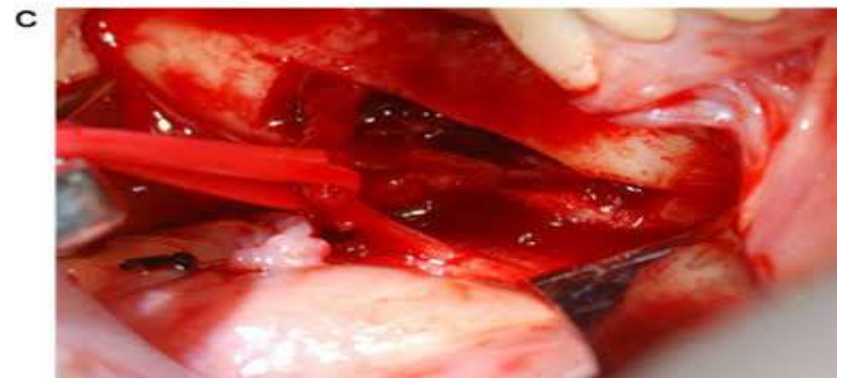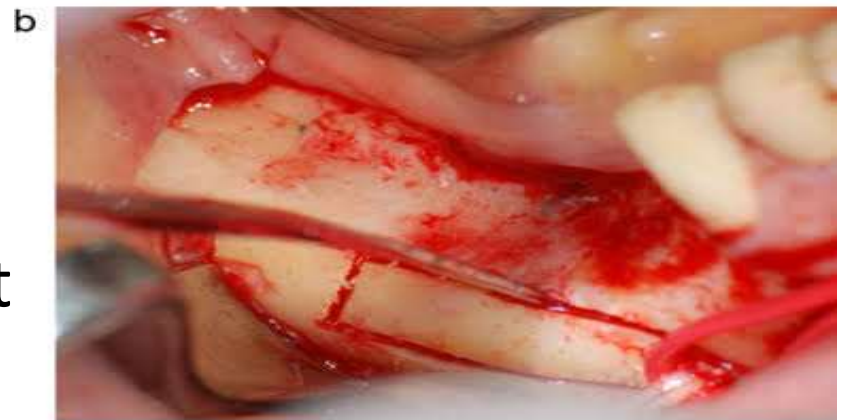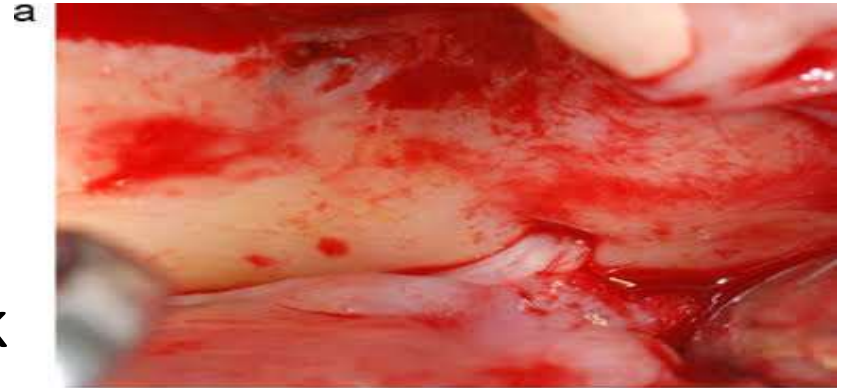- ◆ Many times patient with severe atrophic ridge, complaints of pain after wearing complete denture. This is because that the position of mental nerve is superior because of severe mandibular atrophy so this is the reason for pain on compression.

Procedure:

Here the flap is reflected on buccal aspect in the mental nerve region.

The nerve is held with the hook lightly and a bony groove is cut below mental foramen only in buccal cortex.

Then nerve is positioned in that groove secured in place with gelfoam and flap is sutured.



III. ALVEOLAR RIDGE AUGMENTATION

This procedure is done when alveolar bone has been completely disappeared to the point where in maxilla a flat surface is present between vestibule and palate and in mandible mental nerve is positioned almost at the crest. Here alveolar bone height is less than 15 mm.

So vestibuloplasty is out of consideration in this case until the replacement of necessary supportive bone is done.

So we have two options available with us :

- a) Augmentation of alveolar bone.
- b) Place the implant.

AIMS:

Restoration of optimum ridge height, width, ridge form, vestibular depth and optimum denture bearing area.

Protection of neurovascular bundle.

Establishment of proper interarch relationship

Improvement of retention and stability of denture.

Improve the patient comfort for wearing the denture.

MATERIALS USED FOR RIDGE

AUGMENTATION:

1. Autogeneous bone graft: iliac crest, rib grafts.
2. Allogenic bone grafts: freeze dried cadaver bone.
3. Alloplastic material: hydroxyapatite.
4. Metal mesh with autogenous cancellous bone.
4. Metal mesh with hydroxyapatite.

RIDGE AUGMENTATION PROCEDURE

1. Superior border augmentation
2. Inferior border augmentation
3. Interpositional or sandwich bone grafts.
4. Onlay grafting
5. Visor osteotomy
6. Modified visor osteotomy

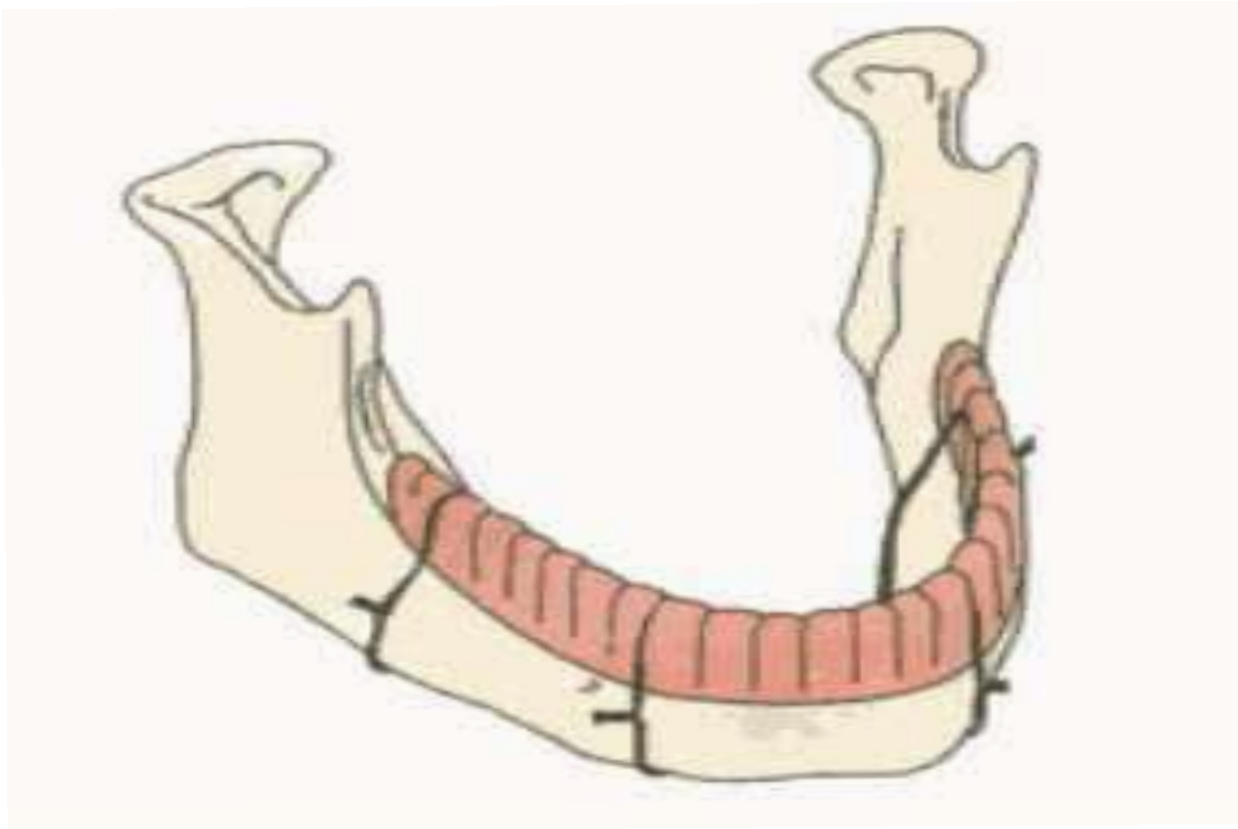
MANDIBULAR AUGMENTATION

Superior border grafting:

- ◆ First described by Davis in 1970.
- ◆ Remaining bone < 10 mm
- ◆ Here two autogenous bone grafts of 15 cm each are used.
- ◆ One rib is scored to the cortex followed by giving shape of the mandible and attached at the superior border of the mandible by circummandibular wiring,
- ◆ The other rib graft is made into corticocancellous particles and moulded around the first rib graft.
- ◆ Surgical flap is then closed.

Disadvantages-

- ◆ Donor site morbidity.
- ◆ Second surgical site is necessary. Continued resorption at the graft sites



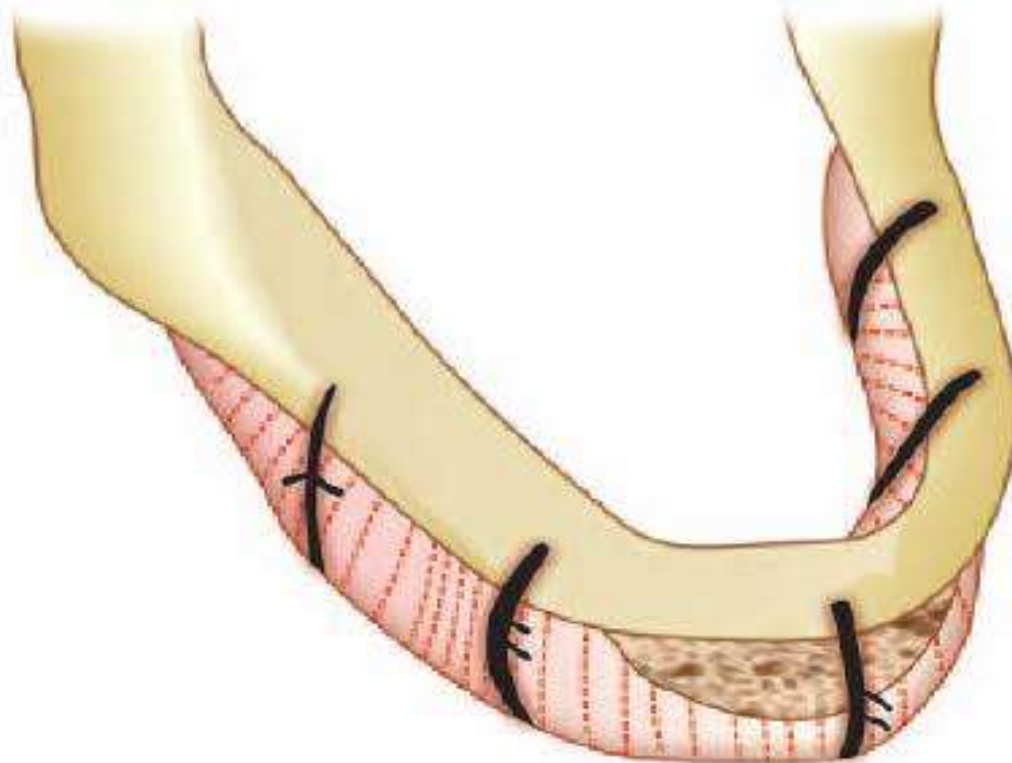
INFERIOR BORDER GRAFTING:

This procedure is indicated when alveolar ridge height is less than 5 to 8mm and is at risk of pathological fracture. In this procedure, a cadaver mandible used for grafting which is filled with cancellous graft material for revascularization. This mandible is then fixed to the inferior border with vicryl sutures, by circummandibular fixation and neck flap is closed.

Osseointegrated implants can be placed after 4-6 months.

Advantages

- ◆ Does not obliterate the vestibule.
- ◆ Interim denture can be worn.
- ◆ No change in vertical dimension.
- ◆ Graft is not subjected to direct masticatory force.



Disadvantages:

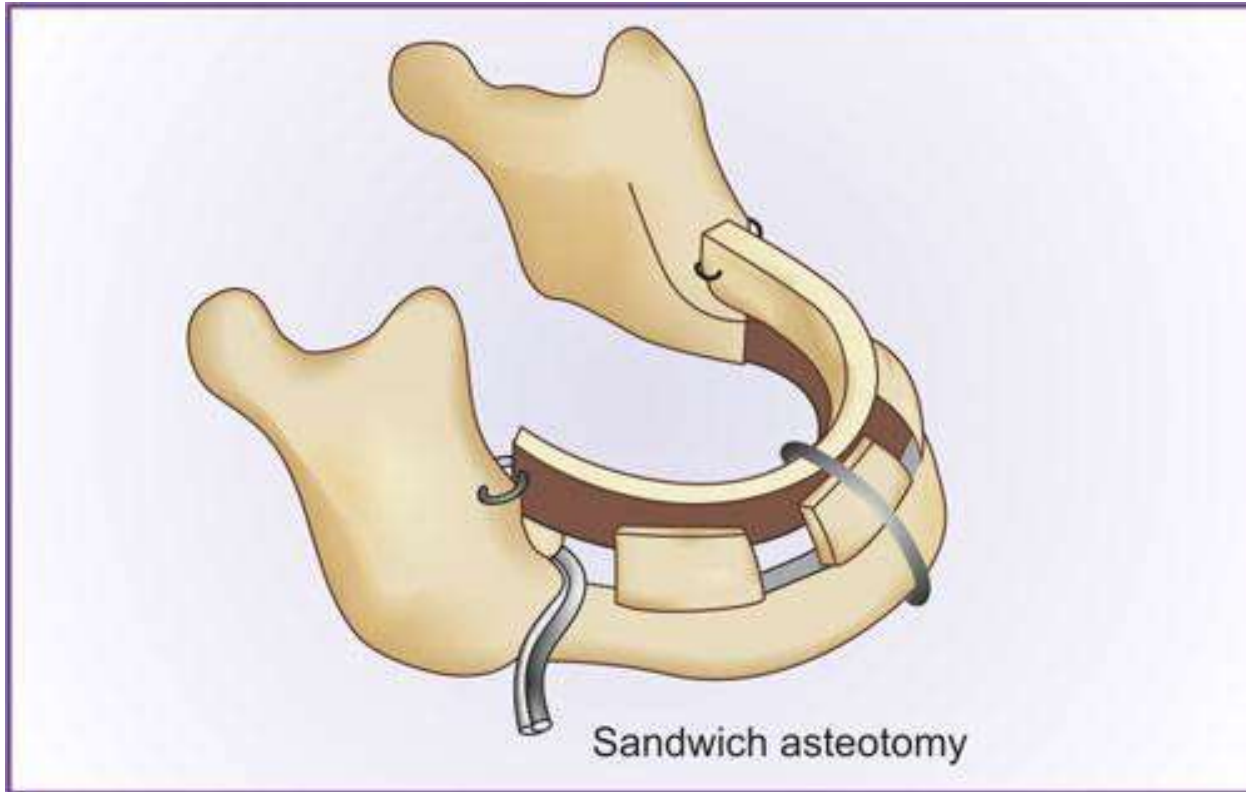
- ◆ It will not correct the abnormalities of denture bearing area.
- ◆ It will not protect a highly placed mental nerve.
- ◆ Donor site morbidity.
- ◆ Resorption of the graft.
- ◆ Presence of scar.

INTERPOSITIONAL BONE GRAFT (SANDWICH GRAFTING)

- ◆ In this procedure, a horizontal osteotomy is performed by splitting of the maxilla or mandible and bone is grafted in the gap.
- ◆ In mandible, this procedure is mainly used in anterior mandible.
- ◆ Prosthetic appliance is given after 3-5 months.

Advantages:

- ◆ Less resorption than onlay grafting.
- ◆ More predictable long term results.
- ◆ Decreased incidence of nerve paresthesia than the visor osteotomy.
- ◆ Can be used in conjunction with implants.

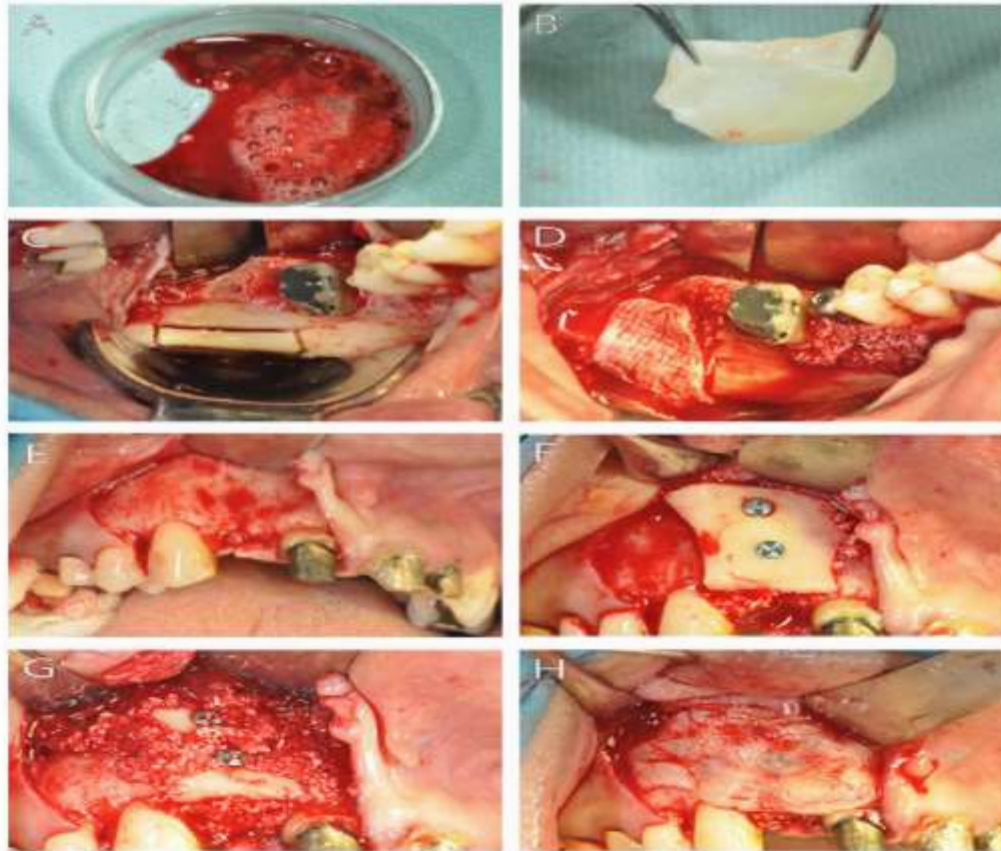


ONLAY GRAFTING

- ◆ This procedure helps in increasing width of the ridge. Here graft material is placed on the buccal cortex either in putty form by mixing with saline/blood or in the form of blocks or split thickness rib/iliac crest graft.

Advantages:

- ◆ Improves width and to some extent height too. Can be used in anterior and posterior region.



Onlay bone graft augmentation technique: the main steps. (A) Bio-Oss saturated with platelet-rich plasma (PRP) and human thrombin. (B) Platelet-poor plasma (PPP) used as biological membrane. (C) Donor site (right mandibular ramus) prior to block separation. (D) Donor site (right mandibular ramus) filled with combination of Bio-Oss and PRP covered by PPP. (E) Bone defect at recipient site (right maxillary lateral incisor). (F) The harvested autologous bone block graft fixed to the recipient site. (G) The harvested autologous bone block graft at the recipient site, with gaps between graft and recipient bed filled with combination of Bio-Oss and PRP. (H) The entire augmented site covered by PPP.

VISOR OSTEOTOMY

- ◆ Was originated by Harle and modified by Peterson and Slade.
- ◆ It is used where insufficient vertical mandibular bone height is present for the horizontal osteotomy technique but adequate bone width (approximately 10mm) is present.

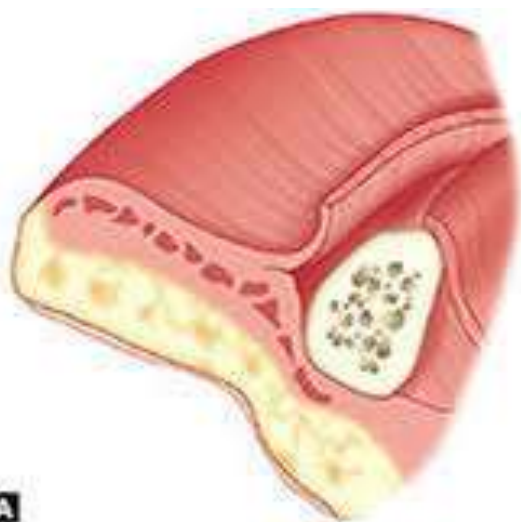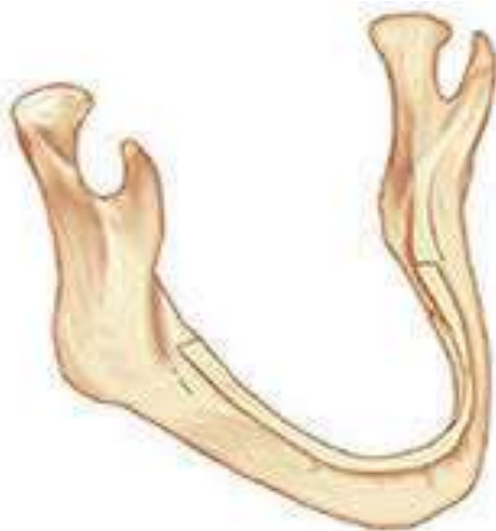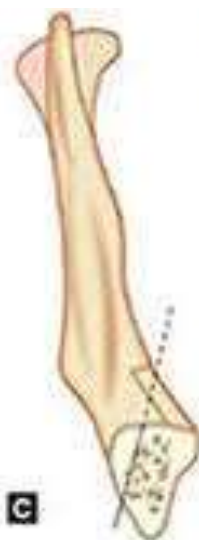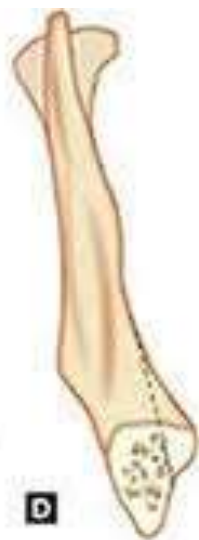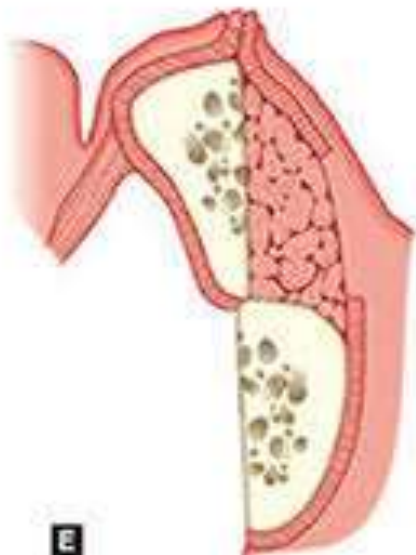
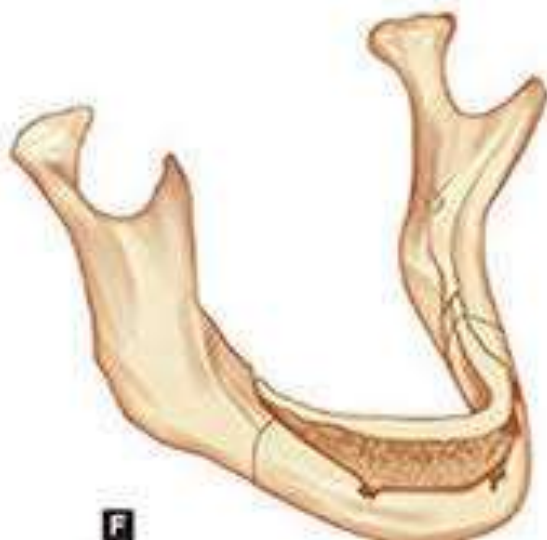- ◆ The mandible is split vertically and the lingual section is elevated to increase the mandibular height. Cancellous bone or particulate bone and marrow is placed to correct the contours and fill in the gaps on
- ◆ the facial side of the elevated segment.
- ◆ Transosteal wires hold the segments in place for a period of 3-4 months before vestibuloplasties are performed.
- ◆ The disadvantage is unavoidable nerve trauma and the resultant parasthesia.

MODIFIED VISOR OSTEOTOMY

- ◆ The procedures of choice for mandibular ridge augmentation include the combination of osteotomy techniques (horizontal or vertical) with interpositional bone grafting.
- ◆ These procedures involve the movement of a pedicle of bone (not technically a graft) along with its blood supply.
- ◆ Theoretically, the viability of the bone will be greater and the resorption decreased because the blood supply to the bone is maintained.

Procedure:

- ◆ Vertical osteotomy cut is made in the posterior region to divide the segments buccolingually.
- ◆ A horizontal osteotomy is performed in the anterior mandible to divide the anterior segment superiorly and inferiorly, and bone grafting was done into the osteotomised gap.
- ◆ Two osteotomised segments are fixed with wires.

**A****B****C****D****E****F**

Advantages:

- ◆ Increased bone height which is relatively stable.
Shortened post-operative period (3 months).
- ◆ Rate of resorption is less when compared to onlay grafts.

Disadvantages:

- ◆ Nerve trauma
- ◆ Parasthesia
- ◆ Mandibular fracture
- ◆ Flap dehiscence.

PROBLEMS ENCOUNTERED WITH **AUGMENTION PROCEDURE**

1. Inadequate soft tissue cover.
2. Rejection of the auto grafts (failure of union with the host bone)
3. Dehiscence of overlying mucosa.
4. Migration of the graft material.
5. Resorption of the graft.

CONCLUSION

- ◆ Accurate diagnosis of the problem areas during denture construction and determination of the necessity of surgery is accomplished by careful evaluation of the information systematically obtained from the patient.
- ◆ As conservation is the philosophy of surgical patient management. Therefore every attempt should be made to preserve as much as oral structures as possible.
- ◆ Proper knowledge of the available surgical procedures helps in achieving the best results.

**THANK
YOU**