

BITEWING RADIOGRAPHY

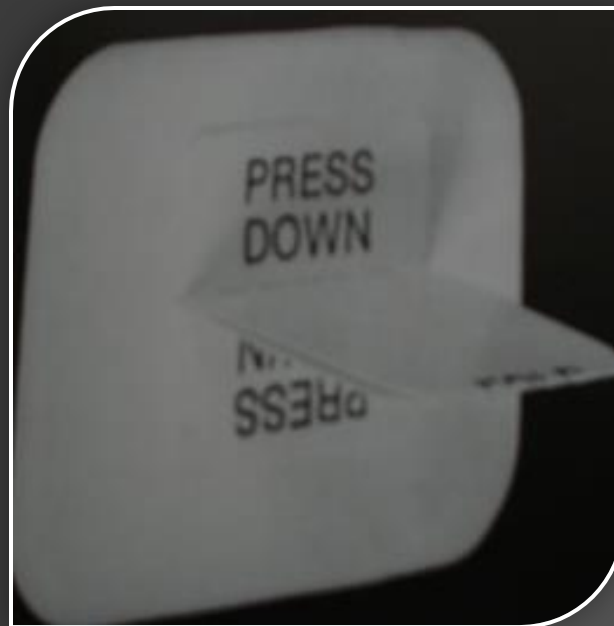Presented by:

Dr. Darshan R. Prasad Hiremutt

Post Graduate Student (Part-1)

Dept. Of Oral Medicine & Radiology

- Also called interproximal radiographs
- Take name from the original technique, which required the patient to bite on a small wing attached to an intra oral film packet.



Indications

- Detection of initial Dental caries.
- Monitoring the progression of dental caries.
- Assessment of overhangs in restorations.
- Assessment of periodontal status.
- Detection of secondary dental caries especially, at the pulpal and cervical floor.
- To study proximity of carious lesions to pulp.
- Detection of early periodontal disease
- Detection of calculus on proximal surface.
- To know occlusal relationship.

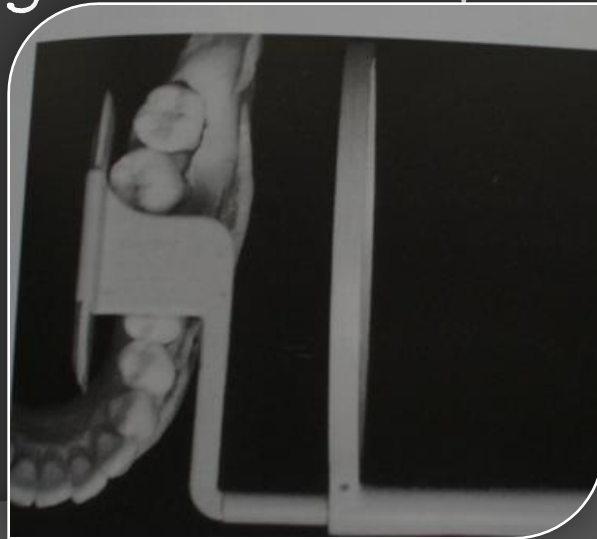Principle

- The film is placed in the mouth parallel to the crowns of both upper and lower teeth.
- The film is stabilized when the patient bites on the bitewing tab or bitewing holder.
- The central ray of the x-ray beam is directed through the contacts of the teeth using + 10° vertical angulation.


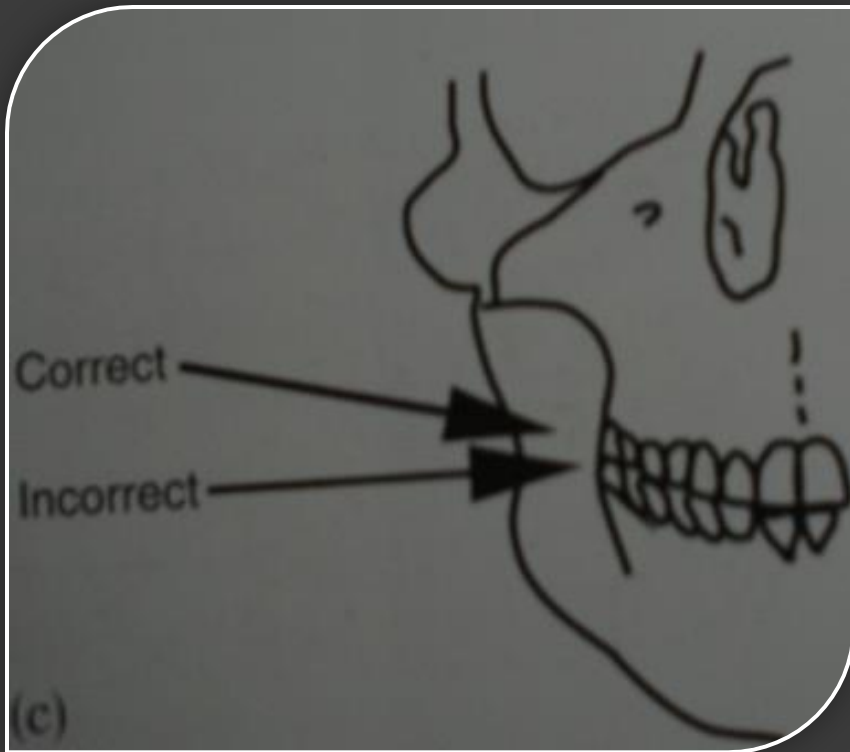
Ideal Technique Requirement

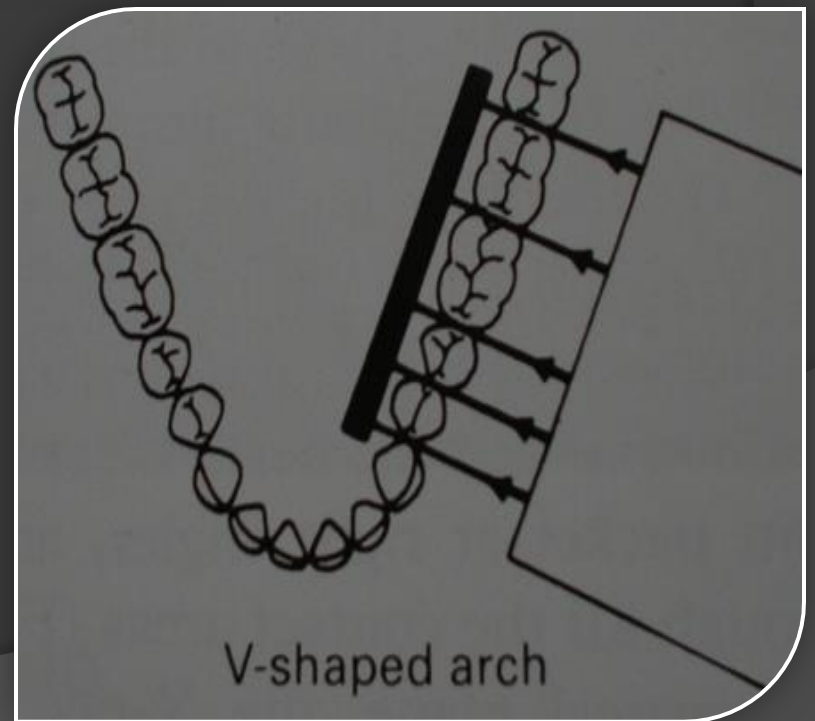
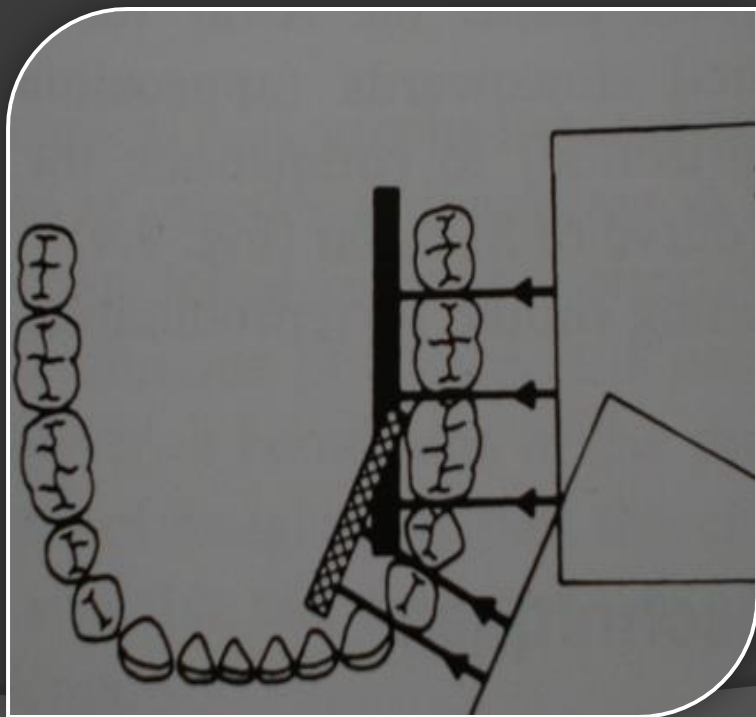
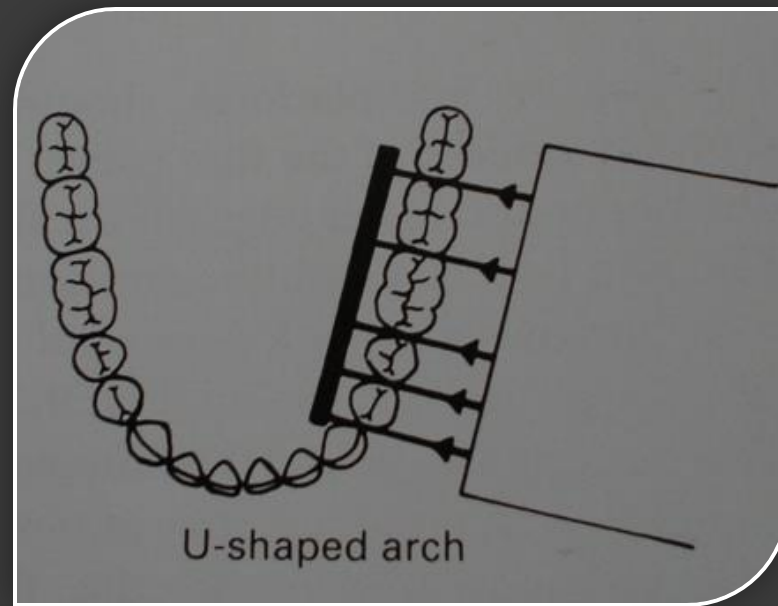
- The tab or bite platform should be positioned on the middle of the film packet and parallel to the upper and lower edges of the film packet.
- The film packet should be positioned with its long axis horizontally for a horizontal bitewing or vertically for a vertical bitewing.
- The posterior teeth and film packet should be in contact or as close together as possible.
- The posterior teeth and film packet should be parallel to the shape of dental arch.

- ⦿ This may necessitate 2 separate film positions to achieve this requirement for the premolar and the molars.
- ⦿ In horizontal plane, the x-ray tube head should be aimed downwards (approximately $5-8^{\circ}$ to the horizontal) to compensate for the upwardly using curve of Monson.
- ⦿ The positioning should be reproducible.



Proper Angulation






Film Holder and Bitewing Tabs


◎ Rinn XCP Bitewing instruments:

- These include plastic bite blocks, plastic aiming rings, and metal indicator arms.
- These film holders are reusable and must be sterilized following use.
- These holders include aiming rings that aid in alignment of the PID and collimators that significantly reduce the amount of radiation exposure.
- These instruments are simple to position and easy to sterilize

Film holders for horizontal bitewing



Film holder for vertical bitewings



Bitewing Tabs

- As an alternative to a film holding device, a film can be fitted with a bitewing tab (also called bite loop/ bite tab).
- The bitewing tab is a heavy paperboard tab or loop fitted around a periapical film and used to stabilize the film during exposure.


- A bitewing film is a periapical film that has been fitted with a bite tab.
- The periapical film is in the bite loop so that the tab portion extends from the white side (tube side) of the film.
- Available with tabs attached to the film or they may be constructed from a periapical film and bitewing tab.
- Bite loops are available in various sizes; adhesive bite tabs are also available.

Film

- Size 0: It is used to examine posterior teeth in children with primary dentitions. This film is always placed with long portion of the film in horizontal direction.
- Size 1: It is used to examine post technique in children with mixed dentitions.
 - In the posterior regions, size 1 film is always placed with the long portion of the film in horizontal direction.
 - Can also be used to examine the anterior teeth of adults (in vertical bitewing exposures). Here film is always placed with long portion of the film in a vertical direction.

- Size 2: : It is used to examine the posterior teeth in adults .
- Size 3 film: Is longer & narrower than the standard size 2 film.
- In adults, size 2 film is recommended for bitewing exposures. Size 3 film is not recommended. With size 3 film overlapped contacts result because of the difference in curvature of arch between premolars and molars.
- In addition, crestal bone areas may not be adequately seen on radiographs of patients with bone loss because of narrow shape of the film

vertical and horizontal tabs



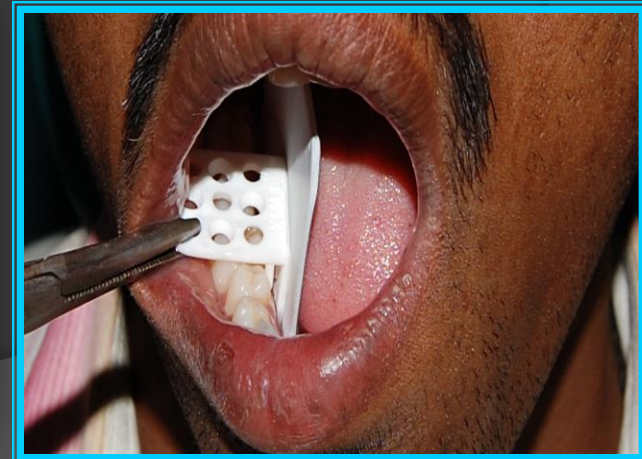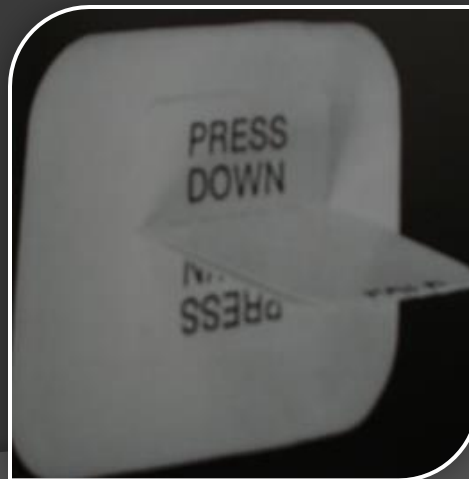
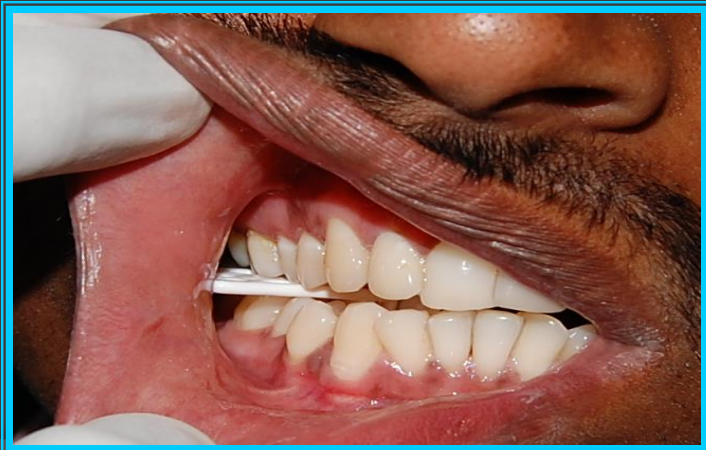Positioning Technique

Two techniques

- using a tab attached to the film packed and aligning the x-ray tube head by eye.
- using a film packet holder with beam aiming device to facilitate the positioning and alignment of x-ray tube head.

Using a tab attached to the film packet

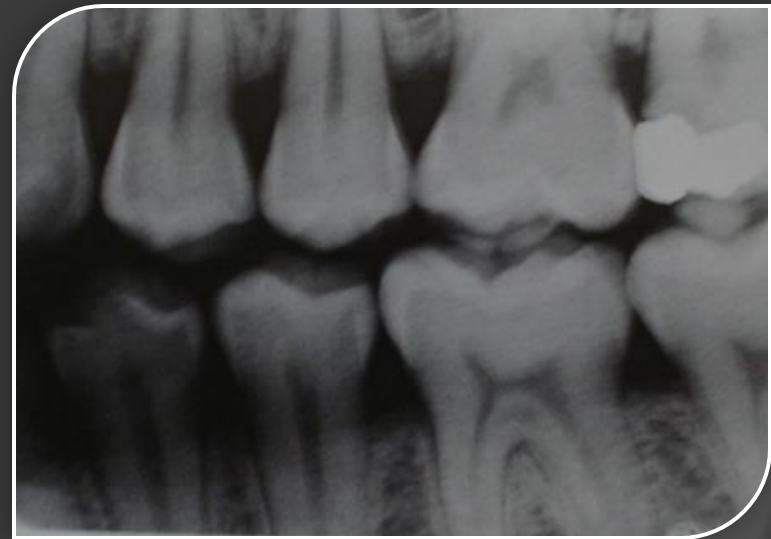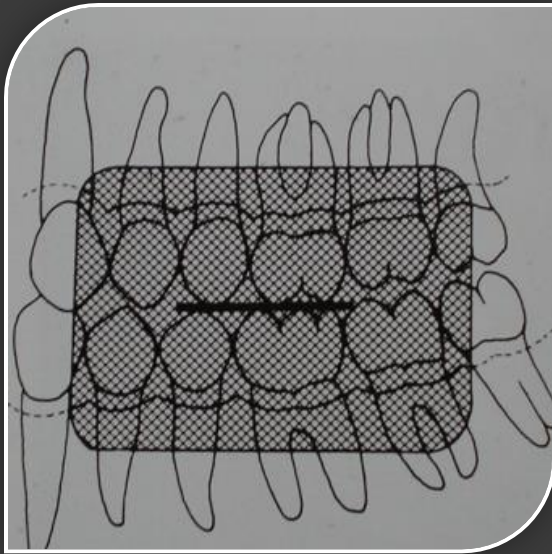
- The appropriate size films are selected and the tab is attached.
- Patient position : Similar to paralleling cone technique.
- Placement of the image receptor :
 - The operator holds the tab between thumb & forefinger & inserts the film packet into the lingual sulcus opposite the posterior teeth.



- The film must be positioned parallel to the crowns of the upper and lower teeth.
- The film must be stabilized when the patient bites on bitewing tab or bitewing holder.
- Vertical bitewings : usually used when the patient has moderate to extensive alveolar bone loss.
- Orientation of the film vertically increases the likelihood of viewing remaining alveolar crests.
- As the patient closes the teeth, the operator pulls the tab firmly between teeth to ensure that the film packet and teeth are in contact.
- The operator releases the tab.

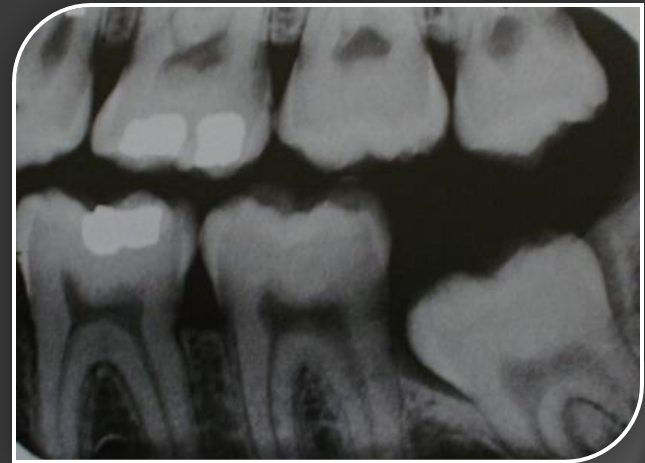
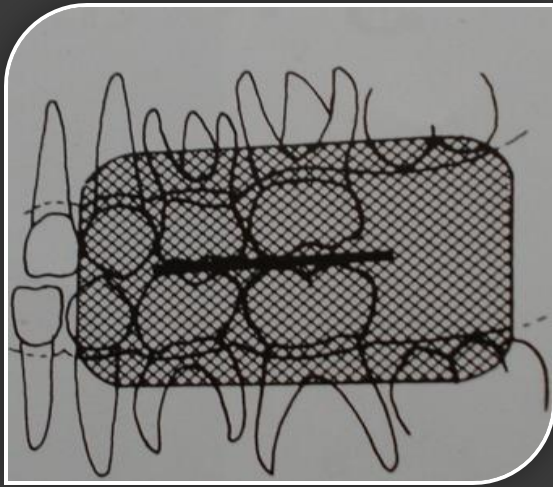
1) For the premolar projection :

- Anterior edge of the receptor should cover the distal half of mandibular canine.



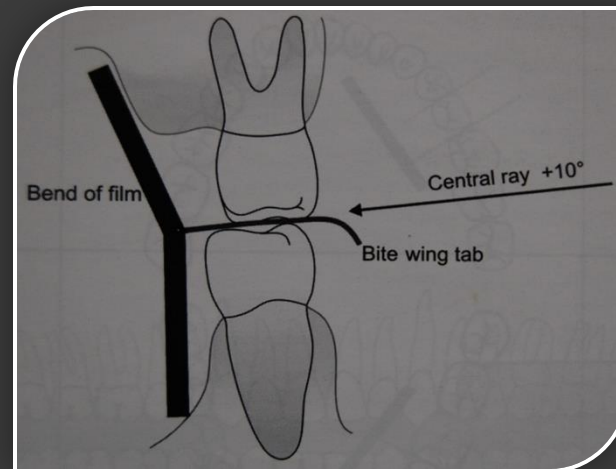
ii) For molar projection :

- The receptor should cover the distal half of the 2nd mandibular premolar. The molar bitewing is placed 1 or 2 mm beyond the most distally erupted molar (maxillary or mandibular).



- Direction of central Ray : The x-ray beam is aimed directly through the contact areas, at right angles to the teeth and the film packet, with an approximate 7° to $+10^{\circ}$ downward vertical angulations.
- This slight positive angulation is given when maxillary teeth are chief concern. This precludes cuspal overlaps.

- Centering point : For molar projections, central ray showed enter the proximal contact between 1st and 2nd molars at the level of the occlusal plane. To help prevent cone cutting, the central ray is directed towards the center of the bitewing tab, with protrudes to the buccal side.



Exposure parameters :

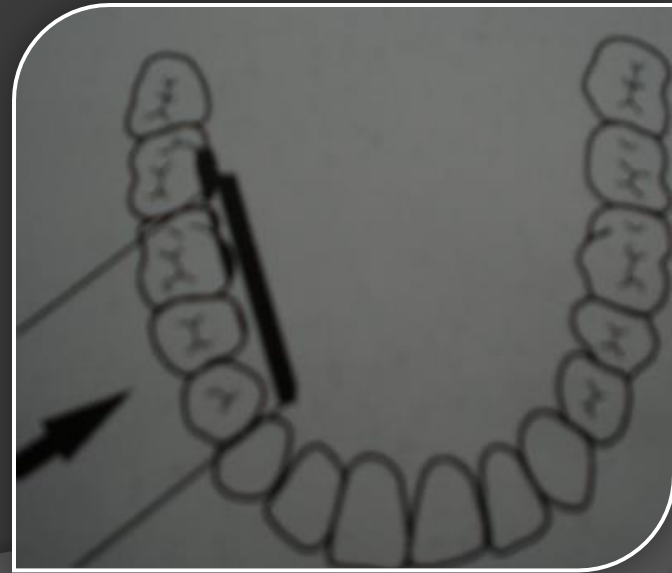
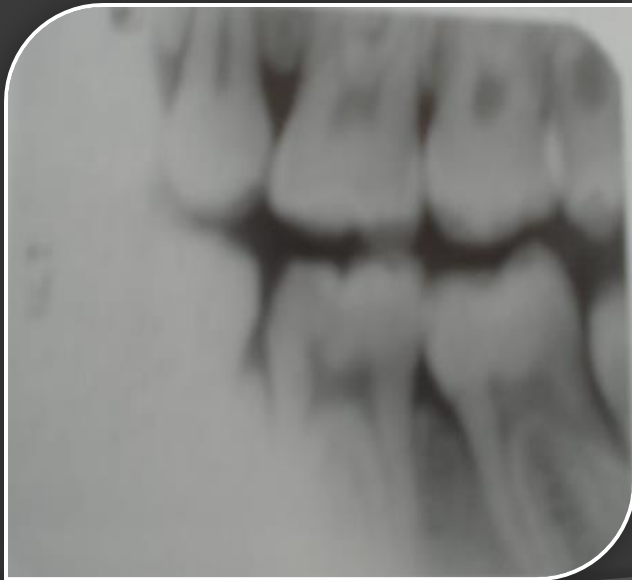- Tube voltage : 65 kVp.
- Tube current : 10 mA
- Exposure time : 0.3sec for Molar & Premolar projections.
0.2S for anterior projections.
- TID = 20 cm
- Type & size of film = Non - screen film, size 2 for molars and PM projections. Size 3 for combined projections, Size 1 or 2 for anterior projections or primary teeth

Advantages

- Simple
- Inexpensive
- The tabs are disposable, so no extra cross infection control procedures required.
- Can be used easily in children.

Disadvantages :

- ⦿ Arbitrary, operator dependent assessment of horizontal and vertical angulations of x-ray tube head.
- ⦿ Radiographs not accurately reproducible, so not suitable for monitoring the progression of caries.
- ⦿ Coning off or cone cutting of anterior part of film is common.
- ⦿ The tongue can easily displace the film packet.



Use simple film packet holders

- Several simple film holders have been produced. They can eliminate many of the disadvantages of the arbitrary tab method.
- Holders essentially consist of 3 basic components :
 - A mechanism for holding the film packet parallel to the teeth.
 - A bite platform that replaces the wing.
 - An x ray beam aiming device.

Advantages

- Simple
- Film packet held firmly in position and cannot be displaced by the tongue.
- Position of x ray tube head determined by the holder, hence less operator dependent, ensuring that x ray beam is always at right angle to the film packet.
- Avoids coning off or cone cutting of anterior part of the film.
- Holders are autoclavable or disposable.

Disadvantages

- Position of the holder in mouth is operator dependent, therefore not 100% reproducible, so still not ideal for monitoring progression of caries.
- Positioning of the film holder can be uncomfortable for the patient.
- Some holders are relatively expensive.
- Holders not suitable for children.

- Ideal exposure factors : The clinical reasons for taking a bitewing radiograph should determine the exposure factors that are used.

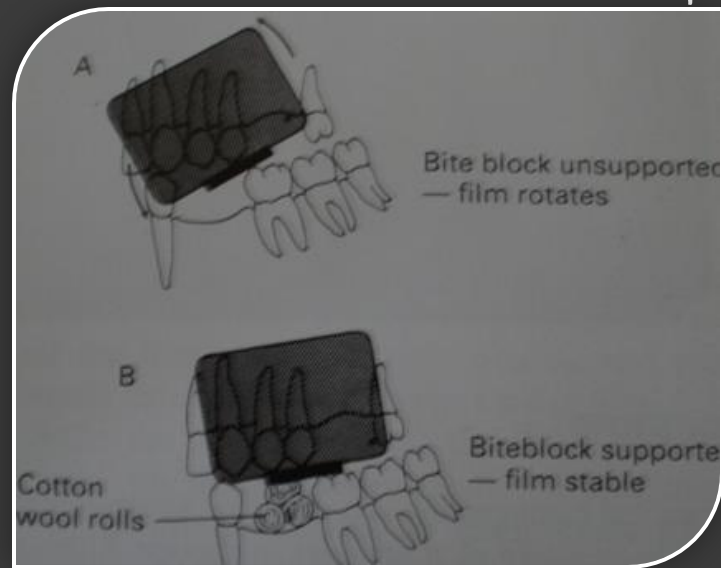
For eg :

- Assessment of caries and restorations : Films should be well exposed and show good contrast to allow differentiation between enamel & dentine and to allow the enamel → DEJ to be seen.
- Assessment of periodontal status : Films should be under-exposed to avoid burnout of the thin alveolar crestal bone.

- Number of bitewing radiographs required to cover the entire permanent dentition : Five
 - 2 premolar (Rt & Lt projections),
 - 2 molar (Rt & Lt),
 - 1 Anterior projection.

Modifications

- **Edentulous spaces:-** A cotton roll must be placed in the area of the missing teeth to support the bite wing tab.



- **Bony growths:-** The film must be placed b/w the tori and the tongue, not on the tori. In case the tori is large, bite wing holders are recommended

When the patient is in the working position.

1: Sagittal plane is central to longitudinal axis of chair and parallel to floor

2: Occlusal plane vertical



References

- Oral Radiology-White & Pharaoh -4th ed.
- Textbook of Dental & Maxillofacial Radiology - Freny R. Karjodkar
- Essential of Dental Radiography & Radiology- Eric Whaites (3rd Ed)
- Dental Radiology- Principles & Techniques (3rd Edition) -Harling & Jansen

THANK YOU

