

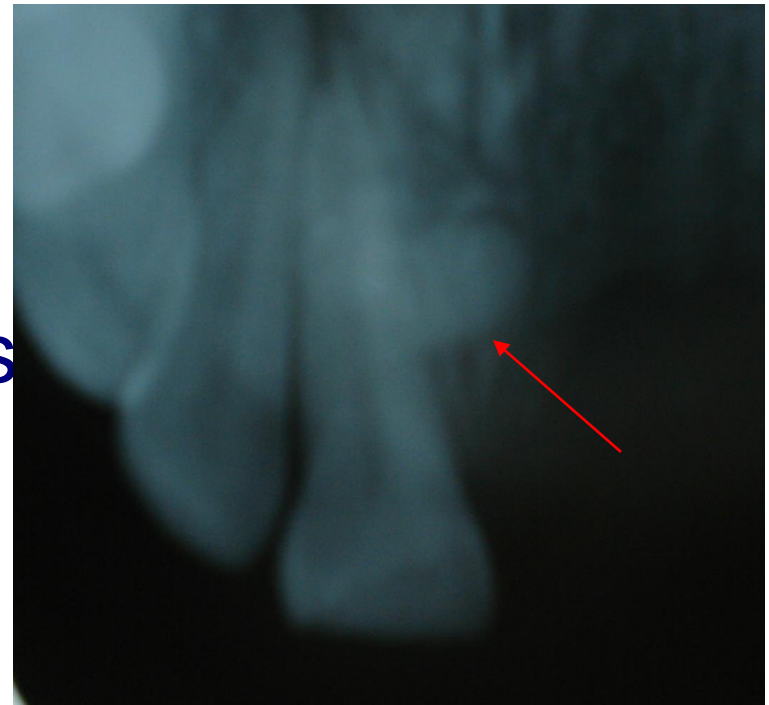
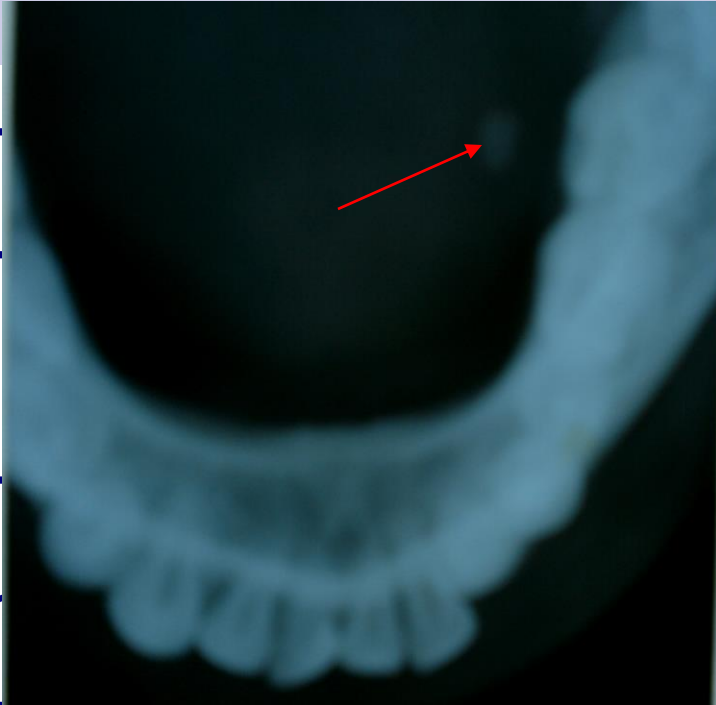


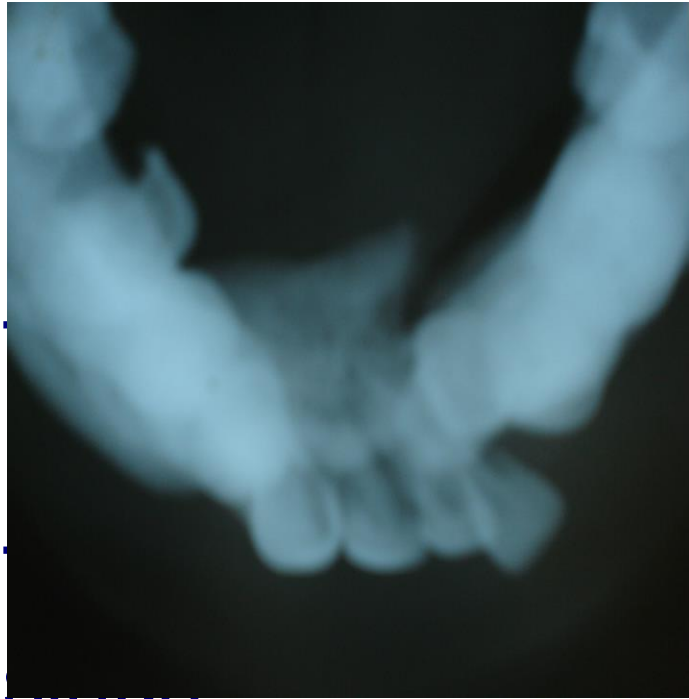Occlusal radiography techniques

Occlusal radiography is defined as those intraoral techniques used to inspect large areas of maxilla or mandible, taken using a dental x-ray set where the film packet of size 5.7x7.6 cm or a small intraoral cassette is placed in the occlusal plane.

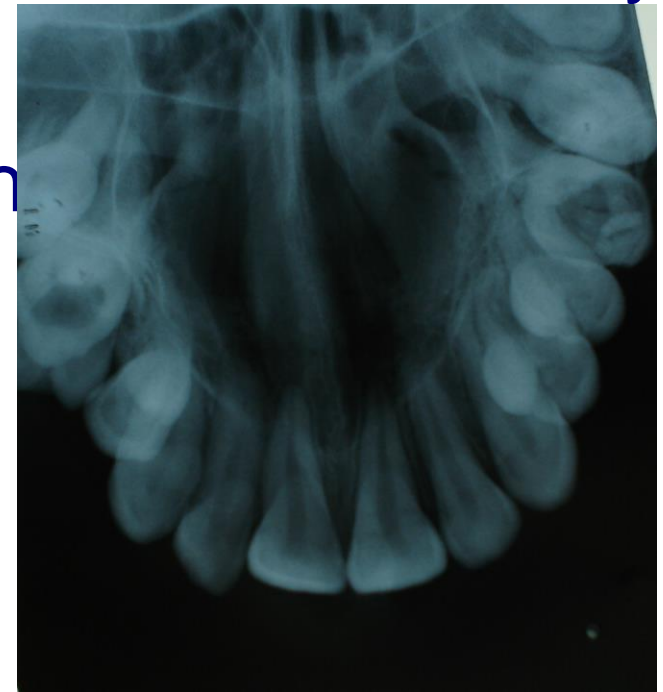
PURPOSE AND USE


- To locate roots of extracted teeth.
- To locate temporary, unerupted or impacted teeth.
- To locate foreign bodies.
- To locate salivary stones in the submandibular gland.





- To evaluate the extent of maxilla or mandible.
- To determine the boundaries of the maxillary sinus.
- To evaluate fractures of the maxilla or mandible.



- 
- To aid in the examination of patients who cannot open their mouth more than a few millimeters.
 - To examine the area of cleft palate.
 - To measure changes in the size & shape of maxilla or mandible.

PRINCIPLES

- The film is positioned with the white side facing the arch that is being exposed.
- The film is placed in the mouth between the Occlusal surface surfaces of the maxillary & mandibular teeth.
- The film is stabilized when the patient gently bites on the surface of the film.

MAXILLARY OCCLUSAL **PROJECTIONS:**


There are four different maxillary occlusal projections.


- Upper standard occlusal / topographic projection.
- Maxillary cross-sectional projection.
- Upper oblique occlusal.
- Vertex occlusal.

UPPER STANDARD / TOPOGRAPHIC PROJECTION.

Main clinical indications

- Periapical assessment of the upper anterior teeth.
- Detecting the presence of unerupted canines, supernumeraries and odontomes.

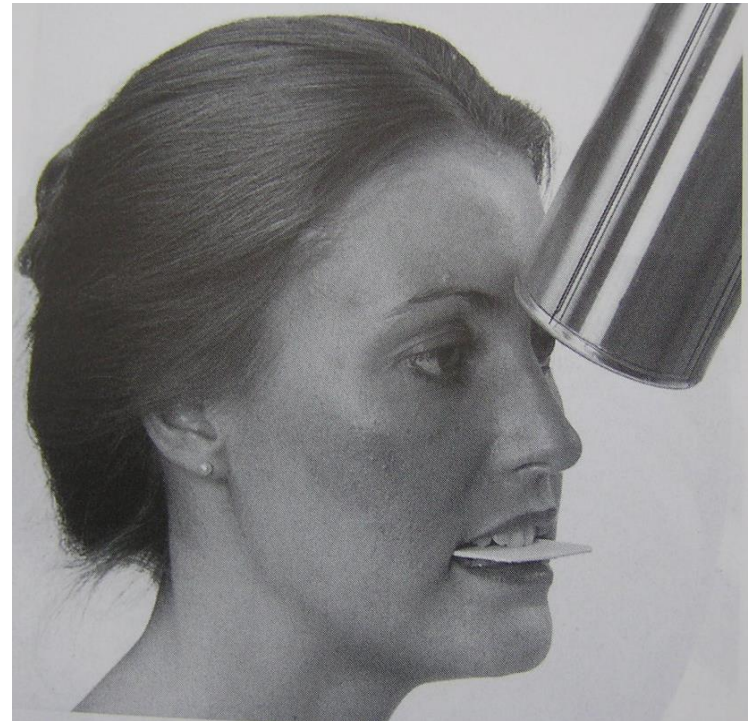- 
- As the midline view when using the parallax method for determining the bucco-palatal position of unerupted canines.
 - Evaluation of the size and extent of the lesions such as cysts or tumors in the anterior maxilla.

- 
- Assessment of fractures of the anterior teeth and alveolar bone. It is especially useful in children following trauma because film placement is straightforward.

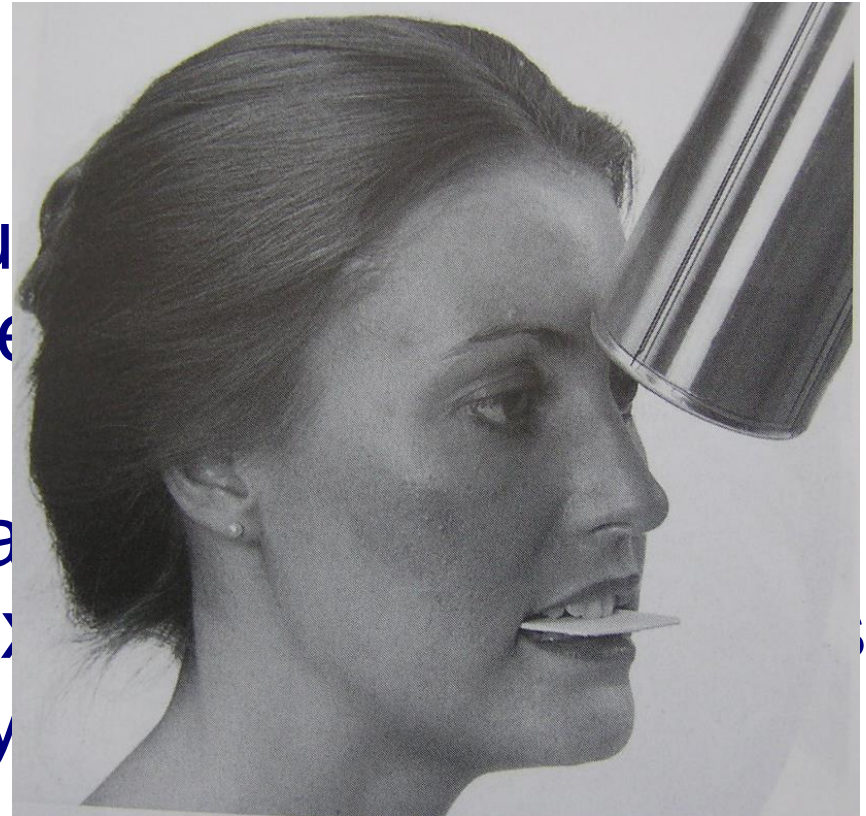UPPER STANDARD / **TOPOGRAPHIC PROJECTION.**

TECHNIQUE AND **POSITIONING**

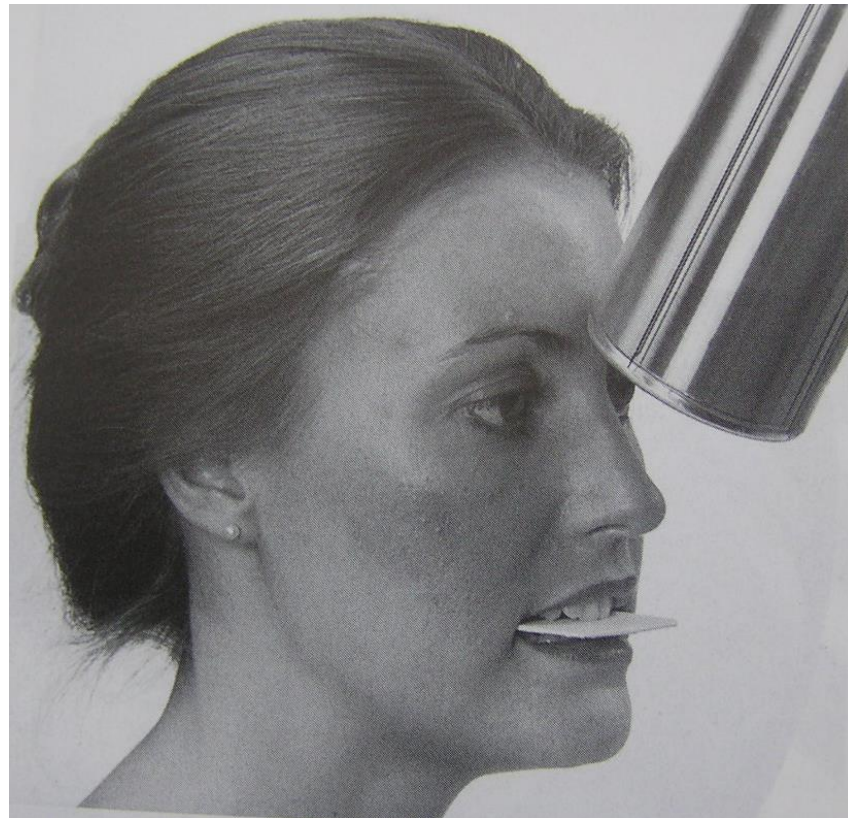- The patient is seated with the head supported and with the occlusal plane horizontal and parallel to the floor.



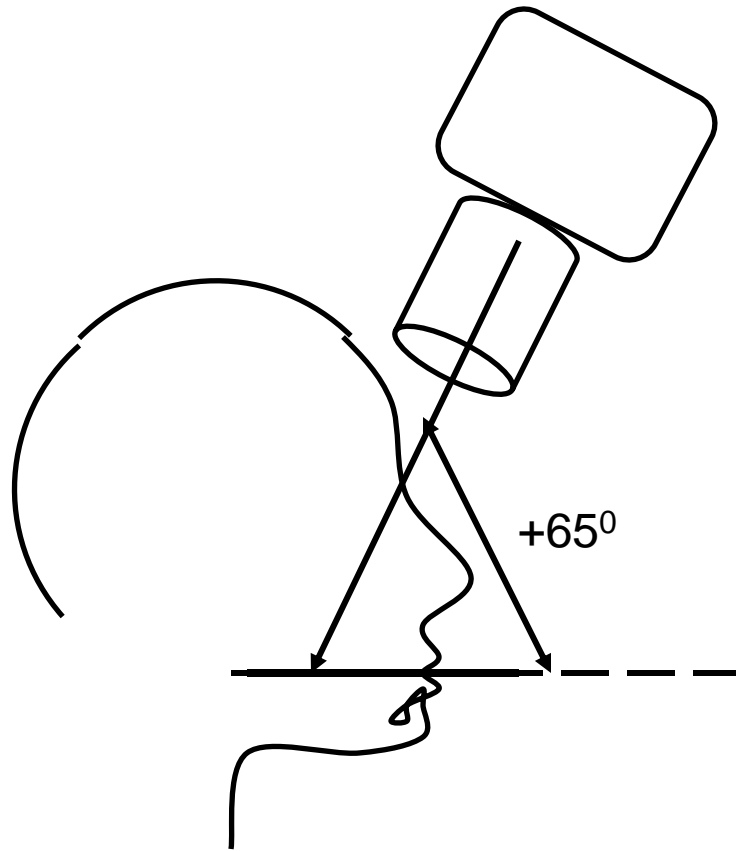
- The film packet, with the film facing uppermost, is placed in the patient's mouth onto the occlusal surface of the lower teeth. The patient is asked to bite together gently.
- The film packet is placed in the patient's mouth with its long axis parallel to the long axis and anteroposteriorly.




- Position the PID so that the central ray is directed through the midline of the arch towards the centre of the film.



- The x-ray tube is positioned above the patient in the midline, aiming downwards through the bridge of the nose at an angle of 65° - 70° to the film packet.

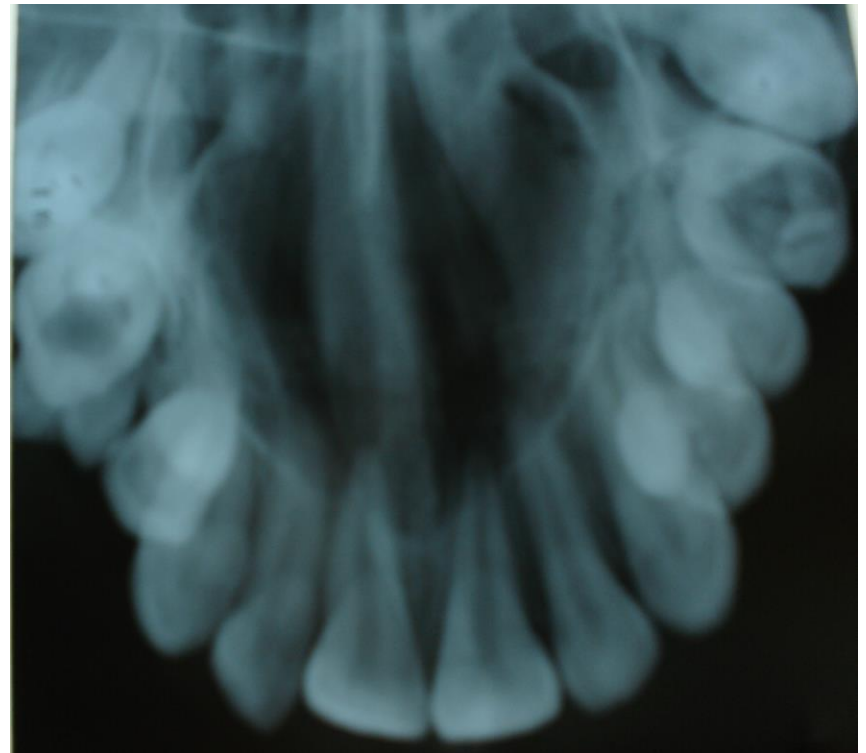


- 
- As recommended by Eastman Kodak Company, use the following exposure factors for E-speed film: 65 kVp, 10 mA, 15 impulses; or 90 kVp, 10 mA, 5 impulses.

CROSS SECTIONAL MAXILLARY **OCCLUSAL VIEW**

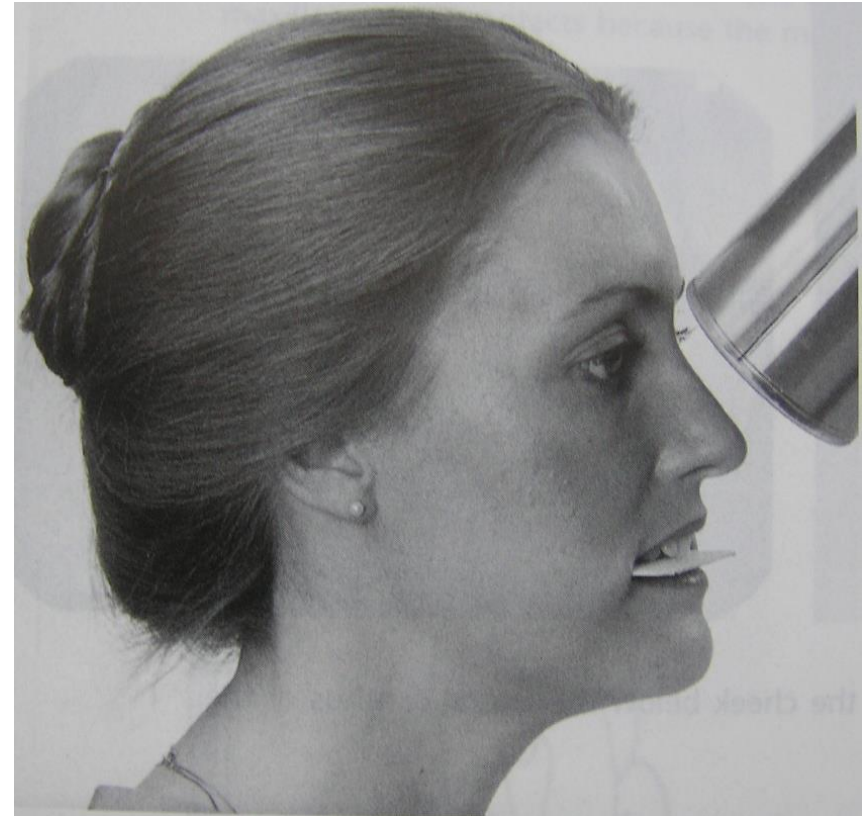IMAGE FIELD

- This projection shows the palate, the zygomatic processes of the maxilla, anteroinferior aspects of each antrum, nasolacrimal canals, teeth from second molar to second molar, and nasal septum.

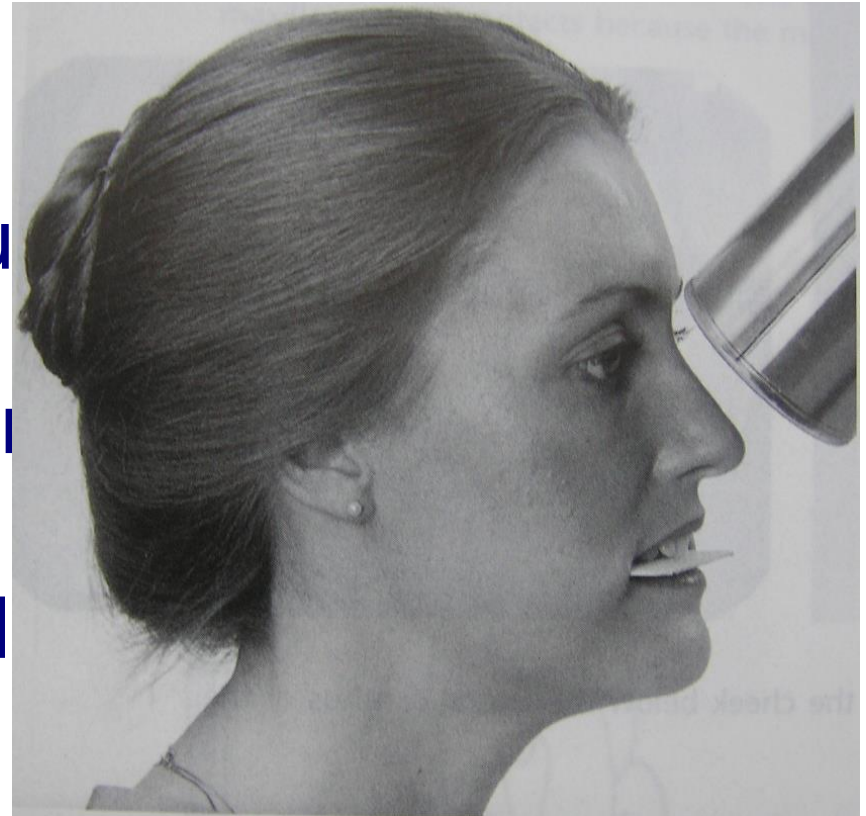

CROSS SECTIONAL MAXILLARY OCCLUSAL VIEW

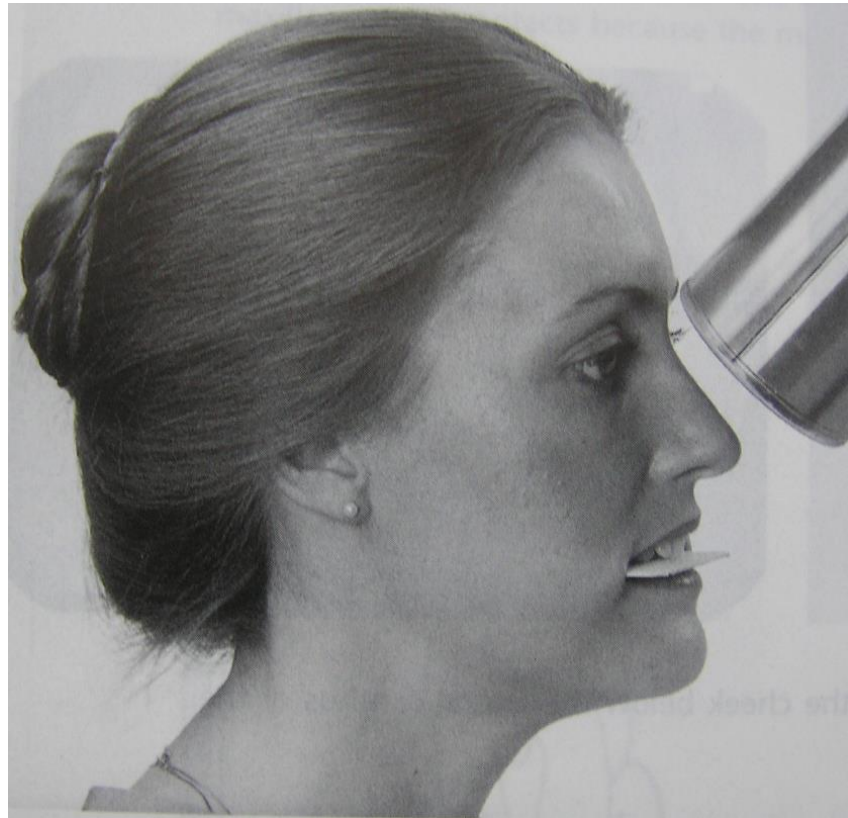
- **TECHNIQUE AND POSITIONING**
- The patient is seated with the head supported and with the occlusal plane horizontal and parallel to the floor.




- The film packet, with facing uppermost, is mouth onto the occlusal surface of the lower teeth. The film is held in place until it contacts the anterior surface of the mandibular rami.
- The patient is asked to bite gently.



- The central ray is directed at a vertical angulation of $+65^{\circ}$ and a horizontal angulation 0° towards the middle of the film.

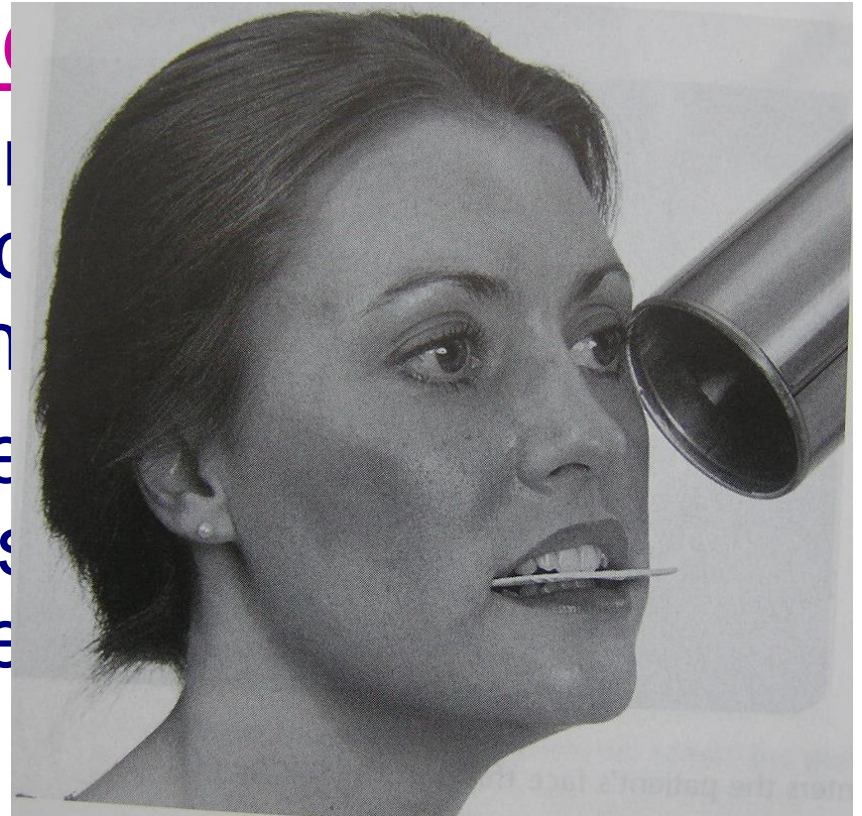


- 
- As recommended by Eastman Kodak Company, use the following exposure factors for E-speed film: 65 kVp, 10 Ma, 15 impulses; or 90 kVp, 10 mA, 5 impulses.

UPPER OBLIQUE OCCLUSAL

MAIN CLINICAL INDICATIONS

- Periapical assessment of teeth, especially in acute cases that do not tolerate periapical films
- Evaluation of the size of lesions such as cysts, tumors or osteodystrophies affecting the maxilla.

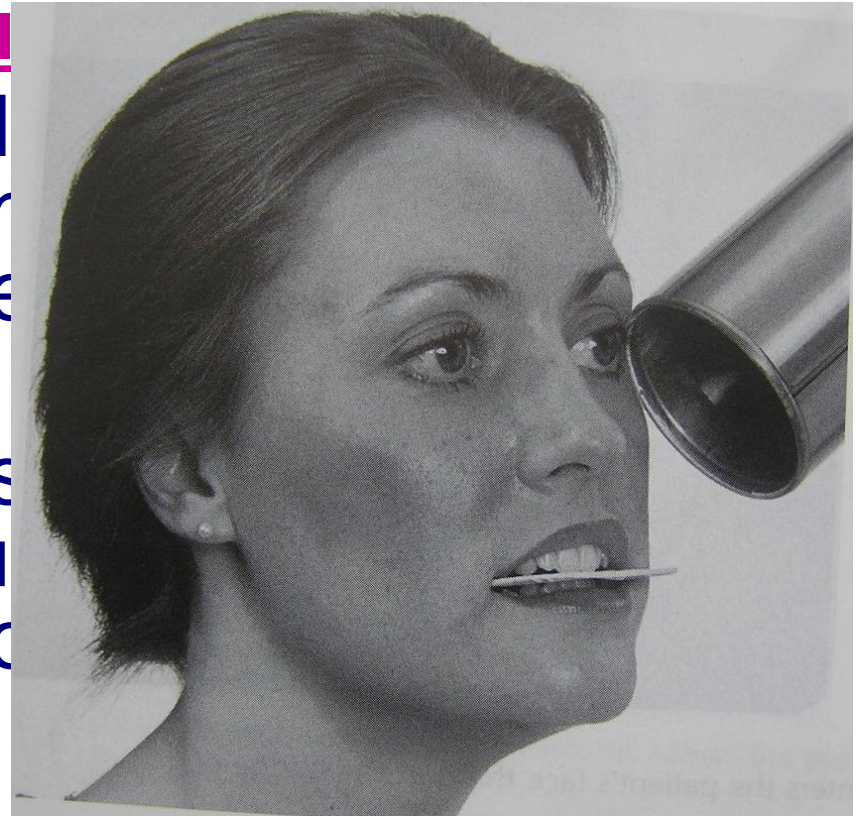

- 
- Assessment of the condition of the antral floor.
 - As an aid to determining the position of roots displaced inadvertently into the antrum during attempted extraction of upper posterior teeth.
 - Assessment of fractures of the posterior teeth and associated alveolar bone including the tuberosity.

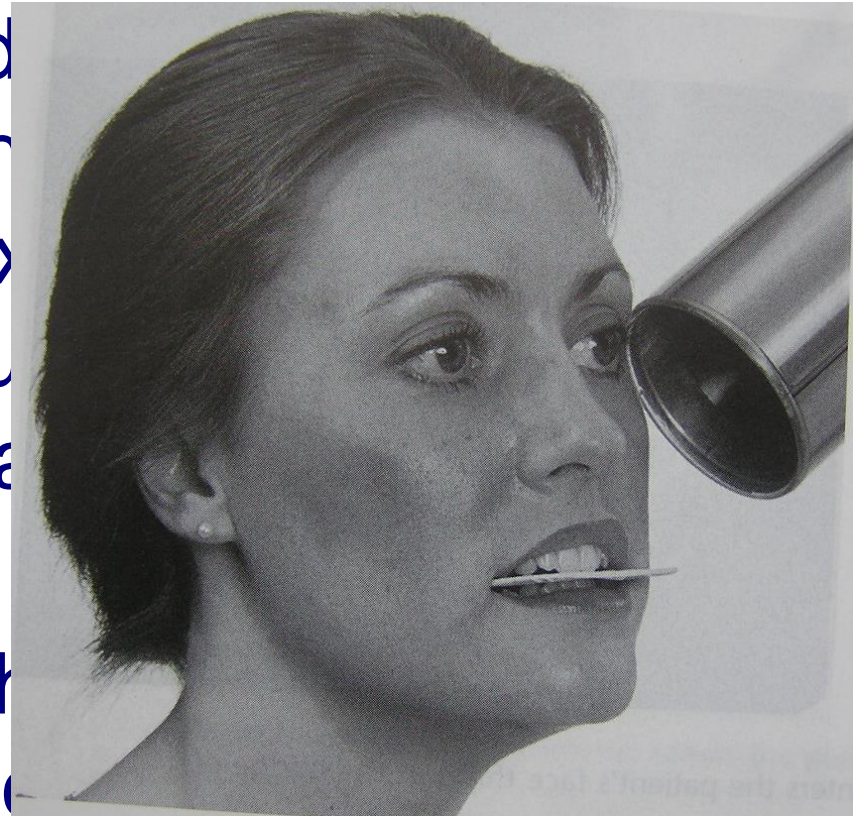UPPER OBLIQUE OCCLUSAL

TECHNIQUE AND POSITION

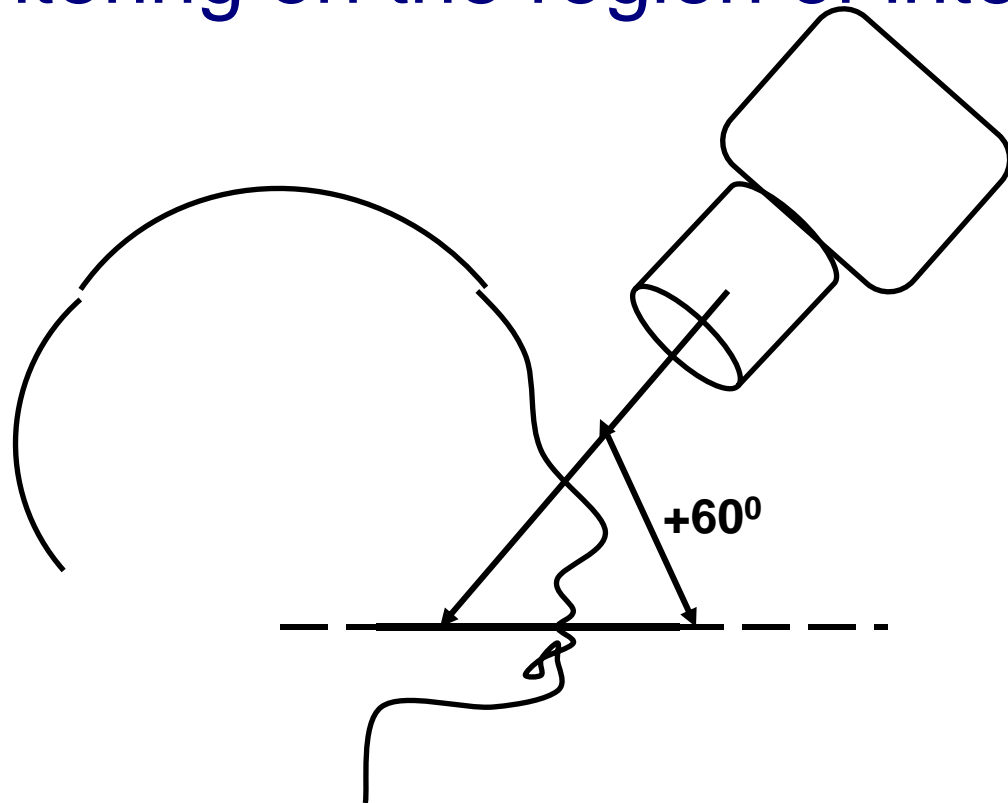
- The patient is seated supported and with the head tilted back and the film horizontal and parallel to the occlusal plane.
- The film packet, with the side facing uppermost, is placed in the mouth onto the occlusal surface of the lower teeth, with its long axis anteroposteriorly.



- It is placed to the side of the patient's head for investigation. The long end of the PID should extend approximately 10 cm beyond the buccal surface of the teeth. The patient is asked to breathe gently.
- Position the PID so that the X-ray beam is directed through the center of the intended teeth.



- The x-ray tube is positioned to the side of the patients face, aiming downwards through the cheek at an angle of $+60^{\circ}$ to the film, centering on the region of interest.



- NOTE: if the x-ray tube is positioned too far posteriorly, the shadow cast of the body of the zygoma will obscure the posterior teeth.
- As recommended by Eastman Kodak Company, use the following exposure factors for E-speed film: 65 kVp, 10 Ma, 15 impulses; or 90 kVp, 10 mA, 5 impulses.

VERTEX OCCLUSAL

- This projection shows a plan view of the tooth bearing portion of the maxilla from above.
- To obtain this view the x-ray beam has to pass through a considerable amount of tissue, delivering a large dose of radiation to the patient.
- An intraoral cassette containing an intensifying screen is used for this projection to reduce the dose.

VERTEX OCCLUSAL

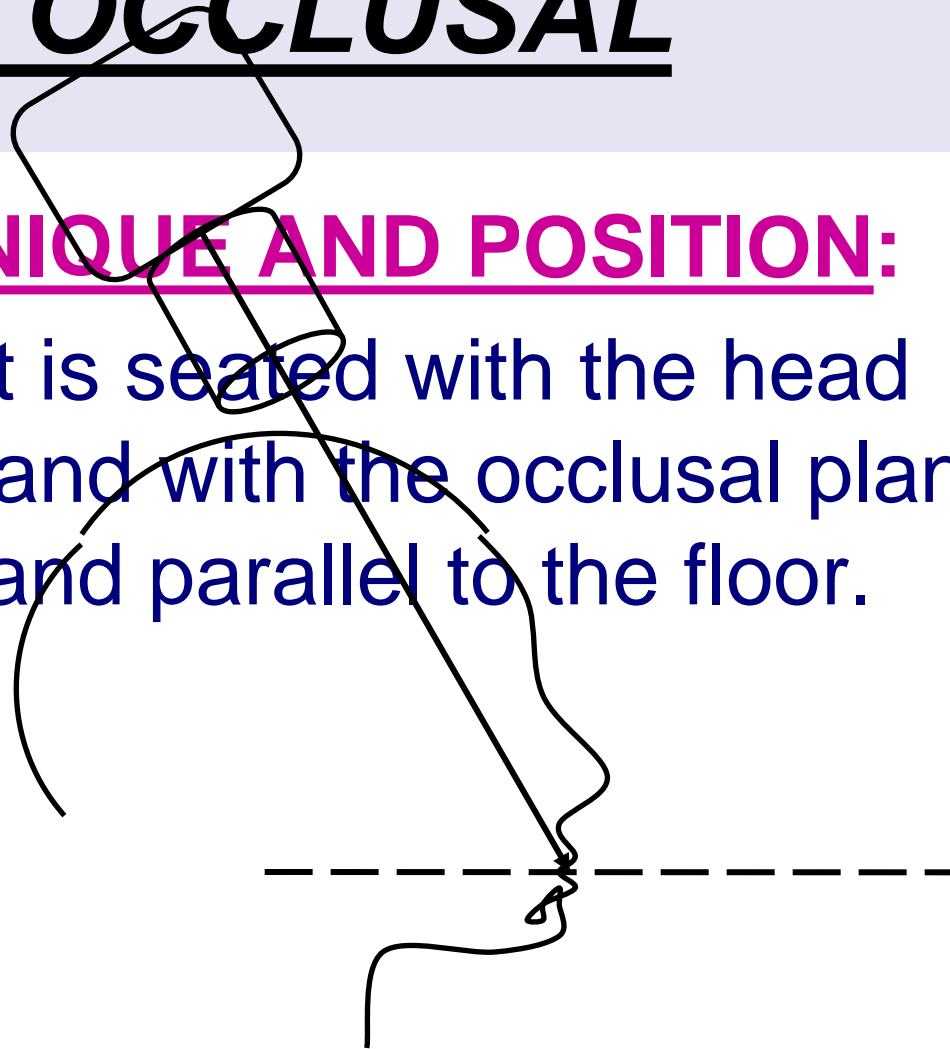
MAIN CLINICAL INDICATION:


- Assessment of the bucco /palatal position of unerupted canines.

VERTEX OCCLUSAL

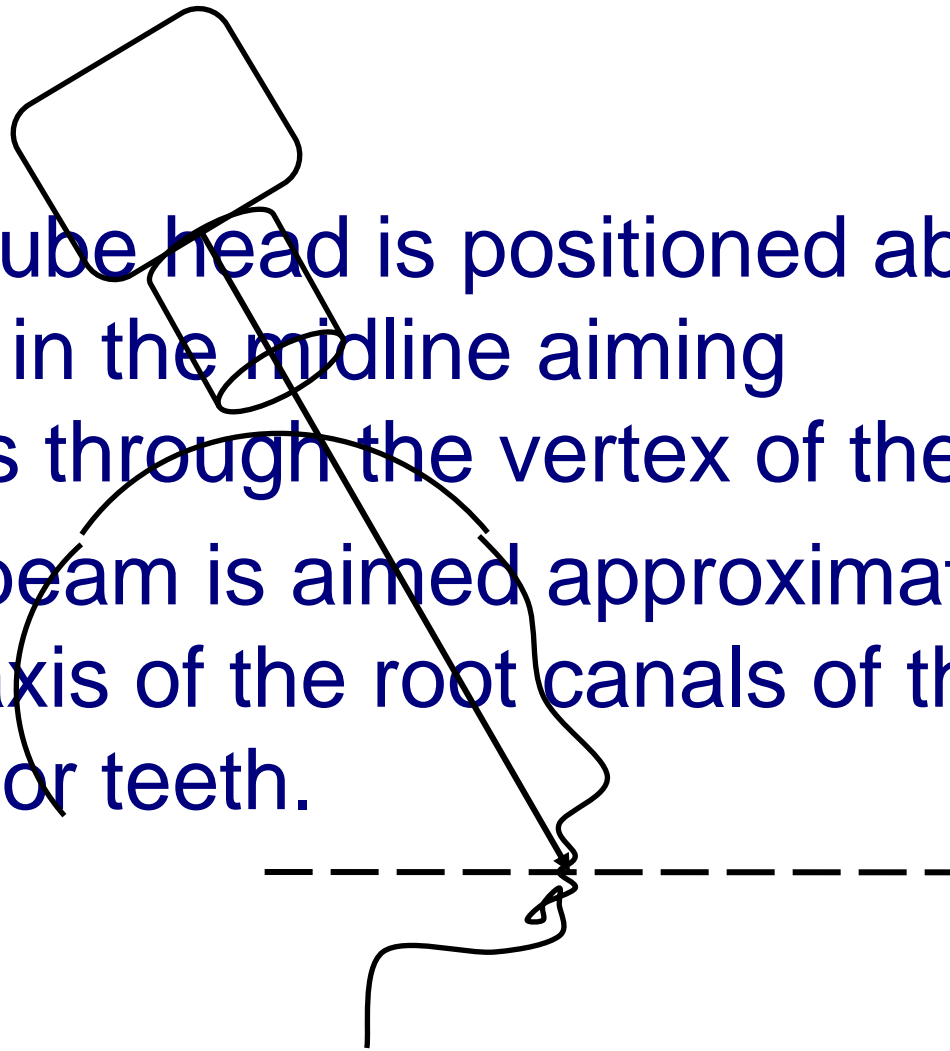
TECHNIQUE AND POSITION:

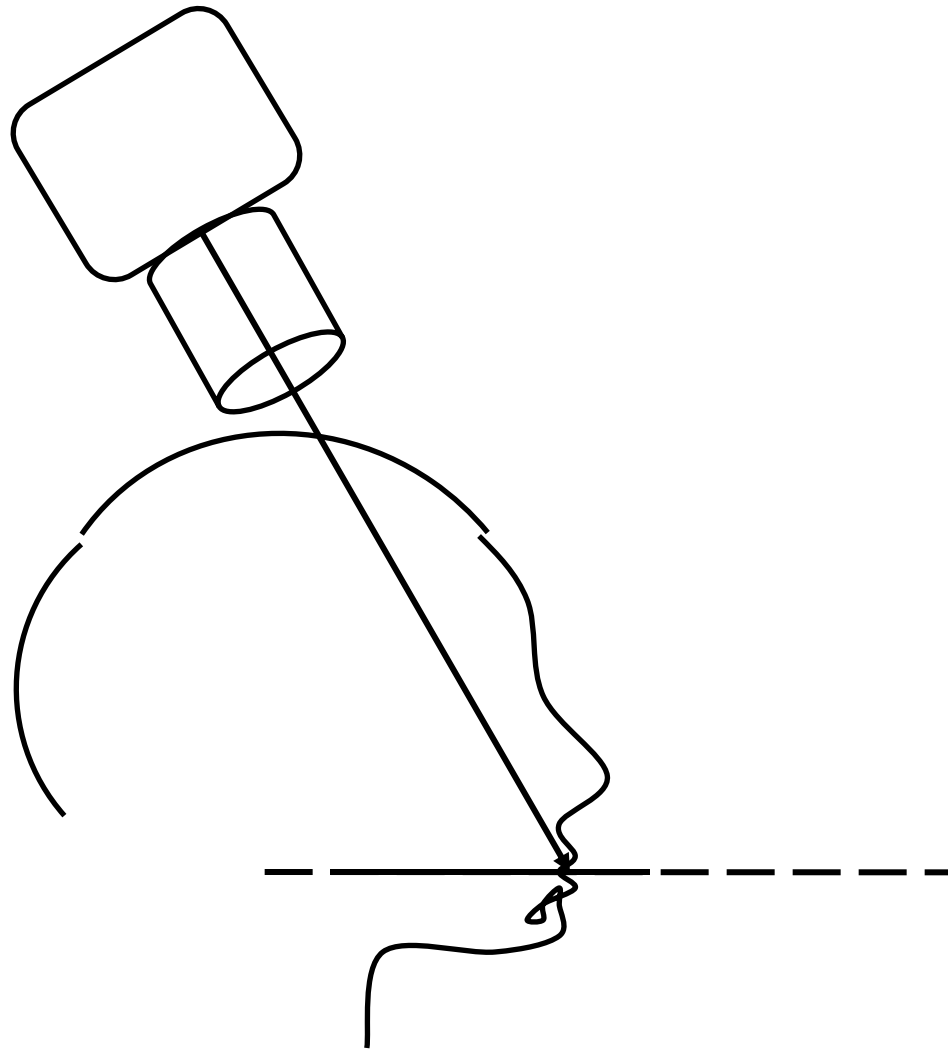
- The patient is seated with the head supported and with the occlusal plane horizontal and parallel to the floor.



- 
- The cassette is placed inside a small plastic bag to prevent salivary contamination and cross infection.
 - It is then inserted into the mouth on to the occlusal surfaces of the lower teeth, with its long axis anteroposteriorly and the patient is asked to bite onto it.

- The x-ray tube head is positioned above the patient in the midline aiming downwards through the vertex of the skull.
- The main beam is aimed approximately down the axis of the root canals of the upper incisor teeth.







VERTEX OCCLUSAL

VERTEX OCCLUSAL

DISADVANTAGES:

- There is a lack of detail and contrast on the film because of the intensifying screens, the mass of the tissue the x-ray beam has to penetrate and the consequent scatter.

- 
- The primary x-ray beam may be directed line with the reproductive organs.
 - A relatively long exposure time is required (about 1 sec) despite the use of the intensifying screens.
 - There is a direct radiation to the pituitary gland and the lens of the eye.

- 
- If the x-ray beam is positioned too far anteriorly, superimposition of the shadow of the frontal bones may obscure the anterior part of maxilla.

MANDIBULAR OCCLUSAL **PROJECTIONS:**

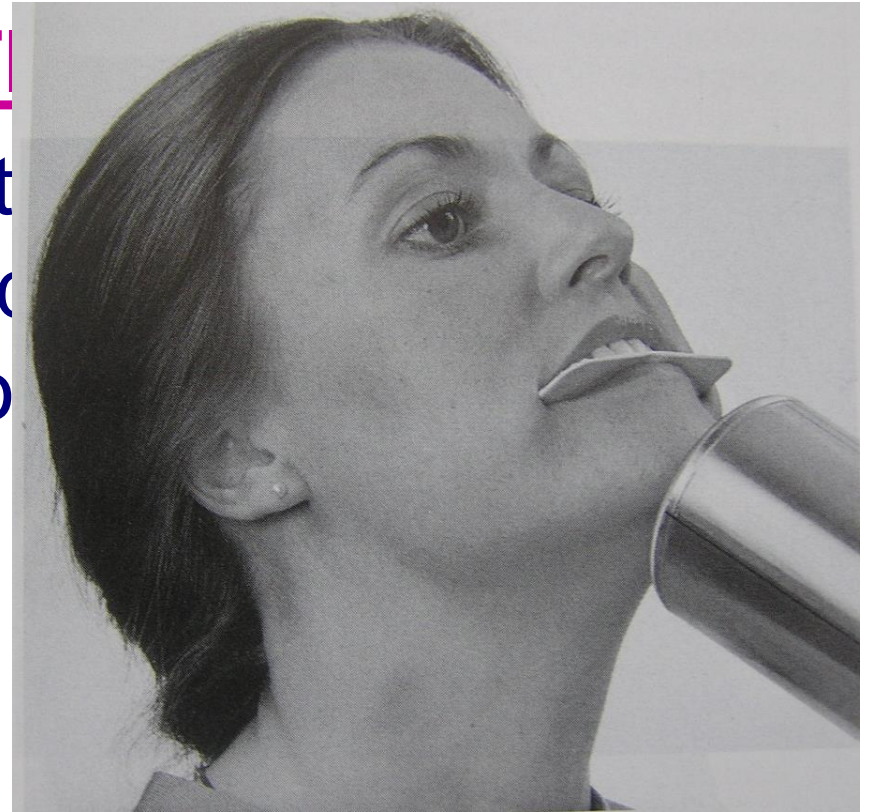There are three different mandibular occlusal projections.

- Mandibular Standard / Topographic occlusal projection.
- True occlusal / mandibular cross-sectional occlusal projection.
- Mandibular oblique occlusal projection.

MANDIBULAR TOPOGRAPHIC OCCLUSAL PROJECTION

IMAGE F

- The projection depicts of the mandible, the c to canine, and inferior mandible.

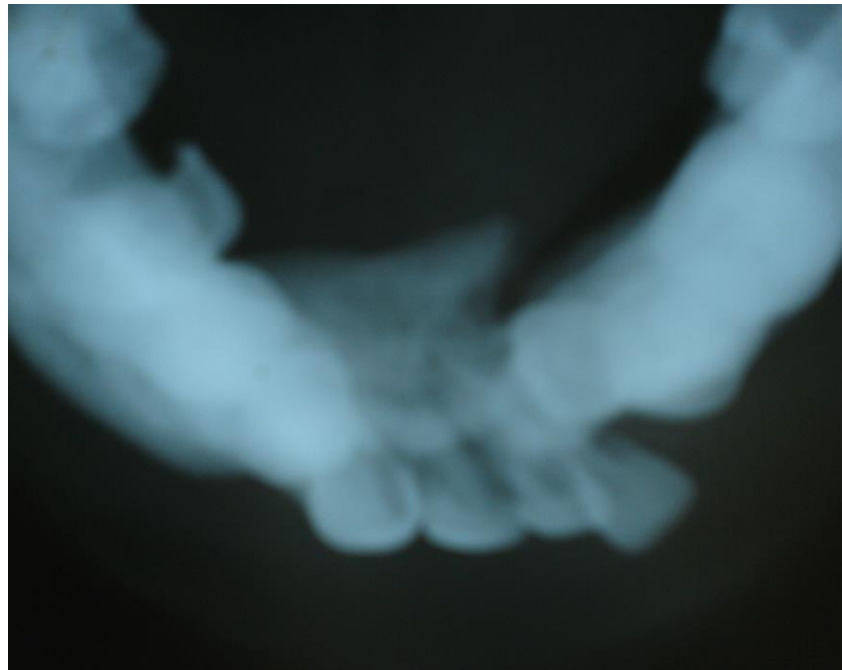


MANDIBULAR TOPOGRAPHIC OCCLUSAL PROJECTION

MAIN CLINICAL INDICATIONS:

- Periapical assessment of the lower incisors teeth, especially useful in adults and children unable to tolerate periapical films.

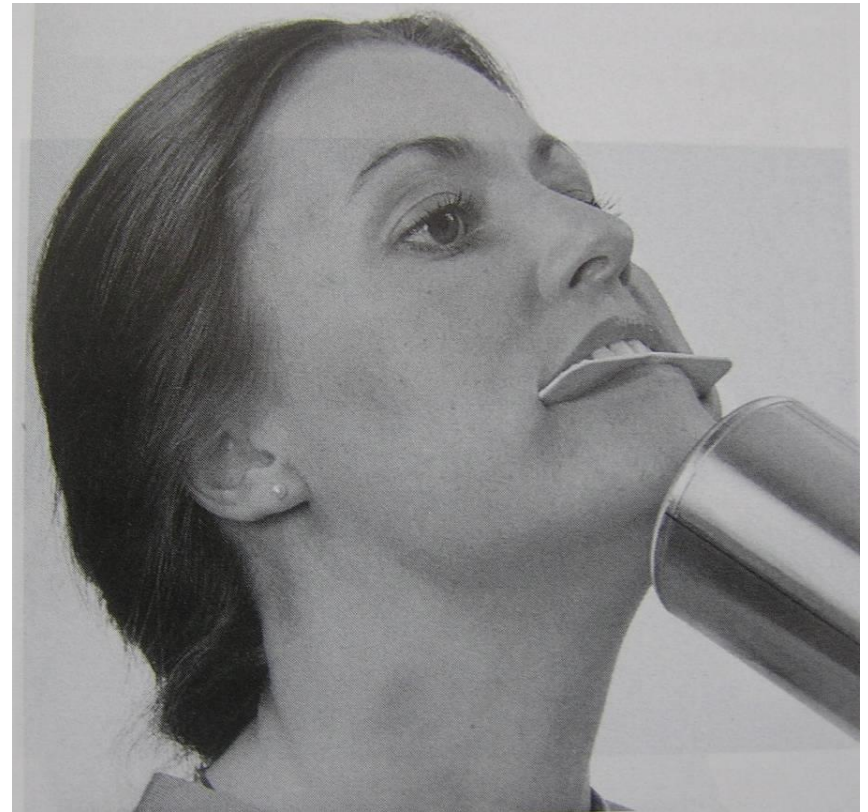- Evaluation of the size and extent of lesions such as cysts or tumors affecting the anterior part of the mandible.
- Assessment of displacement fractures of the anterior mandible in the vertical plane.




MANDIBULAR TOPOGRAPHIC OCCLUSAL PROJECTION

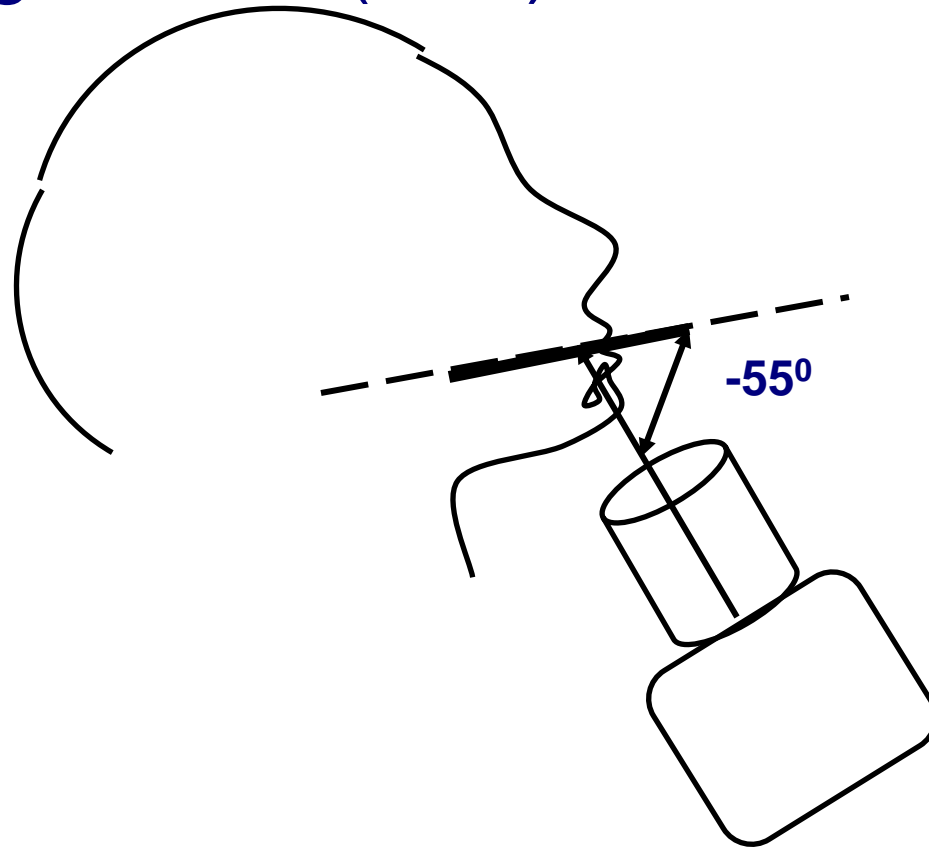
TECHNIQUE AND POSITIONING


- The patient is seated with the head tilted backwards so that the ala-tragus line is 45° above the horizontal.



- 
- The film packet , with the white , pebbly side facing downwards, is placed centrally into the mouth, onto the occlusal surfaces of the lower teeth, with its long axis anteroposteriorly.
 - The patient is asked to bite gently together.

- The x-ray tube head is positioned in the midline, centering through the chin point, at an angle of 55° (-55°) to the film.



- 
- As recommended by Eastman Kodak Company, use the following exposure factors for E-speed film: 65 kVp, 10 Ma, 15 impulses; or 90 kVp, 10 mA, 5 impulses.

MANDIBULAR CROSS-SECTIONAL OCCLUSAL PROJECTION


IMAGE FIELD

- This projection includes the soft tissue of the floor of the mouth and delineates the lingual and buccal plates of the jaw bone and teeth from second molar to second molar.

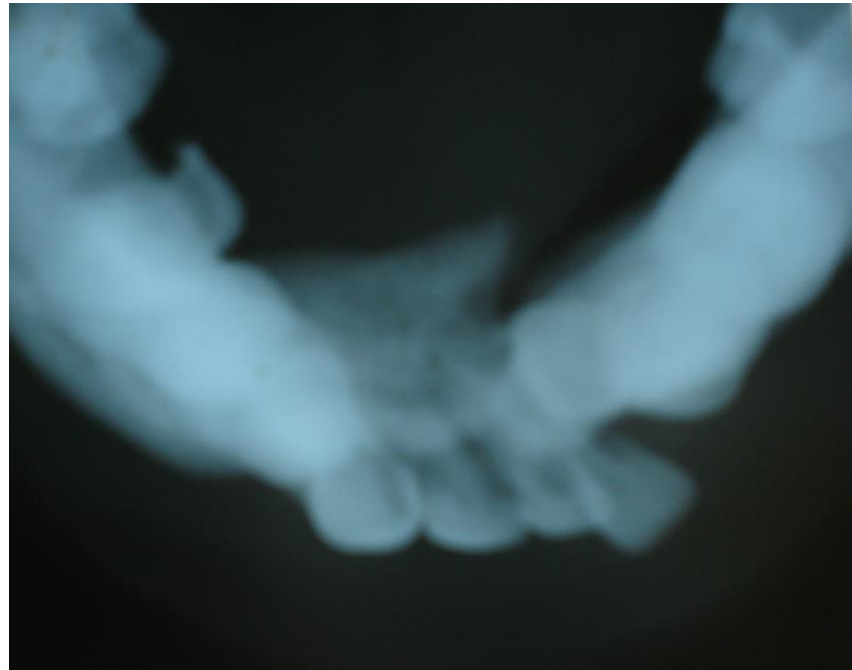
MANDIBULAR CROSS-SECTIONAL OCCLUSAL PROJECTION

MAIN CLINICAL INDICATIONS

- Detection of the presence of radiopaque calculi in salivary ducts.
- Assessment of the buccal unerupted mandibular



- Evaluation of the buccolingual expansion of the body of mandible by cysts, tumors, or osteodystrophies.
- Assessment of displacement fractures of the anterior body of the mandible in the horizontal plane.



MANDIBULAR CROSS-SECTIONAL OCCLUSAL PROJECTION

TECHNIQUE AND POSITION

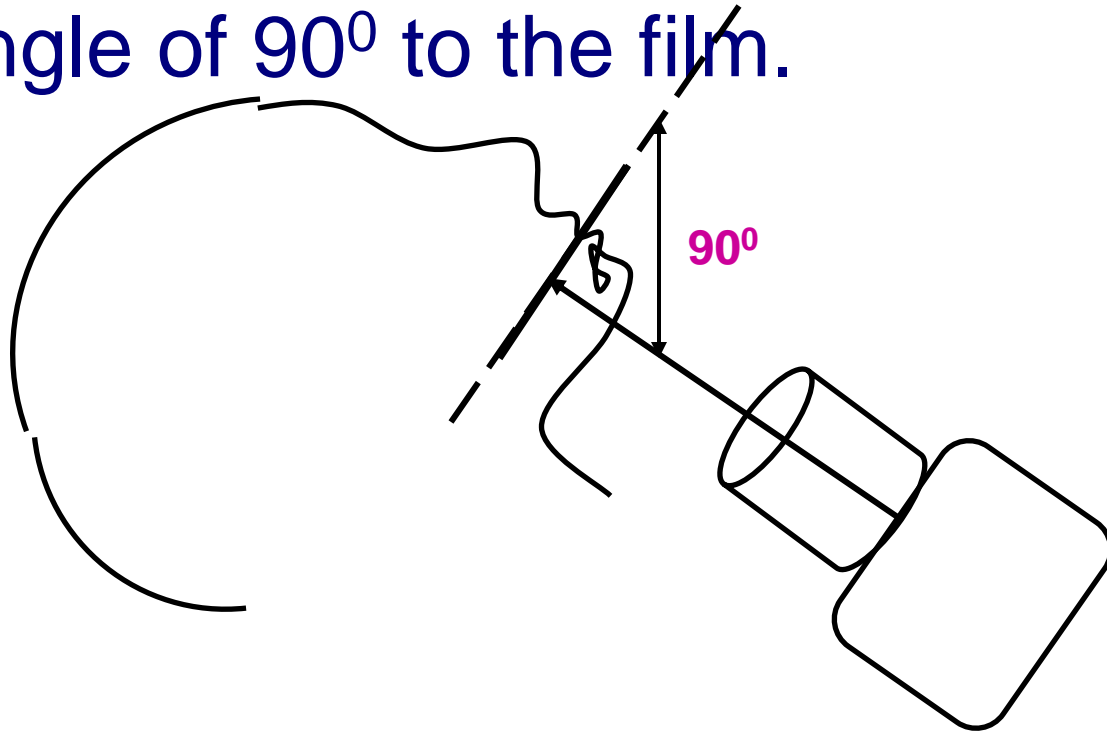
- The film packet , with side facing downward into the mouth, onto the lingual side of the lower teeth, with the film crossways.
- The patient is asked to bite gently together.




- The patient then leans forward and then tips the head backwards as far as is comfortable, where it is supported.



- The x-ray tube head with circular collimator fitted, is placed below the patients chin, in the midline, centering on an imaginary line joining the first molars, at an angle of 90° to the film.

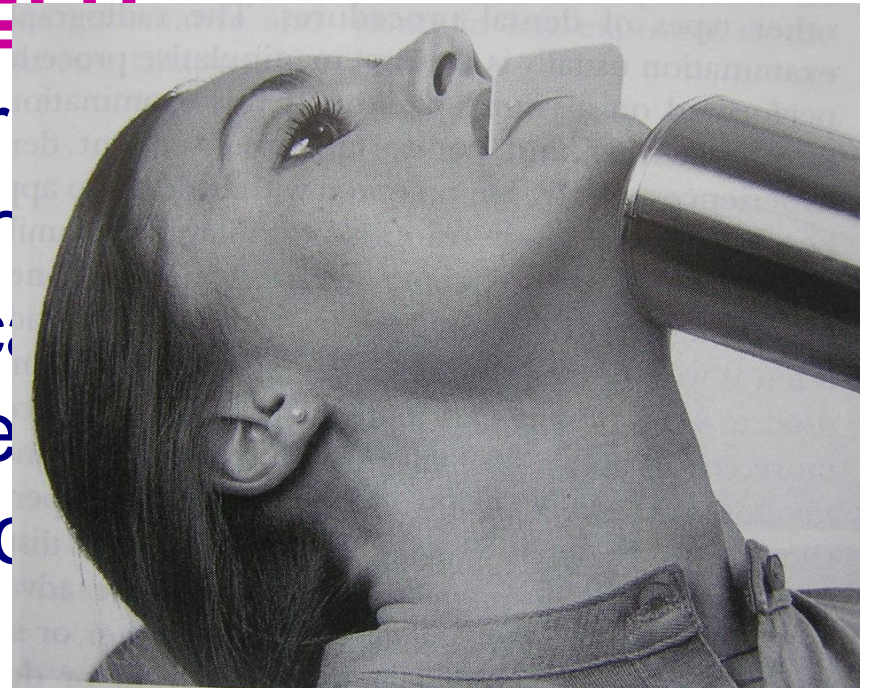


- 
- As recommended by Eastman Kodak Company, use the following exposure factors for E-speed film: 65 kVp, 10 Ma, 15 impulses; or 90 kVp, 10 mA, 5 impulses.

MANDIBULAR LATERAL CROSS SECTIONAL OCCLUSAL VIEW

IMAGE FIELD


- This projection covers the floor of the mouth and the lingual cortical mandible and the teeth from the incisor to the third molar.



MANDIBULAR LATERAL CROSS **SECTIONAL OCCLUSAL VIEW**

MAIN INDICATIONS.


- Detection of radiopaque calculi in a submandibular salivary gland.
- Assessment of the buccolingual position of unerupted lower wisdom teeth.

- 
- Evaluation of the extent and expansion of cysts, tumors or osteodystrophies in the posterior part of the body and angle of the mandible.

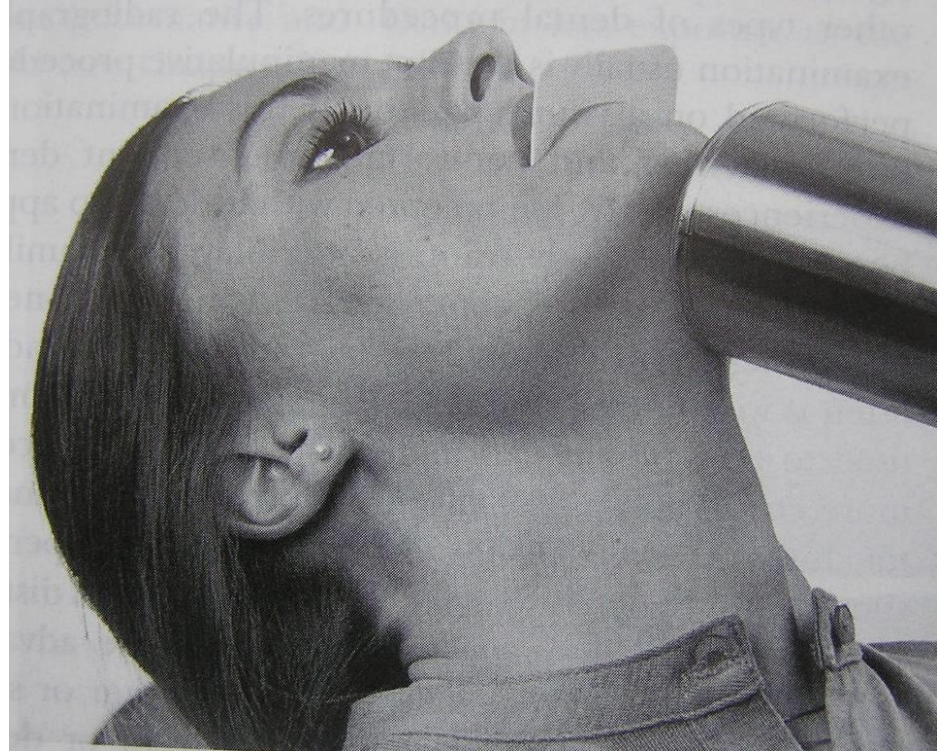
MANDIBULAR LATERAL CROSS SECTIONAL OCCLUSAL VIEW

TECHNIQUE AND POSITIONING

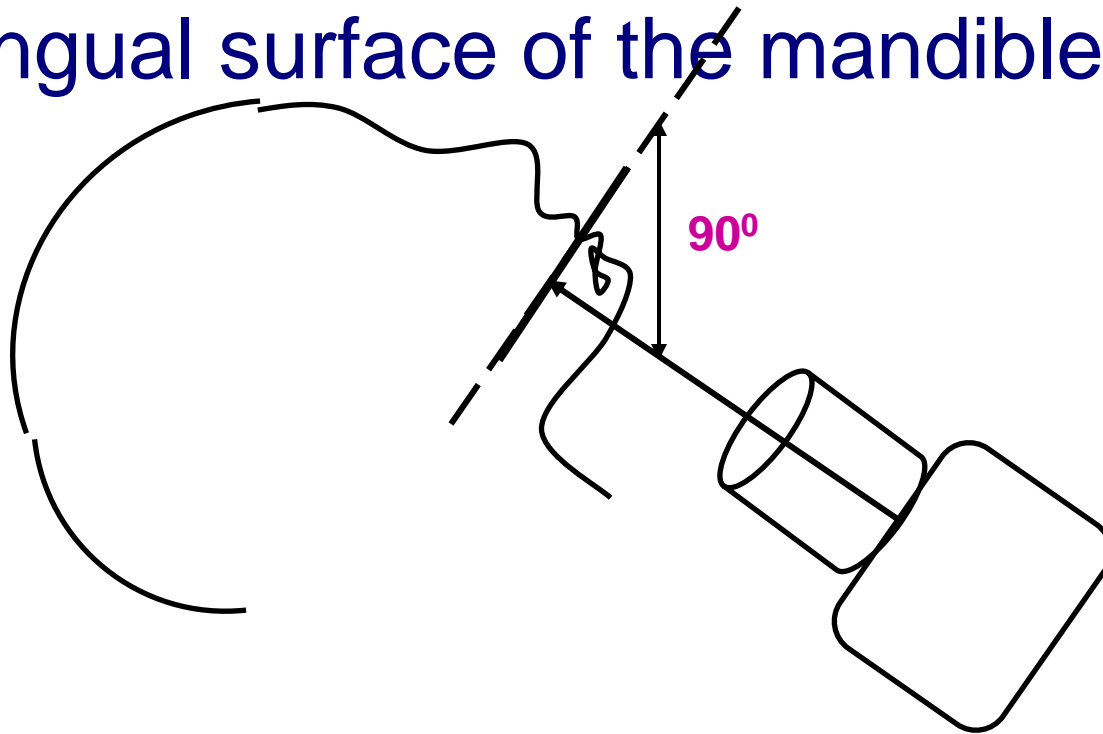
- The film packet , with side facing downward into the mouth, onto the occlusal surface of the lower teeth, over the occlusal plane for investigation, with its long axis directed anteroposteriorly.
- The patient is asked to bite gently together.




- The patients head is supported, then rotated away from the side under investigation and the chin is raised.
- This rotated position allows the subsequent positioning of the x-ray tubehead.



- The x-ray tube head with circular collimator is aimed upwards and forwards towards the film, from below and behind the angle of the mandible and parallel to the lingual surface of the mandible.



- 
- As recommended by Eastman Kodak Company, use the following exposure factors for E-speed film: 65 kVp, 10 Ma, 15 impulses; or 90 kVp, 10 mA, 5 impulses.



Thank
You