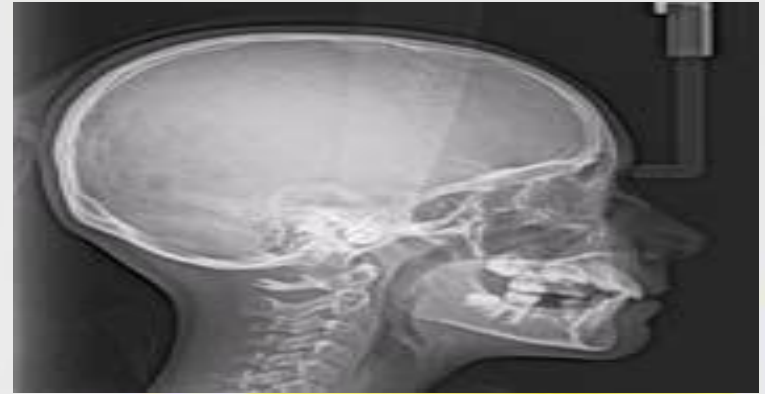
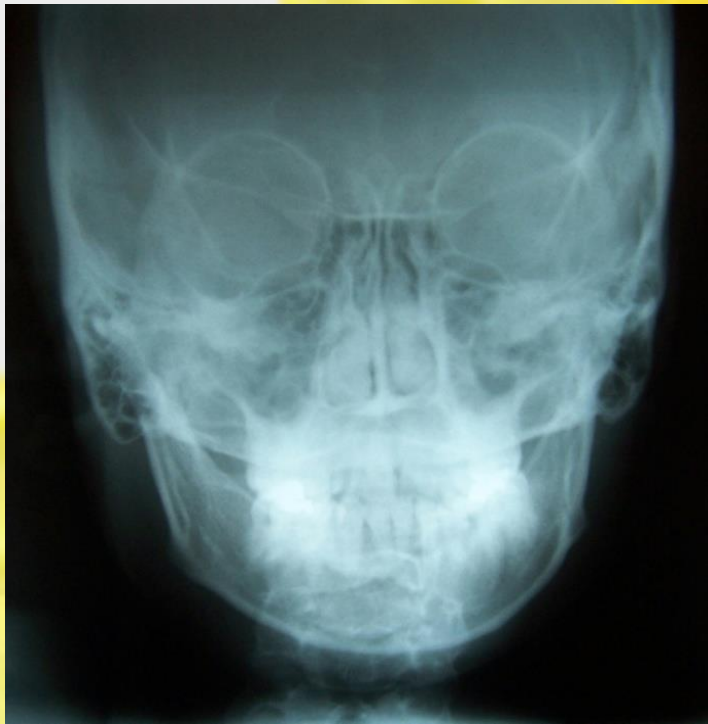
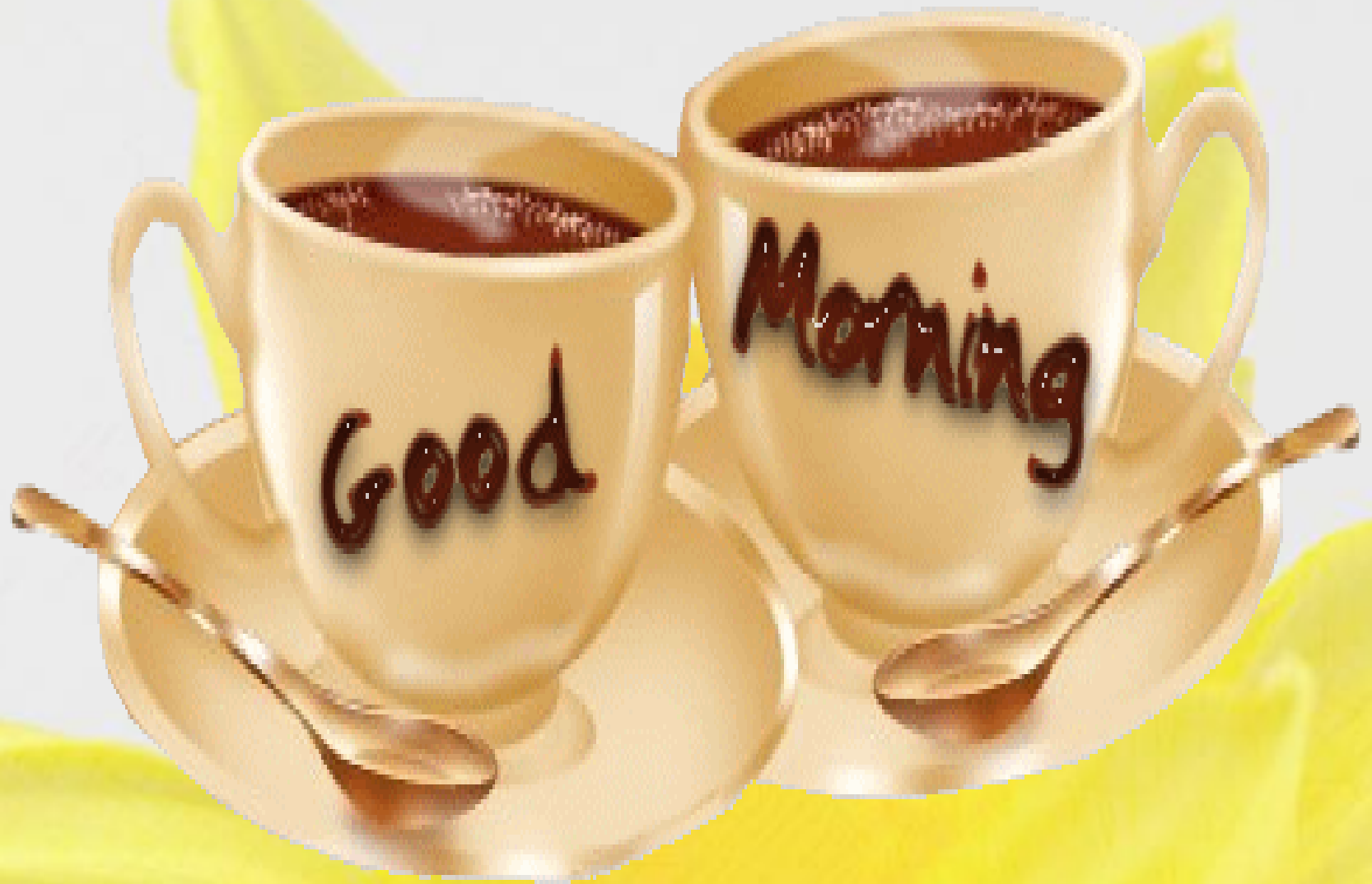

EXTRA ORAL TECHNIQUES





CONTENTS

- INTRODUCTION
- EXTRAORAL RADIOGRAPHS
- CEPHALOMETRIC LANDMARKS
- DENTAL LANDMARKS
- SOFT TISSUE LANDMARKS
- LATERAL SKULL PROJECTION
- SUBMENTOVERTEX PROJECTION
- WATERS PROJECTION
- POSTEROANTERIOR SKULL PROJECTION
- REVERSE TOWNES PROJECTION
- CONCLUSION
- REFERENCES

INTRODUCTION

- In extraoral radiographic examination both the x ray source and image receptor (film and electronic sensor)are placed outside the patients mouth.it contains-

Lateral cephalometric projections

Submentovertex projections

Waters

Posteroanterior cephalometric

Reverse-towne projections

Extra oral radiographs

- Cephalometric and skull views require-20X25 cm (8X10 inches)
- Oblique lateral projections of mandible 13 X18 cm (5X7 inches)

CEPHALOMETRIC LANDMARKS

- **PORION(P)**-most superior point of external auditory canal
- **SELLA(S)**-center of hypophyseal fossa
- **NASION(N)**-frontonasal suture.
- **ORBITALE(O)**-most inferior point of the infraorbital rim.
- **PT point**-most posterior point of the pterigomaxillary fissure

- **BASION**- most ant. Part of foramen mangnum
- **PNS**-tip of post. Nasal spine
- **ANS**-tip of ant nasal spine
- **A point**-deepest point of ant. Border of the maxillary alveolar ridge concavity
- **B point-(B)**-deepest point in the concavity of the anterior border of the mandible
- **POGONION(P)**-most ant. Point of symphysis
- **GANTHION**-midpoint of the symphysis outline b/w pogonion and menton
- **MENTON-(M)**-most inferior point of symphysis

- **GONION**-most convex point along the inferior border of mandibular ramus
- **RAMUS POINT**-most post. Point of posteroinferior point of mandibular ramus
- **R1**-most inferior point of sigmoid notch
- **R2**-an arbitrary point on the lower border of mandible below R1
- **R3**-most concave point of the anterior border of mandibular ramus
- **R4**-most convex point of the posterior border of mandibular ramus

- **ARTICULARE(AR)**-point of intersection b/w the basiphoid and posterior border of condylar head
- **CONDYLE TOP**-most superior point of condyle
- **DC point**-center of condylar head

Dental landmarks

- **U6 MESIAL CUSP**-tip of the max. first molar mesial buccal cusp
- **U6 MESIAL**-contact point on mesial surface of maxillary first molar
- **U6 DISTAL**- contact point on the distal surface of max. first molar
- **L6 MESIAL**-contact point on the mesial surface of the mandibular first molar
- **L6 DISTAL**-contact point is on the distal surface of mandibular molar

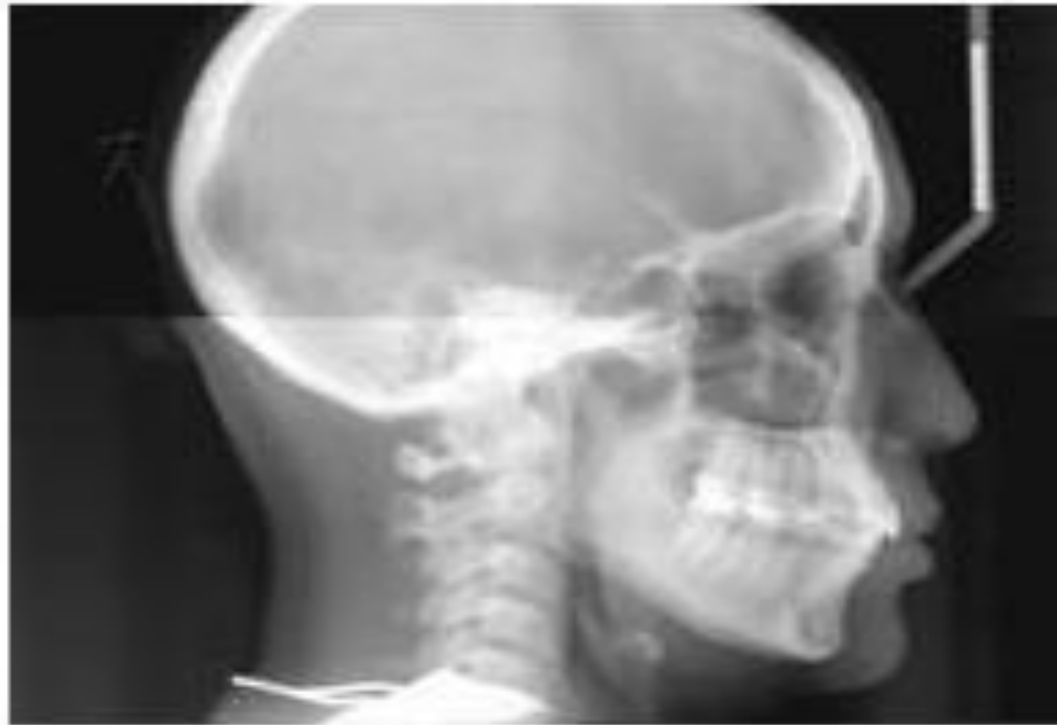- **U1 INCISAL**-incisal edge of max. central incisor
- **U1 FACIAL**-most convex point of buccal surface of maxillary central incisor
- **U1 ROOT**-root tip of maxillary central incisor
- **L1 INCISAL**-incisal edge of mandibular central incisor
- **L1 FACIAL**- most convex point on the buccal surface of mandibular central incisor
- **L1 ROOT**- root tip of mandibular central incisor

Common Extraoral Views

Patient placement	Film parallel to midsagittal plane	Centromental line parallel to film	Centromental line at 37° with film	Centromental line at 10° with film	Centromental line at -30° with film	Film in contact with chin at mental area	Film in contact with chin at ramus area
Central beam	Beam perpendicular to film	Beam perpendicular to film	Beam perpendicular to film	Beam perpendicular to film	Beam perpendicular to film	Beam aims at the zygomatic area	Beam aims at the ramus area
Diagram of patient placement							
Illustration of patient placement							
Skull view							
Resultant image							

From: White and Pharoah 5th edition

Lateral skull projection (lateral cephalometric projection)



Lateral skull projection (lateral cephalometric projection)

Most commonly used in dentistry

- Made with cephalostat that helps in maintain a constant relationship among skull, film and x-ray beam.
- Skeletal ,dental,and soft tissue anatomic landmarks delineate lines planes,angles and distances .

- Used in –

Generate
measurements

Classify
patients
craniofacial
morphologic
features.

IMAGE RECEPTOR AND PATIENT PLACEMENT

Image receptor is positioned parallel to patients
midsagittal plane

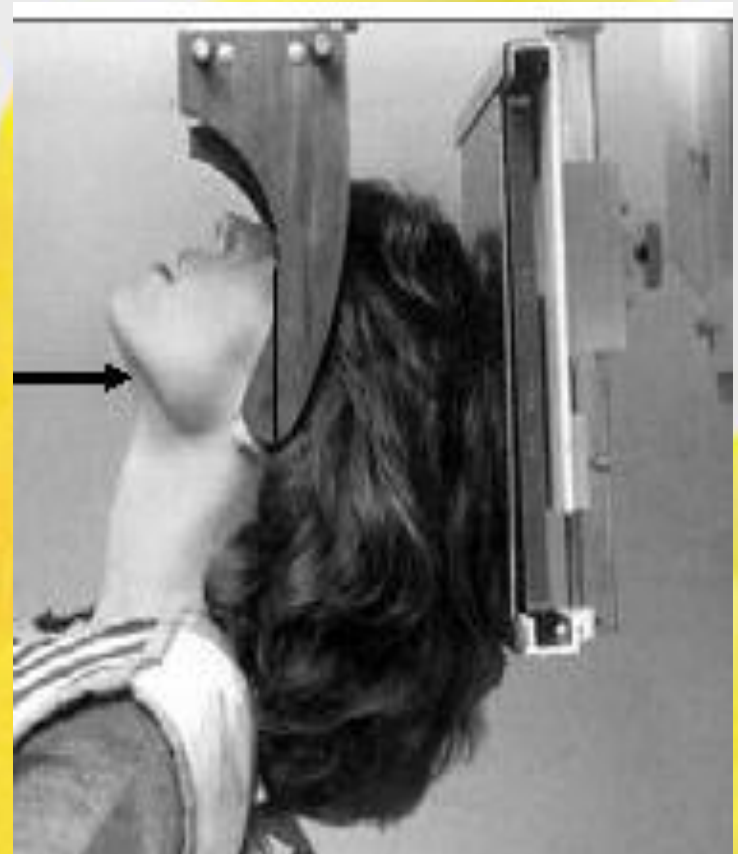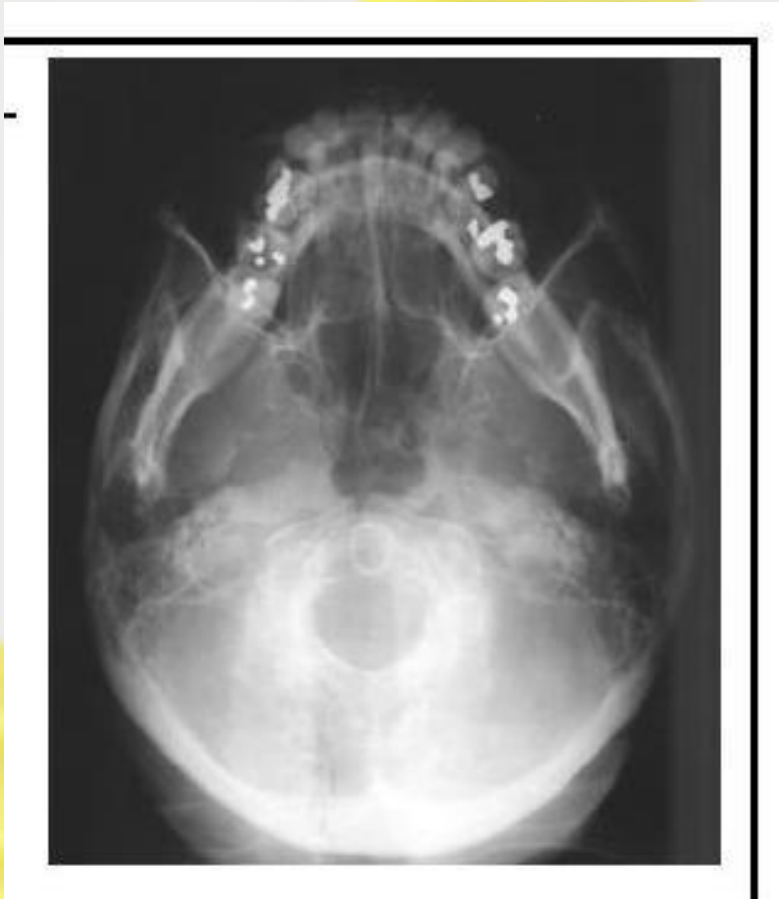- Patient is placed with the left side towards the image receptor
- Wedge filter at tube head is positioned over the anterior aspect of the beam to absorb some of the radiation and allow visualization of soft tissue of face.

POSITION OF CENTRAL X RAY BEAM

Central beam is perpendicular to midsagittal plane of patient and the plane of image receptor and is centered over the external auditory meatus

- **RESULTANT IMAGE**
- Exact superimposition of right and left sides is impossible because structure on the side near the image receptor are magnified less than the same structures on the side far from the image receptor.
- Bilateral structure close to the midsagittal plane demonstrate less discrepancy in size compared with bilateral structures farther away from the midsagittal plane

Submentoverteax (base) projection



Submentoververtex (base) projection

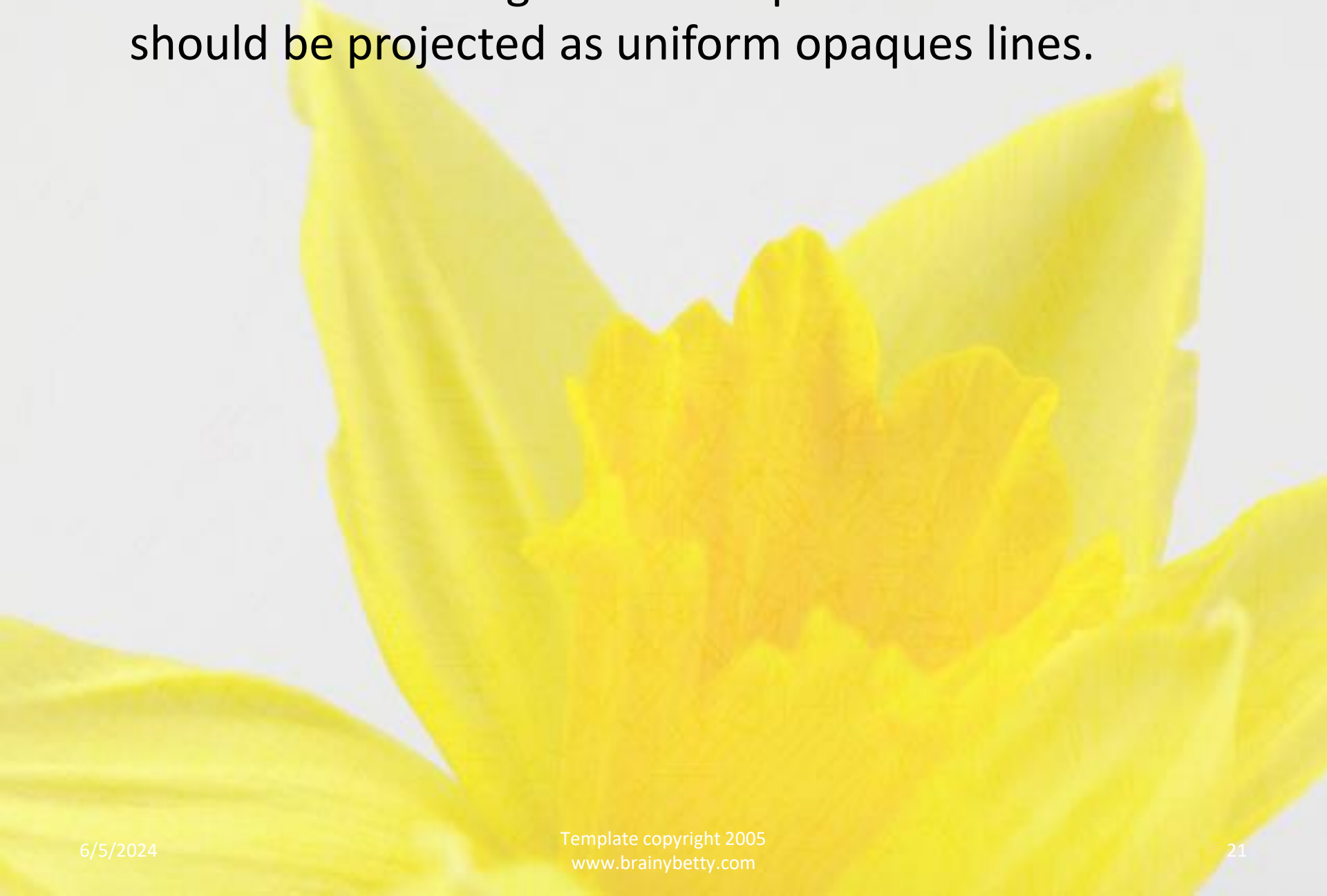
- **IMAGE RECEPTOR AND PATIENT PLACEMENT**

The image receptor is positioned parallel to patients transverse plane and perpendicular to the midsagittal and coronal planes.

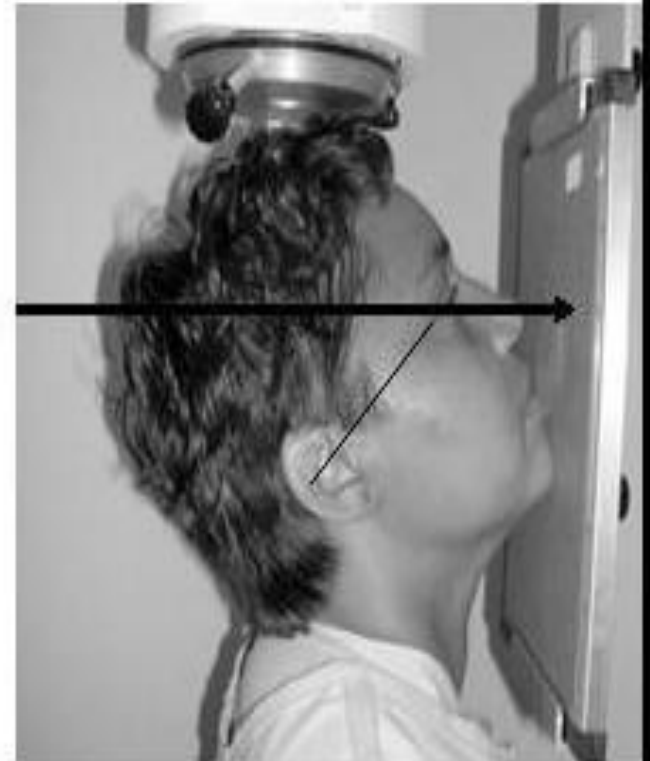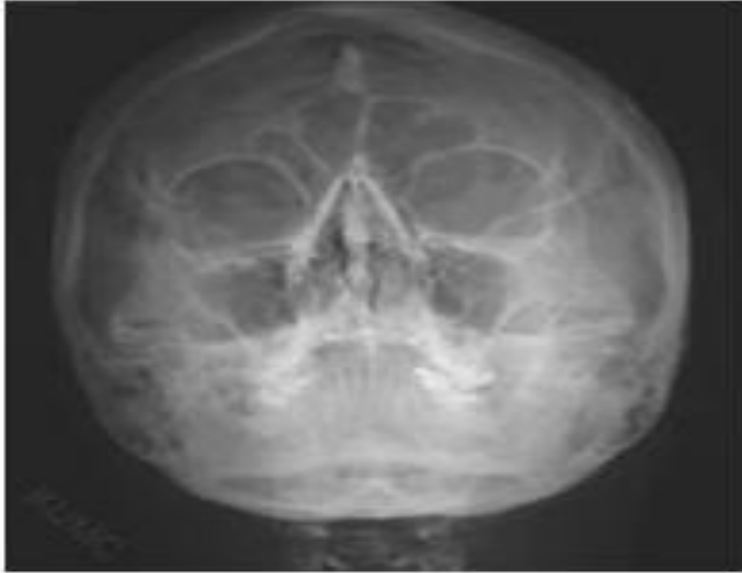
Patients neck is extended as far backward as possible, with canthomeatal line forming line forming a 10 degree angle

- With the image.
- **POSITION OF CENTRAL XRAY BEAM**
- The central beam is perpendicular to the image receptor, directed from below the mandible towards the vertex of the skull.
- Centered about 2 cm ant. To a line connecting the right and left condyles.
- **RESULTANT IMAGE**
- The midsagittal plane should divide the skull image in two symmetric halves.

- The buccal and lingual cortical plates of mandible should be projected as uniform opaques lines.



WATERS PROJECTION



WATER PROJECTIONS

- IMAGE RECEPTOR AND PATIENT PLACEMENT

Image receptor is placed in front of the patient and perpendicular to midsagittal plane.

The patients head is tilted upward so that the canthomeatal line forms 37 degree angle with image receptor

If the patient mouth is open the sphenoid sinus will be seen superimposed over the palate

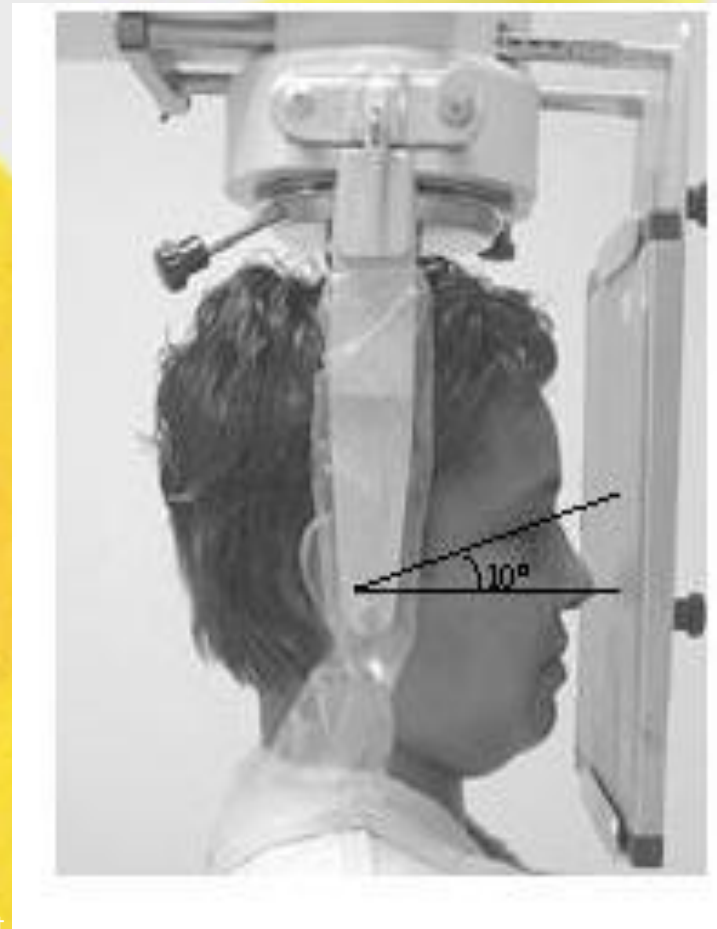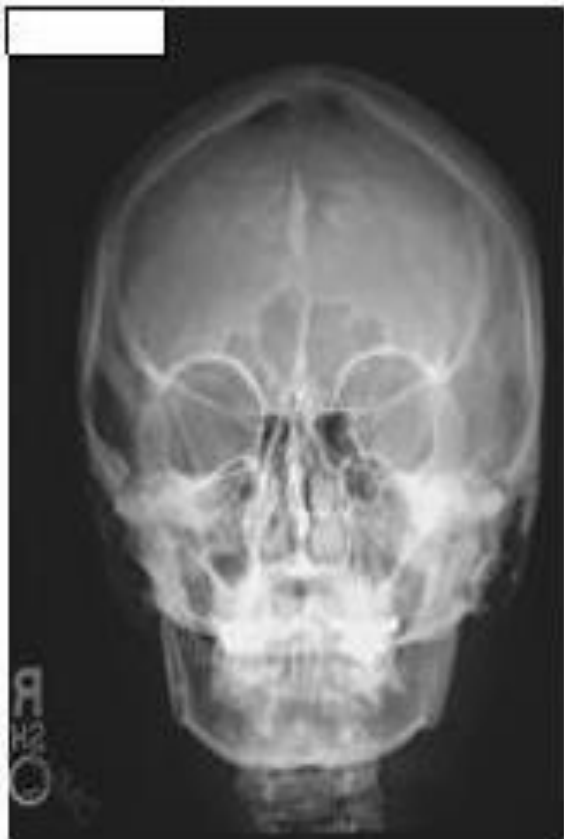- **POSITION OF X RAY BEAM**

- The central beam is perpendicular to the image receptor and centered in the area of maxillary sinus.

- **RESULTANT IMAGE**

- The mid sagittal plane should divide the skull image in two symmetric halves .
- The petrous ridge of the temporal bone should be projected below the floor of the maxillary sinus.

POSTEROANTERIOR SKULL PROJECTION(posteroanterior cephalometric projection)



POSTEROANTERIOR SKULL PROJECTION(posteroanterior cephalometric projection

- IMAGE RECEPTOR AND PATIENT PLACEMENT
- Image receptor is placed in front of patient ,perpendicular to the mid sagittal plane and parallel to coronal plane
- The patient is placed so that the canthomeatal line forms 10 degree angle with the horizontal plane and the frankfort plane is perpendicular to image receptor

- Canthomeatal line is perpendicular to the image receptor

POSITION OF XRAY BEAM

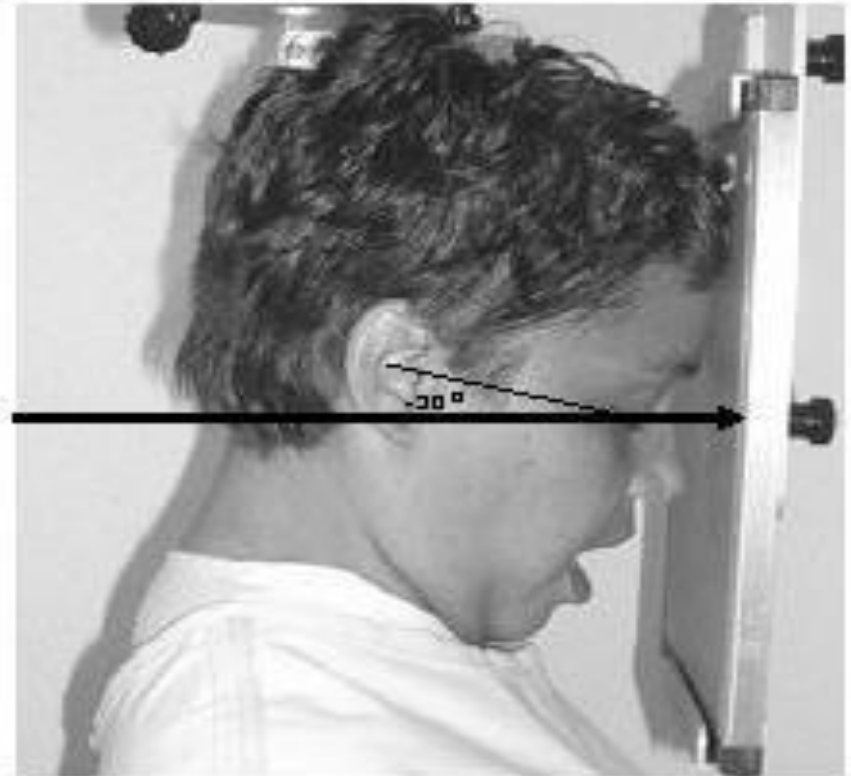
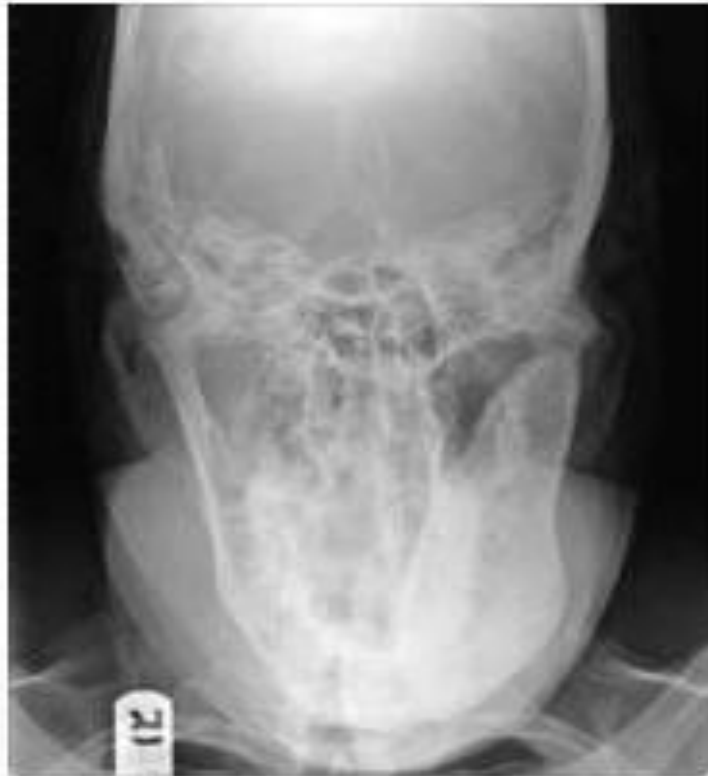The central beam is perpendicular to the image receptor, directed from the posterior to the anterior, parallel to patient's midsagittal plane and is centered at the level of the bridge of the nose.

RESULTANT IMAGE

The midsagittal plane should divide the skull image into two symmetric halves. superior border of petrous ridge lie in lower 3rd of orbit

REVERSE TOWNE PROJECTION

Reverse Towne projection



REVERSE-TOWNE PROJECTION(OPEN MOUTH)

- IMAGE RECEPTOR AND PATIENT PLACEMENT
- The image receptor is placed in front of the patient, perpendicular to midsagittal and parallel to the coronal plane .
- Patients head is tilted downwards so that the cantomeatal line forms 25-30 degree angle with image receptor.

- The mouth is opened so
- **POSITION OF CENTRAL X RAY BEAM**
- Central beam is perpendicular to image receptor and parallel to patient midsagittal and it is centered at the level of the condyles
- **RESULTANT IMAGE**
- The midsagittal plane should divide the skull image into two symmetric halves. petrous ridge of the temporal bone should be superimposed at the inferior part of the occipital bone. condylar heads should be projected inferior to articular eminence.

CONCLUSION

- Proper positioning of patient ,x ray source, and image receptor require patience,attention to detail and experience
- .the main anatomic landmarks in extraoral radiography is canthomeatalline(joins center of eye external auditory canal)



very much!