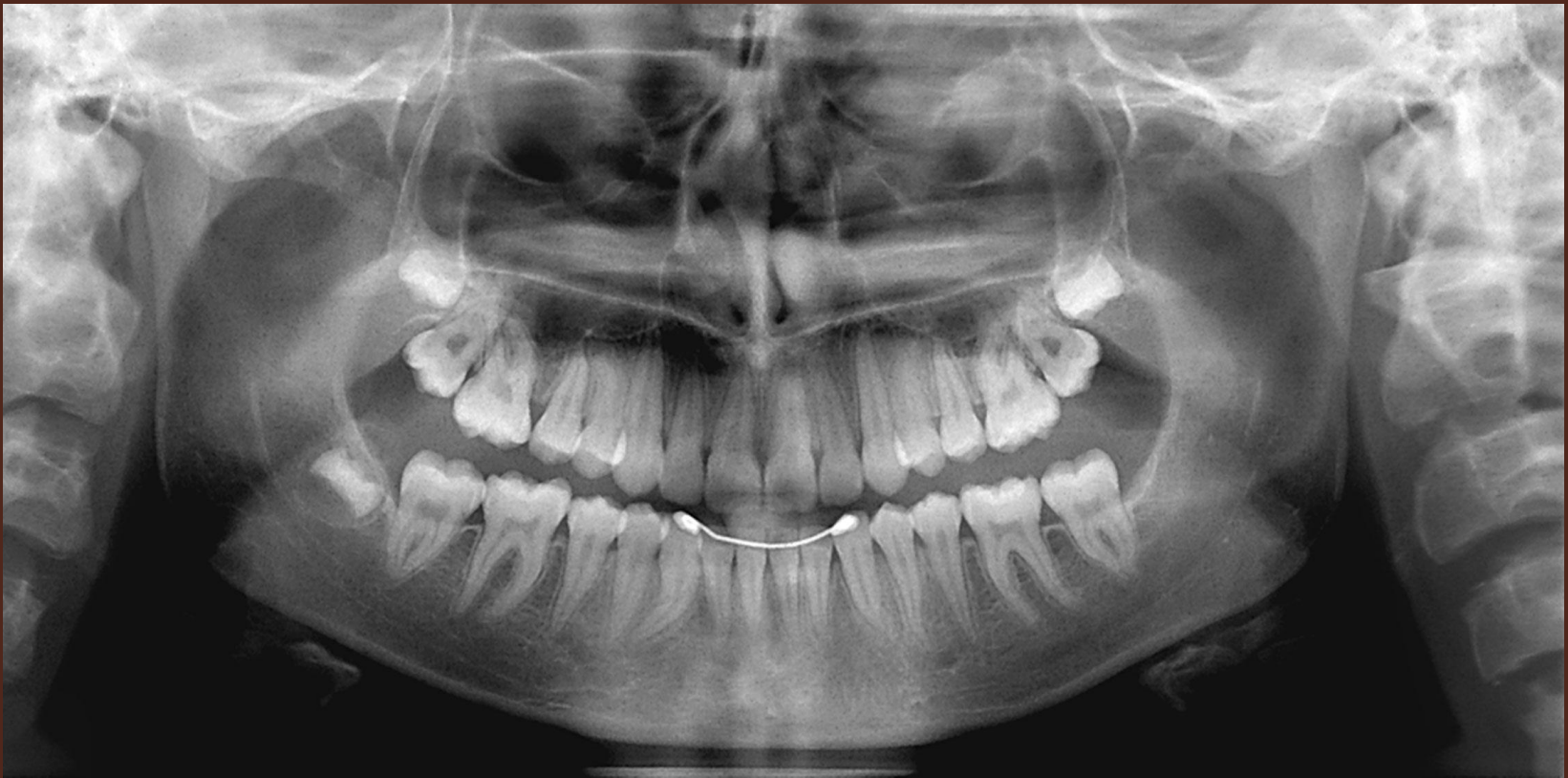

# ***PANORAMIC RADIOGRAPHY***




# CONTENTS

- FOCAL TROUGH
- FACTORS AFFECTING SIZE AND SHAPE OF FOCAL TROUGH
- CONCEPTS OF IMAGE FORMATION

FOCAL TROUGH

# FOCAL TROUGH

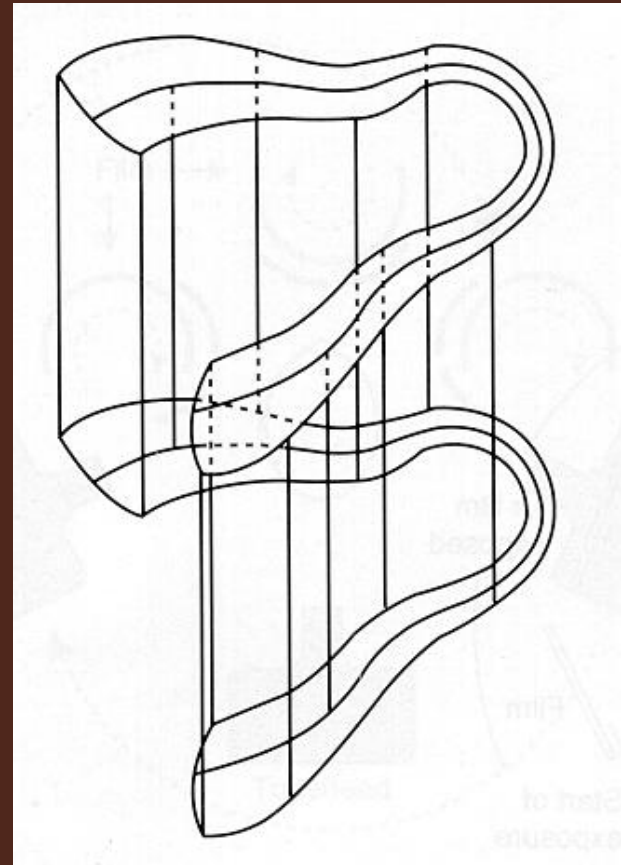
- Refers to image layer, image zone or focus zone
- Theoretical concept as to where the jaws must be placed for clearest image
- Structures within image zone relatively defined and structures outside blurred or not visible on film



- Objects outside the focal trough are blurred, magnified, or reduced in size and are sometimes distorted to the extent of not being recognizable

# FACTORS AFFECTING SHAPE AND SIZE

The shape of the focal trough varies with the brand of equipment used.



# CONCEPTS OF IMAGE FORMATION

# IMAGING CONCEPTS

1. **Structures are flattened and spread out**
2. **Midline structures may project as single or double Images**
3. **Ghost images are formed**
4. **Soft tissue shadows are seen**
5. **Air spaces are seen**
6. **Radiolucencies and radiopacities are seen**
7. **Panoramic images are unique**

*(Langland)*

CONCEPT 1  
STRUCTURES ARE  
FLATTENED AND SPREAD  
OUT

# **Concept 1**

## **STRUCTURES ARE FLATTENED AND SPREAD OUT**

- **The jaws and structures of the of the maxillofacial complex as well as the spine are portrayed as if they were split vertically in half down the midsagittal plane with each half folded outward.**

*(Langland)*

# **CONCEPT 1**

## **STRUCTURES ARE FLATTENED AND SPREAD OUT**

- **Radiographic image is “laid out” on the film, the same way paint is applied to a wall with a roller.**

*(Langland)*

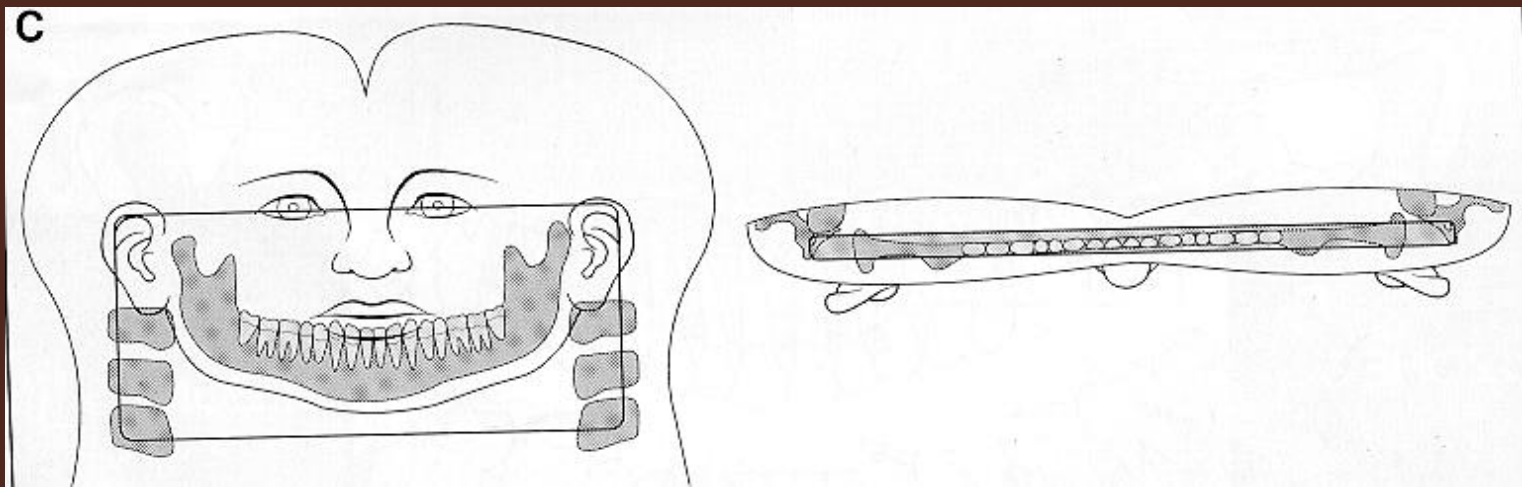
# **Concept 1**

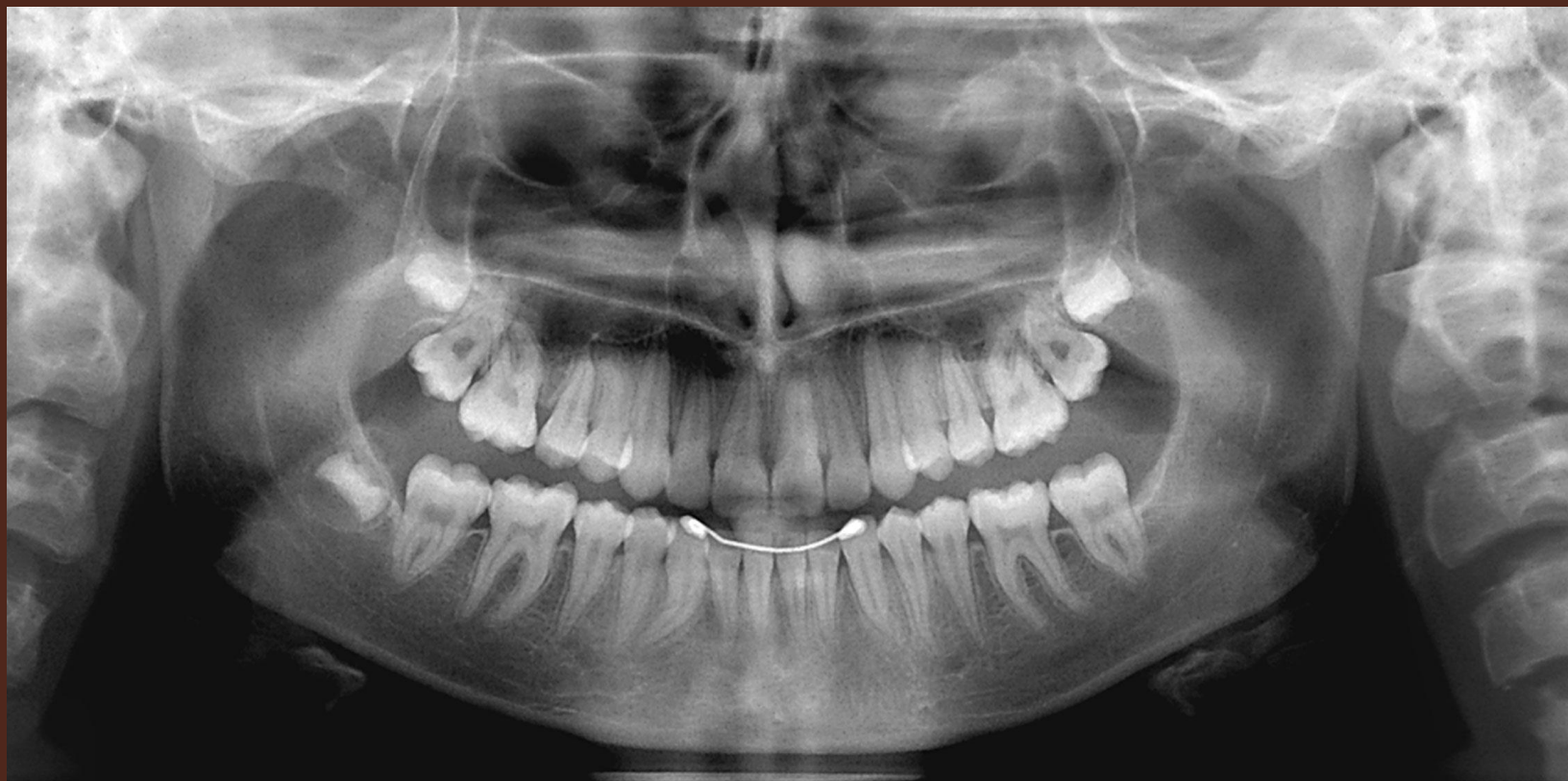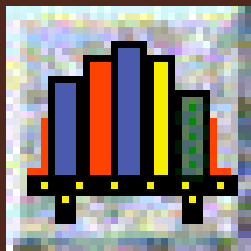
## **Structures are Flattened and Spread Out**

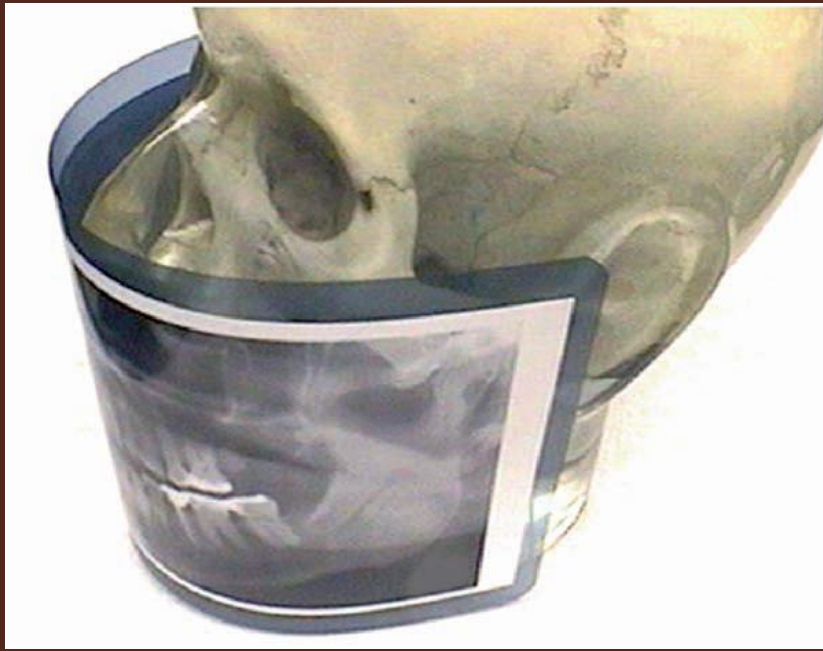- **Resultant Image:**
  - **Nose remains in the middle**
  - **Right and left sides of the jaws are on each side of the film**
  - **The spine (having been split in half) appears beyond the rami at the extreme right and left edges of the film.**

# CONCEPT 1

## STRUCTURES ARE FLATTENED AND SPREAD OUT

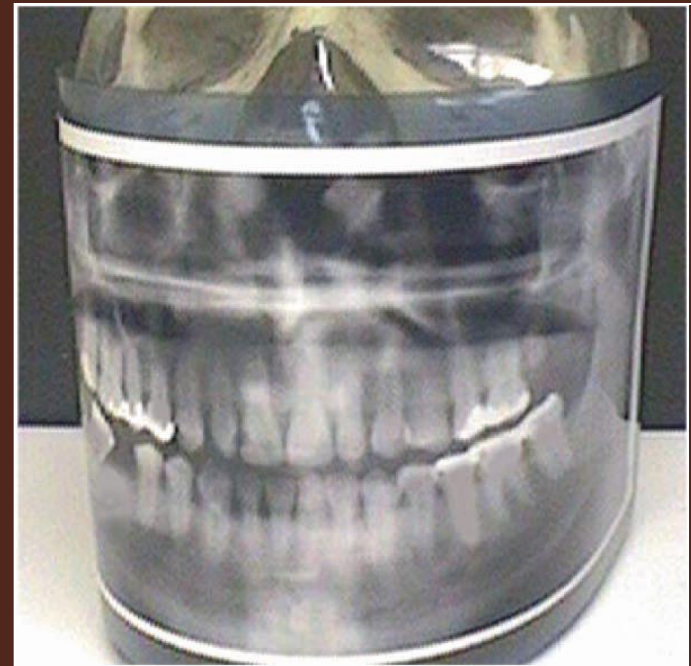





The lateral and more posterior structures are projected to each side of the panoramic radiograph

The anterior structures are shown in the midline of the standard panoramic projection



## Desirable effects:

1. The midline of the film corresponds to the anterior midline of the patient and right and left hand edges correspond to the posterior midline of the patient.
2. The right and left halves of the jaws and maxillofacial complex can be seen side by side on the film without one half being superimposed on the other.

## CONCEPT 2

MIDLINE STRUCTURES MAY  
PROJECT AS SINGLE OR DOUBLE  
IMAGES

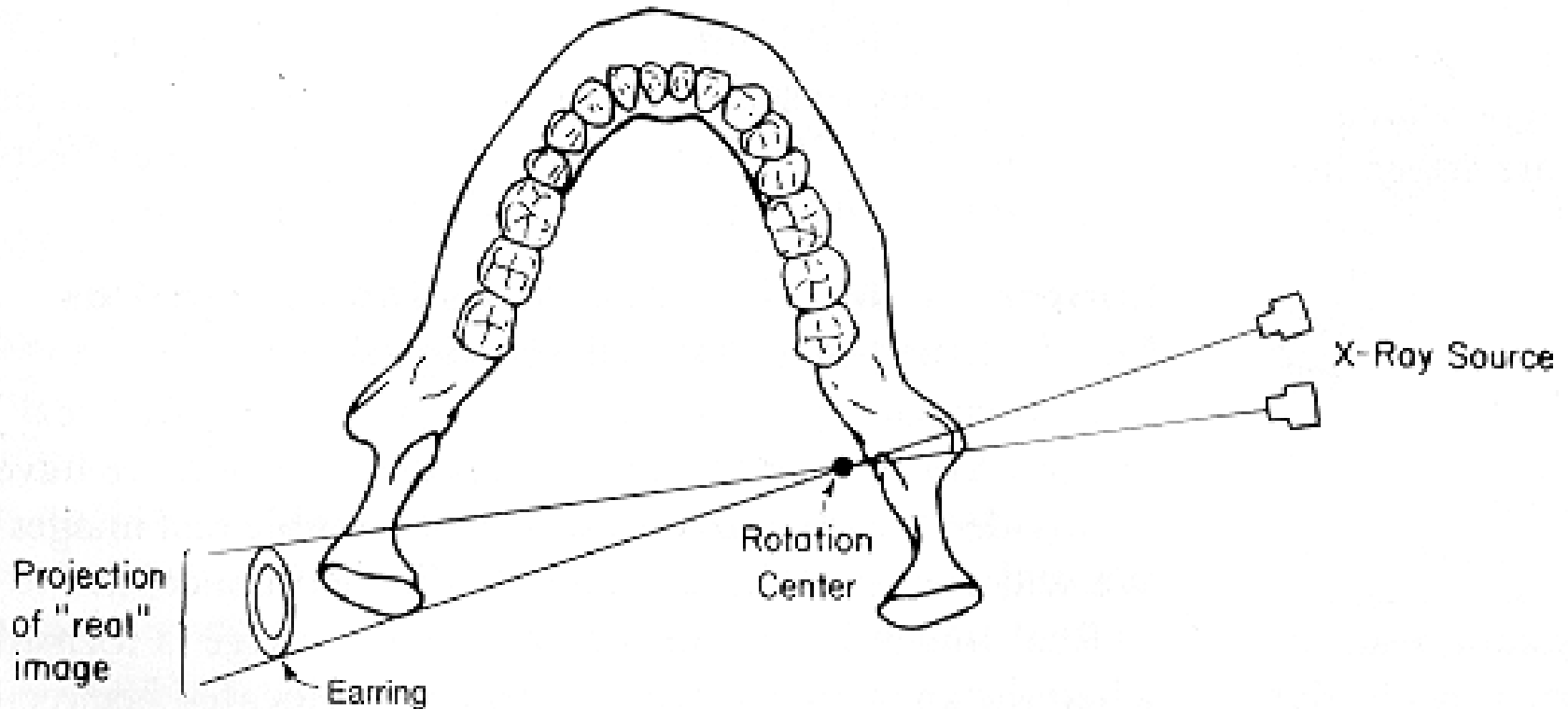
# CONCEPT 2

## MIDLINE STRUCTURES MAY PROJECT AS SINGLE OR DOUBLE IMAGES

- Real image formation:
  - Single
  - Double

# CONCEPT 2

## MIDLINE STRUCTURES MAY PROJECT AS SINGLE OR DOUBLE IMAGES



*(Langland)*

# **CONCEPT 2**

## **MIDLINE STRUCTURES MAY PROJECT AS SINGLE OR DOUBLE IMAGES**

- **Some midline structures fall within the focal trough twice; beam intercepts these objects twice due to machine**

# CONCEPT 2

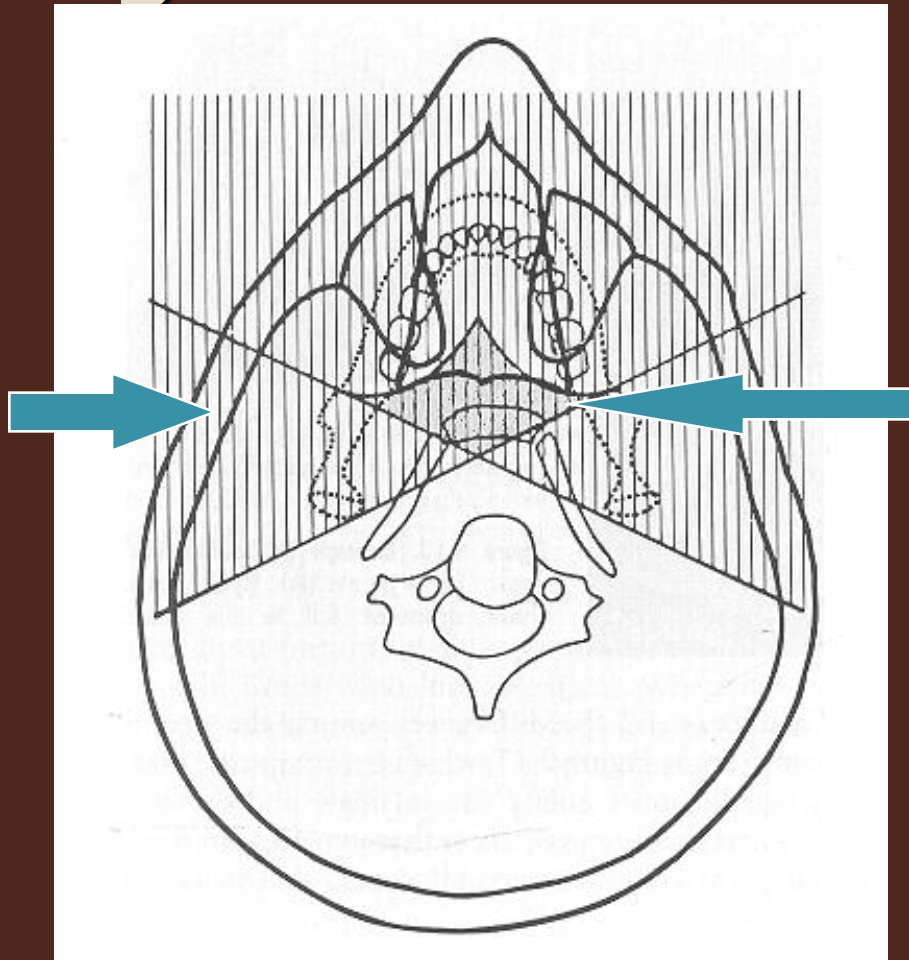
## MIDLINE STRUCTURES MAY PROJECT AS SINGLE OR DOUBLE IMAGES

- *A double real image* is a pair of real images formed by objects located in the central portion of the oral & maxillofacial region.
- Double images are mirror images of each other.

# Concept 3: Midline Structures May Project as Single or Double Images

Vertical  
hatch  
marks =  
real image  
formation

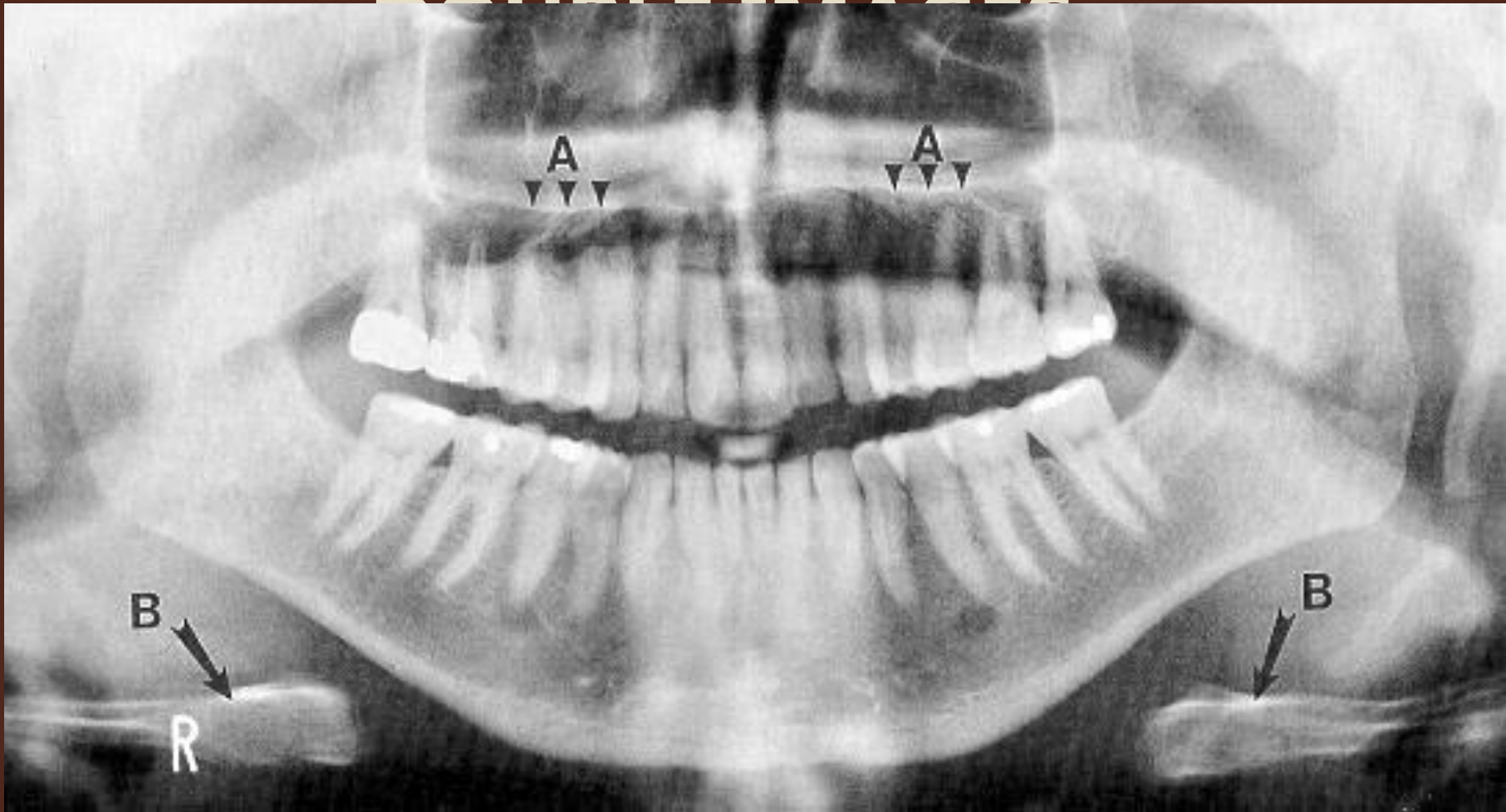
*(Langland)*



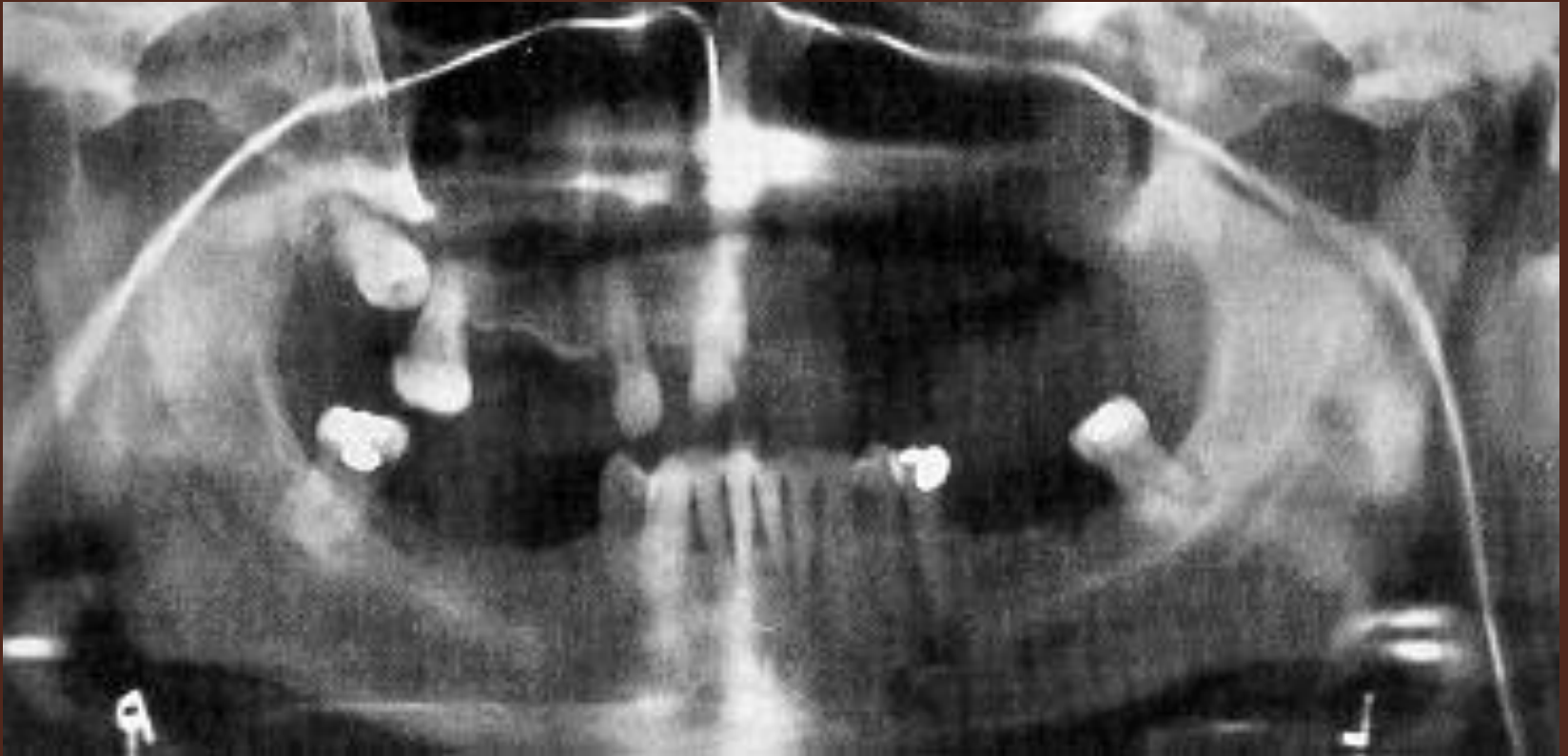
Double real  
images  
formed in  
central  
diamond-  
shaped  
region

# CONCEPT 2

## MIDLINE STRUCTURES MAY PROJECT AS SINGLE OR



**CONCEPT 2**  
**MIDLINE STRUCTURES MAY**  
**PROJECT AS SINGLE OR**  
**DOUBLE IMAGES**

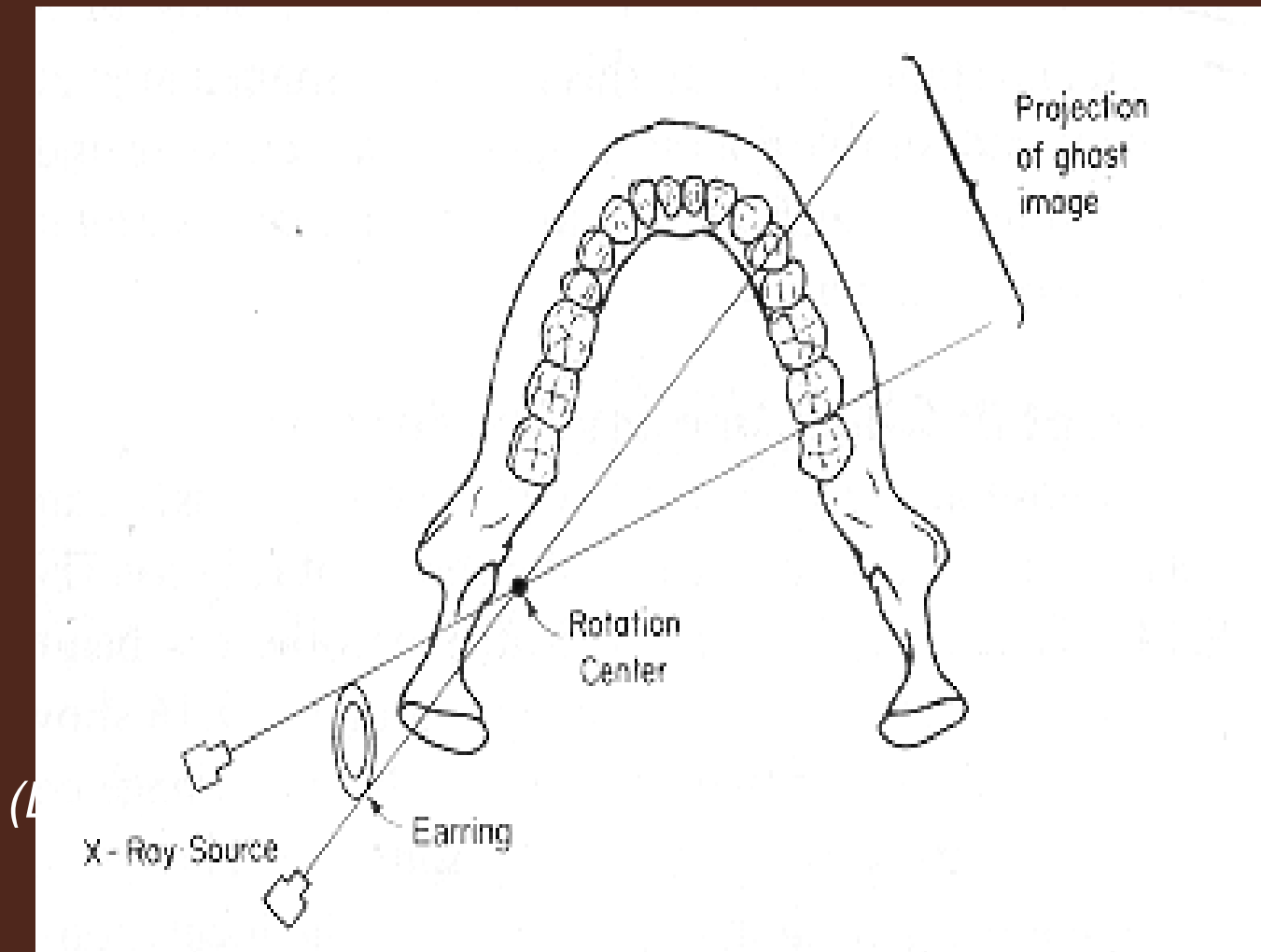


CONCEPT 3

GHOST IMAGES ARE FORMED

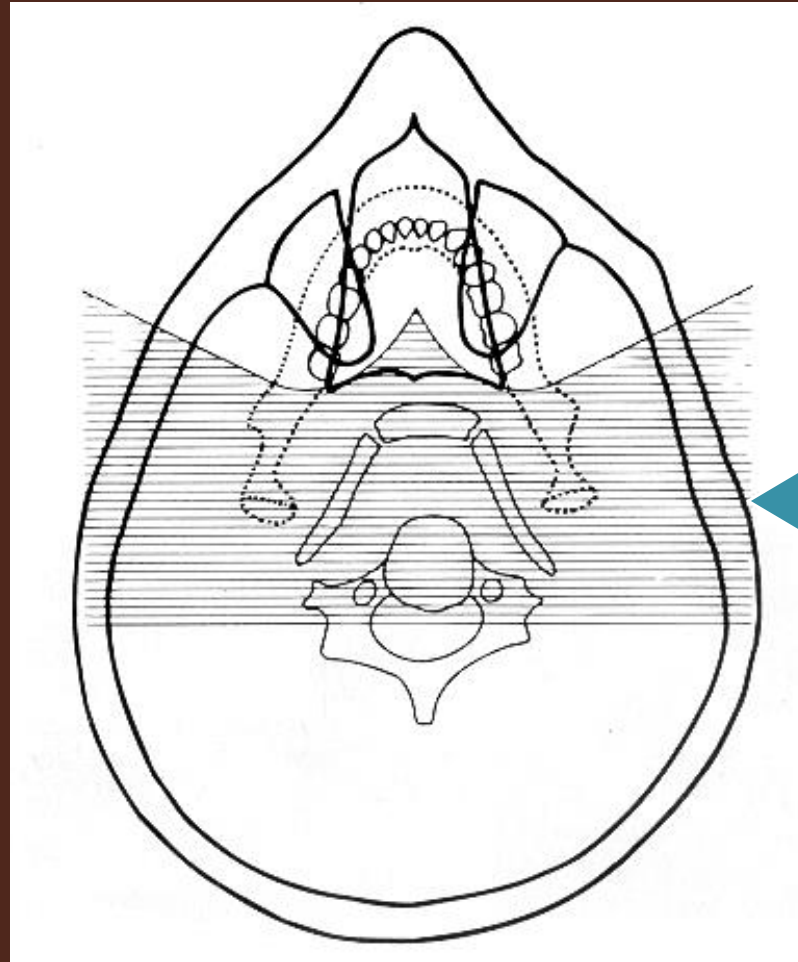
# CONCEPT 3

## GHOST IMAGES ARE FORMED



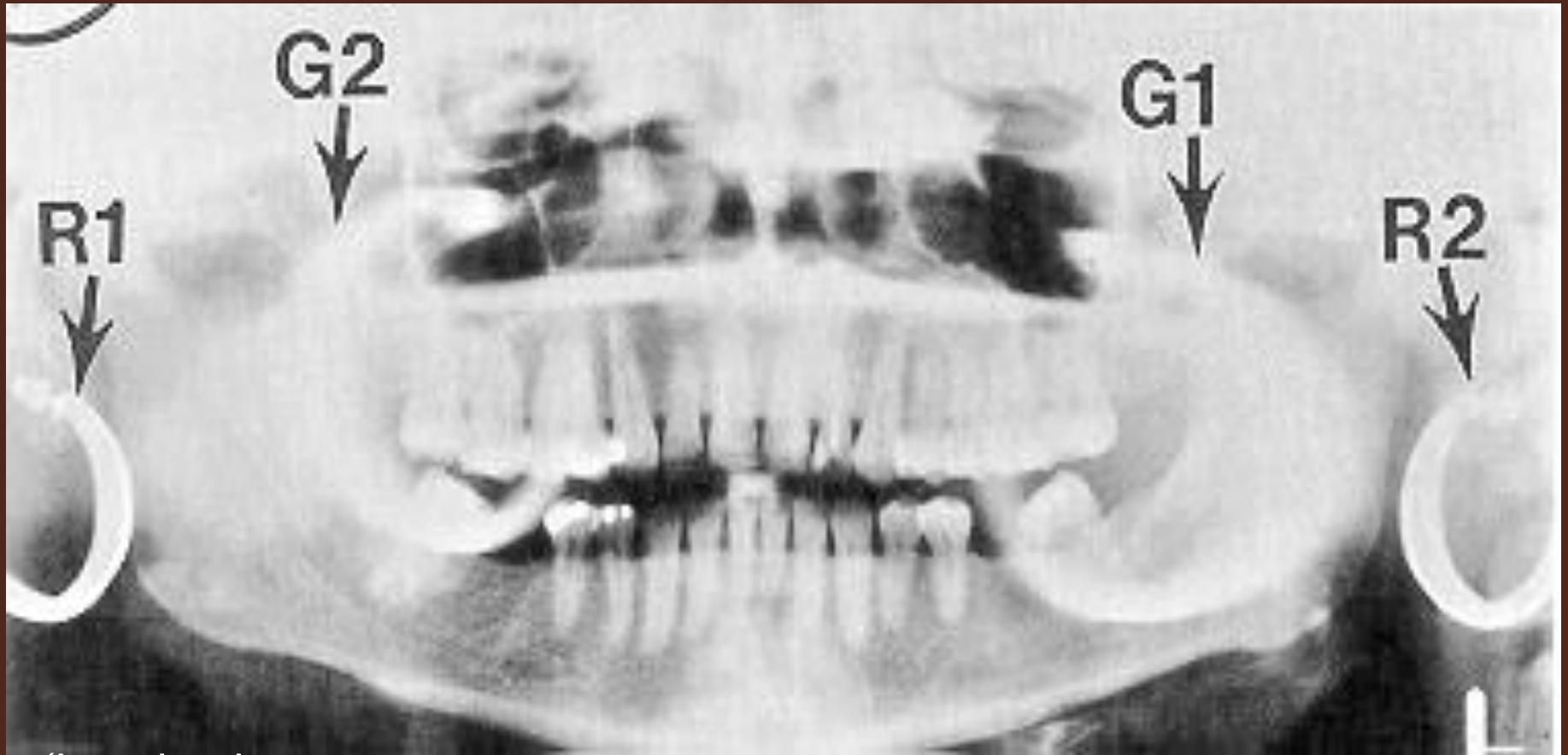# Concept 3

## GHOST IMAGES ARE FORMED



Horizontal hatch marks represent the region where ghost images form

# CHARACTERISTICS OF GHOST IMAGES



*(Langland)*

# SUMMARY OF SINGLE & DOUBLE REAL IMAGES & GHOST IMAGES

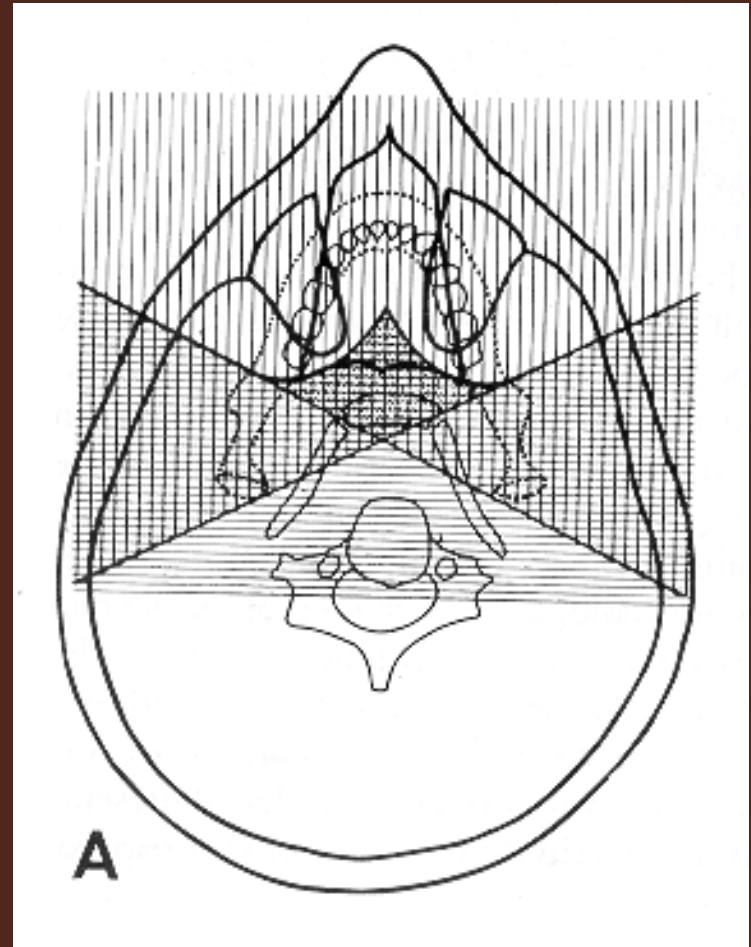
## Hatch marks:

Vertical = Real images

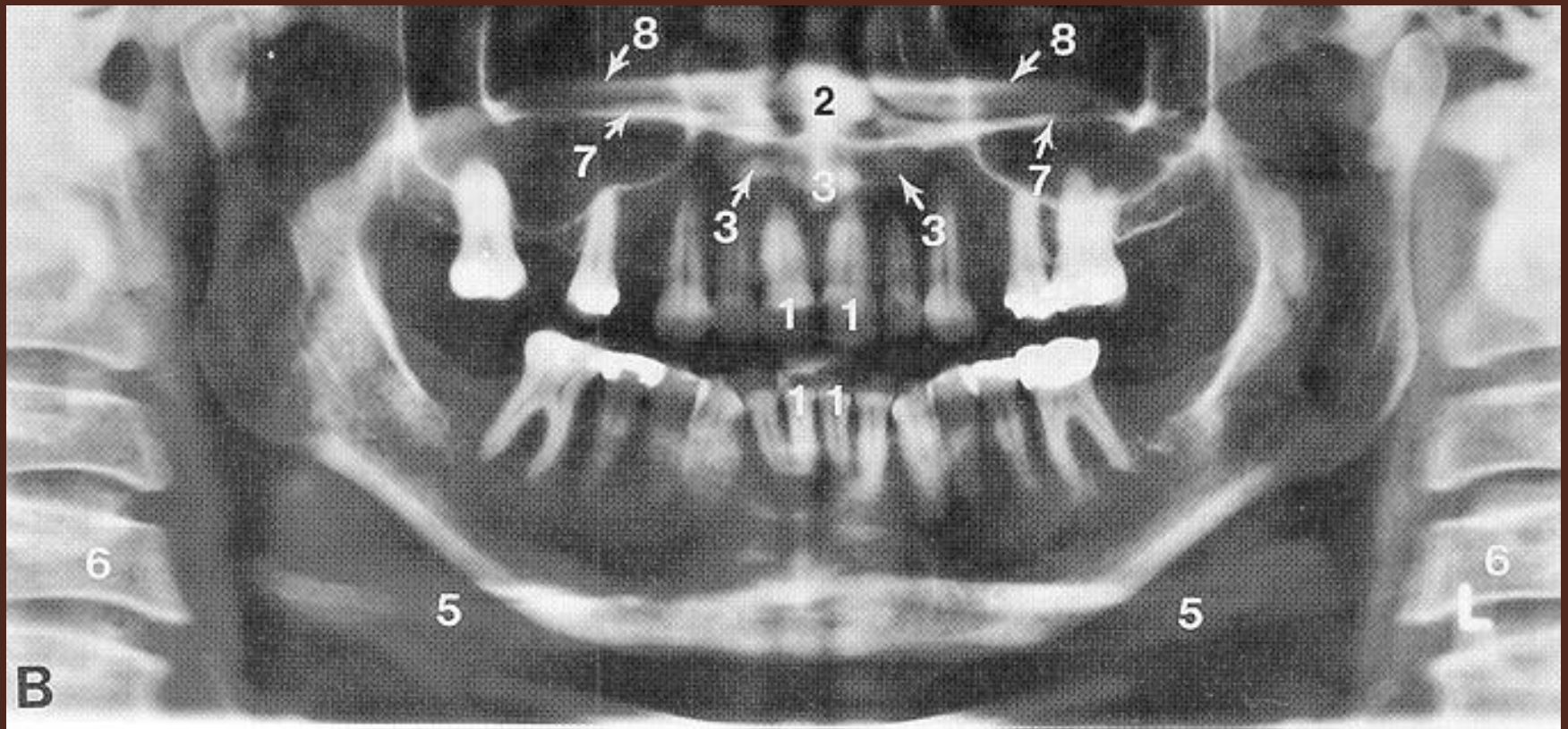
Horizontal = Ghost images

Both = Single real & ghost

Diamond = Double real & ghost



# SUMMARY OF SINGLE & DOUBLE REAL IMAGES & GHOST IMAGES



CONCEPT 4  
SOFT TISSUE SHADOWS ARE  
SEEN

# **CONCEPT 4**

## **SOFT TISSUE SHADOWS ARE SEEN**

- Soft tissue structures attenuate the beam of radiation to sufficient degree to become visible in the radiograph

# **Concept 4**

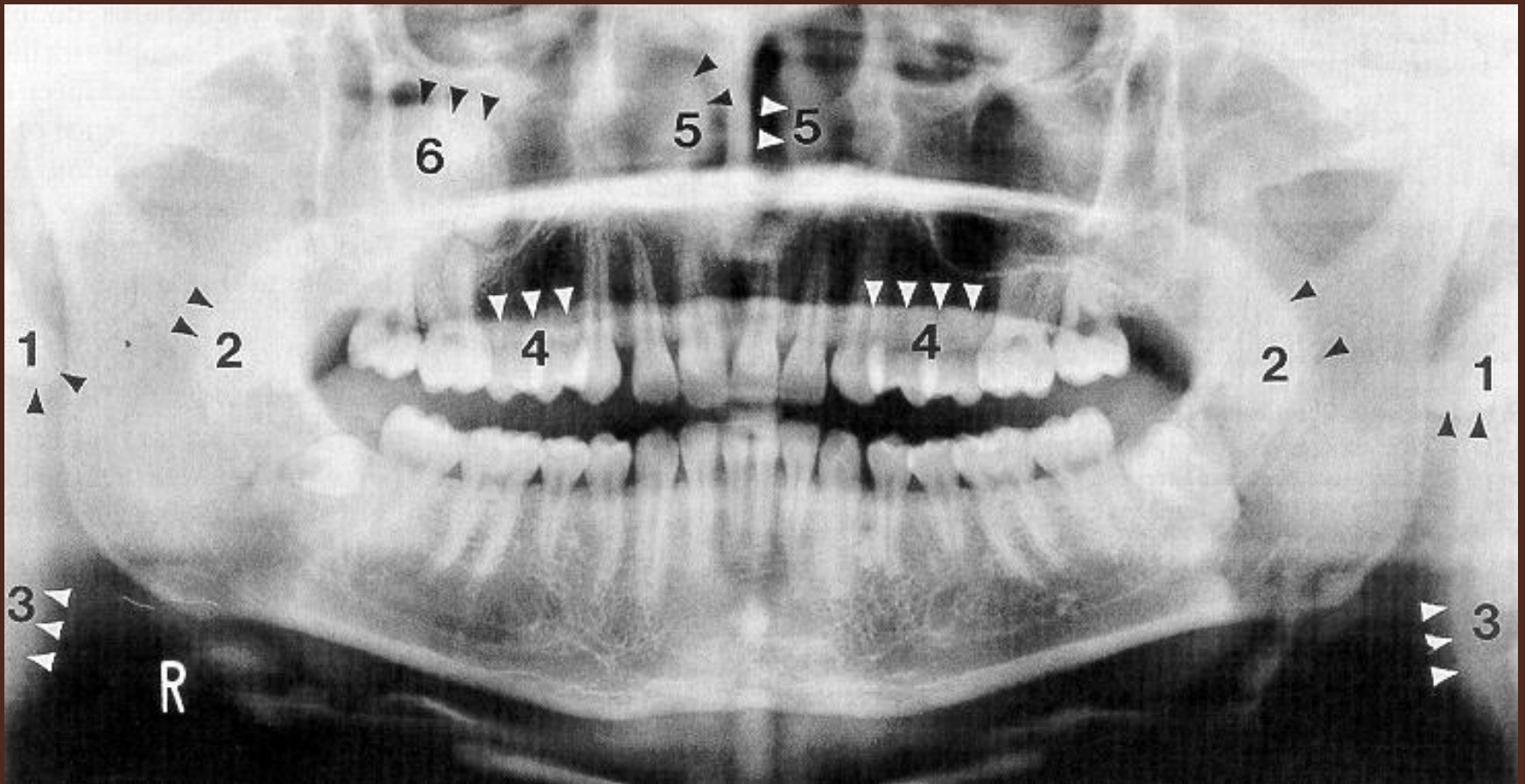
## **SOFT TISSUE SHADOWS ARE SEEN**

- **Visualization of the tongue, ears, nose and nasal turbinates spread-out are indications of technique errors.**

*(Langland)*

# Concept 4

## SOFT TISSUE SHADOWS ARE SEEN



CONCEPT 5

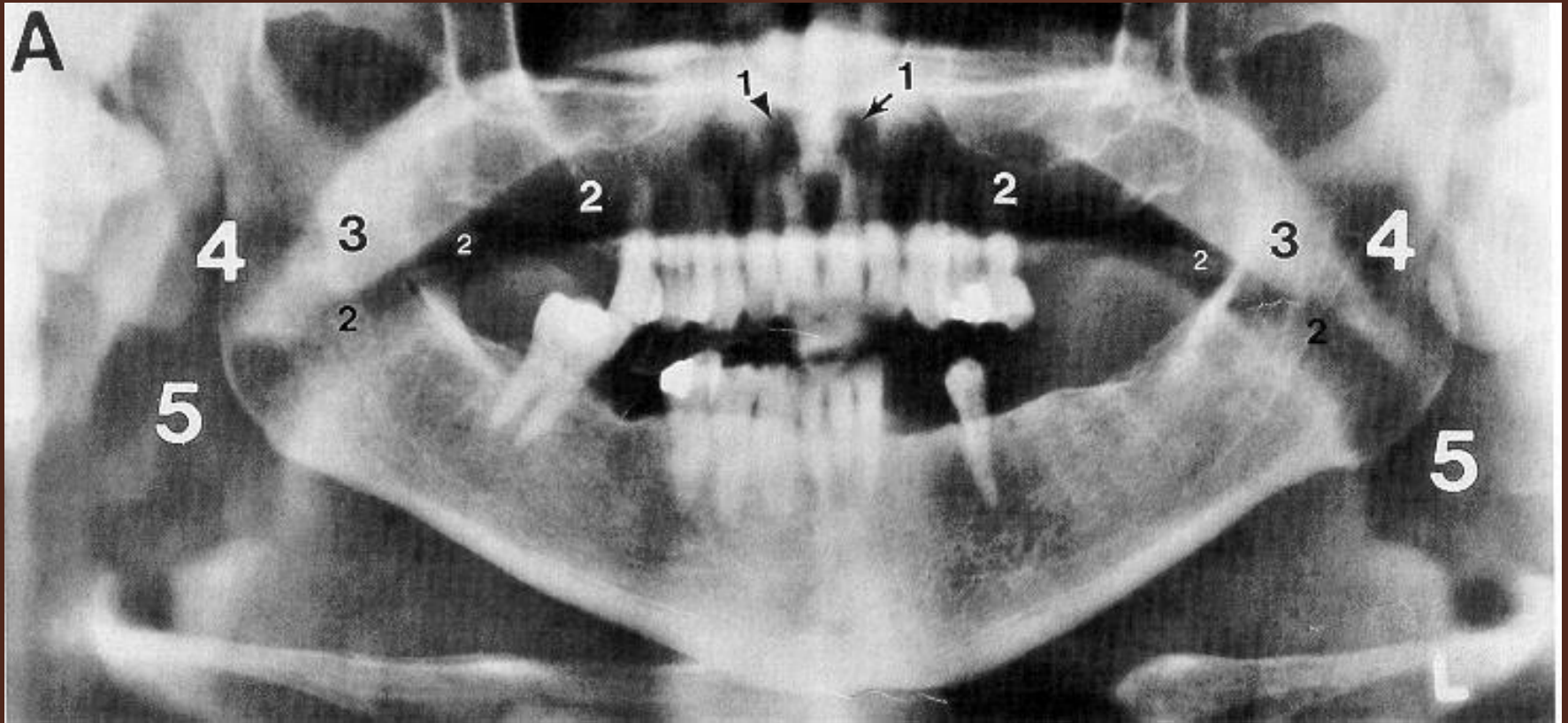
AIR SPACES ARE SEEN

# CONCEPT 5

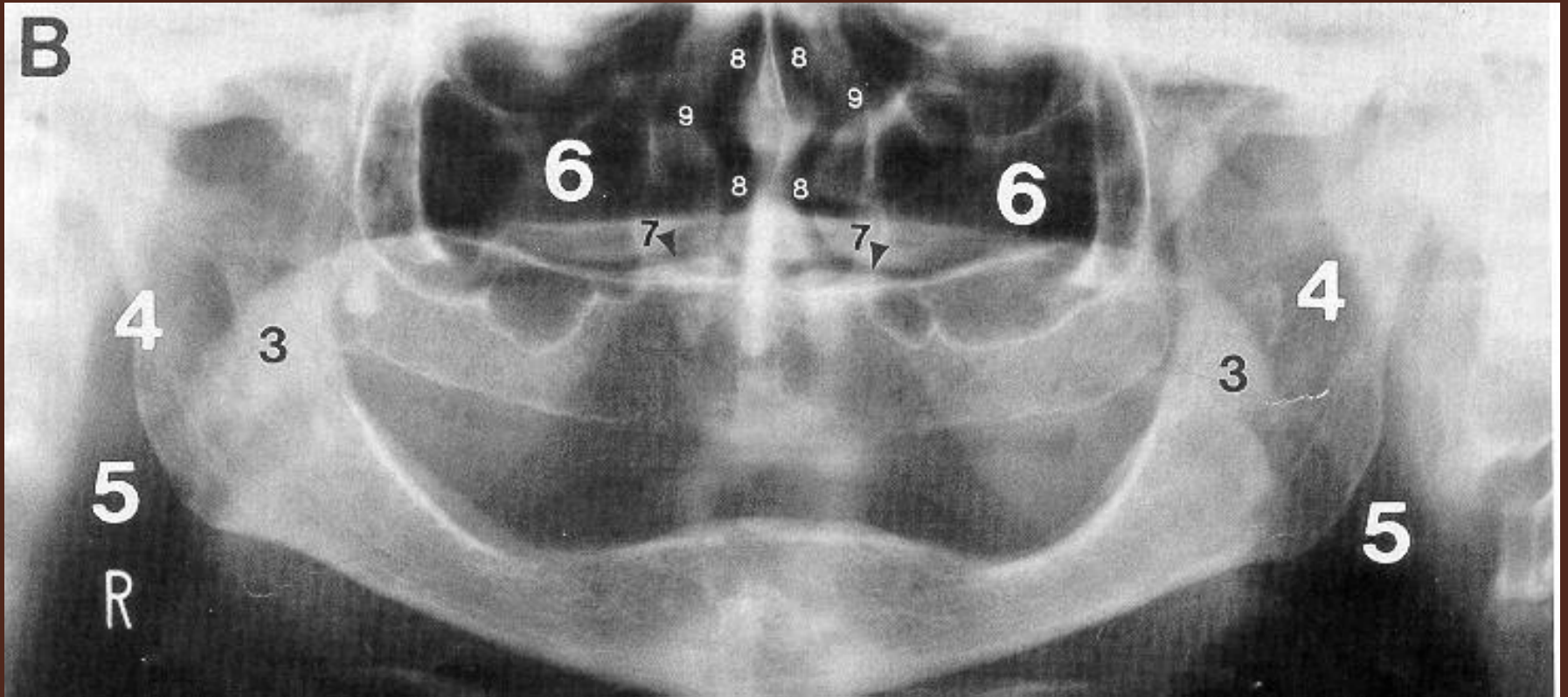
## AIR SPACES ARE SEEN

- Appear black
- Areas containing air do not attenuate the x ray beam as much as soft or hard tissue so it appear black
- Air space appearing above dorsum of tongue or anterior teeth is a *technique error*

# Concept 5: Air Spaces are Seen



# Concept 5: Air Spaces are Seen



CONCEPT 6:  
RELATIVE RADIOLUCENCIES &  
RADIOOPACITIES ARE SEEN

# **CONCEPT 6: RELATIVE RADIOLOGUCENCIES & RADIO PACITIES ARE SEEN**

- **Need to separate shadows originating from parts of machine from those coming from the client.**
  - **Machine parts are plastic with density similar to soft tissue**
  - **Easy to identify due to geometric/linear configuration**

# **CONCEPT 6**

## **RELATIVE RADIOLUCENCIES & RADIOPACITIES ARE SEEN**

- **All machine & client components (hard tissue, soft tissue & air) may produce single and/or double real images and ghost images.**
- **Thus, multiple areas consisting of relative density changes are produced.**

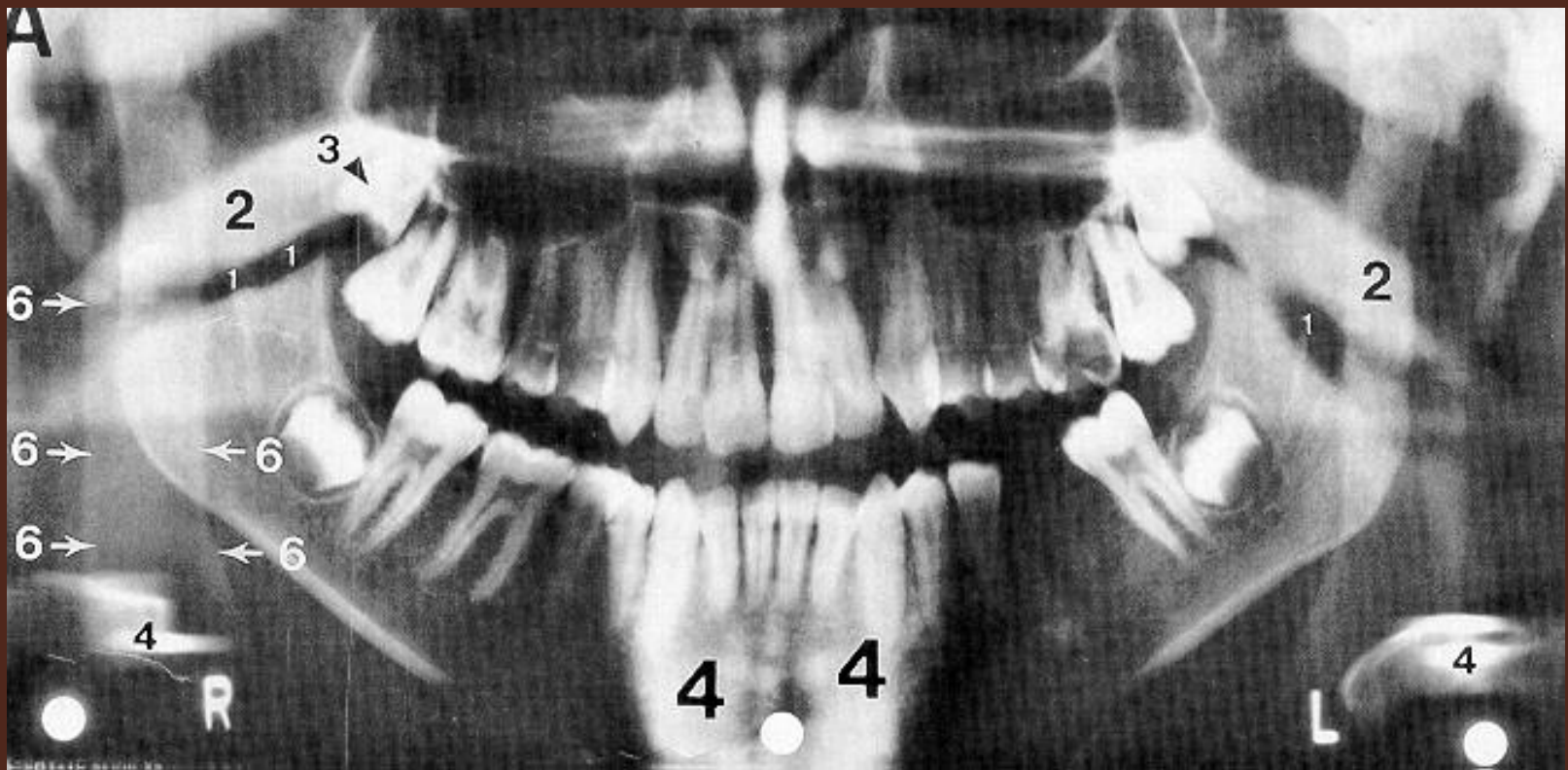
# **CONCEPT 6: RELATIVE RADIOLUCENCIES & RADIOPACITIES ARE SEEN**

- **Effects of Density Changes on Panoramic Radiographs**
  - **Air obscures hard tissues**
  - **Soft tissue obscures air**
  - **Hard tissue obscures soft tissue**
  - **Ghost images obscure everything**

*(Langland)*

# Concept 6

## RELATIVE RADIOIOLUCENCIES & RADIOOPACITIES ARE SEEN



CONCEPT 7

PANORAMIC RADIOGRAPHS

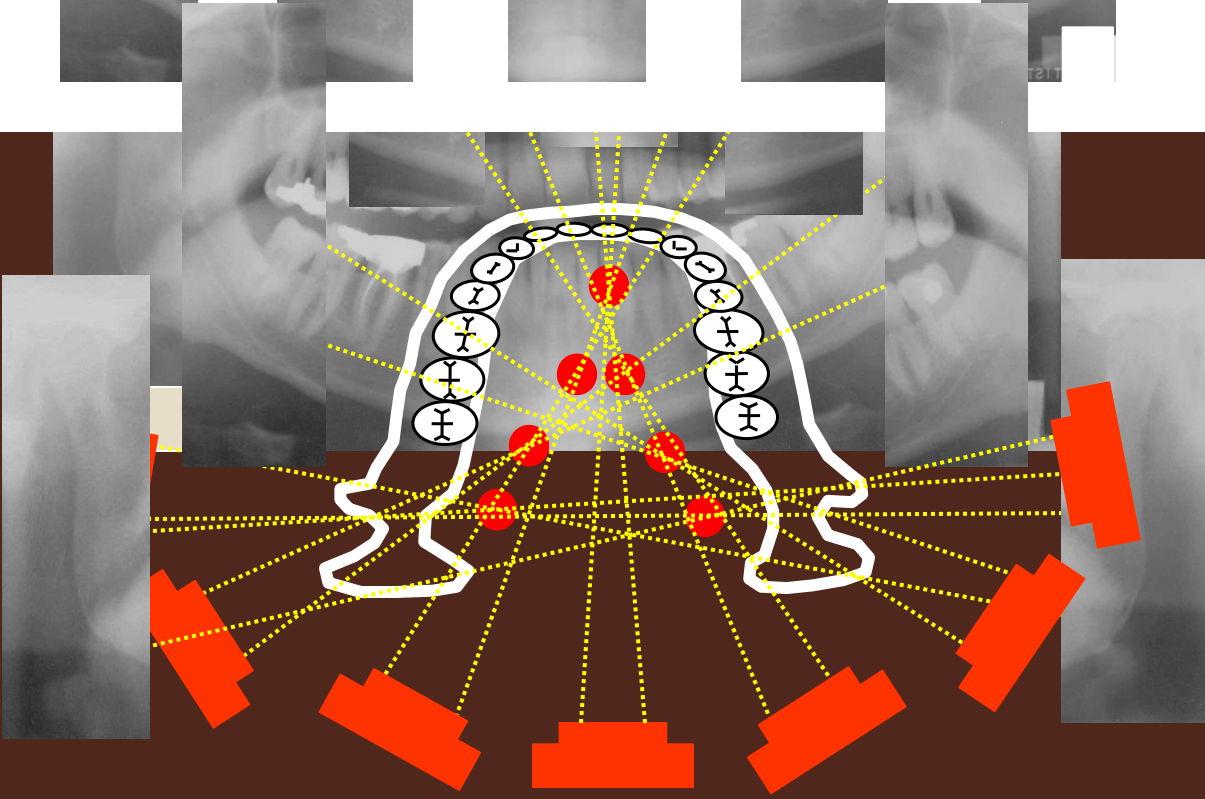
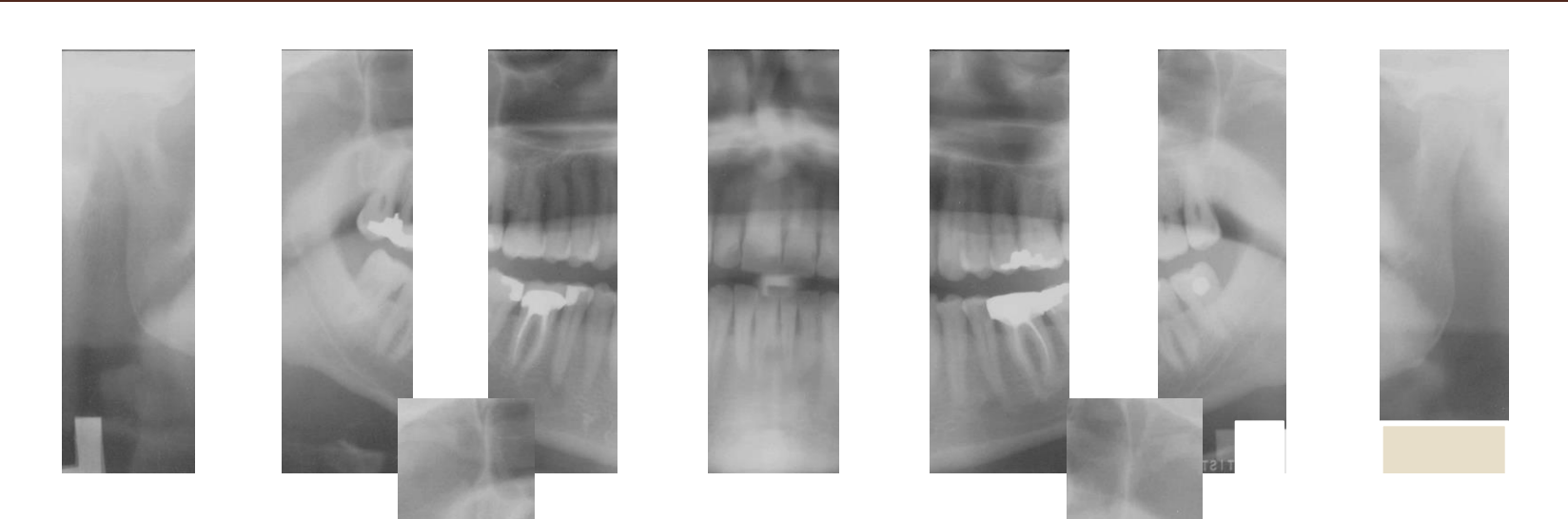
ARE UNIQUE

# **CONCEPT 7**

## **PANORAMIC RADIOGRAPHS ARE UNIQUE**

- **Scope of assessment & interpretive potential exceeds that of full mouth intra oral survey**
  - Relationship of teeth can be studied (crown & bridge, ortho, third molars)
  - Jaws can be studied: ramus, styloid process, tmj, sinus
  - Excellent for clients with trimus or trauma

- The principal advantages of panoramic images are
  - (1) their broad coverage of the facial bones and teeth
  - (2) low patient radiation dose
  - (3) the convenience of the examination for the patient
  - (4) the fact that it can be used in patients unable to open their mouths
  - (5) the short time required to make a panoramic image, usually in the range of 3 to 4 minutes



Thank you