

ORAL TUMORS

W. H. O Classification

Tumors of Dental Tissues

~~Lesions consisting of Odontogenic Epithelium~~

- Ameloblastoma
- Adenomatoid Od. Tumor
- Calcifying Ep. Od. Tumor
- Calcifying Od. Cyst

Lesions consisting of Od. Ep and mesenchyme

- Ameloblastic fibroma
- Ameloblastic sarcoma

Lesions consisting of Od. Ep & calcified dental tissues

- Odontoameloblastoma

ORAL TUMORS

W. H. O Classification

Tumors of Dental Tissues

Lesions consisting of calcified dental tissues
without Od. Epithelium

- Complex odontome
- Compound odontome
- Dens invaginatus
- Enameloma
- Dentinoma
- Cementoma

Lesions consisting of Od. mesenchyme

- Fibroma
- Myxoma

ORAL TUMORS

W. H. O Classification

Tumors of Non-Dental Tissues

Primary tumors of N D tissues

Epidermal

- Leukoplakia
- Sq. Cell papilloma
- Keratoacanthoma
- Sq. cell Ca & it's variants verrucous Ca, intraepidermal Ca and basal cell Ca.

Fibrous connective tissue

- Fibroma, myxoma, fibrosarc.
- Fibrous epulis, denture fibrosis, pyogenic granuloma
- Fibromatosis
- Fibrous histiocytoma

ORAL TUMORS

W. H. O Classification

Tumors of Non-Dental Tissues

Primary tumors of N D tissues

Adipose

- Lipoma, liposarcoma

Cartilage

- Chondroma, chondrosarcoma

Bone

- Osteoma, osteomatosis
- Osteoid osteoma
- Torus palatinus & mand.
- Osteosarcoma

Vascular tissue

- Hemangioma, angiosarcoma, lymphangioma

ORAL TUMORS

W. H. O Classification

Tumors of Non-Dental Tissues

Primary tumors of N D tissues

Neural tissue

- Neurilemmoma
- Neurofibroma
- Neurofibromatosis

Muscle

- Leiomyoma, leiomyosarc,

Lymphoid tissue

- lymphoma
- leukemia

Myeloma

ORAL TUMORS

Histopathologic classification of Odontogenic tumors

Epithelial origin

ORAL TUMORS

Histopathologic classification of Odontogenic tumors

Mesodermal origin

- Odontogenic myxoma
- Central odontogenic fibroma
- Cementomas
 - Periapical cemental dysplasia
 - Familial multiple gigantiform cementoma
 - Cementifying fibroma
 - Cementoblastoma

ORAL TUMORS

Histopathologic classification of Odontogenic tumors

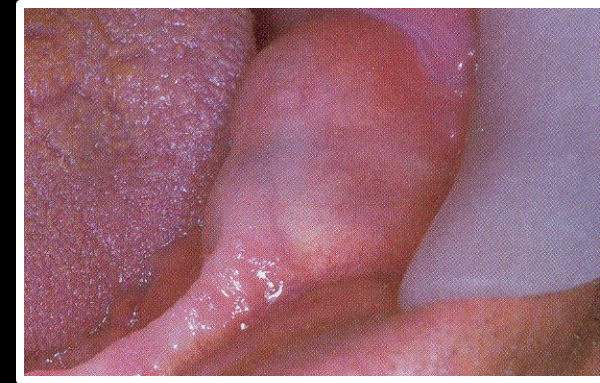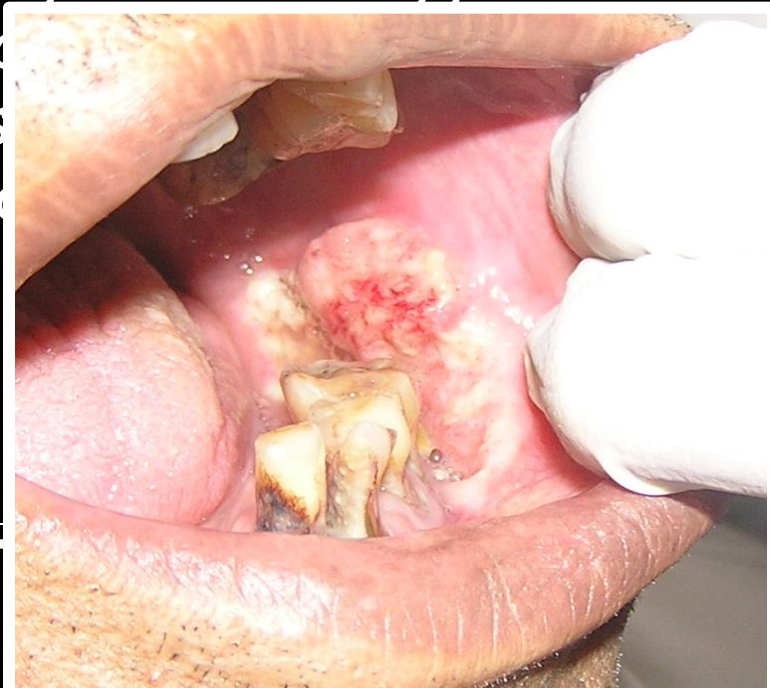Mixed ectodermal & mesodermal origin

- Ameloblastic fibroma
- Ameloblastic fibro-odontoma
- Odontomas
 - Complex
 - Compound

BENIGN TUMORS

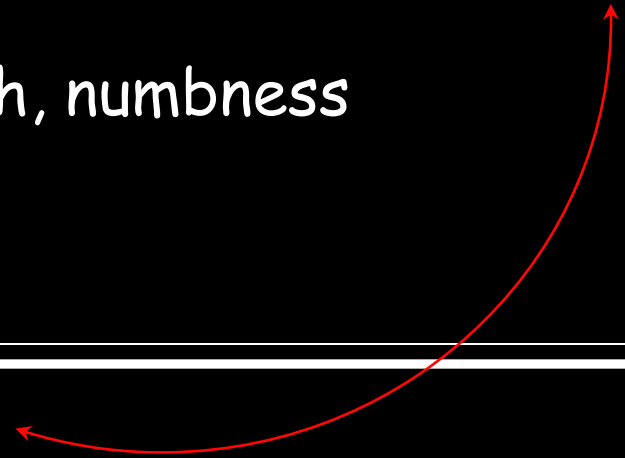
General Features

- Round or oval in shape, usually definitive
- Surface smooth or nodular
- Overlying skin or mucosa normal
- Expansion of bone
- Thinning of bone- 'egg shell crackling'
- Displacement of teeth
- Painless
- Pathological fracture
- Facial swelling



ted

th, numbness



RADIOGRAPHIC FEATURES

BENIGN

V/S

MALIGNANT

Well defined borders

Ill defined borders



RADIOGRAPHIC FEATURES

BENIGN

V/S

MALIGNANT

Round or oval shape

Impossible to establish exact limit of lesion on Rg



RADIOGRAPHIC FEATURES

BENIGN

V/S



MALIGNANT

Growth by displacement

- Expansion of cortex
- Bone resorbed on inner side
- Reactive periosteal bone

Growth by infiltration

- Destruction of adjacent structures
- Rapid destruction of cortex
- 'Sun burst'
- Soft tissue mass



RADIOGRAPHIC FEATURES


BENIGN

V/S

MALIGNANT

- Resorption of roots &
- Displacement of teeth

- Rapid growth
- Roots intact, teeth left in position



AMELOBLASTOMA

Most common of odontogenic tumors

~~Benign , but locally invasive hence - 'locally malignant'~~

Occurance

- Male = Female
- 80% mandible- 3/4th posterior jaws
- 20 - 50years peak incidence
- Post. Mandible- thick cortical plates limit expansion
- Max. cases- close to nasal cavity, paranasal sinus, orbital cavity, pharyngeal tissues & base of skull

ODONTOMA

Most common

Benign, but

Clinical Fe

• Slow growth

• Migration, loosening of teeth, root resorption

lip p

• Typi

than

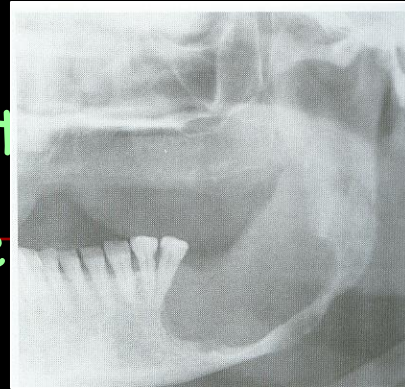

• Pain

• Exp

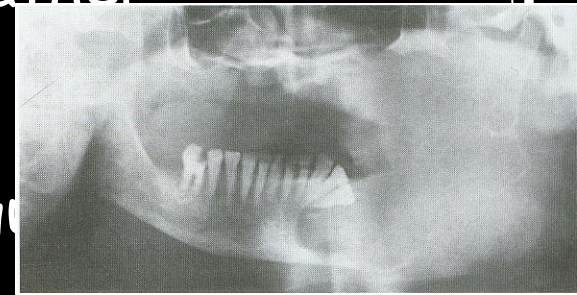
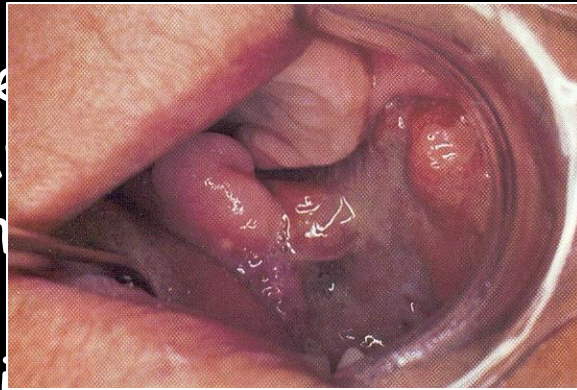
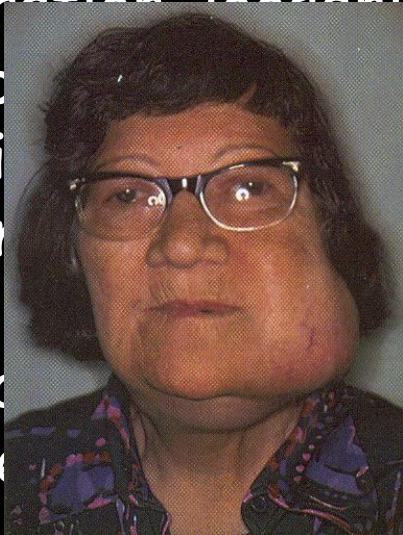
• Ulc

• Trauma → development (extn., cystectomy, other)

• Extn. of teeth frequently effect rather than cause



'alignant'




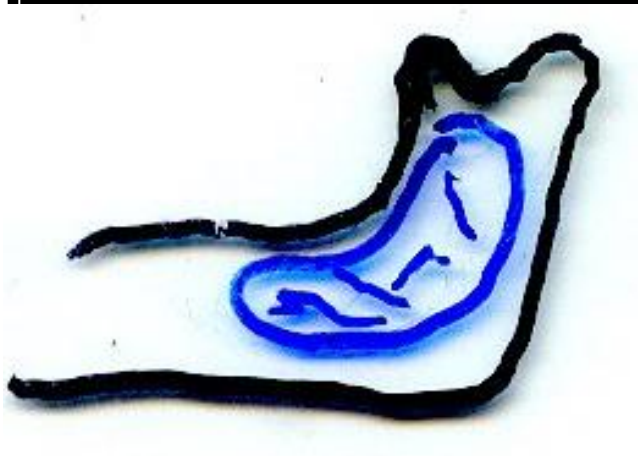


AMELOBLASTOMA

Radiographic Features

I. Dental cyst in ramus- extending into horizontal portion of mand.- presence of septae

Cyst with loss of wall $\left\{ \begin{array}{l} \text{ant.} \\ \text{sup.} \end{array} \right. + \text{septae}$

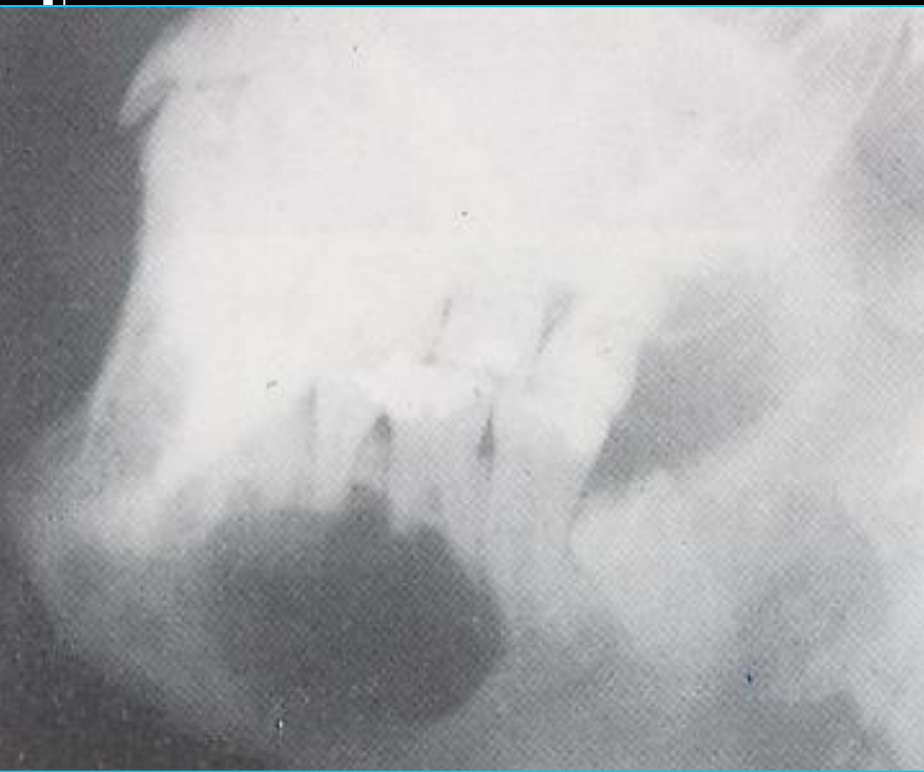


AMELOBLASTOMA

Radiographic Features

I. Dental cyst in ramus- extending into horizontal portion
of mand.- presence of septae

Cyst with loss of wall $\left\{ \begin{array}{l} \text{ant.} \\ \text{sup.} \end{array} \right. + \text{septae}$

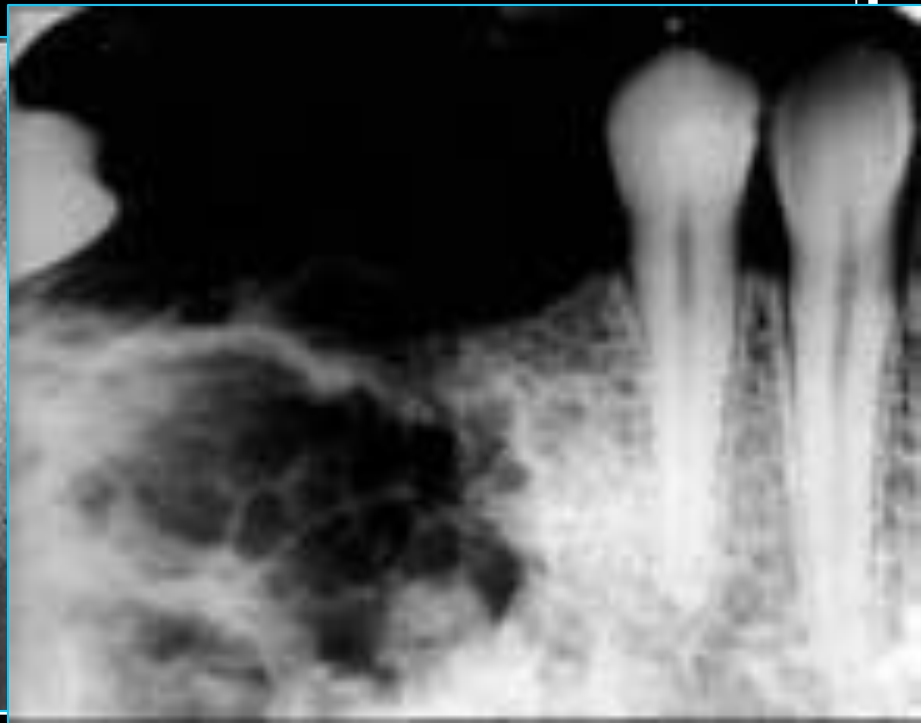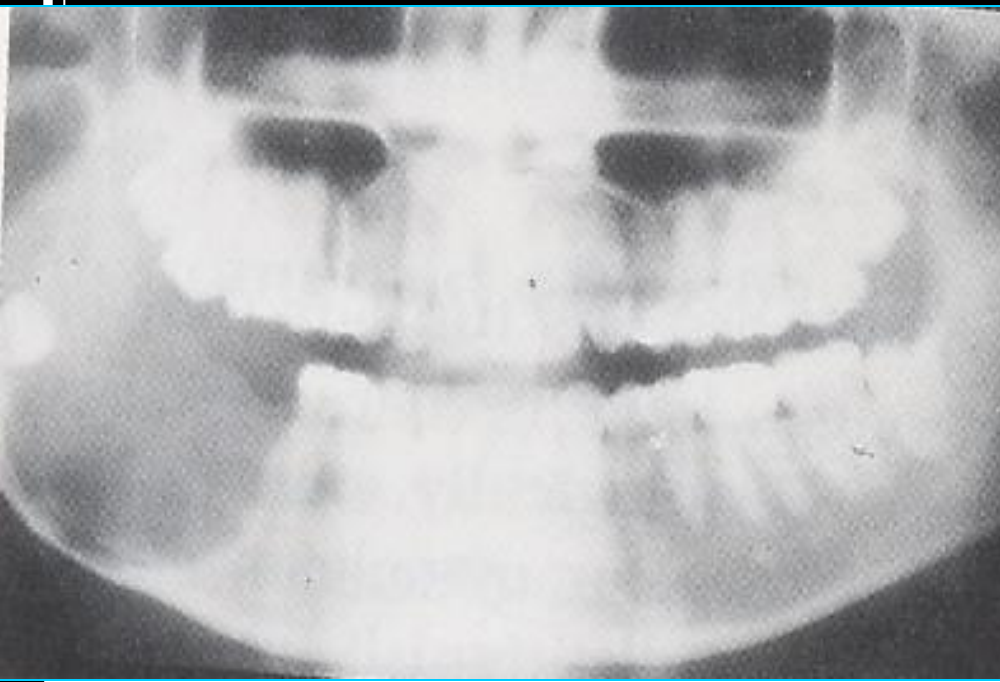


AMELOBLASTOMA

Radiographic Features

I. Dental cyst in ramus- extending into horizontal portion of mand.- presence of septae

Cyst with loss of wall $\left\langle \begin{array}{l} \text{ant.} \\ \text{sup.} \end{array} \right.$ + septae



AMELOBLASTOMA

Radiographic Features

II. Area of bone destruction- curved margins-trabeculae

Thin
septae



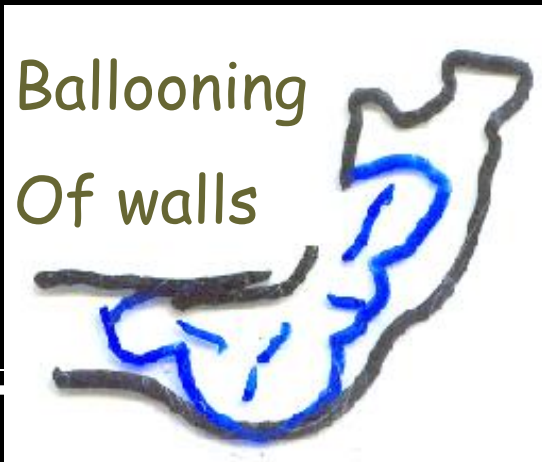
spider



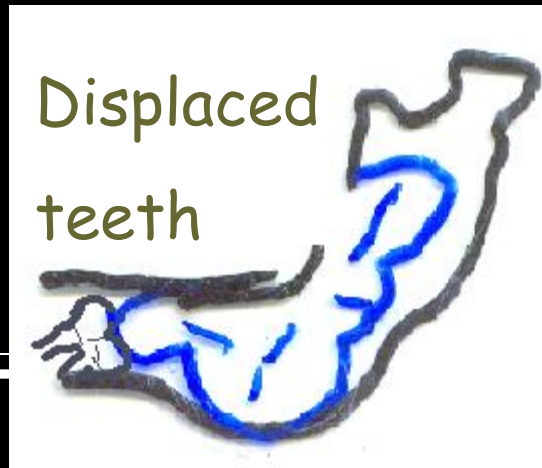Loss of
wall



Ballooning
Of walls



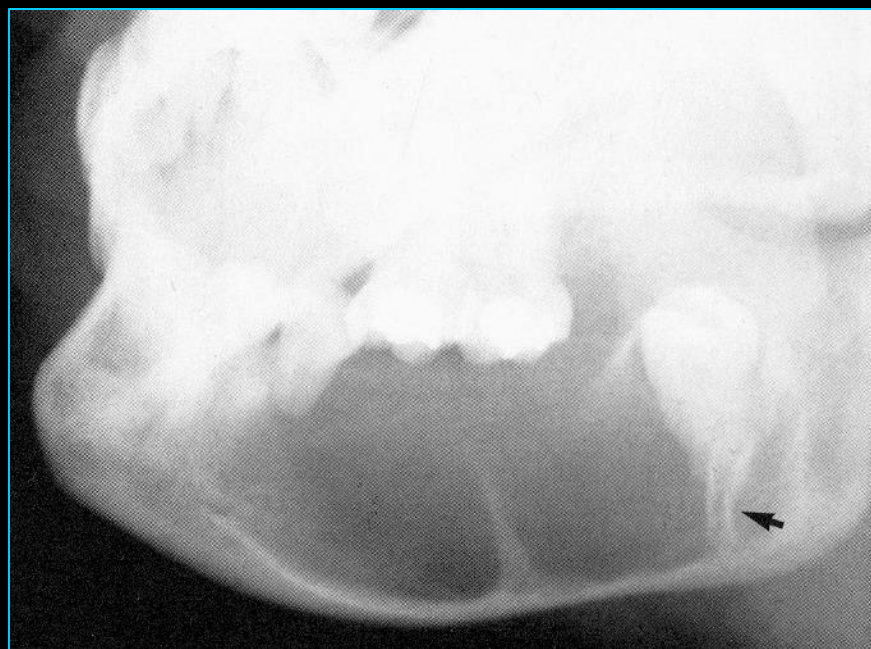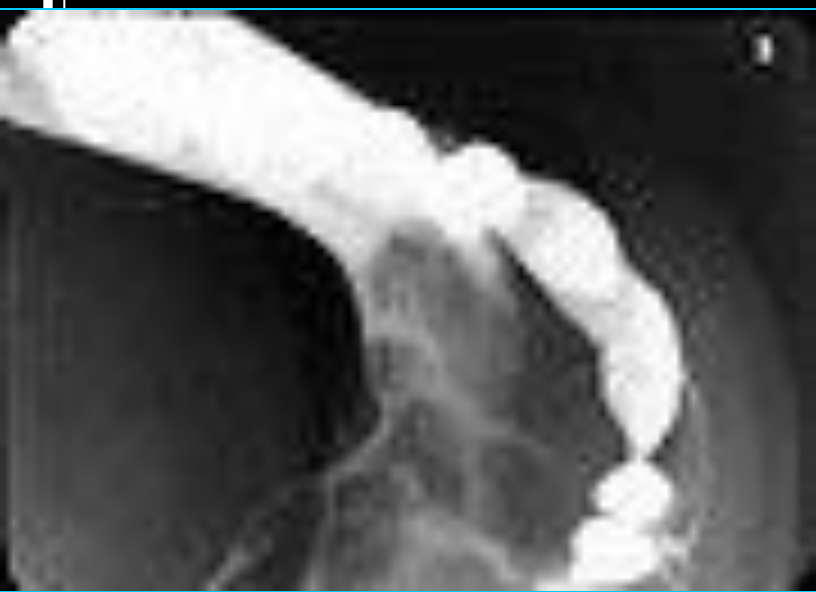Displaced
teeth



AMELOBLASTOMA

Radiographic Features

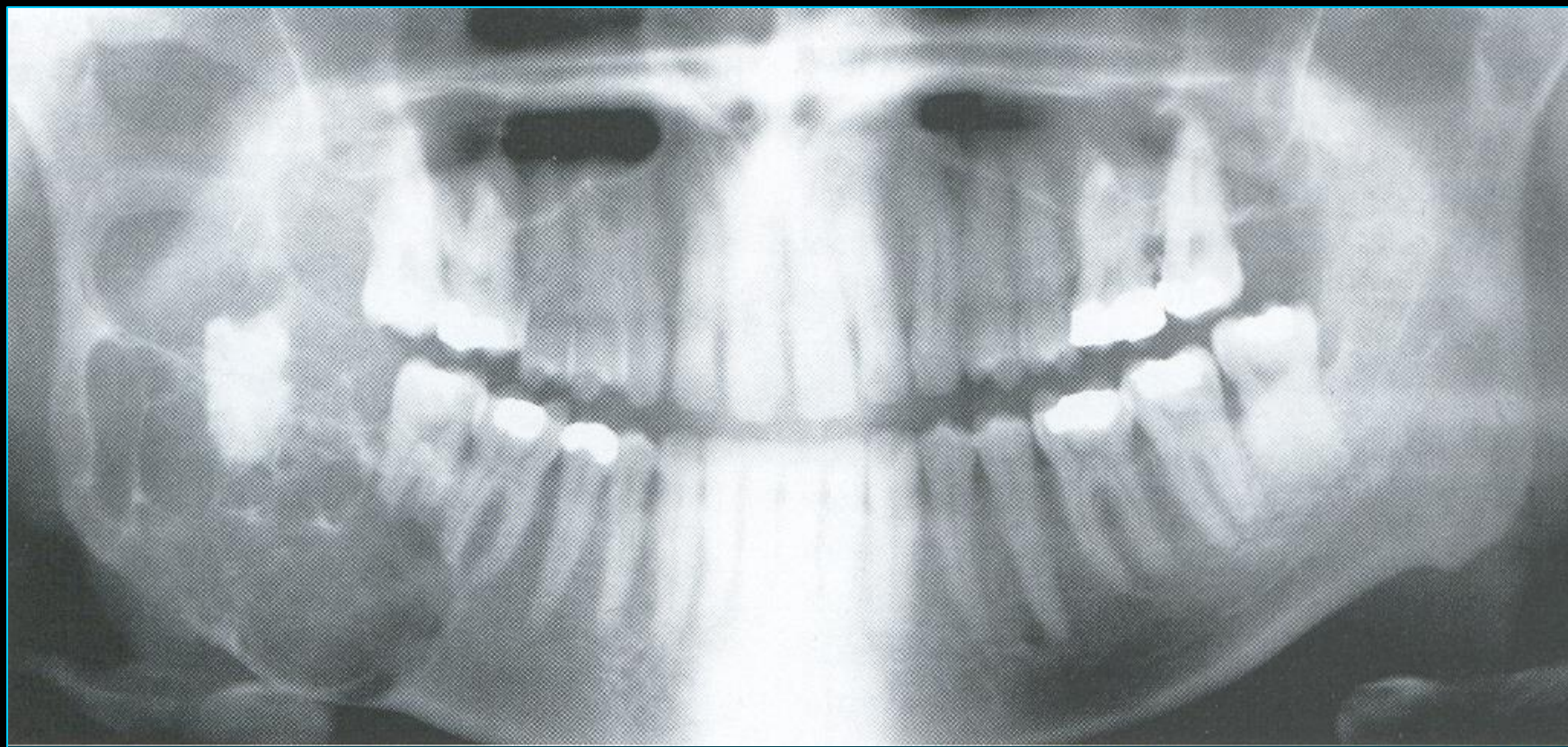
II. Area of bone destruction- curved margins-trabeculae



AMELOBLASTOMA

Radiographic Features




II. Area of bone destruction- curved margins-trabeculae



AMELOBLASTOMA

Radiographic Features

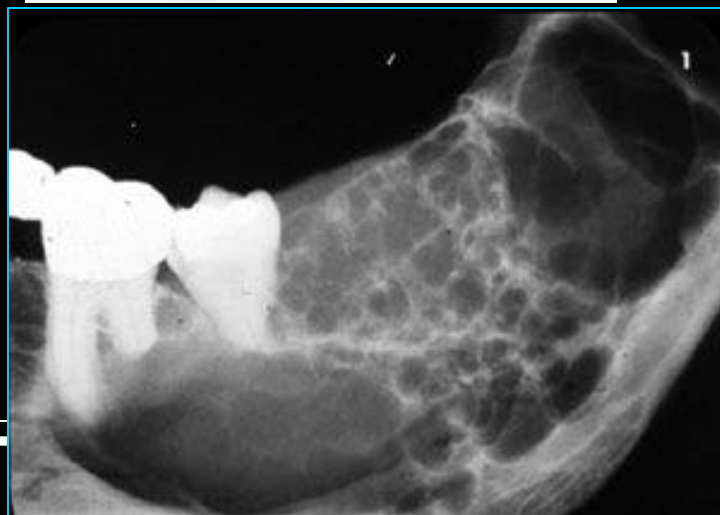



III. Multilocular cyst- Root resorption



AMELOBLASTOMA

Radiographic Features

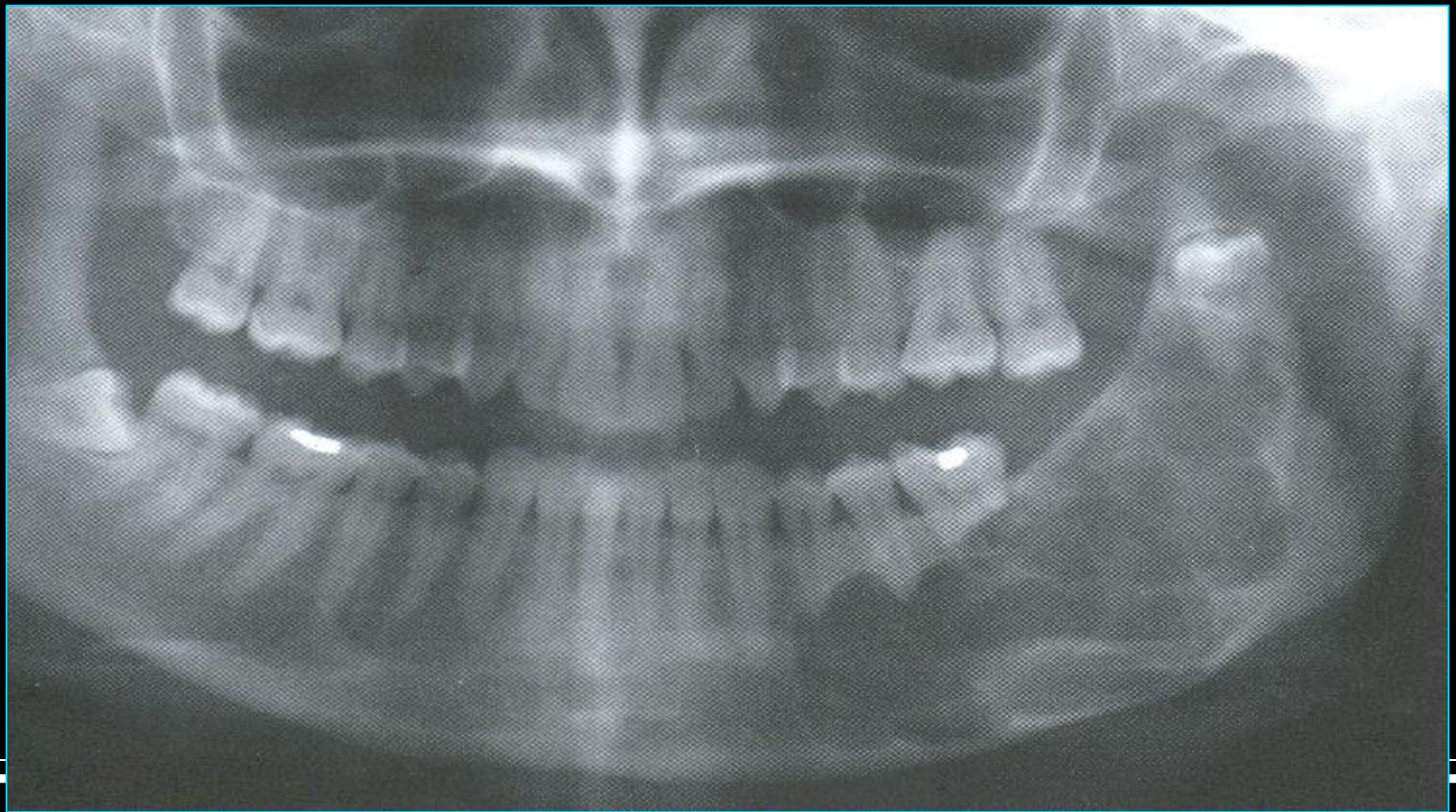
III. Multilocular cyst- Root resorption



AMELOBLASTOMA

Radiographic Features

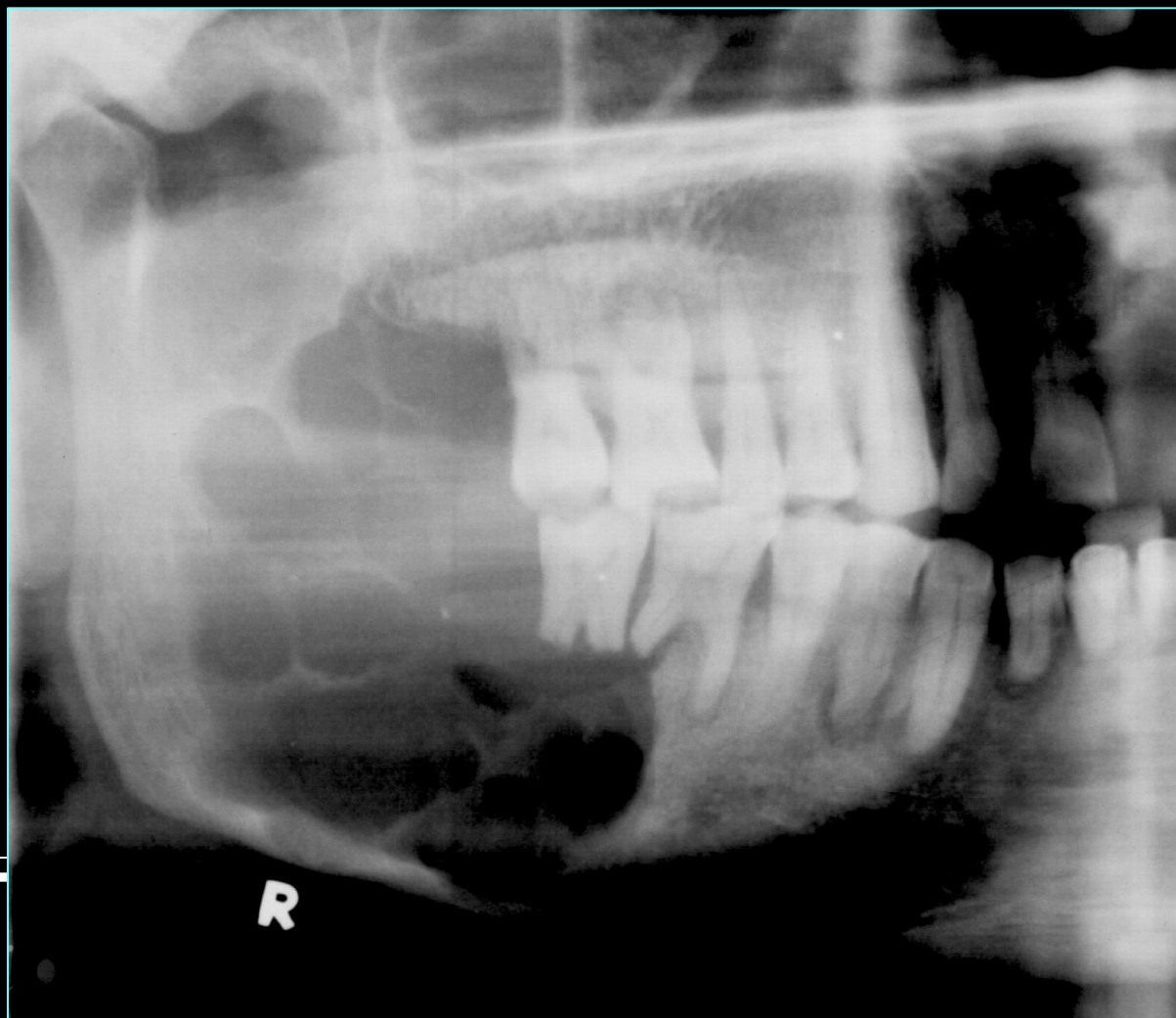
III. Multilocular cyst- Root resorption



AMELOBLASTOMA

Radiographic Features

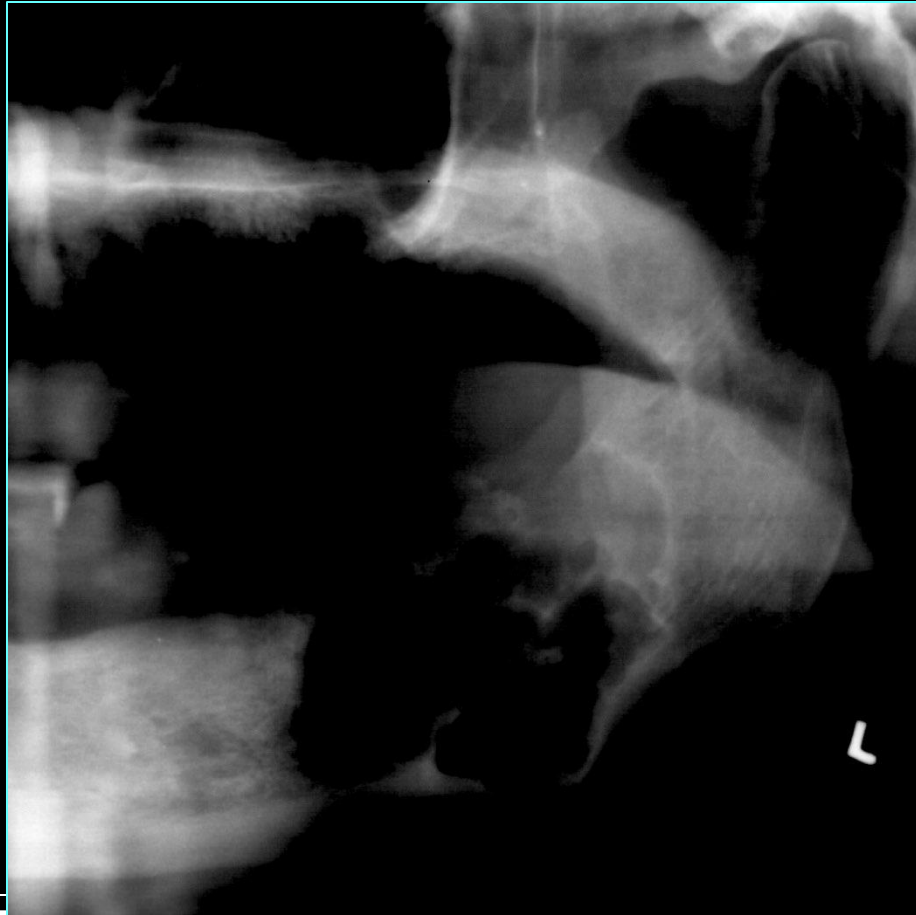
III. Multilocular cyst- Root resorption



AMELOBLASTOMA

Radiographic Features

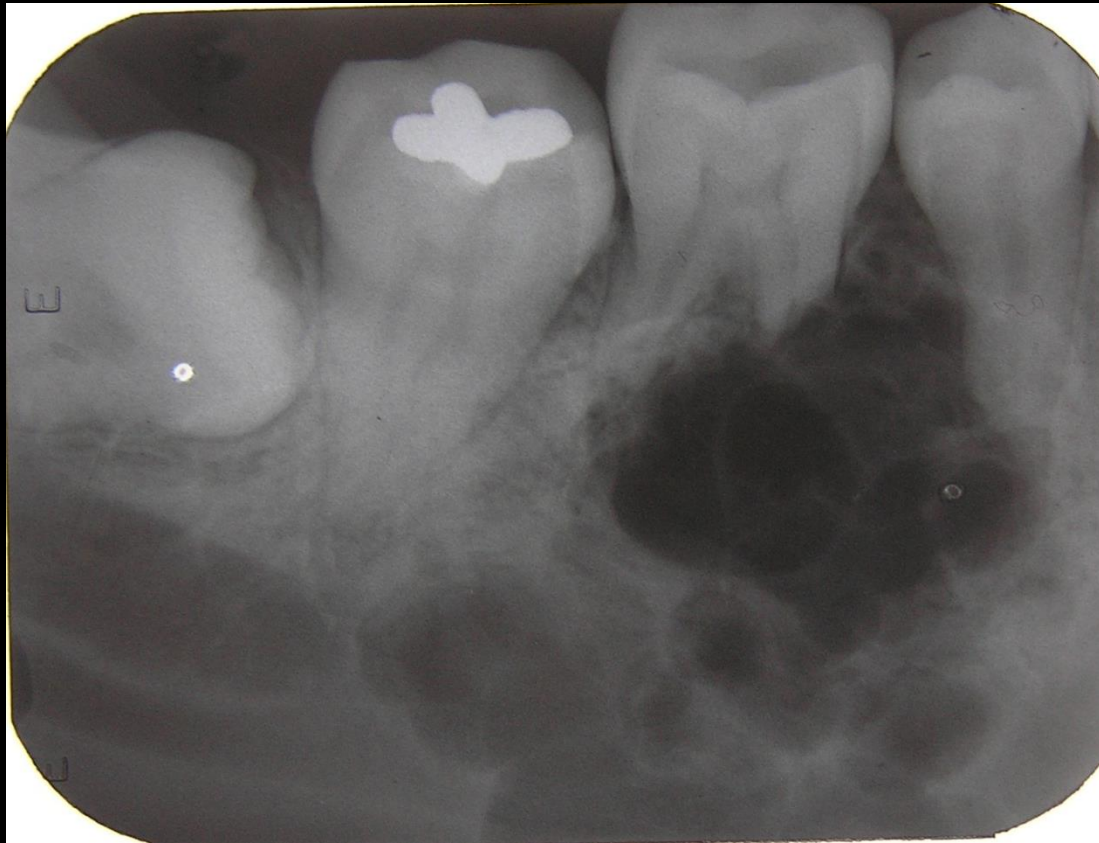
III. Multilocular cyst- Root resorption



AMELOBLASTOMA

Radiographic Features

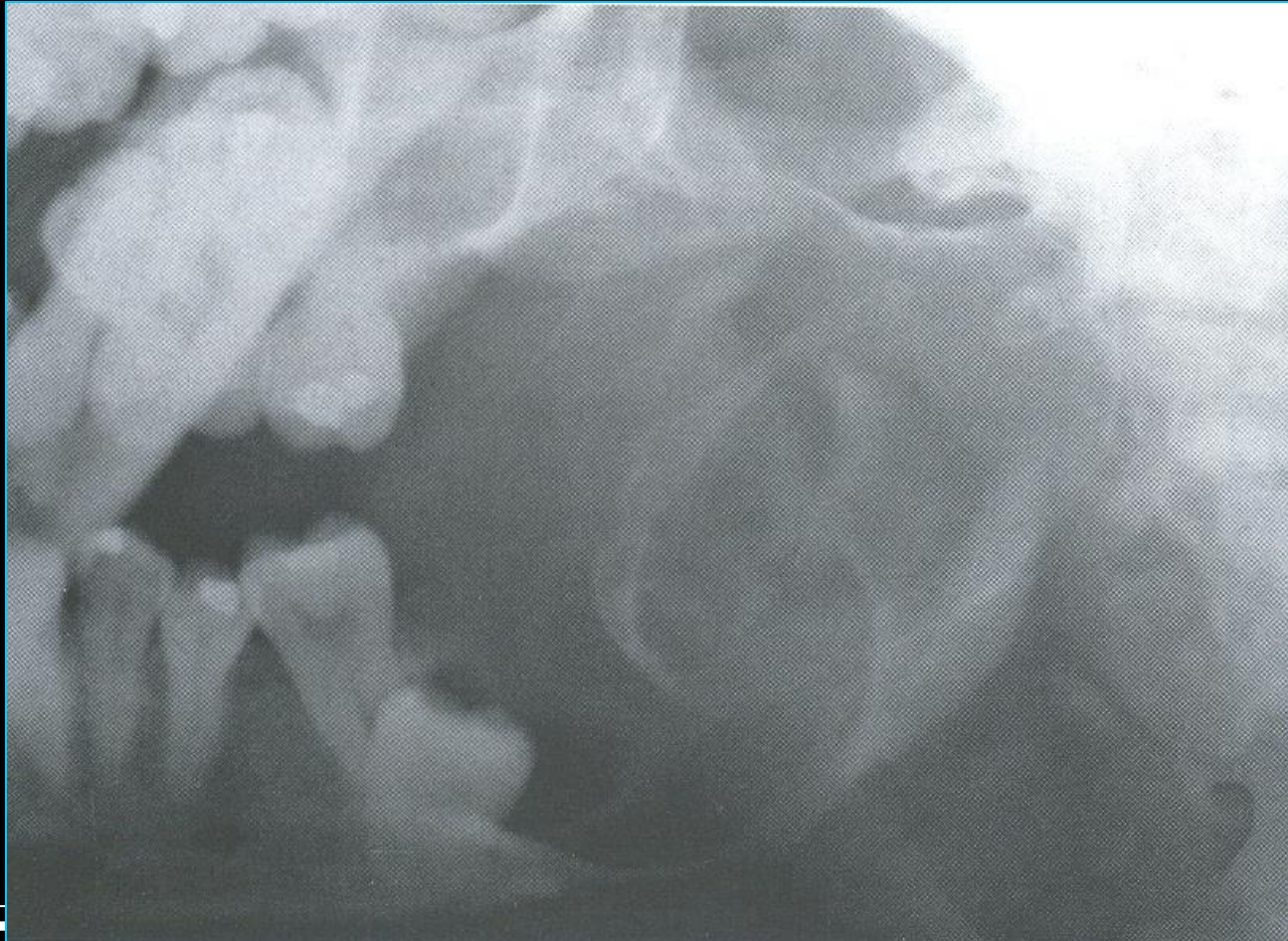
III. Multilocular cyst- Root resorption



AMELOBLASTOMA

Radiographic Features

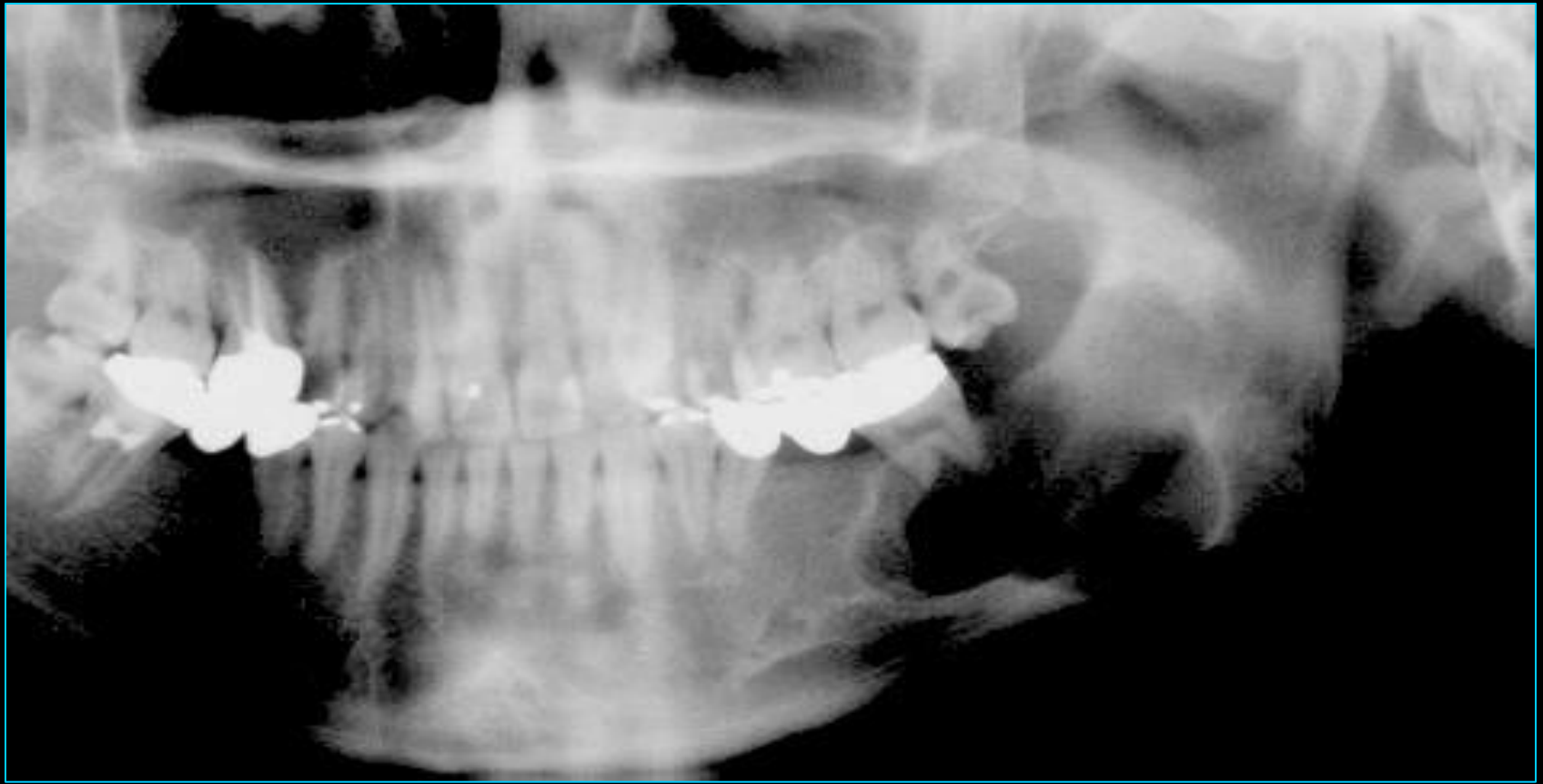III. Multilocular cyst- Root resorption



AMELOBLASTOMA

Radiographic Features

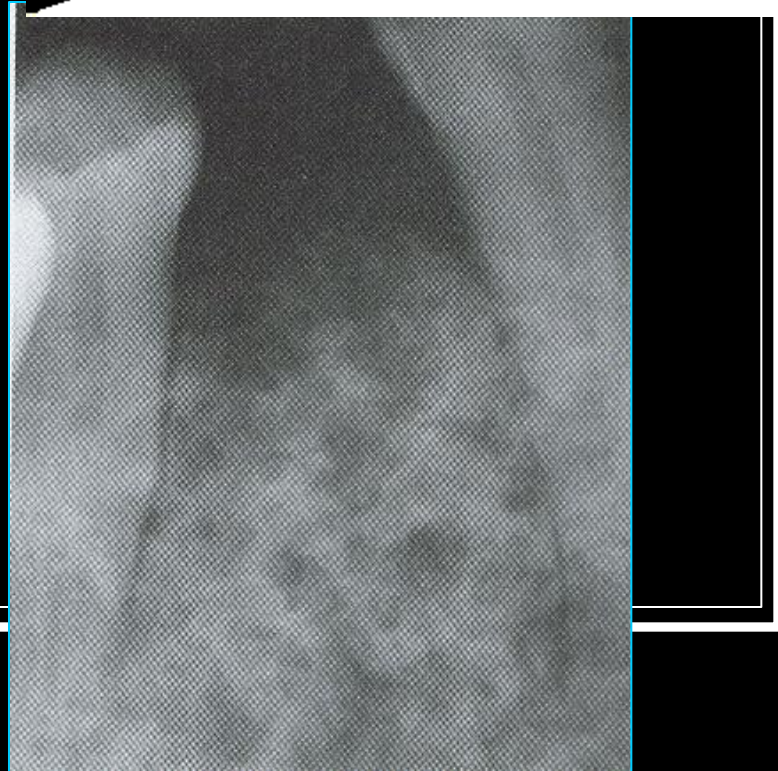
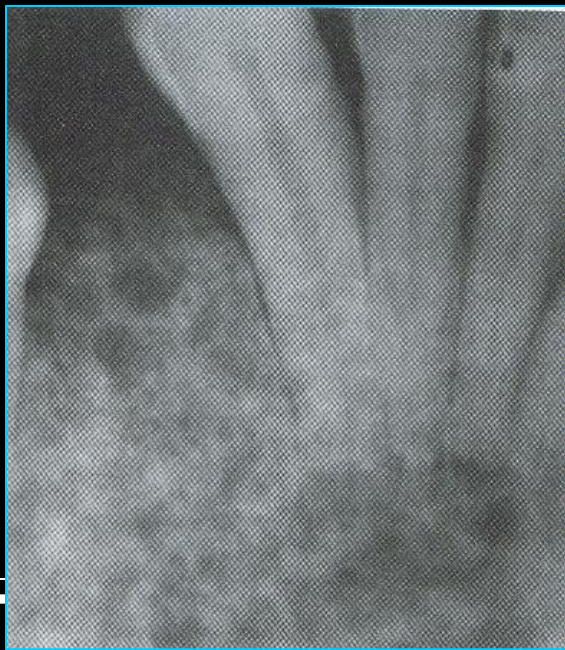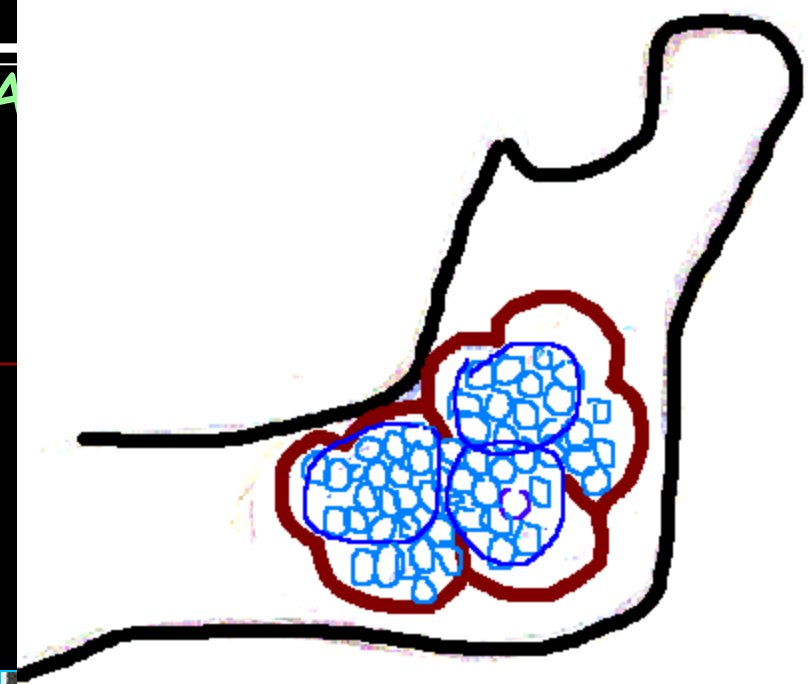
III. Multilocular cyst- Root resorption



AMELOBLASTOMA

Radiographic Features

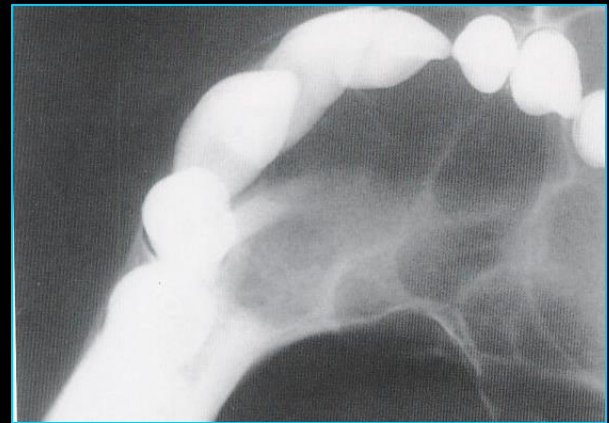
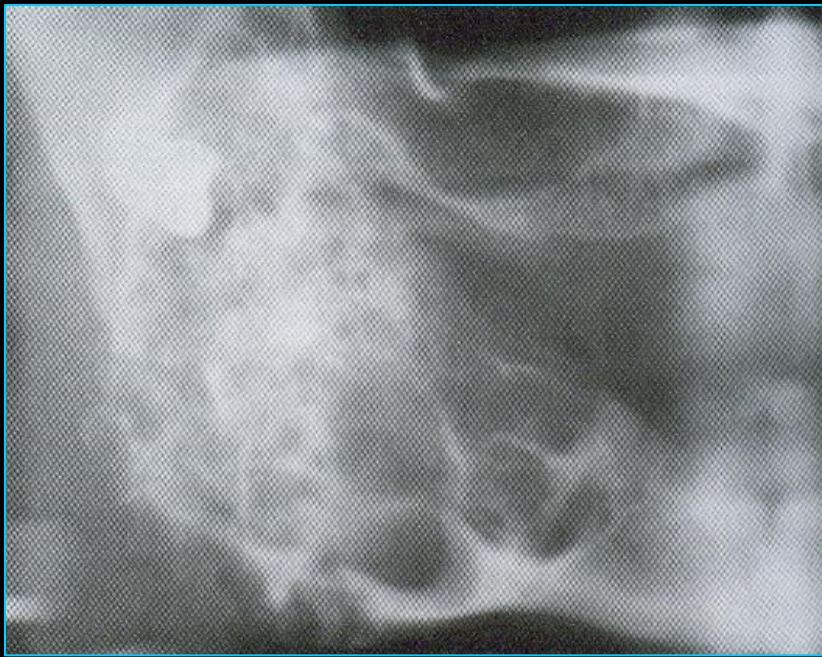
IV. Honeycomb



AMELOBLASTOMA

Radiographic Features

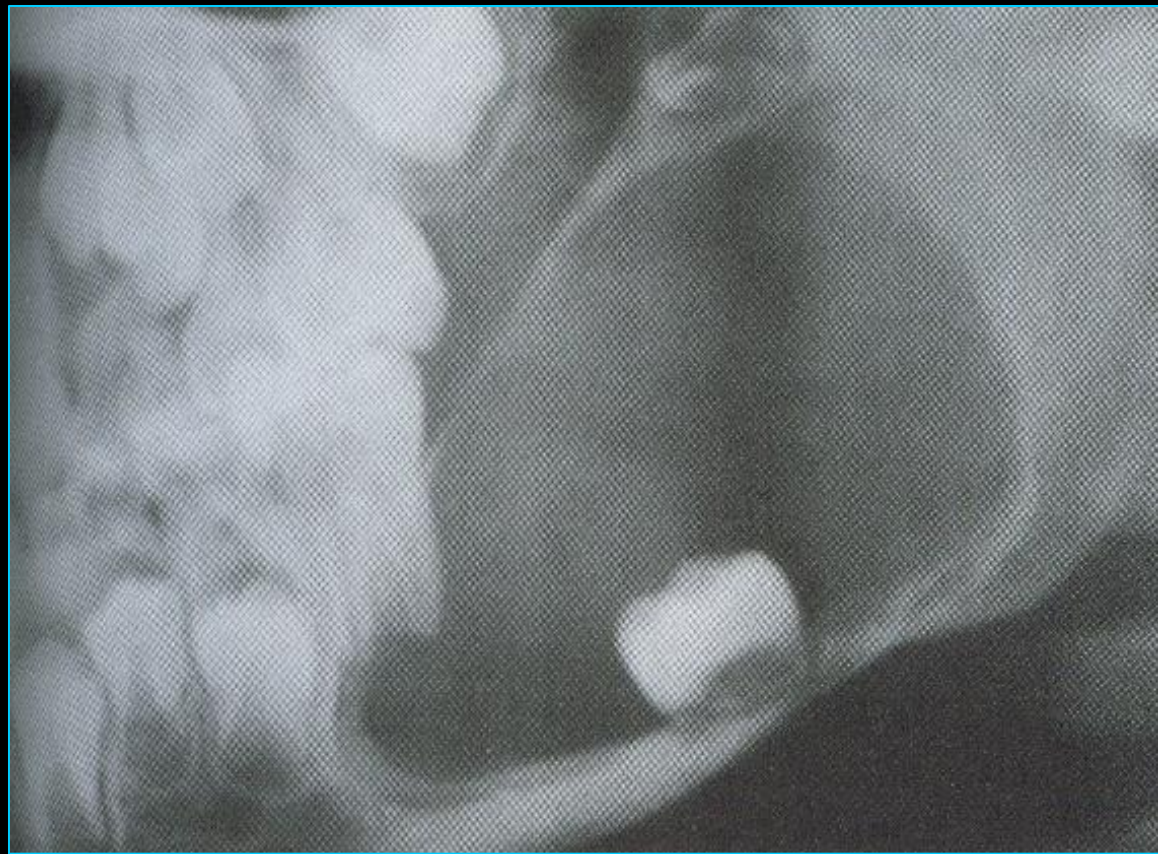
V. Soap bubble appearance



AMELOBLASTOMA

Radiographic Features

VI. Unicystic ameloblastoma

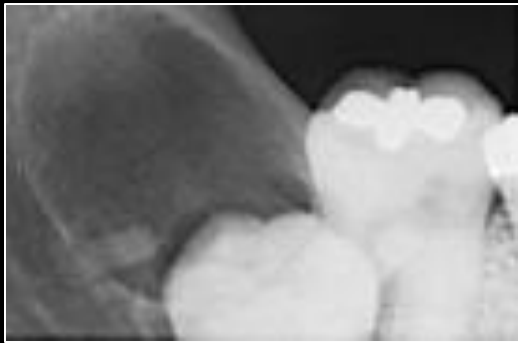

AMELOBLASTOMA

Differential Diagnosis

Unilocular

- Cysts
- Radiolucent benign tumors



Multilocular

- Multilocular cysts
- Central G.C granuloma
- Giant cell lesion of hyperparathyroidism
- Cherubism
- Od. Myxoma
- Aneurysmal bone cyst
- Central hemangioma (rare)
- Metastatic tumor

AMELOBLASTOMA

Management

- ~~High recurrence due to small projections~~
- Solid amelo. More likely to recurr than cystic
- Radioresistant
- Surgical- wide block resection with placement of bone graft
- Older patient- curretment and cautery

Prognosis

- Favorable
- Death by invasion of local structures

ADENOMATOID ODONTOGENIC TUMOR (AOT)

Uncommon ,nonaggressive tumor of Od. Epithelium

Duct like structure by the ep. component of lesion

Clinical Features

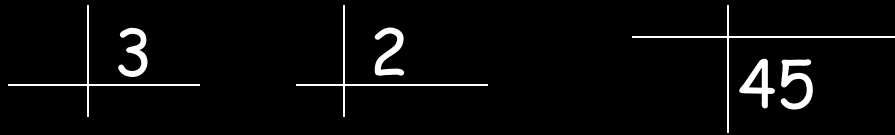- F/M = 2:1
- 2nd decade, average 16 years
- Max/ mandible = 2:1
- Most in ant. Jaws, most assoc. with unerupted teeth or in walls of dentigerous cysts

ADENOMATOID ODONTOGENIC TUMOR (AOT)

Uncommon ,nonaggressive tumor of Od. Epithelium

Duct like structure by the ep. component of lesion

Clinical Features



- Either small (no signs) → growth → expansion of c. plates
- Clinical swelling & asymmetry, no soft tissue invasion
- Teeth not disturbed morpho., hence lesion originates after odontogenesis complete

ADENOMATOID ODONTOGENIC TUMOR (AOT)

Radiographic Features



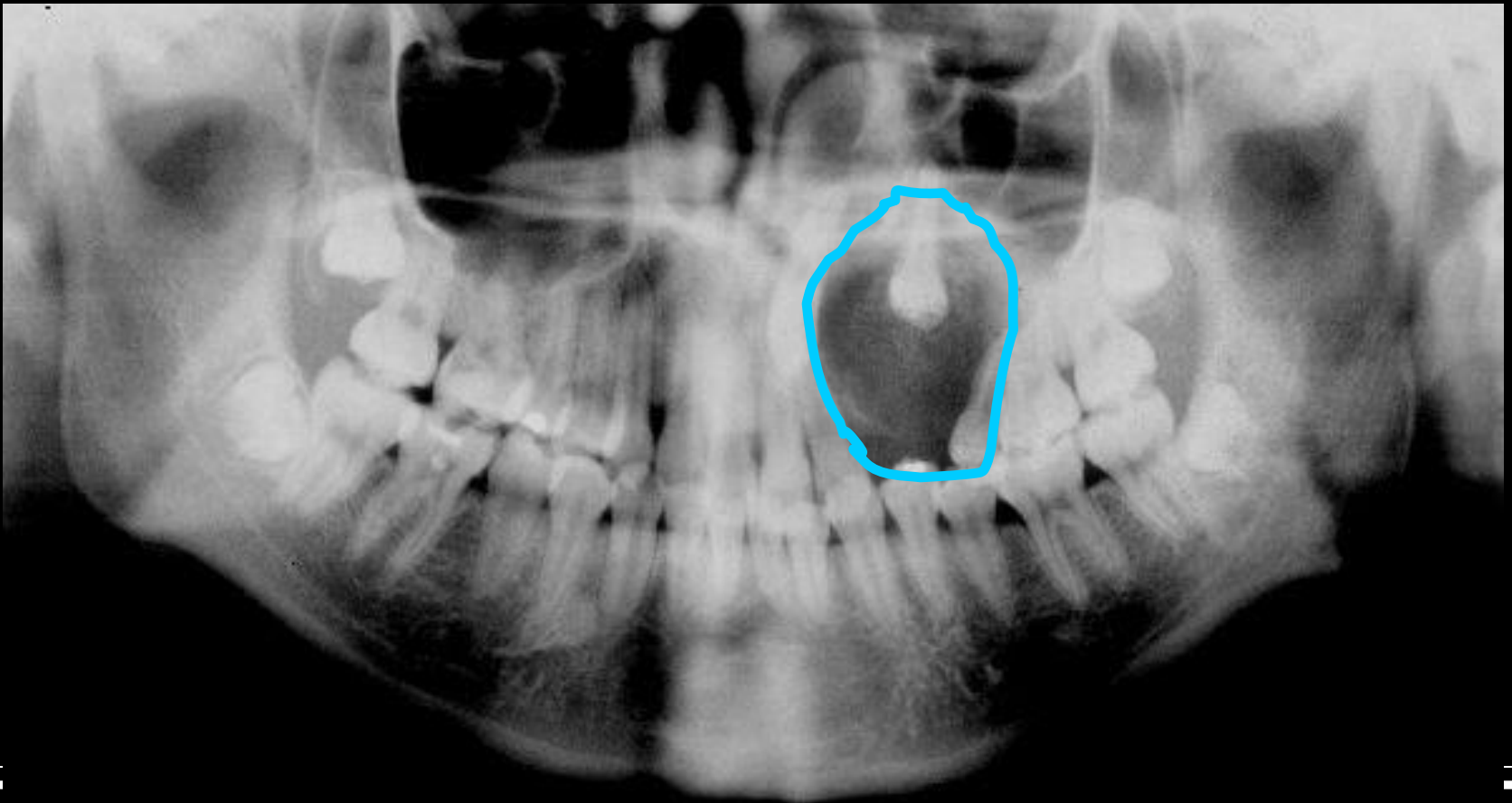
- Pericoronal R.L
- Not confined to crown
- Sclerotic border

- Faint R.O foci

- Dense R.O clusters
- Roots displaced
- Resorption rare

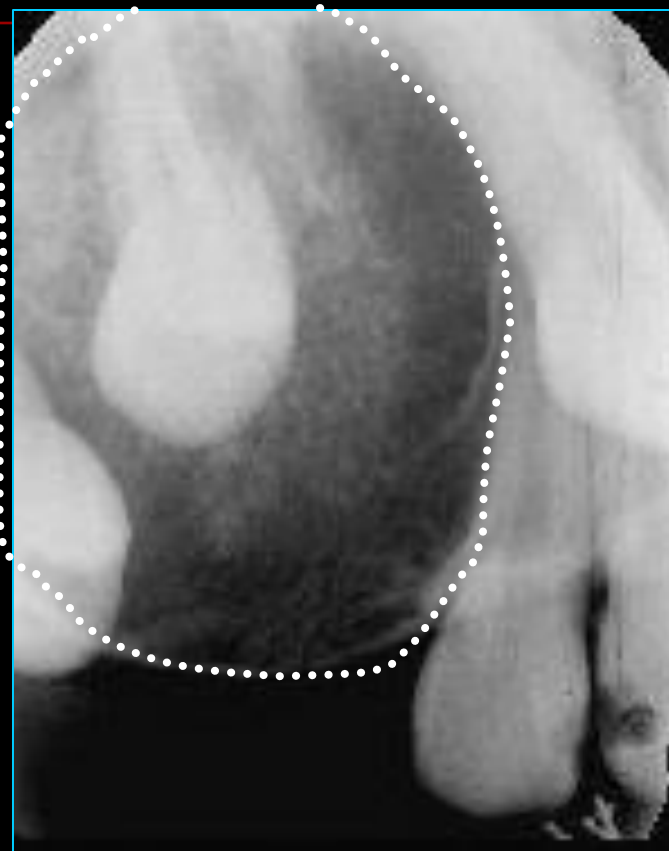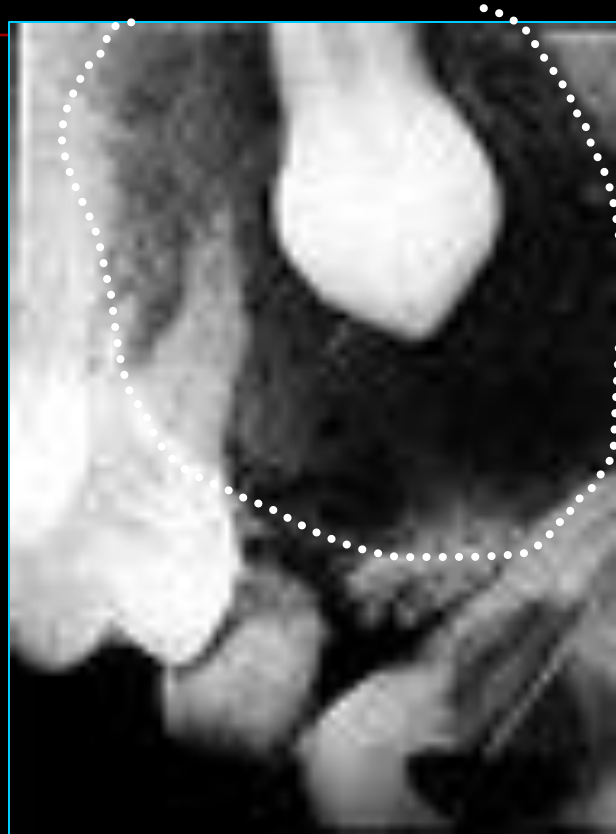ADENOMATOID ODONTOGENIC TUMOR (AOT)

Radiographic Features



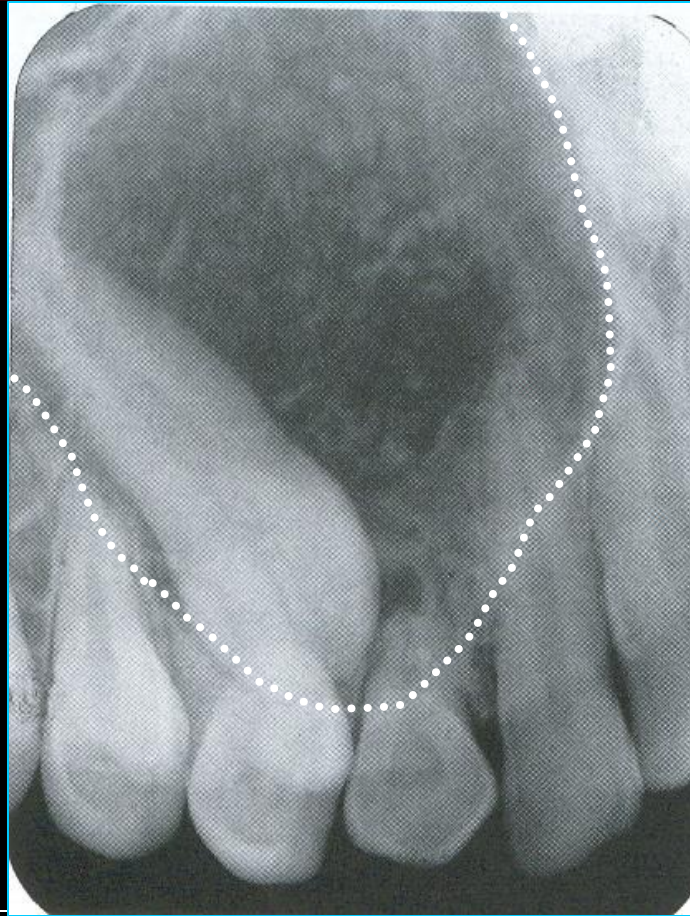
ADENOMATOID ODONTOGENIC TUMOR (AOT)

Radiographic Features



ADENOMATOID ODONTOGENIC TUMOR (AOT)

Radiographic Features

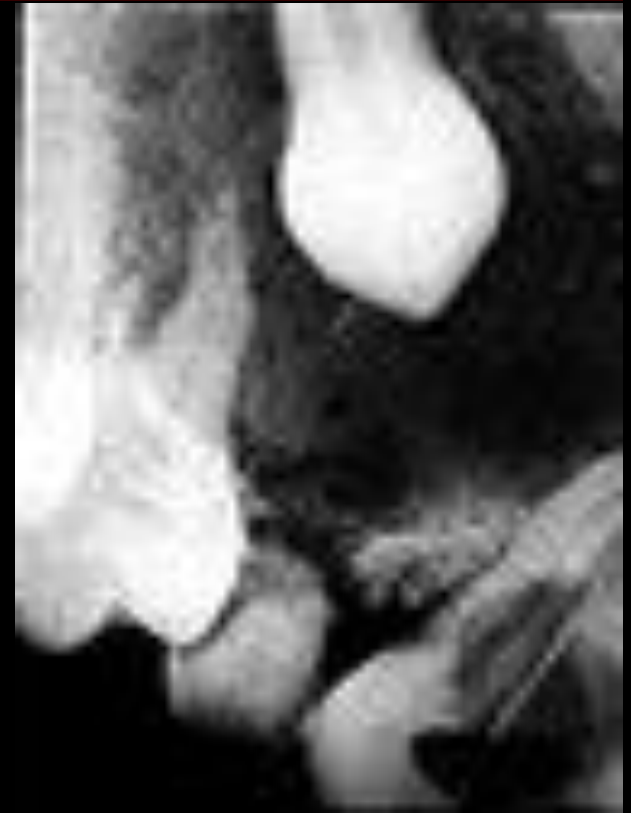

ADENOMATOID ODONTOGENIC TUMOR (AOT)

Radiographic Features- Differential Diagnosis

Pericoronaral R.L

- Follicular spaces
- Impacted teeth
- Developing teeth
- Unicystic amelo.
- AOT
- Amelo. fibroma



ADENOMATOID ODONTOGENIC TUMOR (AOT)

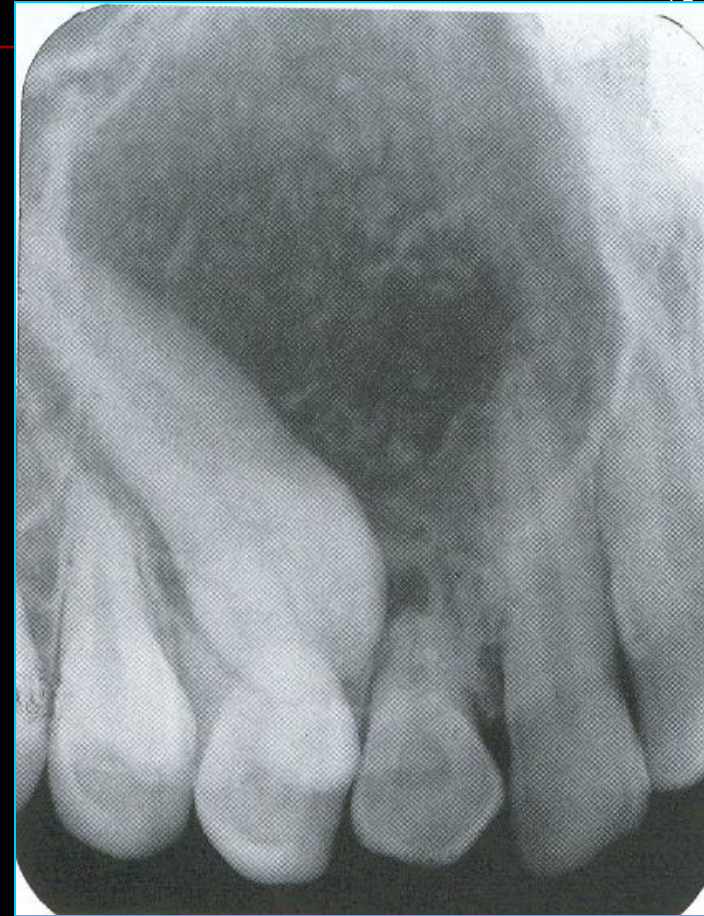Radiographic Features- Differential Diagnosis

Mixed lesions

- Compound odontome
- Complex odontome
- A O T
- Calcifying Od. cyst
- Am. Fibro-odontome
- C E O T

Rx

- Conservative surgical removal, easy separation
- Low recurrence rate, no evidence of metastatic behavior



Calcifying Epithelial Odontogenic Tumor- (CEOT)

'Pindborg Tumor'


Rare neoplasm of tooth producing apparatus

Clinical features

- Mandible/Max = 2:1
- Behavior similar to ameloblastoma
 - locally invasive
 - high recurrence rate
 - same age group
 - site predeliction
 - extraosseous lesions

Calcifying Epithelial Odontogenic Tumor- (CEOT)

Radiographic Features



- Well delineated pericoronal R.L
- Impacted teeth
- Uni/ multilocular

Poorly defined Pericoronal R.L

R.L not associated With teeth

Calcifying Epithelial Odontogenic Tumor- (CEOT)

Radiographic Features



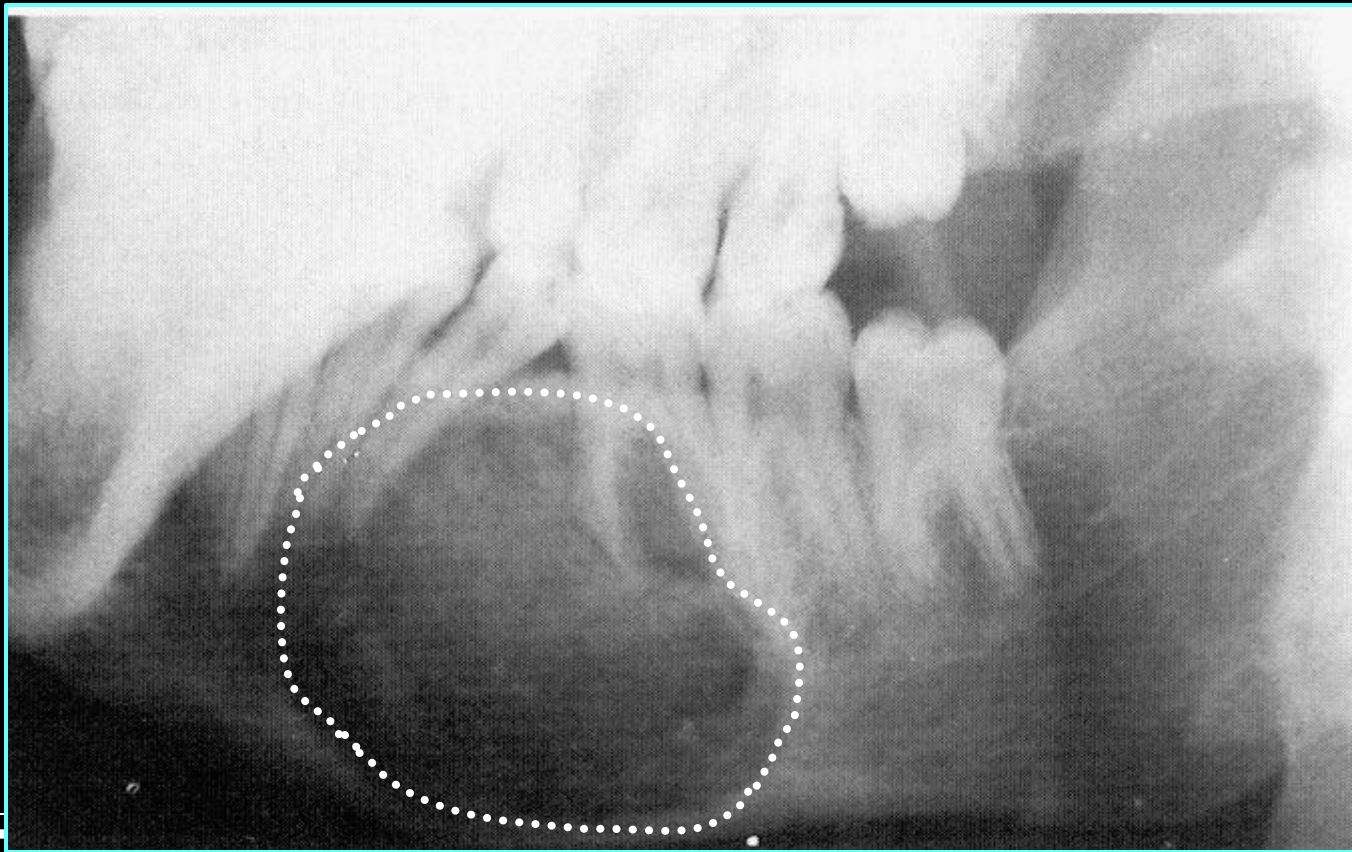
•R.L with R.O foci



R.L with trabeculae & foci -
'driven snow appearance'

Calcifying Epithelial Odontogenic Tumor- (CEOT)

Radiographic Features



Calcifying Epithelial Odontogenic Tumor- (CEOT)

D.D- *Complex odontome

*AOT

*Calcifying odontogenic cyst

*Ameloblastic fibro-odontome

*CEOT

*Odontogenic fibroma

Management

- Surgical excision with satisfactory border of normal tissue
- Careful follow-up mandatory

ODONTOGENIC MYXOMA

3-6% of Odontogenic tumors

CLINICAL FEATURES


- Females, mand./max.= 3:1, P.m & molar region
- Congenitally missing or unerupted
- Eventual expansion, teeth displaced & loosened

RADIOGRAPHIC FEATURES


Typically multilocular- Various trabecular arrangements



Honeycomb



Tennis racket




Soap bubble

ODONTOGENIC MYXOMA RADIOGRAPHIC FEATURES

Typically multilocular- Various trabecular arrangements



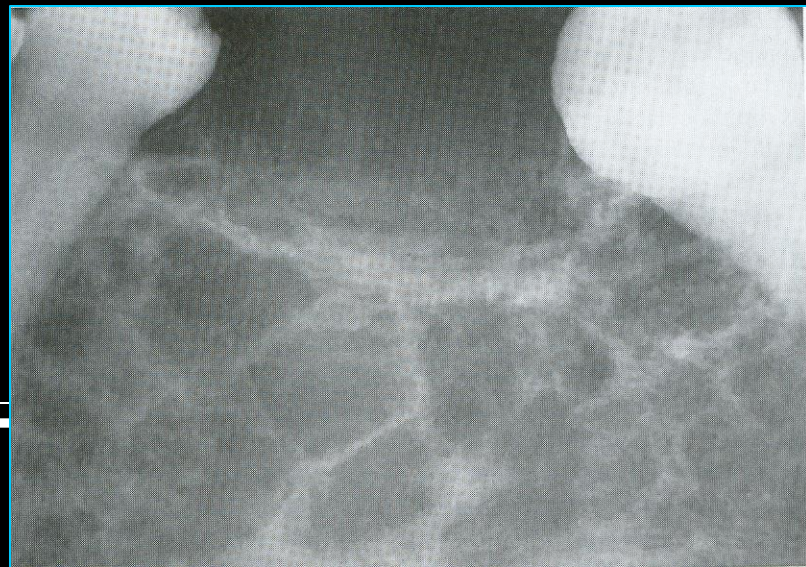
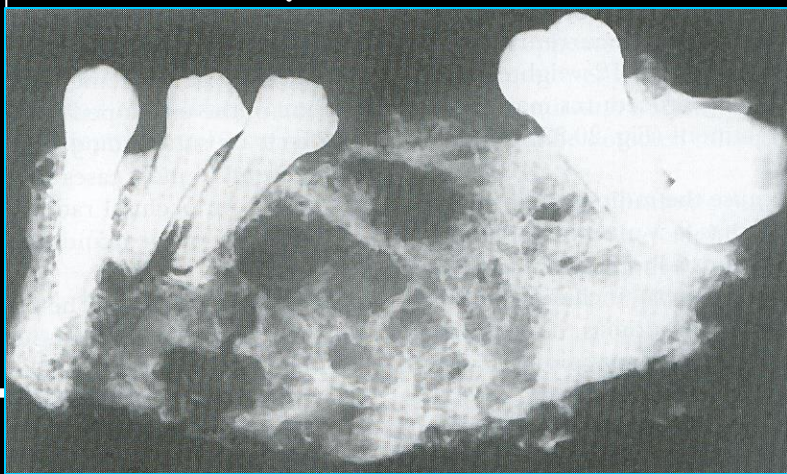
Honeycomb



Tennis racket



Soap bubble



ODONTOGENIC MYXOMA

RADIOGRAPHIC FEATURES

- Scalloping between roots of adjacent teeth
- Root resorption rare

D.D

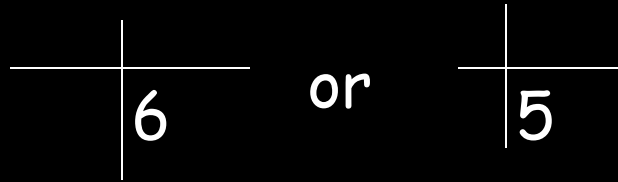
- Ameloblastoma
- CGCG
- Cherubism
- ABC
- Metastatic tumor to jaws
- Central hemangioma

BENIGN CEMENTOBLASTOMA

Large, bulbous mass of cementoid tissue on roots

CLINICAL FEATURES

- Most pts < 25, solitary



- Vital teeth, expansion

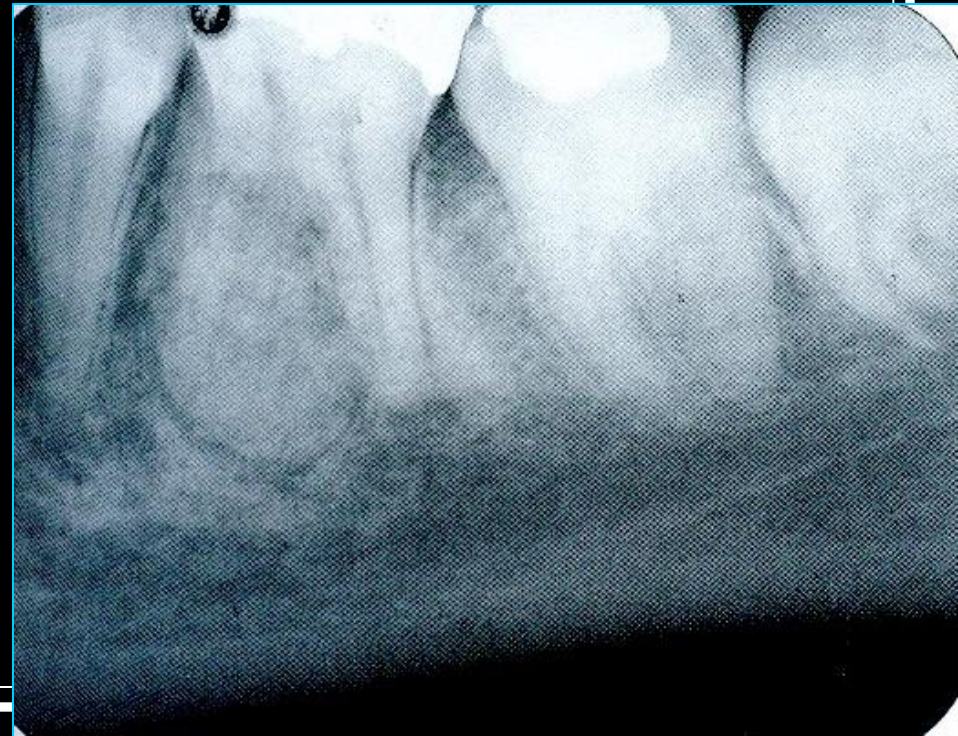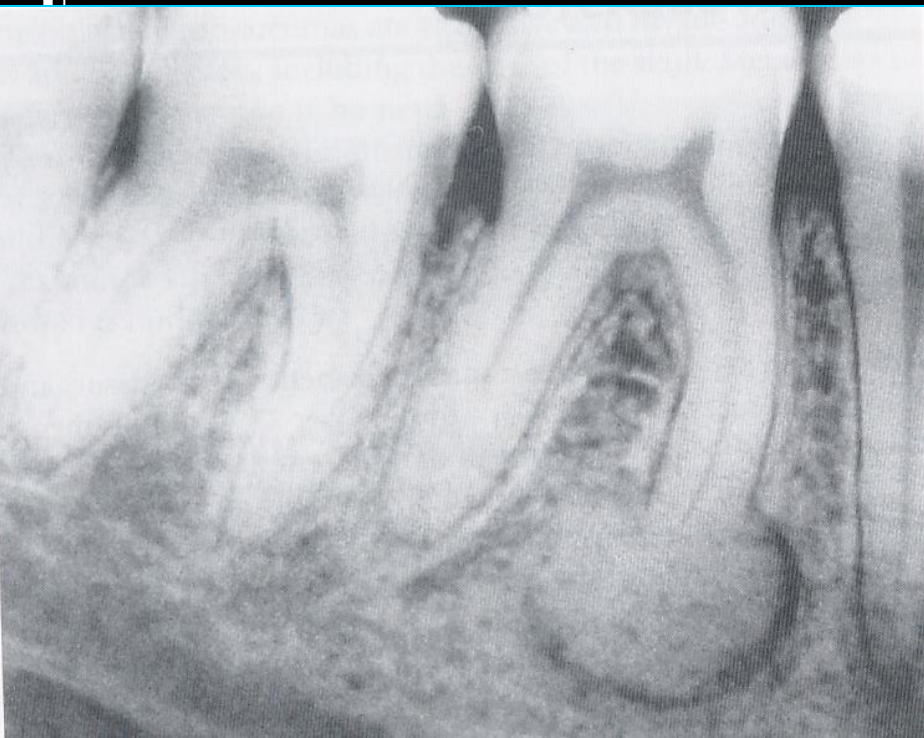
RADIOGRAPHIC FEATURES

- Well defined R.O attached to root surface, border R.L
- Outline of root obscured
- Root resorption

BENIGN CEMENTOBLASTOMA

RADIOGRAPHIC FEATURES

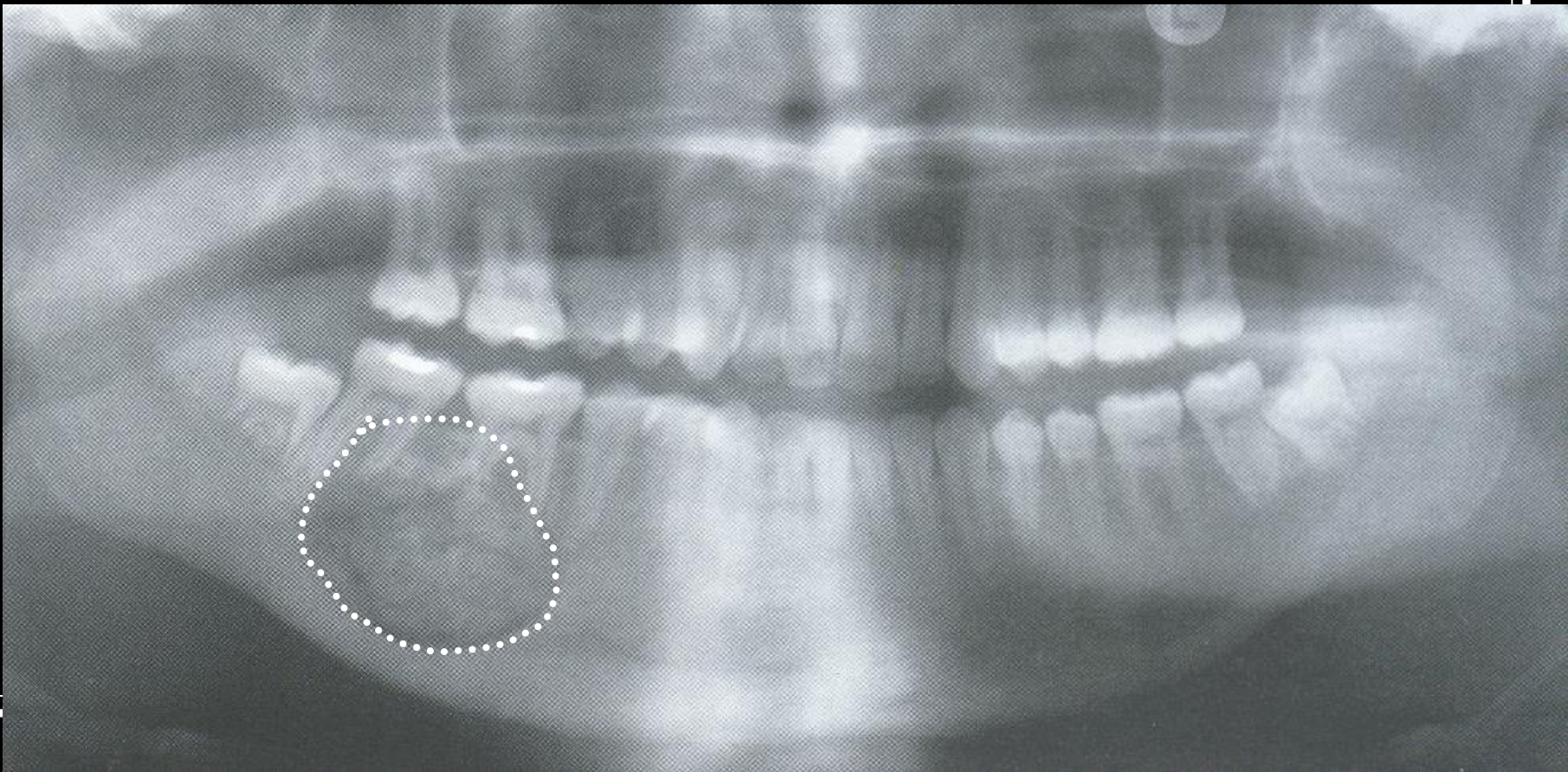
- Well defined R.O attached to root surface, border R.L
- Outline of root obscured
- Root resorption



BENIGN CEMENTOBLASTOMA

RADIOGRAPHIC FEATURES

- Well defined R.O attached to root surface, border R.L
- Outline of root obscured
- Root resorption



BENIGN CEMENTOBLASTOMA

RADIOGRAPHIC FEATURES

- Well defined R.O attached to root surface, border R.L
- ~~Outline of root obscured~~
- Root resorption

D.D

- Periapical cemental dysplasia (PCD)
- Chronic focal sclerosing osteomyelitis
- Periapical osteosclerosis
- hypercementosis

Management

- Self limiting, no recurrence
- Simple excision
- In some cases, tumor to be amputated from tooth and tooth treated endodontically

NEURILEMMOMA

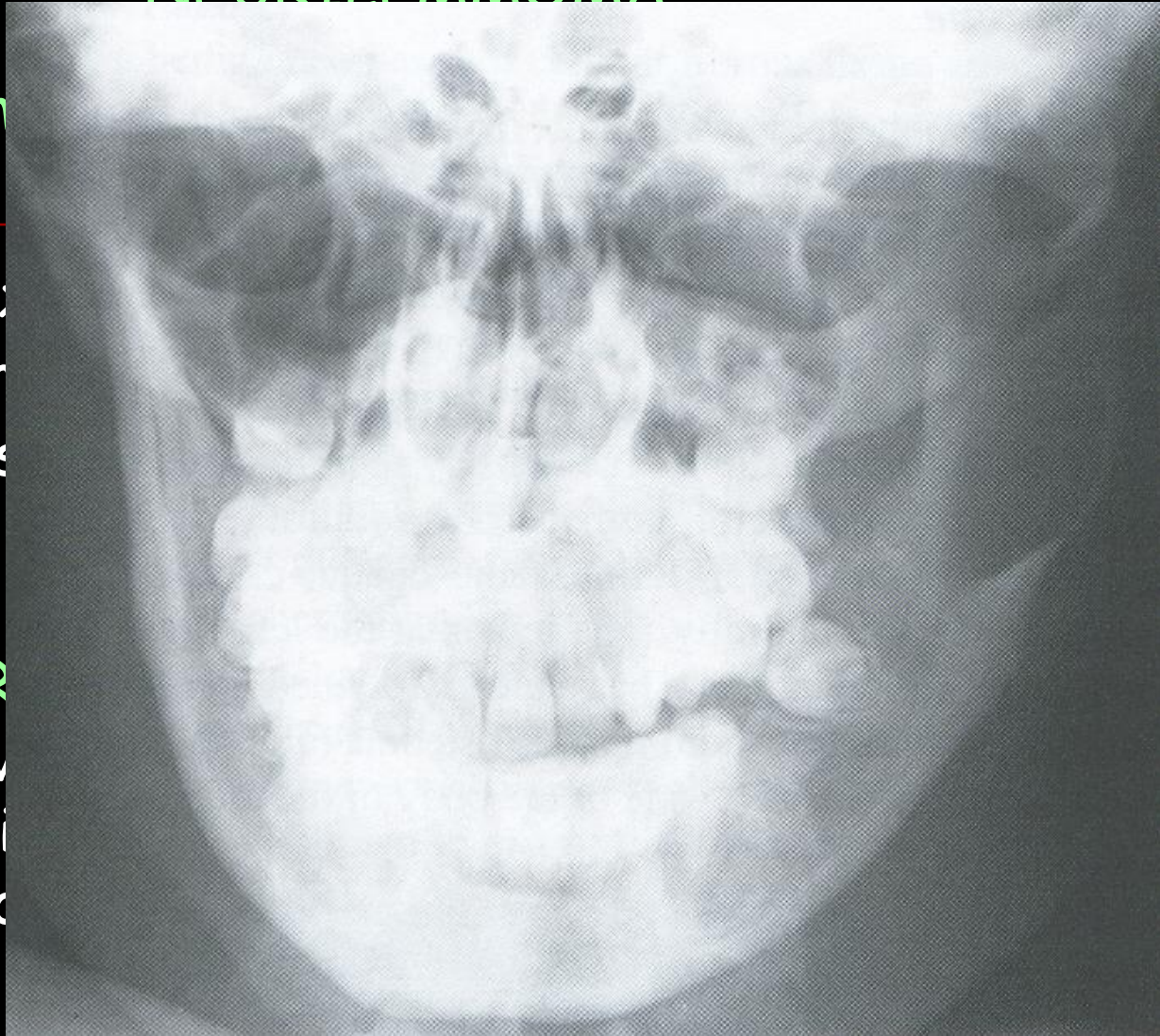
Most com

CLINICAL

- Mand > Max
- Jaw expan
- Pain localis

RADIOGR

- Round, ov
- Well defi
- Root reso



on

d f.
n

Rx: Excision

NEUROMA

Overgrowth of a severed nerve attempting to regenerate when blocked from reaching distal end by scar tissue

CLINICAL FEATURES

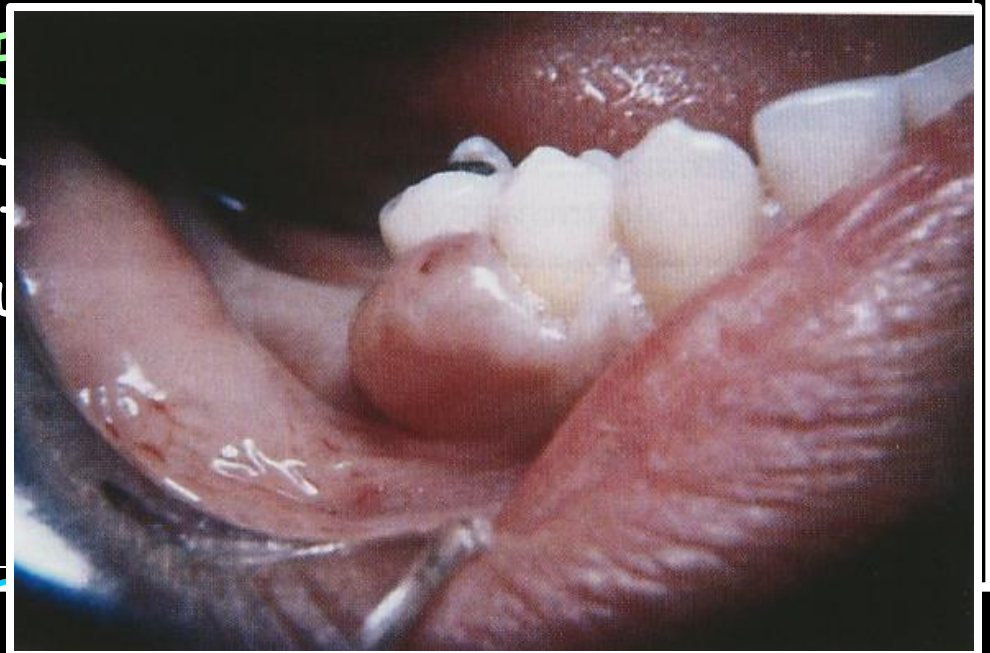
- Slow growing reactive hyperplasia, seldom becomes large
- Larger lesions, considerable bone destruction
- Reflex neuralgia, pain referred to eyes, face head

RADIOGRAPHIC FEATURES

- Small- will fit into trabeculae
- Large- R.L area in bone with
- Mand.- assoc with mandibular

D.D- Painful cystlike radiolucency

H/o # or surgery in r



CENTRAL HEMANGIOMA

Rare in jaws

- Developmental
 - Anomaly of B.V in marrow spaces
 - traumatic
-

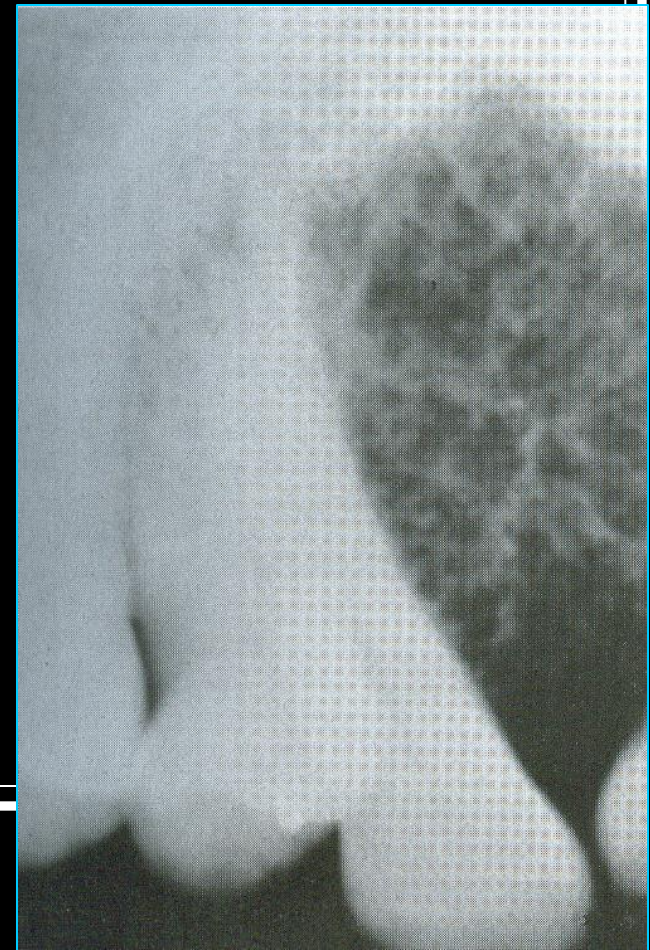
CLINICAL FEATURES

- F:M = 2:1, Mand-body & ramus, 10-20 years of age
- Slow, nontender expansion
- Swelling, not tender, bony hard, pain + -
- Pulsation
- Bruit on auscultation
- Teeth loosened, migration
- Gingival bleeding
- Teeth - pumping action
- Aspiration- blood

CENTRAL HEMANGIOMA

RADIOGRAPHIC FEATURES

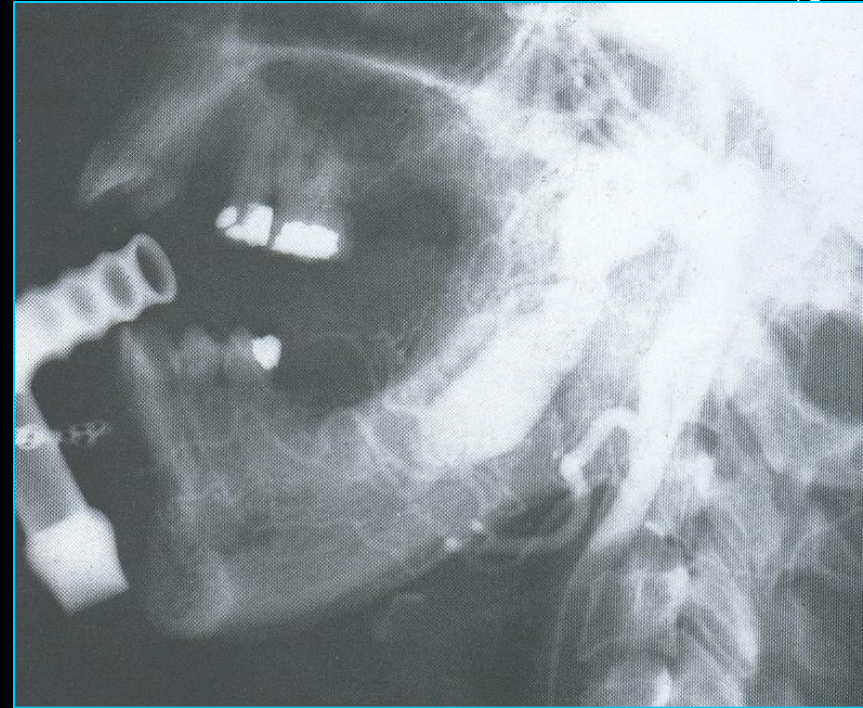
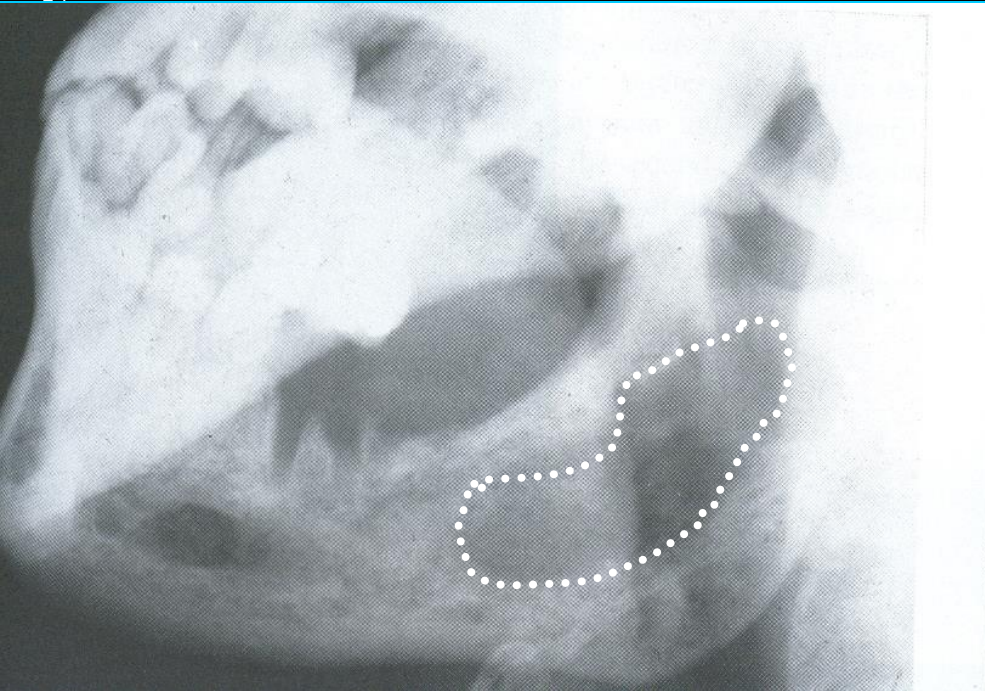
- Osteolytic
- ~~Multilocular, locules resemble enlarged trabecular spaces~~
- Trabeculae coarse & dense
- Soap bubble, honeycomb, spider
- Expanding lesion in profile - 'sunray'



CENTRAL HEMANGIOMA

RADIOGRAPHIC FEATURES

- ANGIOGRAPHY



CENTRAL HEMANGIOMA

D.D

- Note clinical features
- Aspiration
- Multilocular - CGCG

Giant cell lesion of hyperparathyroidism

ABC

Ameloblastic fibroma

Odontogenic myxoma

Ameloblastoma

Metastatic

Management

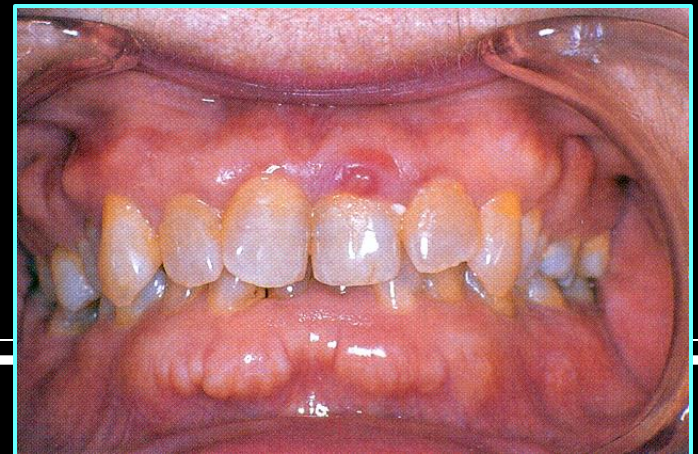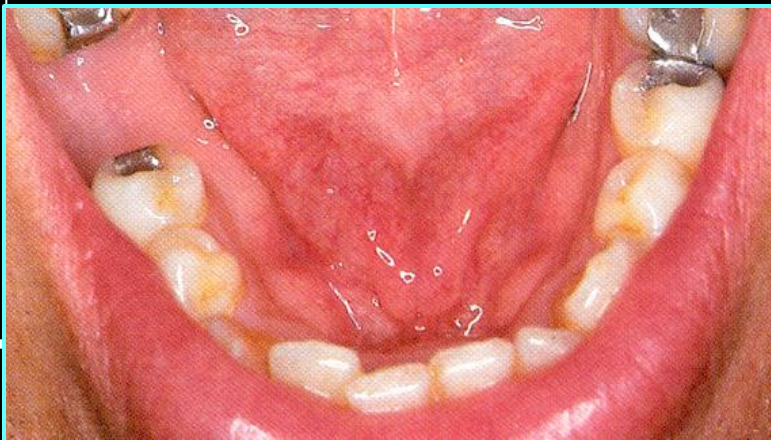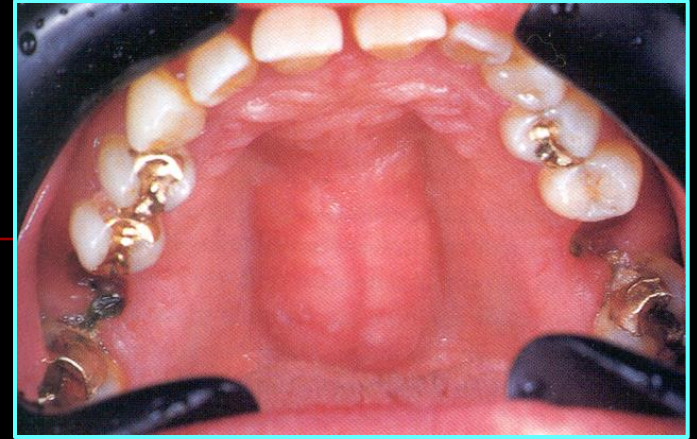
- Radiation (X or gamma)
- Embolisation (gel foam, metallic pellets)
- Surgery with ECA ligation
- Sclerosing techniques

OSTEOMA

- Compact bone
- Cancellous
- Combination

CLINICAL FEATURES

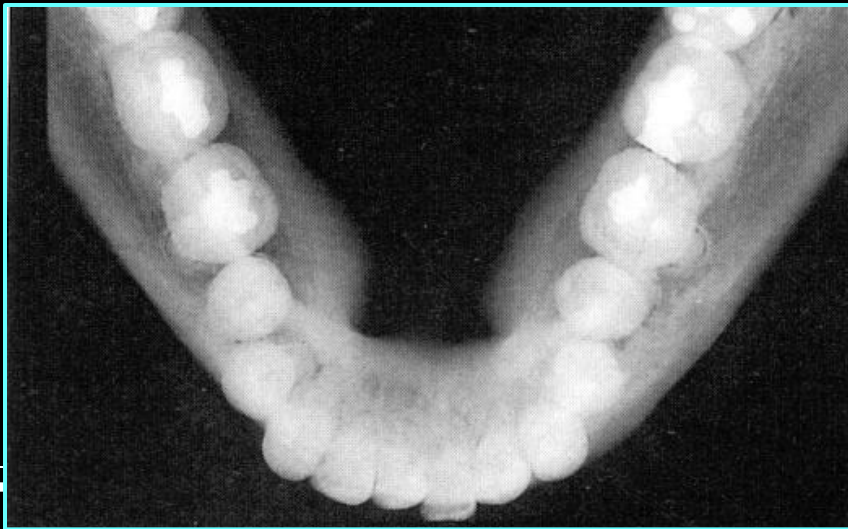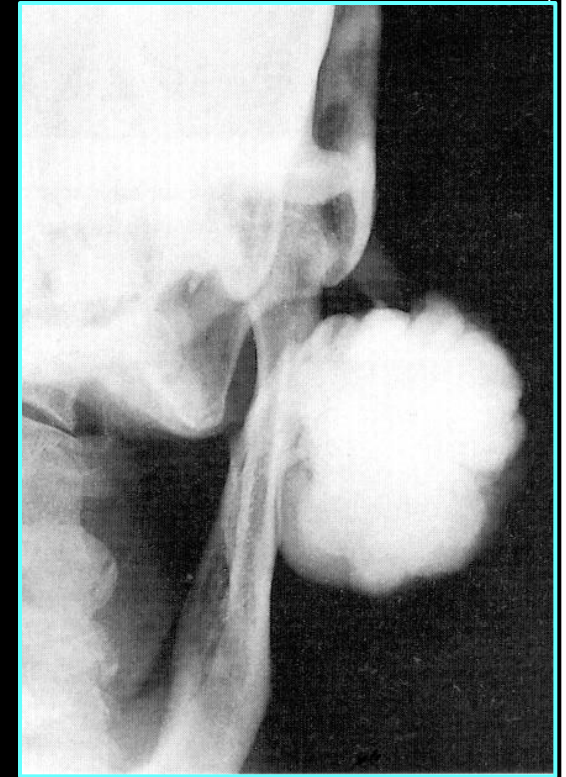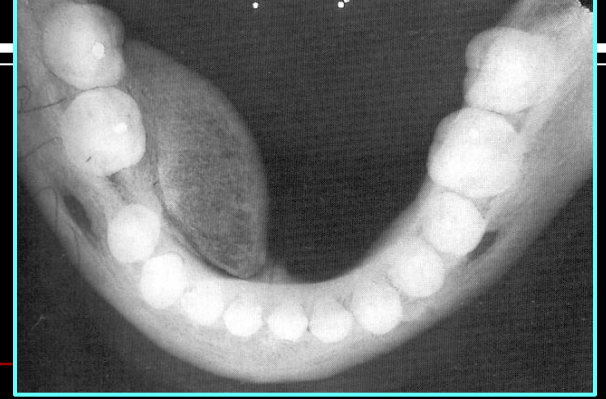- Individuals older than 40 years
- Lingual side of ramus and inferior border below molars
- Bony hard swelling
- Attached to cortex of jaw by pedicle or wide base
- Cancellous - females, compact - males



OSTEOMA

RADIOGRAPHIC FEATURES

- R.O mass with well defined borders
- Mass of compact bone- uniformly R.O
- Cancellous bone- internal trabeculae



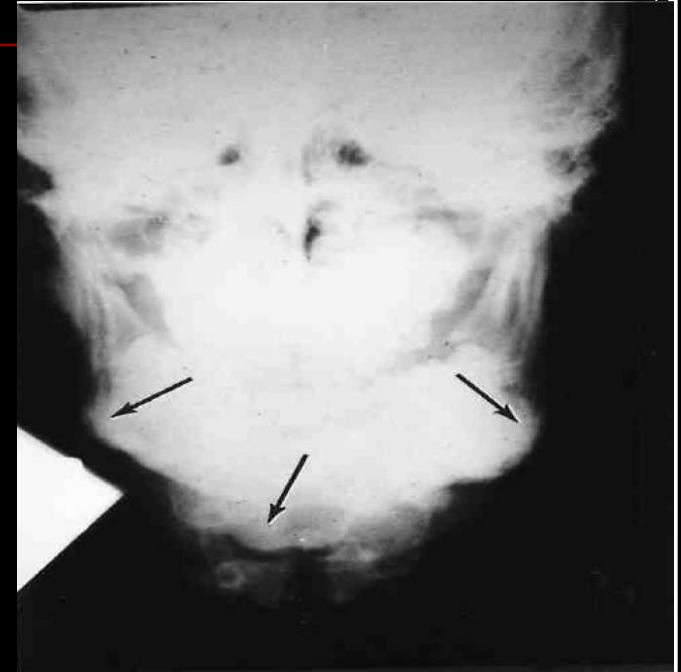
OSTEOMA

D.D

- Characteristic bony enlargement
- Radiographic image of R.O mass
 - early osteogenic sarcoma
 - mature ossifying fibroma

Gardener's syndrome

- Multiple osteomas
- Cutaneous sebaceous cysts
- Subcutaneous fibromas
- Multiple polyposis of small & large intestine



CENTRAL GIANT CELL GRANULOMA

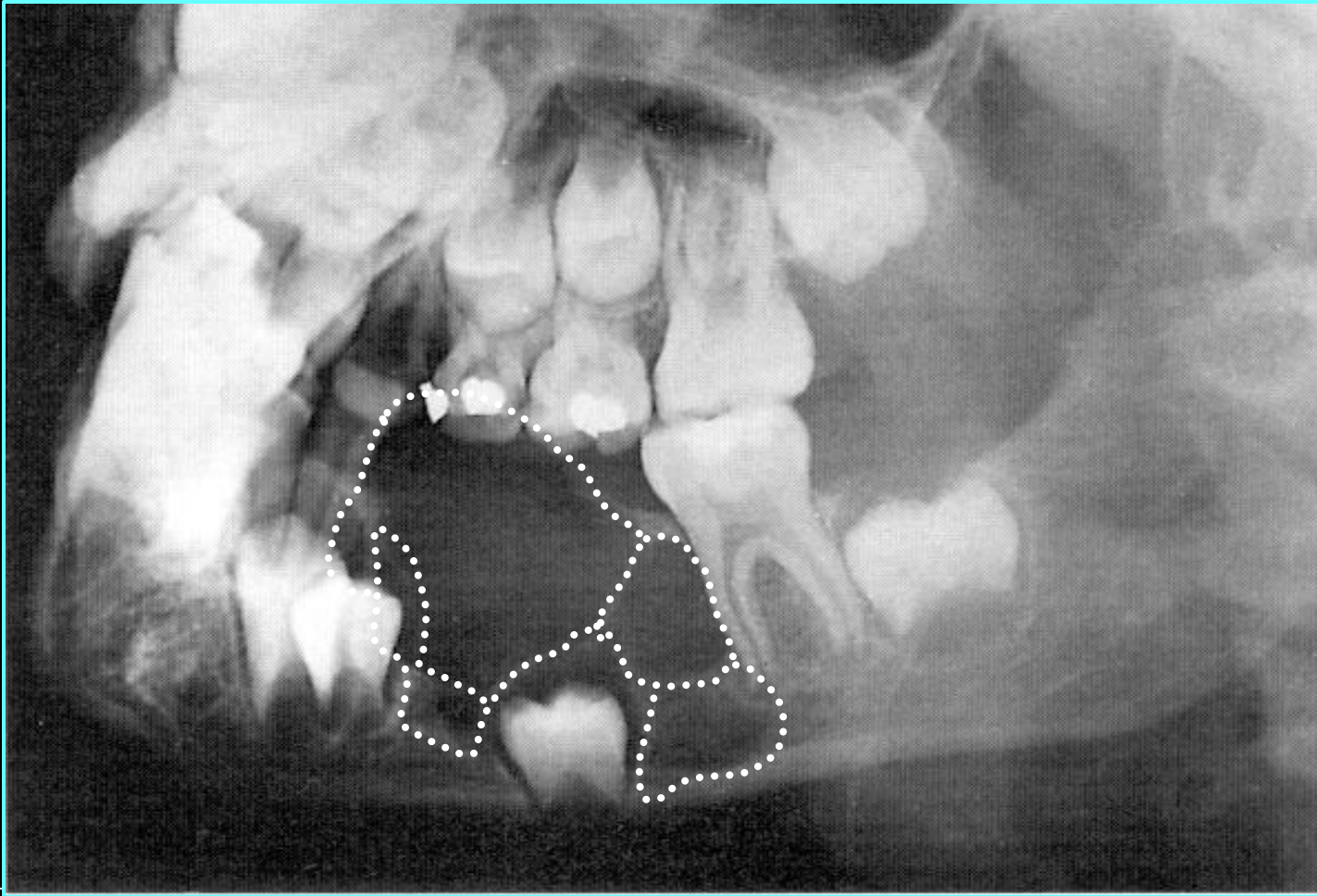
A reactive lesion to an unknown stimulus

CLINICAL FEATURES

- Common lesion in young adults, < 20 years of age
- Painless swelling,
- Palpation may elicit tenderness
- Overlying mucosa may be purple
- Slow growing, if rapid in some cases, malignancy suspected
- Mand : Max = 2:1, anterior to 1st molar
- Lesions tend to cross midline in mandible

CENTRAL GIANT CELL GRANULOMA

RADIGRAPHIC FEATURES



ped

g M.L app.

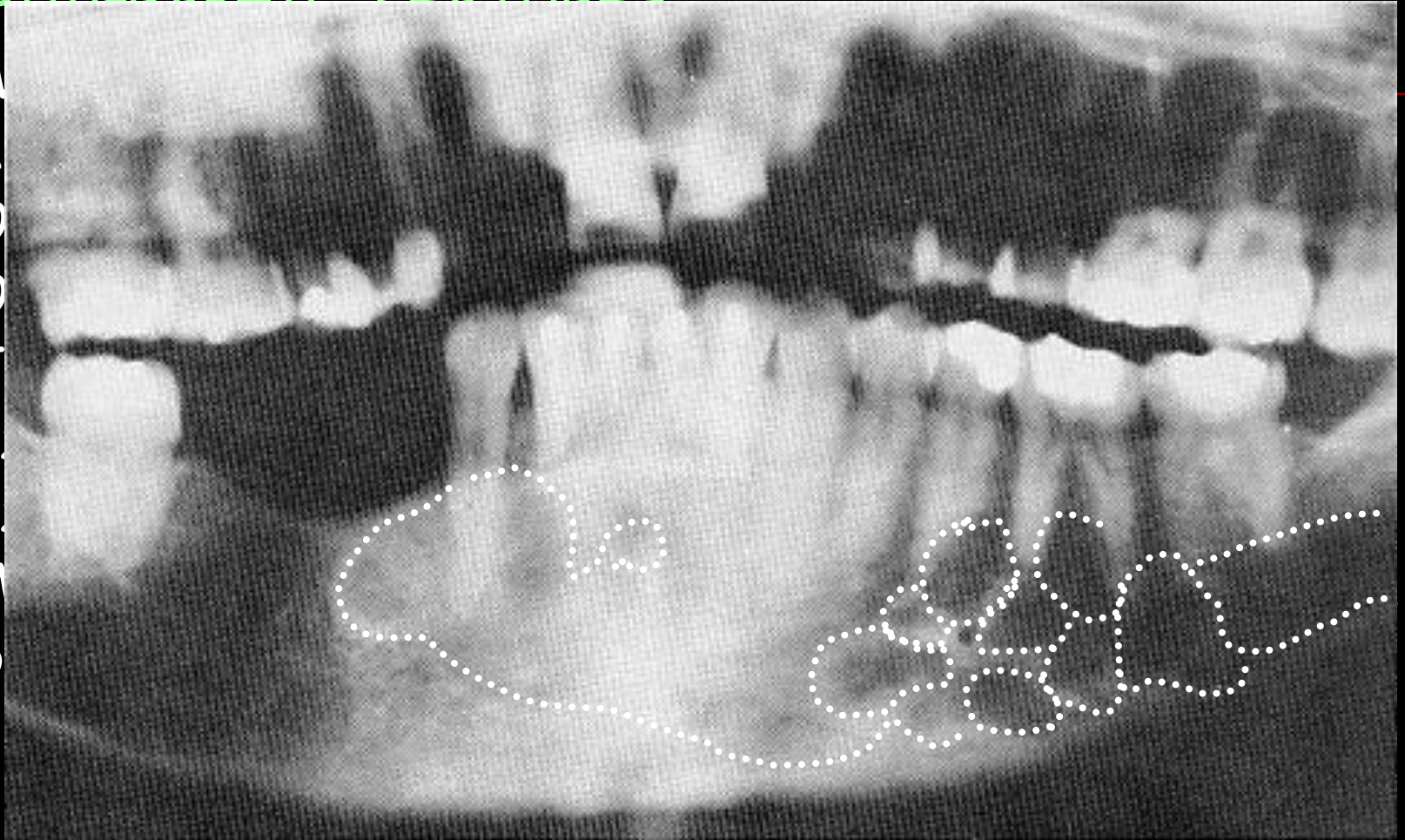
e

gnant app.

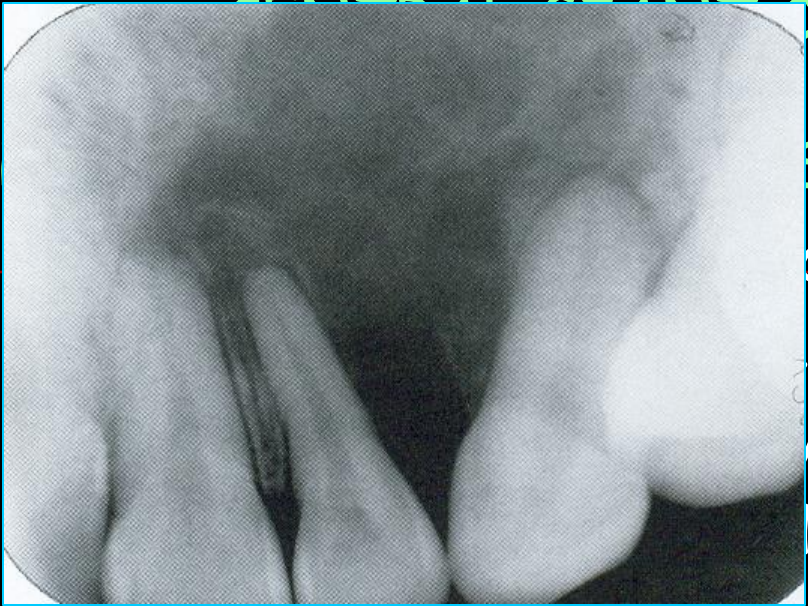
CENTRAL GIANT CELL GRANULOMA

RADIOGRAPHIC FEATURES

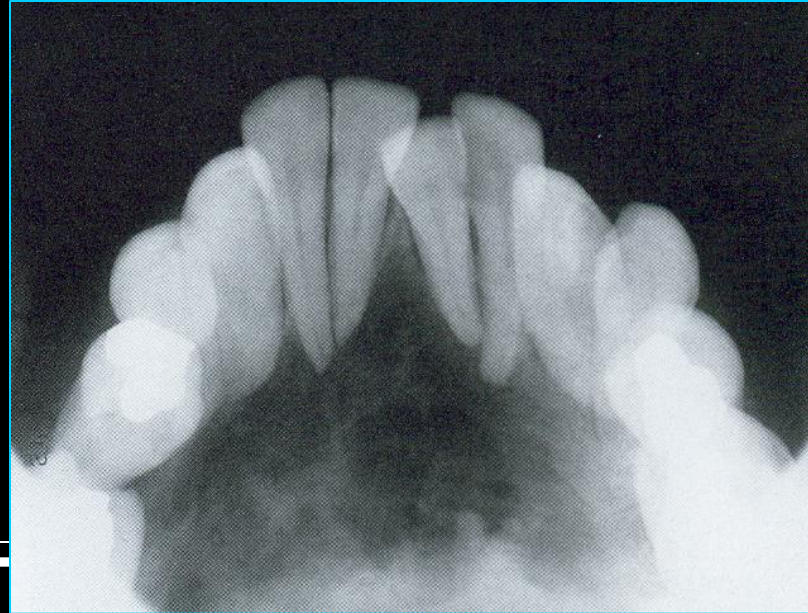
- W
- A
- O
- O
- T
- E
- E
- M
- D



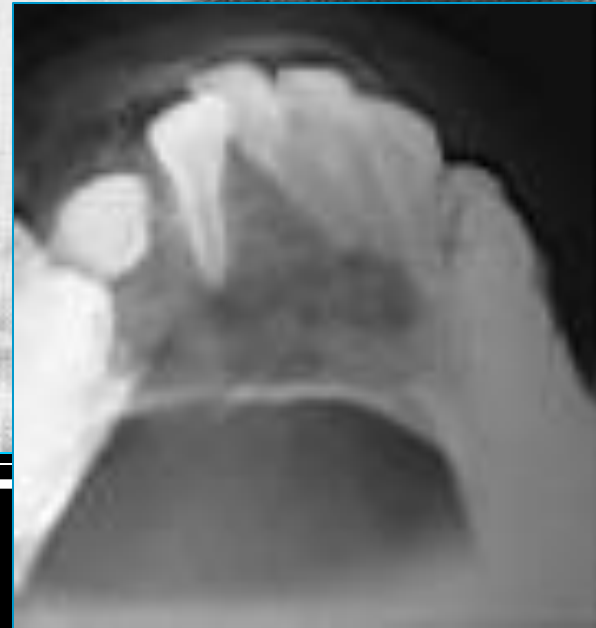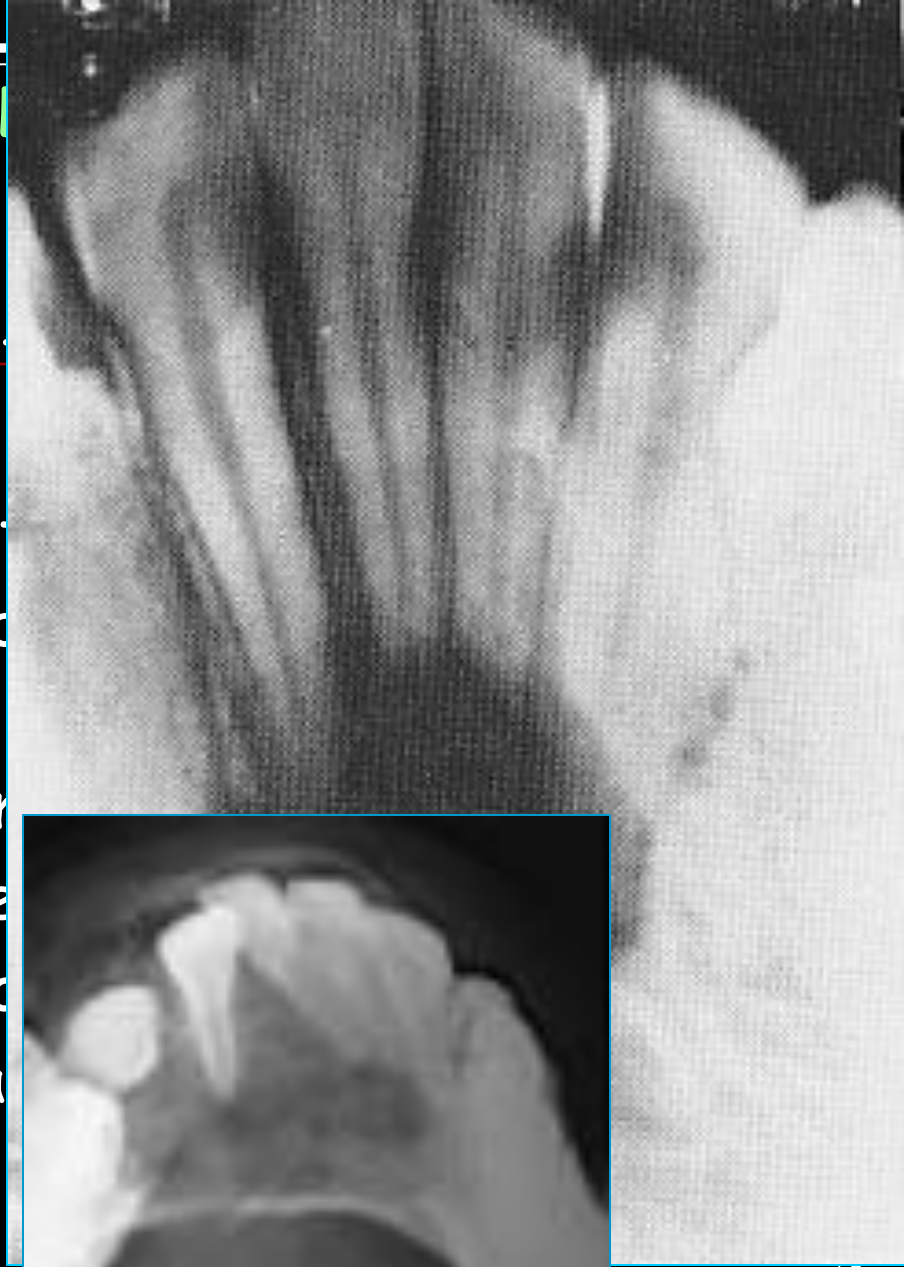GENERAL ORAL HEALTH



• Teeth displaced or resorbed



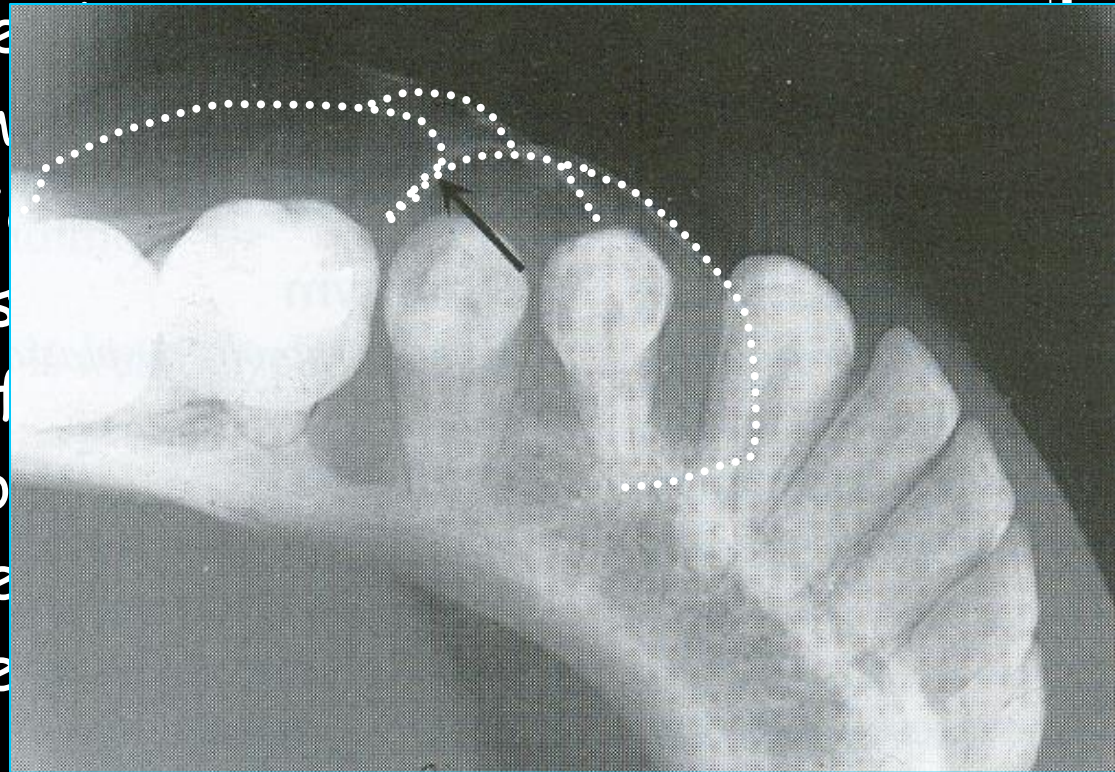
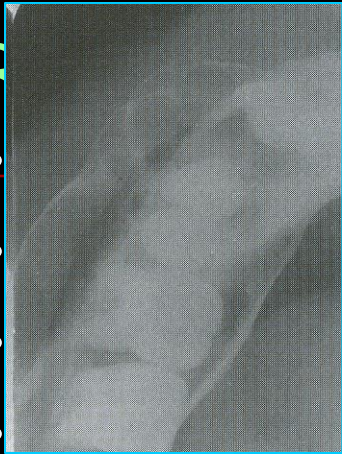S
cor
ar
y in
livi
oth r
neve
oy co
al ca



CENTRAL GIANT CELL GRANULOMA

RADIOLOGIC FEATURES

- Well defined R.L., border corticated or scalloped
- Expansion of R.L may be
- Expansion of thin, w
- Septae which
- Teeth displaced or resorbed
- Expansion of cortex of
- Expansion undulating or
- Max. expansion may de
- Displacement of inf de



CENTRAL GIANT CELL GRANULOMA

DIFFERENTIAL DIAGNOSIS

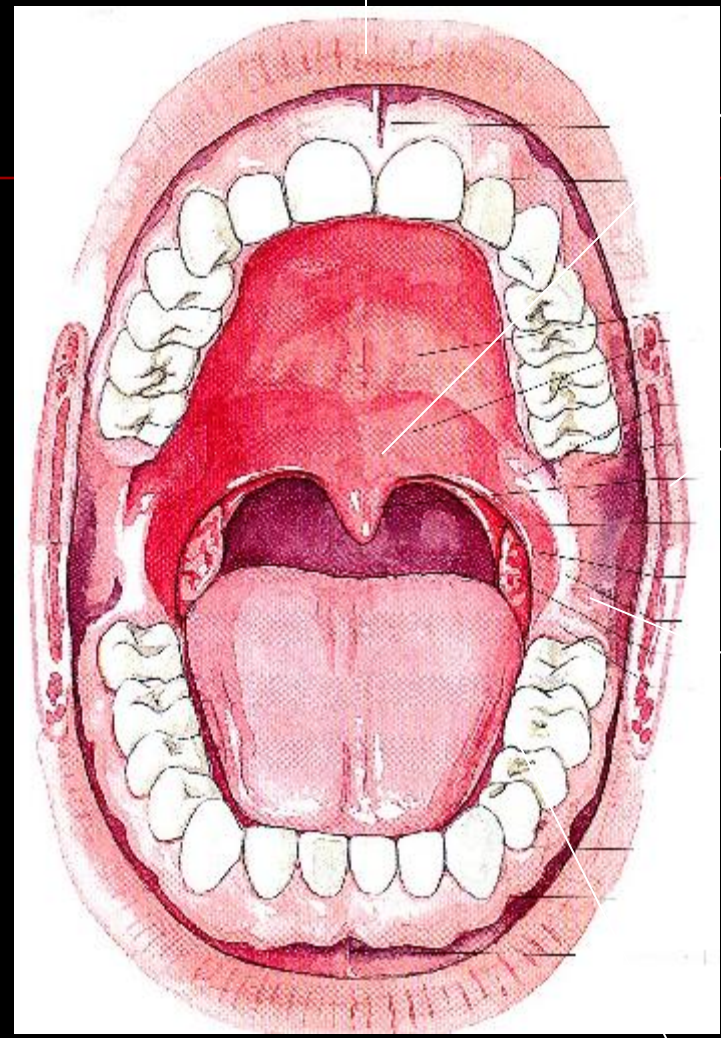
- ~~Ameloblastoma~~
- Odontogenic myxoma
- Aneurysmal bone cyst
- Giant cell lesion of hyperparathyroidism

Management

- If after age 20 consider hyperpara. & investigate
- Enucleation and curettage
- Jaw resection in some cases
- Careful follow-up for recurrence

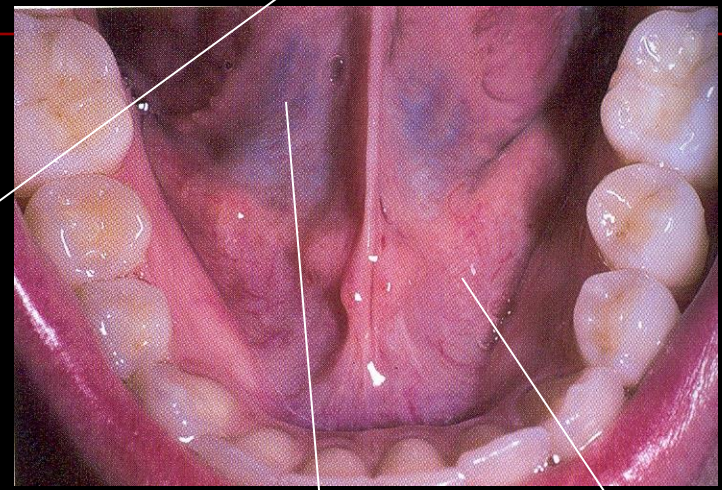
lip

ORAL CANCER



Soft palate

Buccal mucosa



Floor of mouth

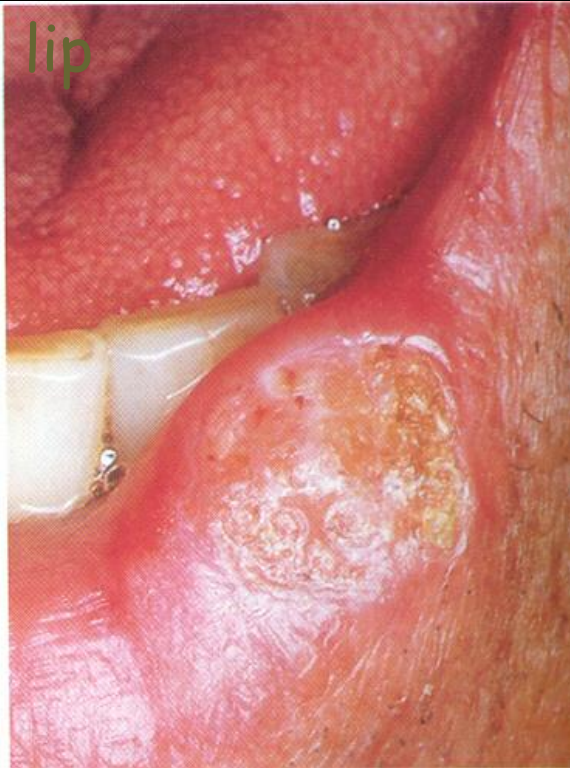Retromolar region

Ventral surface- tongue

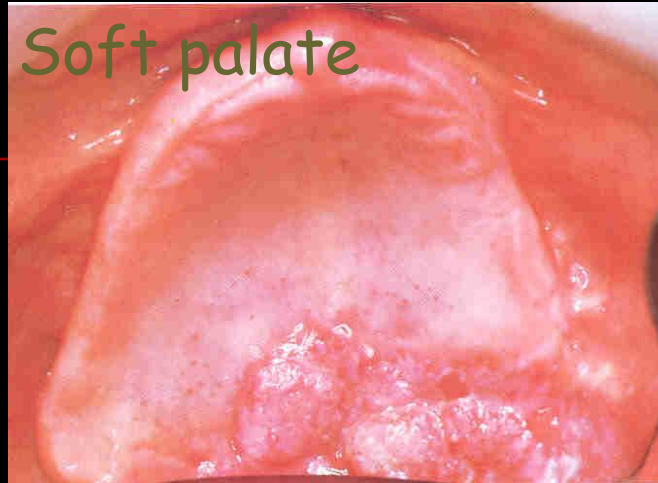
Lateral border tongue

ORAL CANCER

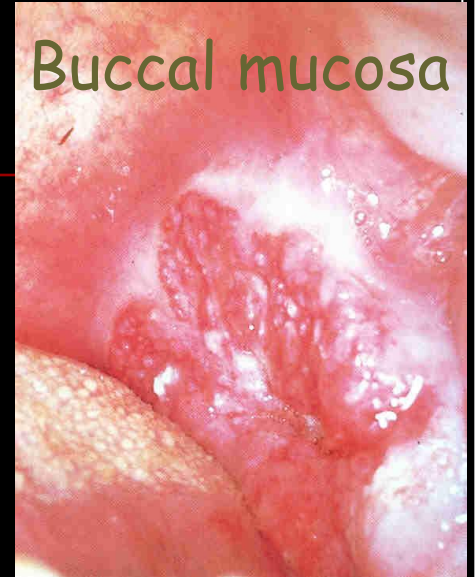
lip



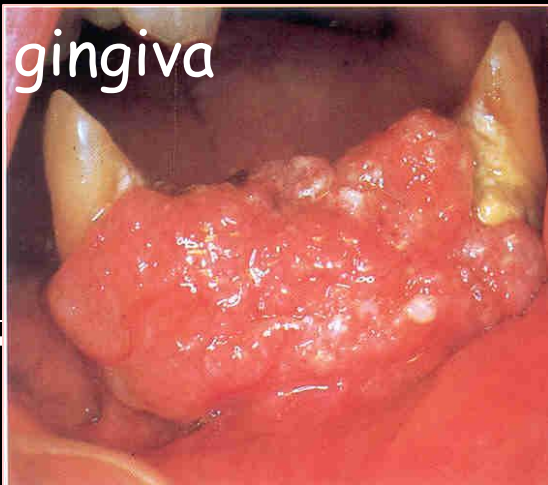
Soft palate



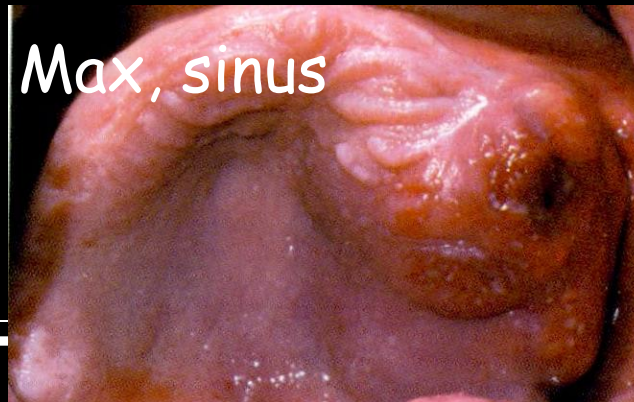
Buccal mucosa



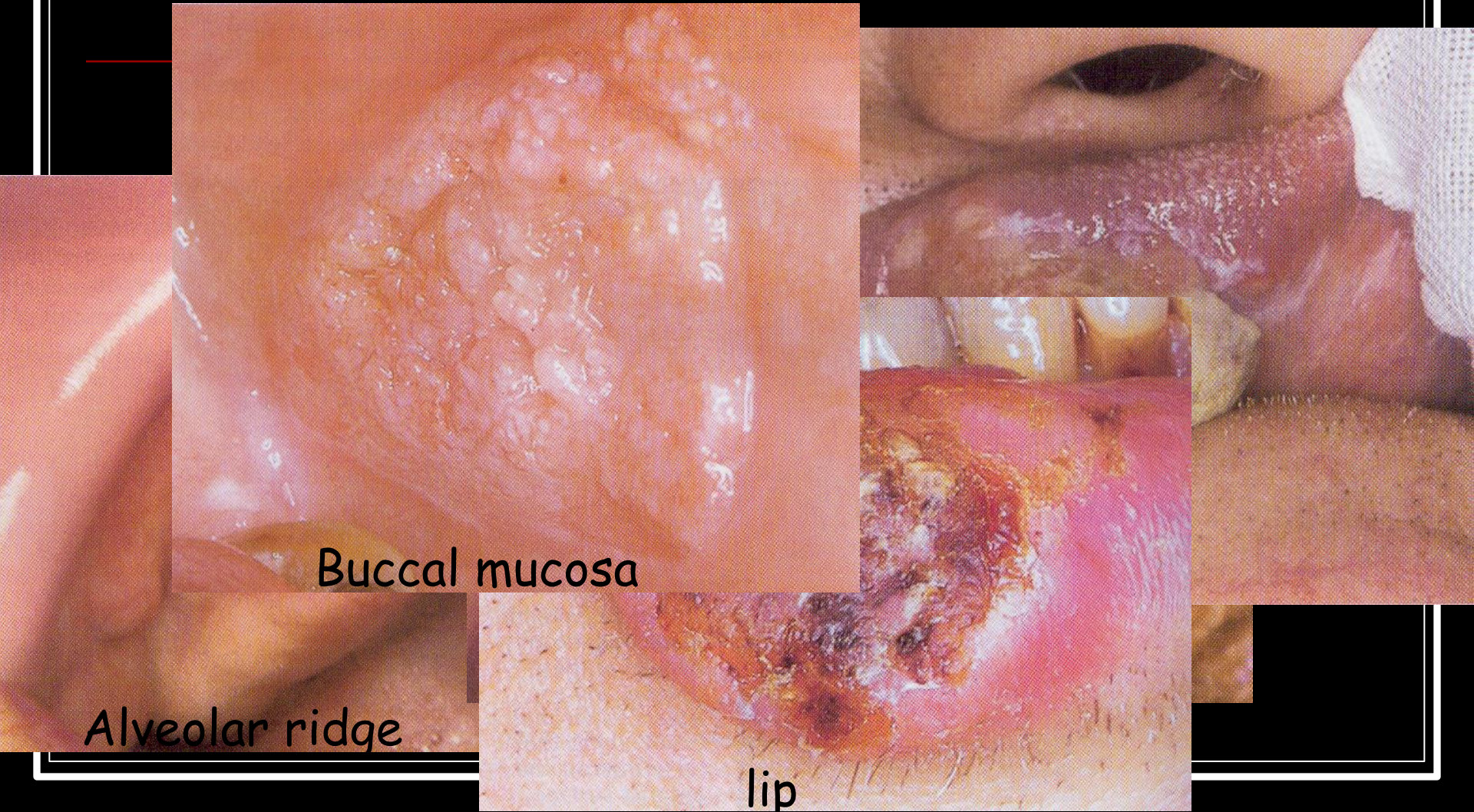
gingiva



Max, sinus



ORAL CANCER



Buccal mucosa

Alveolar ridge

lip

ORAL CANCER

OTHER

- Candidiasis
- syphilis
- electrogal.
- Environmental carcinogens
- L.E
- P.V syndrome
- OSMF

IMPAIRED
IMMUNITY

ORAL LICHEN
PLANUS

U.V. LIGHT

Etiology & Predisposing
Factors

ALCOHOL

TOBACCO
CHEWING

MOUTHWASH

SMOKING

- Cigarette
- Cigar
- Pipe smoking
- Reverse

VIRUSES

- HSV
- HPV

MECHANICAL TRAUMA

- Sharp denture flanges
- Irregular/sharp teeth
- Food burns
- Spicy food
- Poor oral hygiene

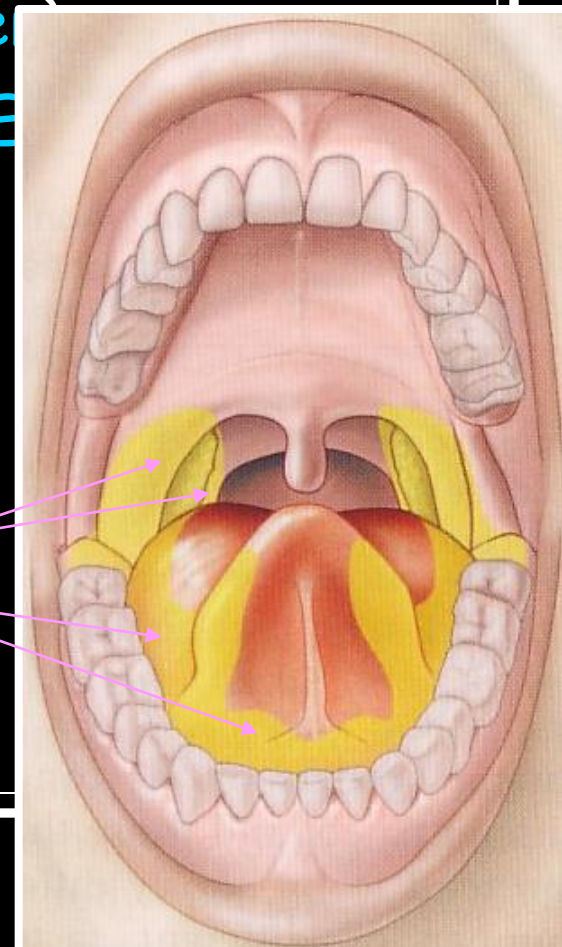
ORAL CANCER

Groups at high risk

- Patients over 40 years of age
- Tobacco and alcohol users/ abusers
- Patients with H/O cancer (Oral or other)
- Patients with viral infections (HIV or EBV)

AREAS AT HIGH RISK

- Ant floor of mouth
- Lat border of tongue
- Tonsillar pillars
- Lat soft palate



ORAL CANCER

SYMPTOMS

- An I.O swelling, on lip, or in neck
- Crust on the lip
- Oral bleeding
- Rough spot
- Change in the bite
- Pain or tenderness
- A denture that no longer fits
- A loose tooth or teeth
- Restriction of tongue or jaw movements
- Taste changes
- Paresthesia, anesthesia
- Double vision
- Chronic cough
- Dry mouth
- Speech changes
- Color changes in tissue
- Symptoms related to primary tumor elsewhere

ORAL CANCER

SIGNS

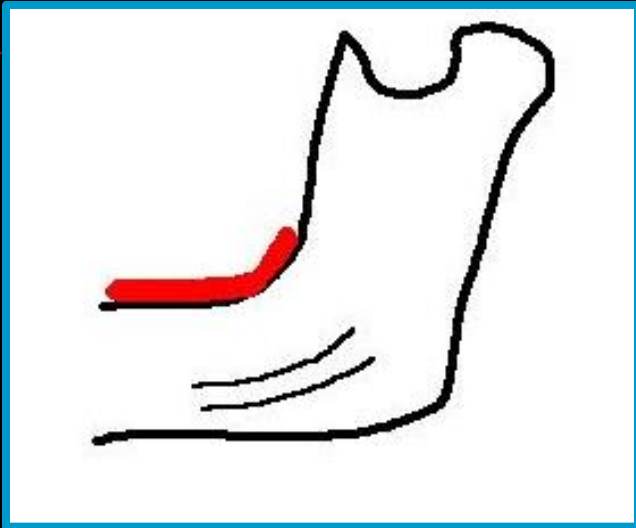
- A red patch
- A red & white patch
- A white patch
- Bluish/ brownish/ black lesion
- Swollen and bleeding gingiva (leukemia)

Most 'oral cancer' (90-95 %) is oral squamous cell Ca. , hence term 'oral cancer' when used loosely implies S.Q.C unless differently mentioned

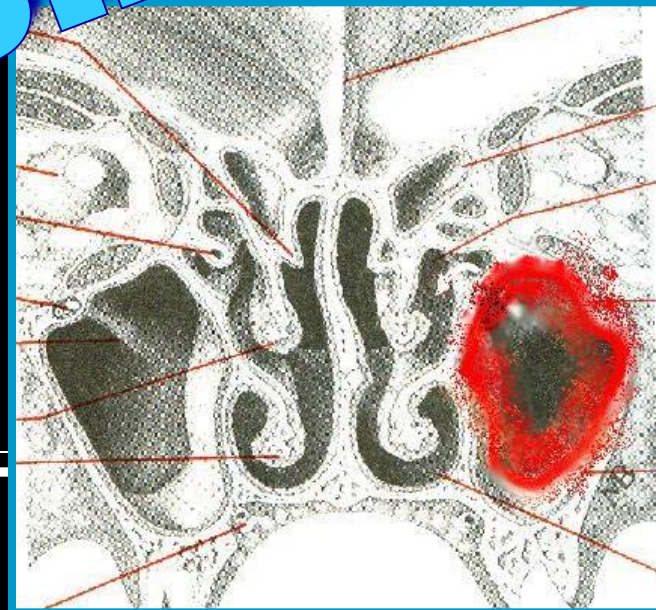
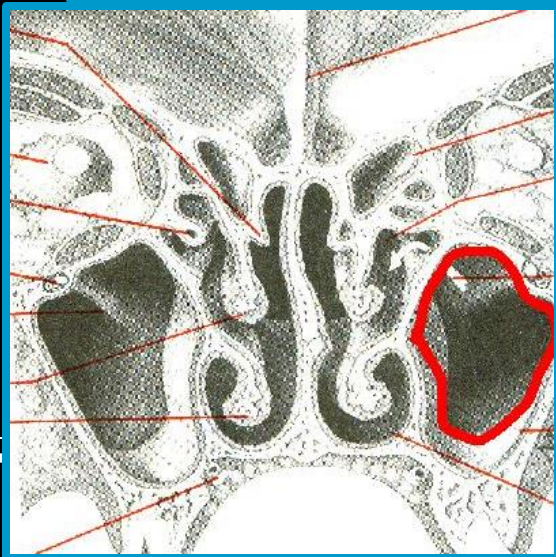
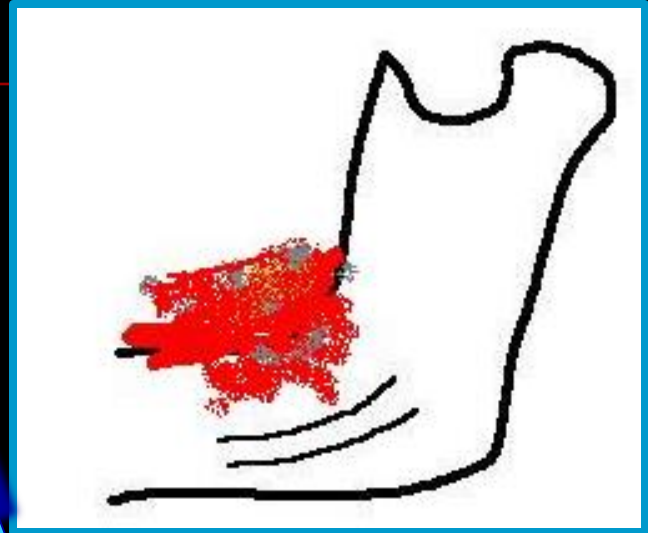ORAL CANCER

SQUAMOUS CELL CARCINOMA

Peripheral lesions invading deeper tissues (bone)

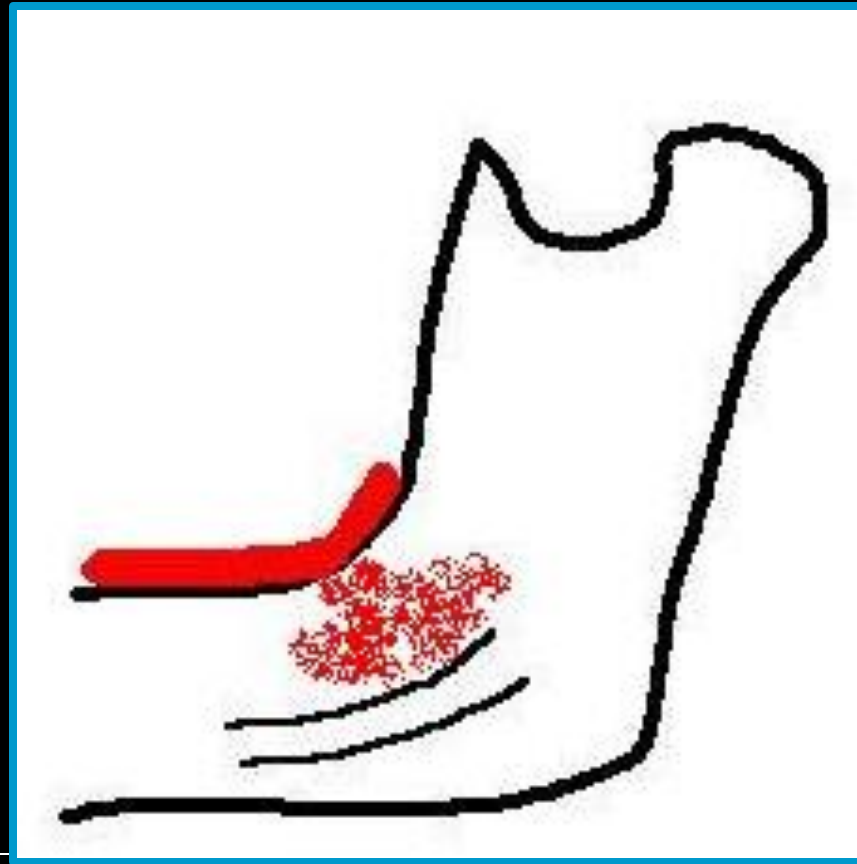


OR



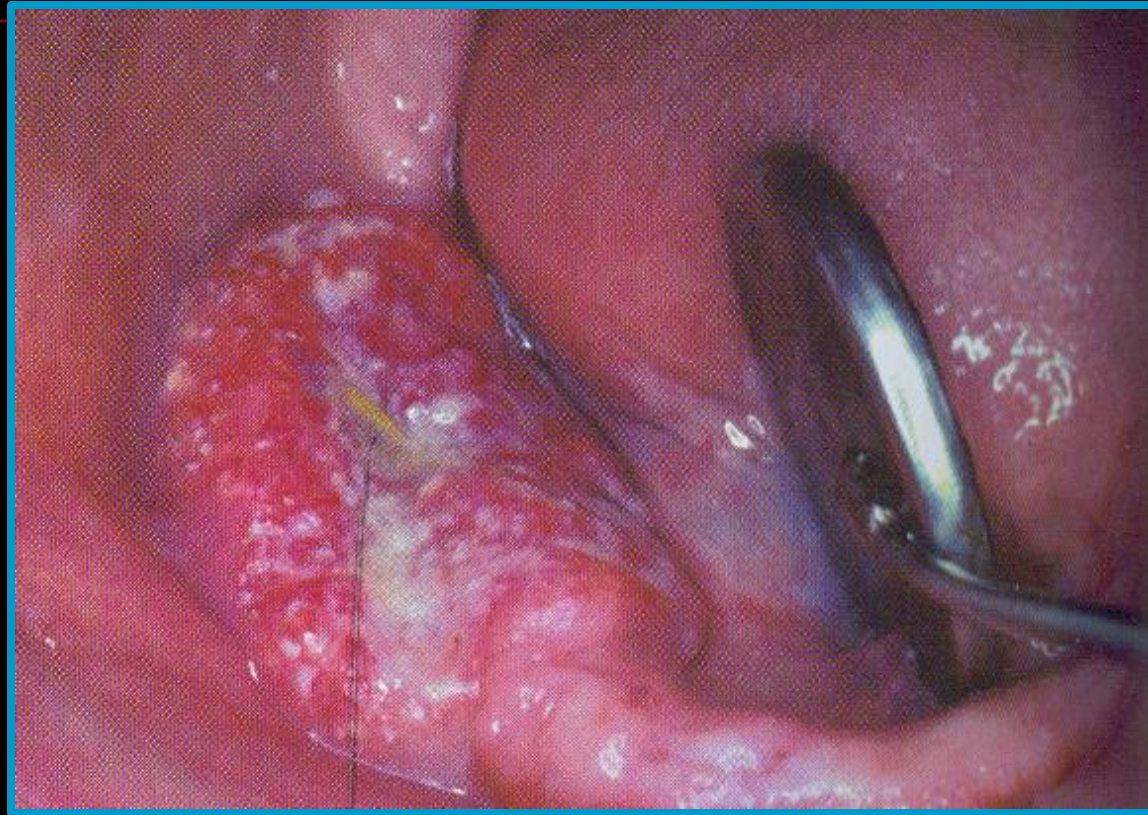
ORAL CANCER

Central S.Q.C originating from malignant transformation of residual epithelium of dental lamina



ORAL CANCER

Peripheral lesions invading deeper tissues (bone)



ORAL CANCER

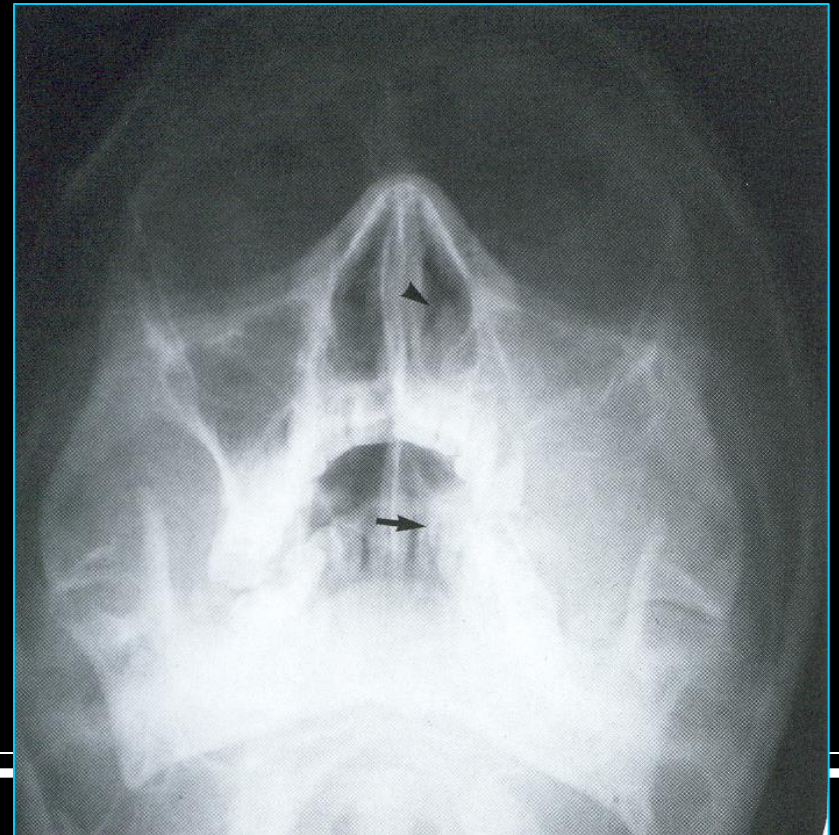
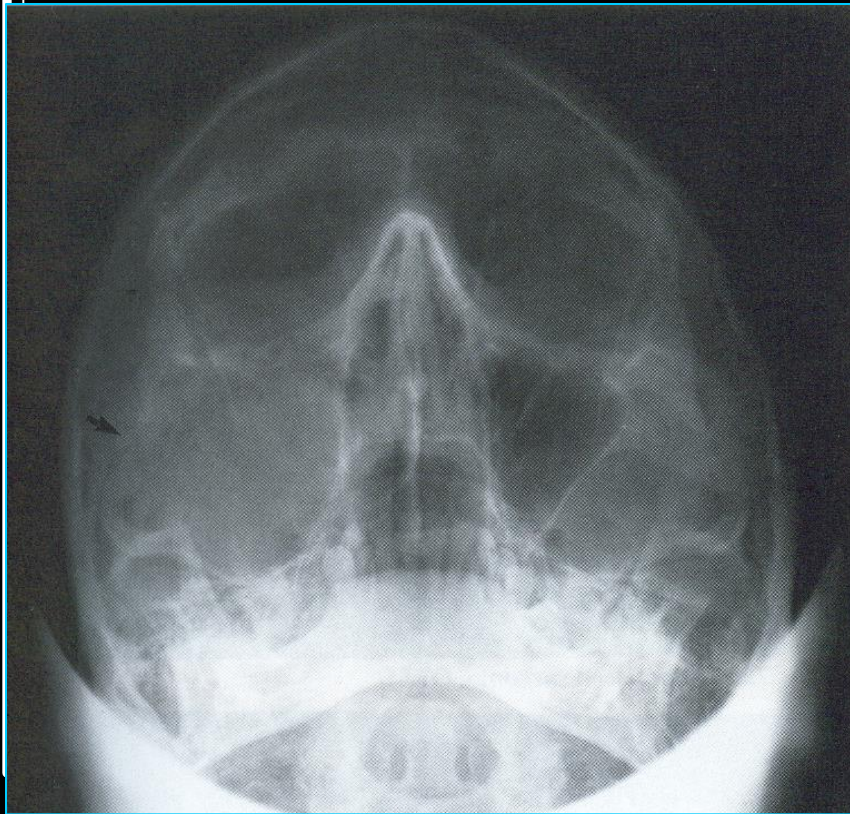
Clinical Features

- Men over 50
- Etiology
- Areas involved
- Small lesions < 1 c.m in diameter-asymptomatic
- Larger lesions- pain, paresthesia, swelling
- Ca in relation to teeth- loosening, exfoliation
 - root resorption
- Expanding lesion - ill fitting of dental prosthesis
- Spread - Direct extension or metastasis

ORAL CANCER

Radiographic Features

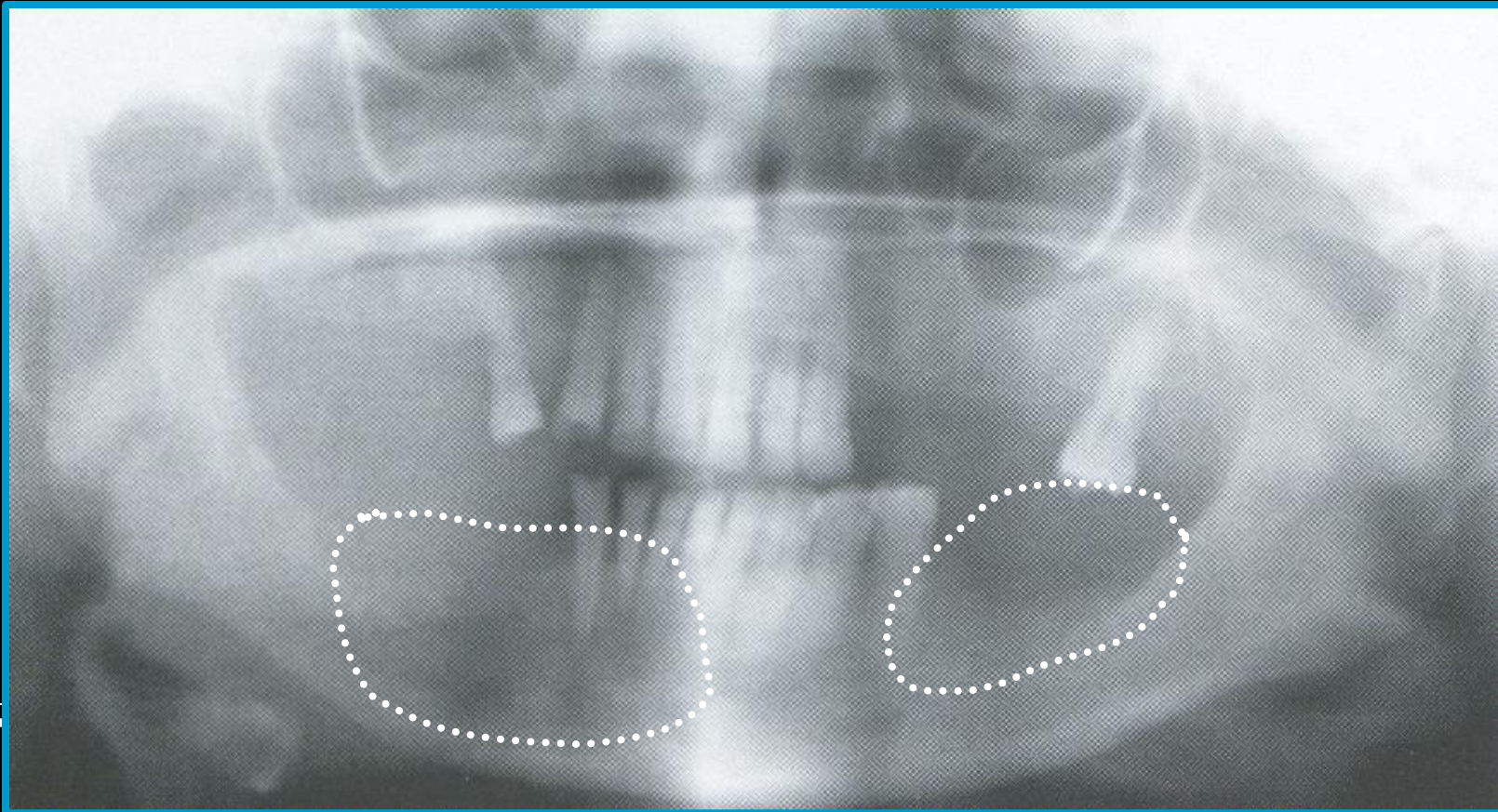
- Destructive lesion
- Erosion of alveolar bone margin



ORAL CANCER

Radiographic Features

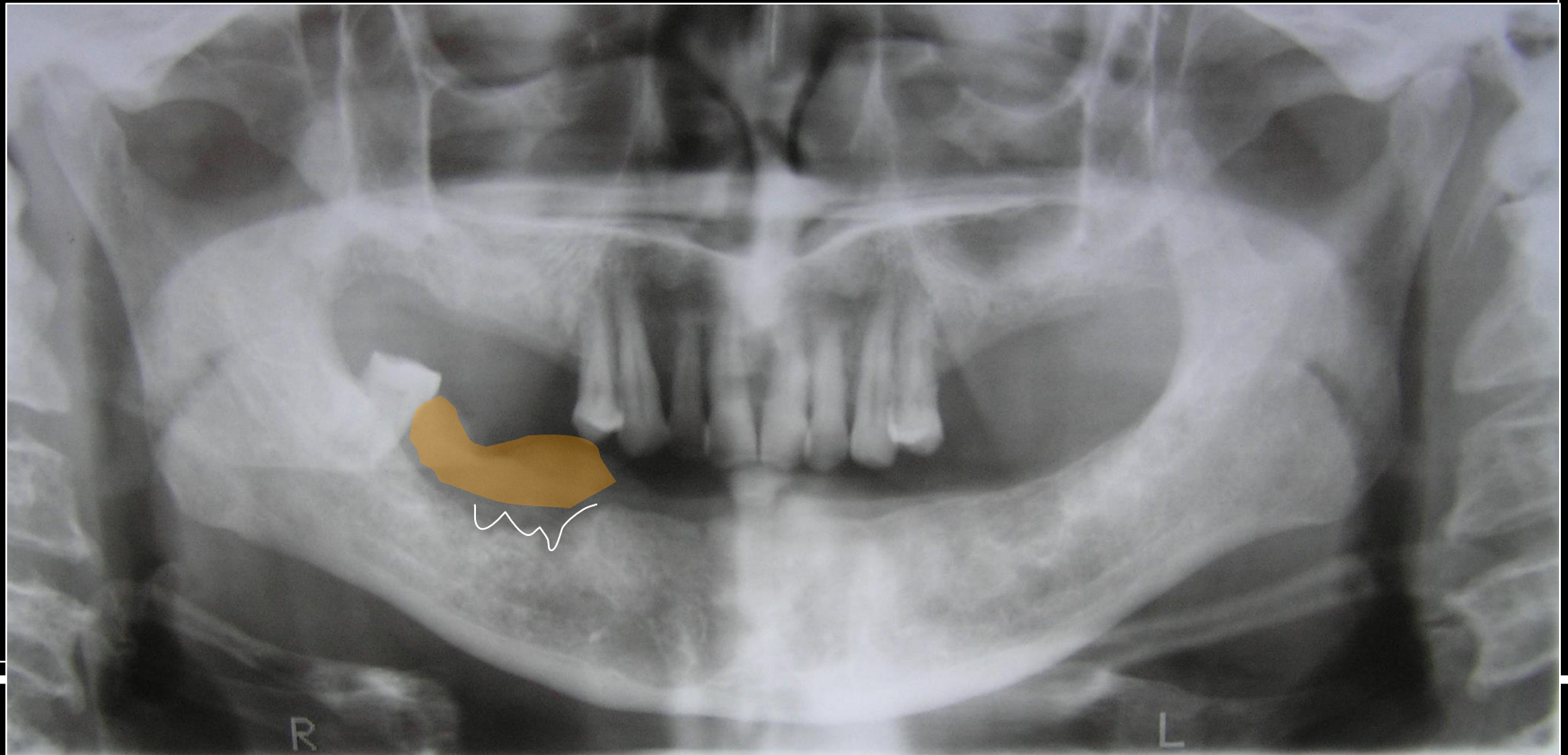
- Destructive lesion
 - Erosion of alveolar bone margin
-



ORAL CANCER

Radiographic Features

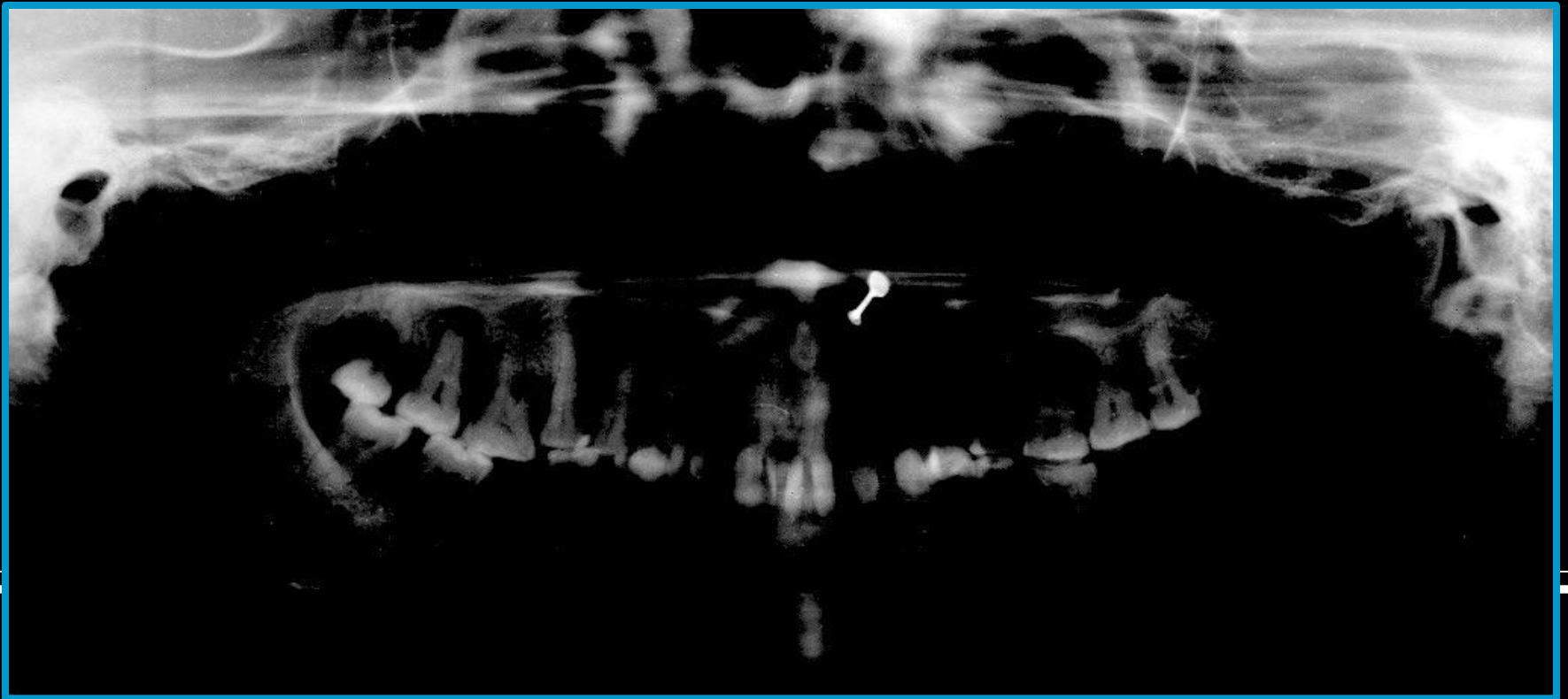
- Destructive lesion
- Erosion of alveolar bone margin



ORAL CANCER

Radiographic Features

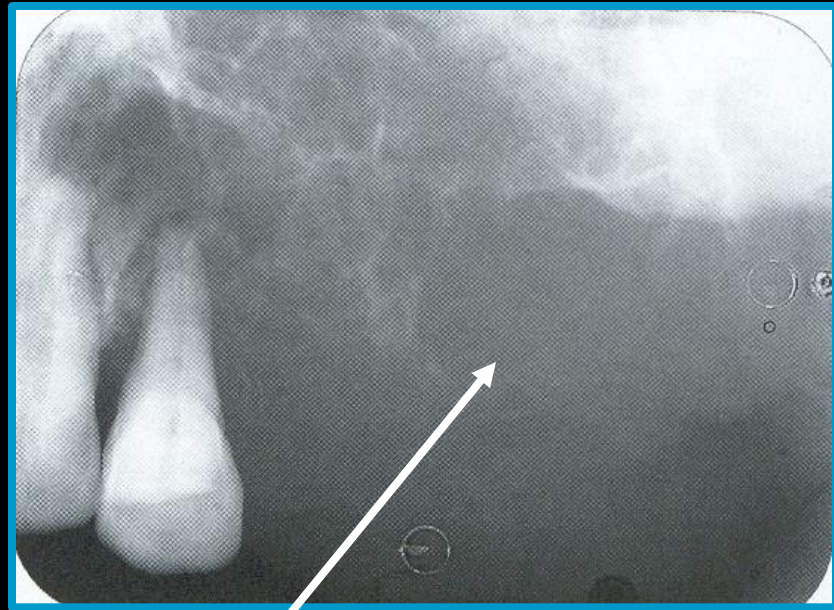
- Destructive lesion
- Erosion of alveolar bone margin
- Destructive lesion with ill-defined irregular margins
- Large mand. Lesion- erode into mand. canal



ORAL CANCER

Radiographic Features

- **'INFILTRATION'** of bone
- Resorption 'bays'
- Jagged bone margins



- Elevated outline of soft tissue
- Pathologic #

ORAL CANCER

Radiographic Features

Central S.Q.C- bone destructive lesion
- small residual islands of bone

D.D

- Osteomyelitis / osteoradionecrosis
 - signs of infection
 - Sequestration
 - Periosteal reaction

D.D- periapical cysts/ granulomas
odontogenic cysts & tumors

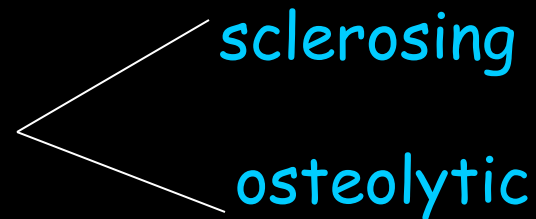S.Q.C originating in a cyst

ORAL CANCER

OSTEOGENIC SARCOMA

Malignant lesions that arise within connective tissue

- less common than Ca, usually young patients
- From osteoblasts containing high level of alkaline phosphatase



ORAL CANCER

OSTEOGENIC SARCOMA

Clinical Features

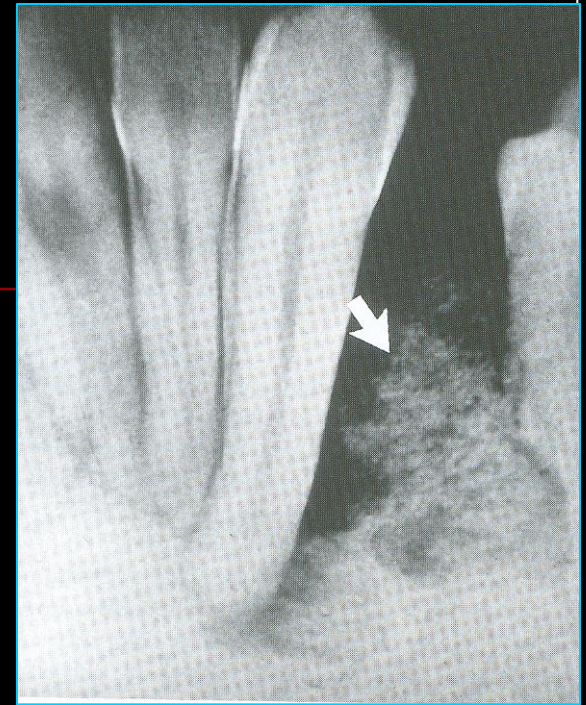- Most common type of primary sarcoma
- Max=Mand., M>F
- Mand.- body, Max. - antrum, alveolar ridge
- Increased incidence in bones - irradiated
 - subjected to trauma
 - Paget's disease
- Swelling with fairly short history
- Rapid growth
- Local recurrence
- Metastasis early via bloodstream to lungs

ORAL CANCER

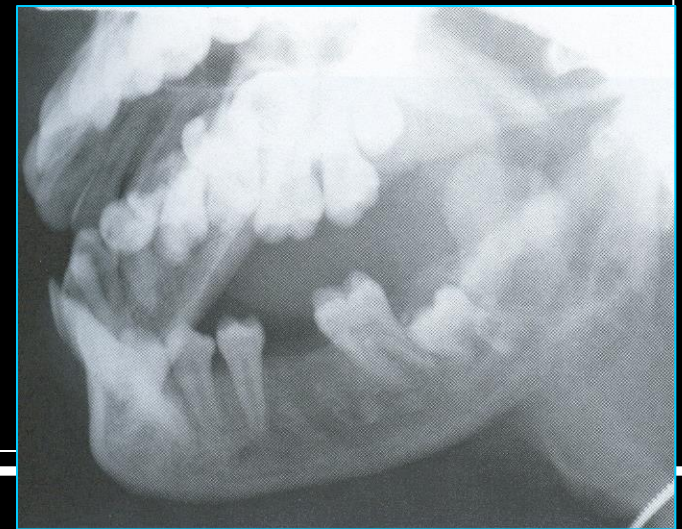OSTEOGENIC SARCOMA

Radiographic Features

- Widening of PDL spaces - asymmetrical



- Lytic variety- borders similar to Ca

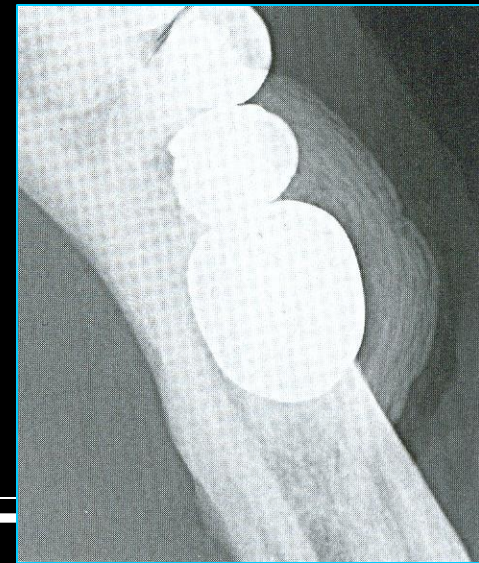

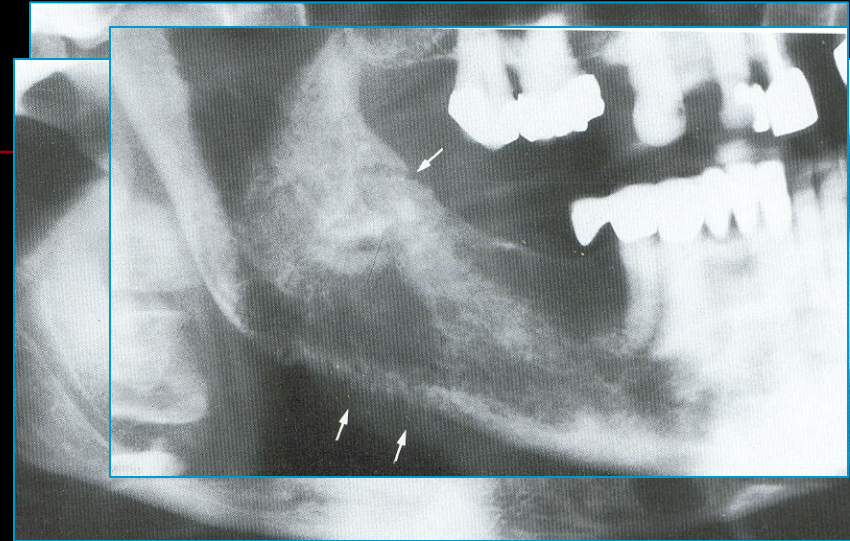


ORAL CANCER

OSTEOGENIC SARCOMA

Radiographic Features

- Mixed and opaque- vertical obliteration of trabeculae by new bone 'sclerotic type'
- Subperiosteal new bone deposition

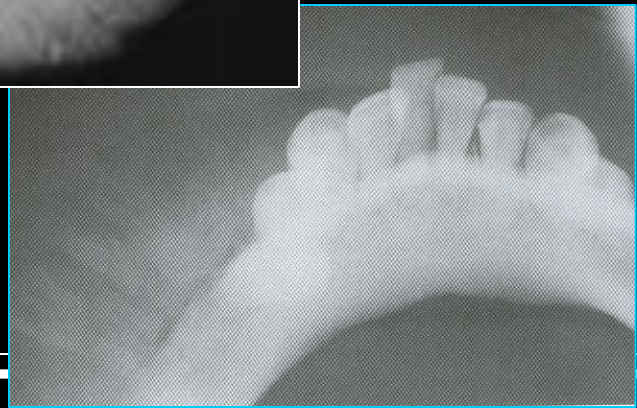
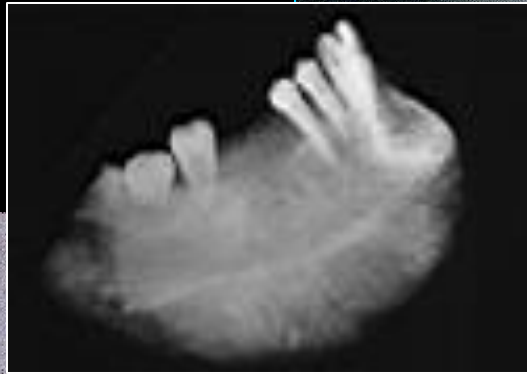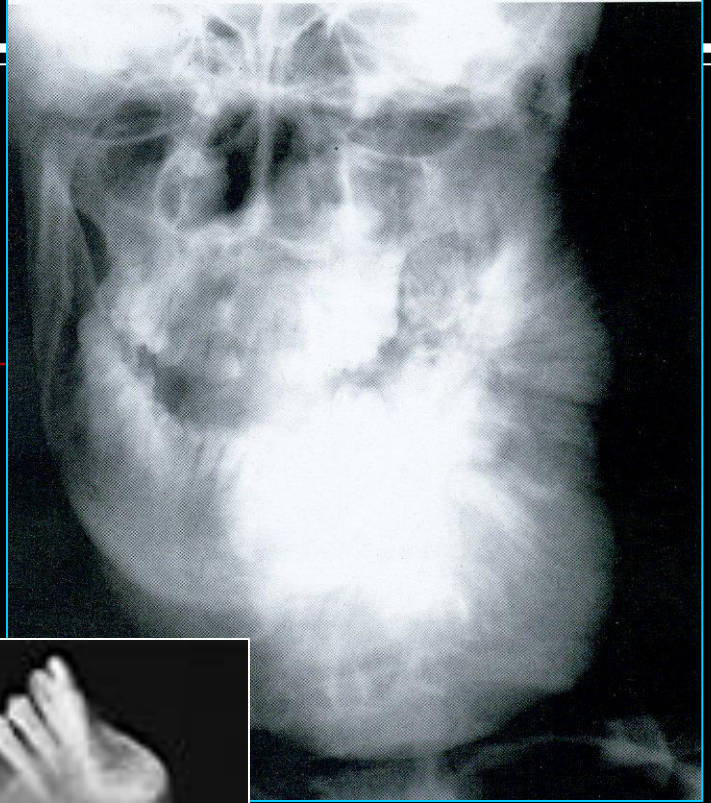


ORAL CANCER

OSTEOGENIC SARCOMA

Radiographic Features

- Tumor bursts through
- Spicules of tumor bone carried along
- 'Sun ray' or sunburst



ORAL CANCER

OSTEOGENIC SARCOMA

Radiographic Features

- Tumor bursts through
- Spicules of tumor bone
Carried along
- 'Sun ray' or sunburst
- Codman's triangles



ORAL CANCER

OSTEOGENIC SARCOMA

D.D

- Osteolytic secondary Ca
- Osteoblastic secondary Ca
- Eosinophilic granuloma
- Giant cell granuloma
- Periostitis

BIOPSY

Biopsy is the removal of sample of tissue from a living individual so that it's cellular components may be examined microscopically

Indications for Biopsy

- When after careful clinical examination, it is not possible to positively identify the condition
- To evaluate all chronic ulcerations & soft tissue enlargements that do not quickly respond to the removal of irritation
- To identify the true nature of any intraosseous lesion not readily apparent on radiograph
- To confirm the existence and nature of a clinically apparent malignancy

BIOPSY

Types of biopsy

- Excisional
- Incisional
- Intraosseous
- Aspiration
- Punch

BIOPSY

Excisional Biopsy

Indications


- When the lesion is relatively small < 1 c.m
- Sessile or pedunculated, circumscribed and freely movable
- Located above the mucosa or just beneath surface

Not indicated

- If lesion is large and diffuse > 1 c.m
- Looks and feels malignant
- Is part of a surface projection of a larger more extensive submucosal lesion

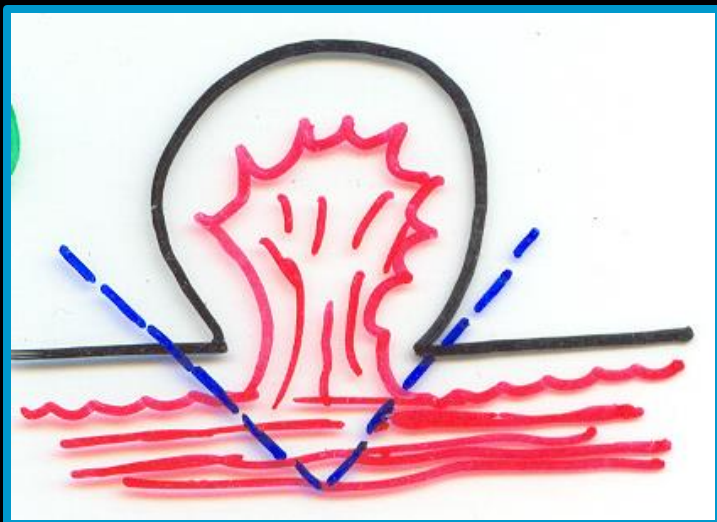
BIOPSY

Excisional Biopsy



BIOPSY

Excisional Biopsy




suture



Elliptical incision at approx. 45° toward centre of lesion

Surgical site closed

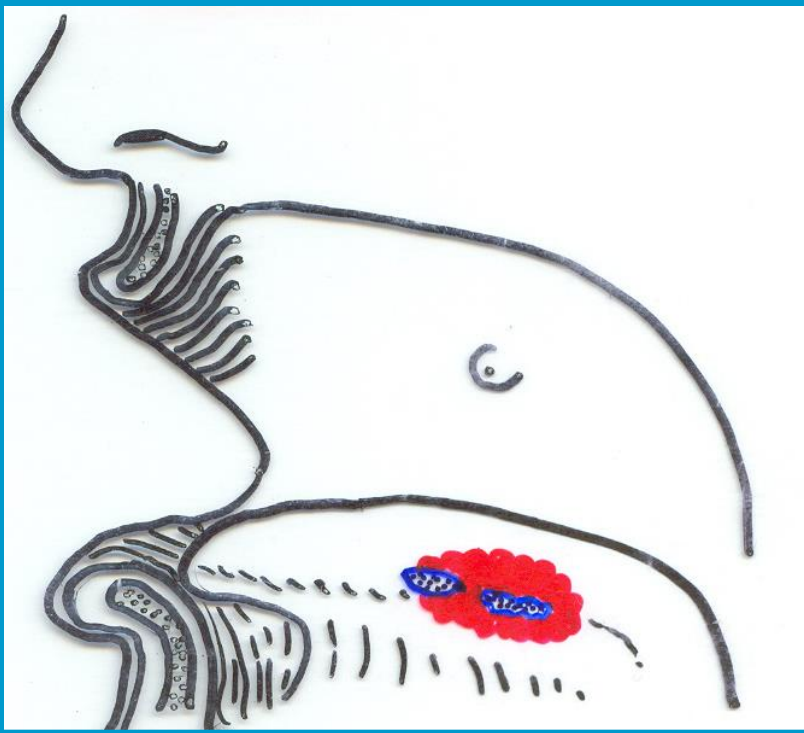


BIOPSY

Incisional biopsy

Indications


- When excisional biopsy not possible
- Lesion widespread or requires a more involved surgical procedure for removal



BIOPSY

suture

Incisional biopsy



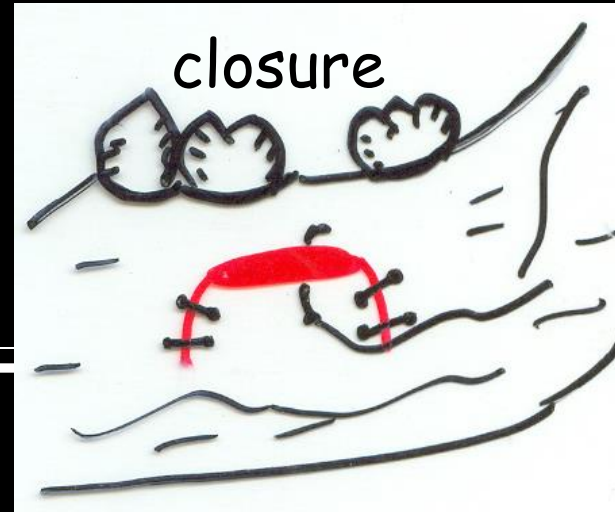

Elliptical incision to muscle/ bone



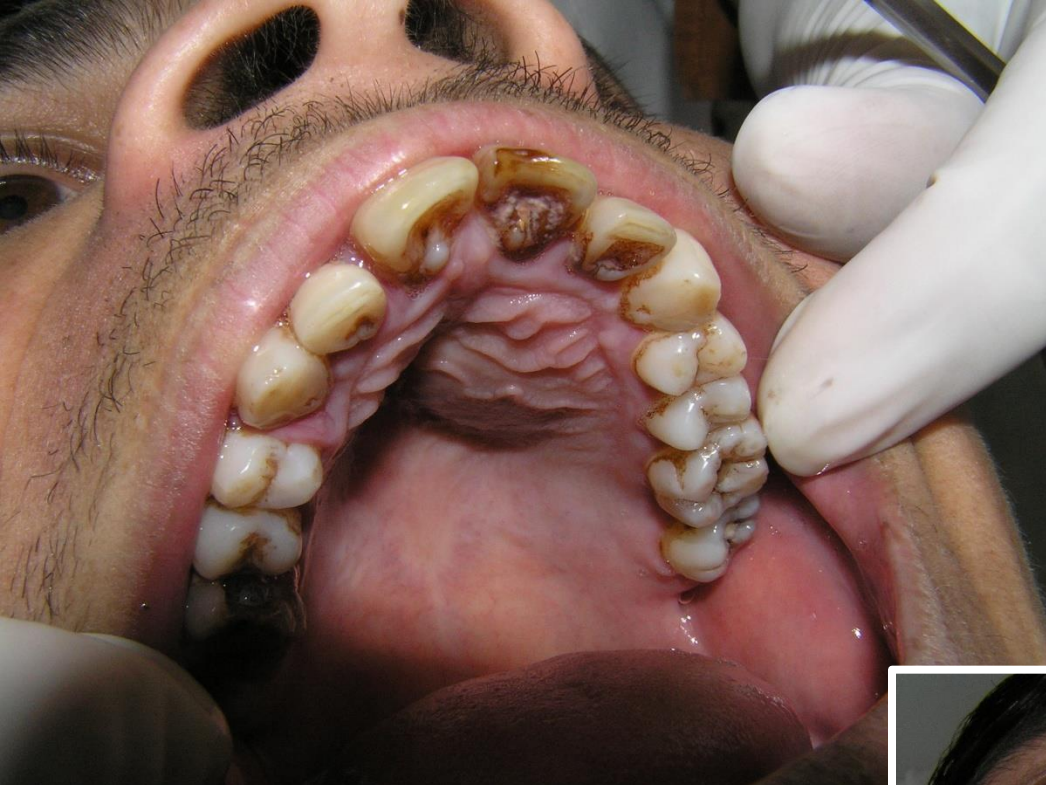BIOPSY

window

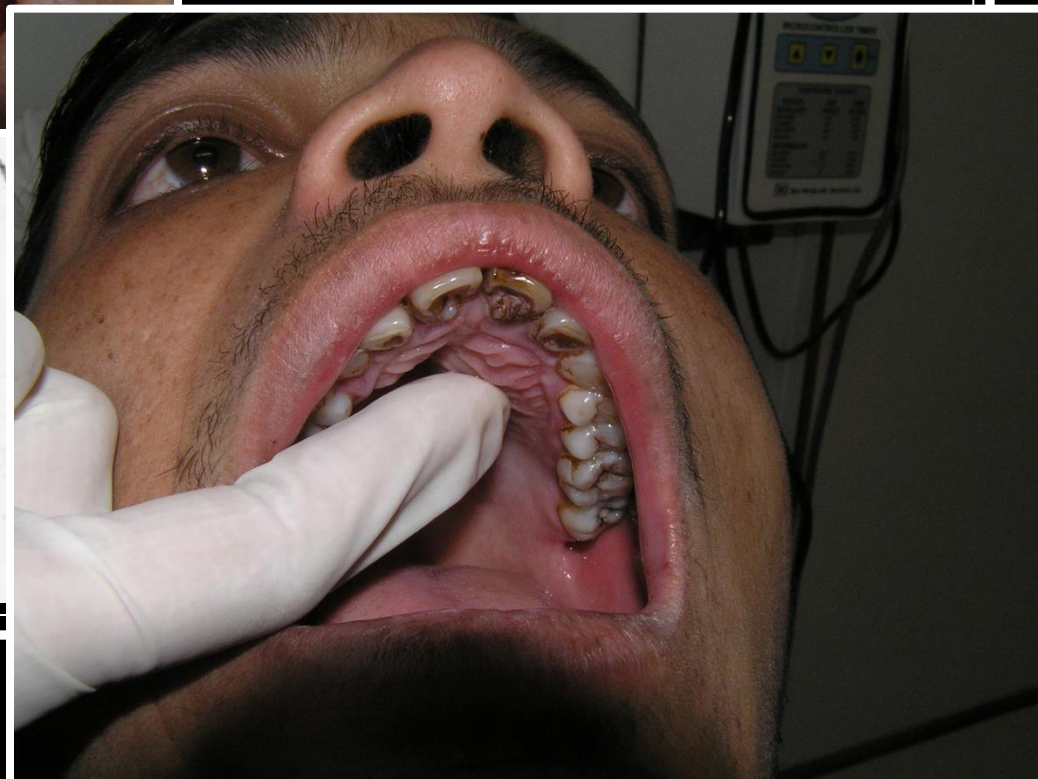
Intraosseous biopsy



curette



nt of 'cystic' lesion



BIOPSY


Exfoliative Cytology

Indications

- Patient refuses biopsy
- Follow-up for recurrences
- Extremely debilitated or pts who pose a healing problem
- To analyze the cells found in the fluid of oral vesicles

BIOPSY

Exfoliative Cytology

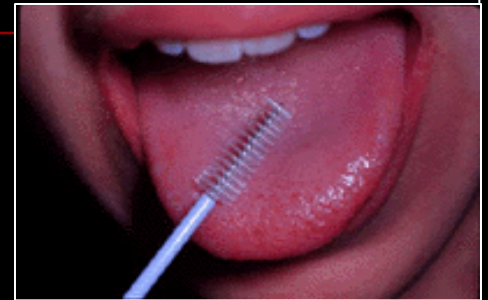

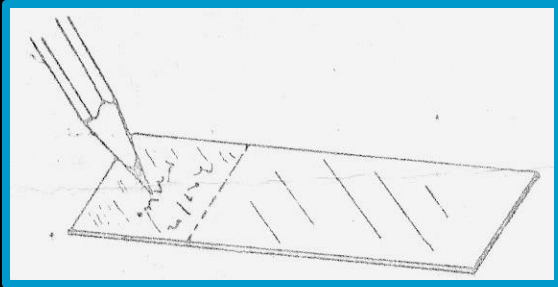


- Glass microscopic slides
- Lead pencil
- Cement spatula/ wax carver
- Wooden tongue depressors

- Toothpicks
- Canister of Cytospray
- 95% isopropyl alcohol

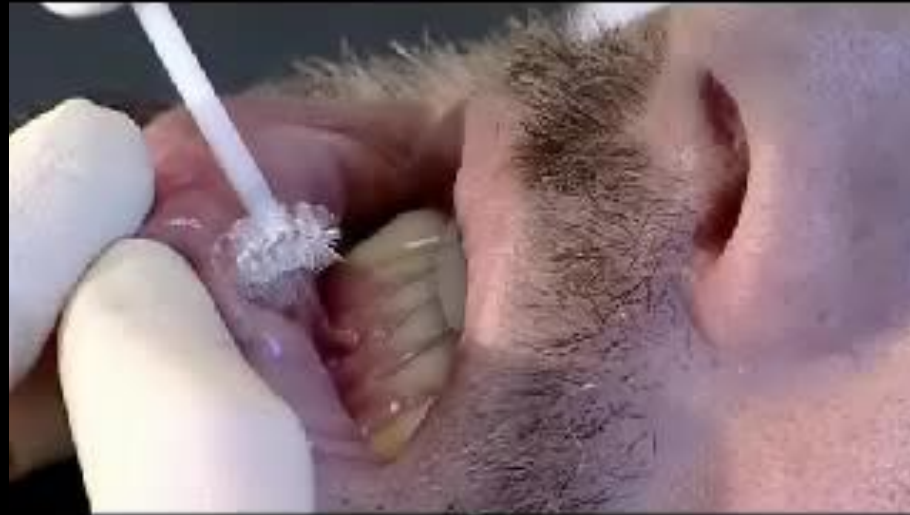BIOPSY

Exfoliative Cytology



BIOPSY

Exfoliative Cytology



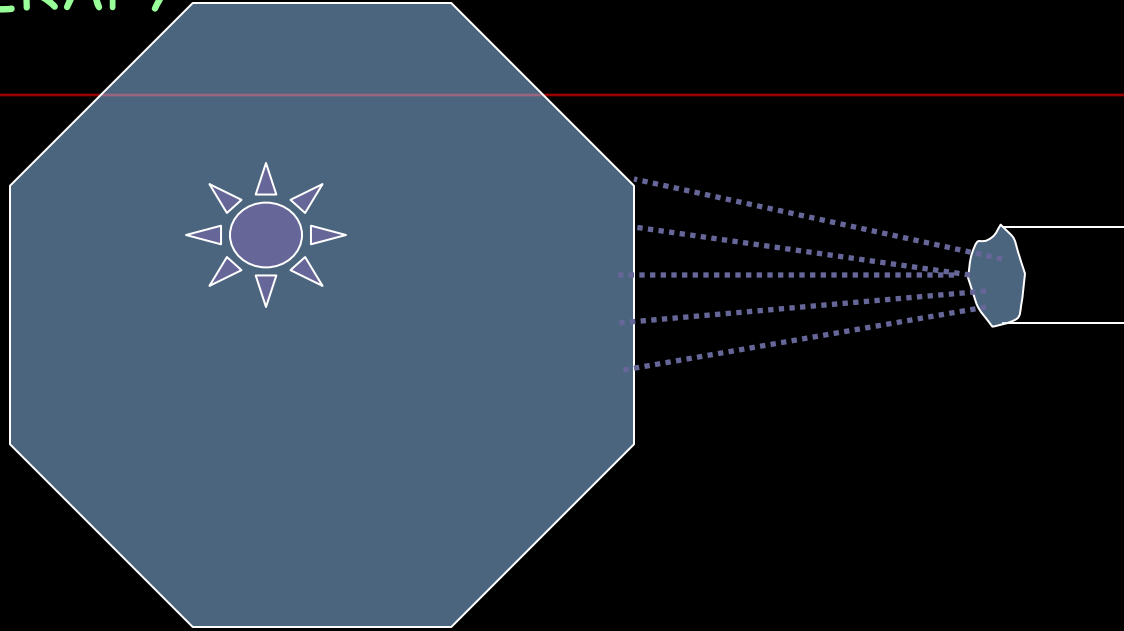
ORAL TUMORS

Management

- Surgery
- Chemotherapy
- Radiotherapy
- Combination of above

ORAL TUMORS

RADIOTHERAPY



BRACHYTHERAPY OR
INTRACAVITARY
RADIATION THERAPY

EXTERNAL BEAM
RADIATION

ORAL TUMORS

Radiotherapy

HIGH ENERGY
ELECTRO-MAGNETIC
RADIATION

HIGH ENERGY
PARTICULATE MATTER

HIGH ENERGY
ELECTRO-MAGNETIC
RADIATION

PRODUCT OF DECAY OF
RADIOACTIVE- ^{60}Co

ACCELERATING PARTICULATE
MATTER ACROSS HIGH P.D
AGAINST HEAVY METAL

TARGET

ORAL TUMORS

CANCER CHEMOTHERAPY

- Alkylating agents
 - Antimetabolites
 - Antimitotic agents
 - Antibiotic
-

Complications

- Mucositis
- Bacterial infections
- Fungal infections
- Viral infections
- Xerostomia
- Hemorrhage
- Neurologic complications
- Inadequate nutrition