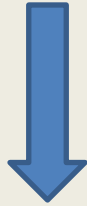

Osteomyelitis

An inflammatory reaction of bone to infection



- tooth,
- fracture site,
- soft tissue wound or
- surgery site.

- root canal,
- a periodontal ligament or
- an extraction site.

mandible > maxilla

- poor blood supply
- Dense mandibular cortical bone


Avascular bone

- therapeutically irradiated bone,
- osteopetrosis,
- Paget's disease, and
- florid osseous dysplasia

underlying predisposing factor

- malnutrition,
- alcoholism,
- diabetes,
- leukemia or anemia

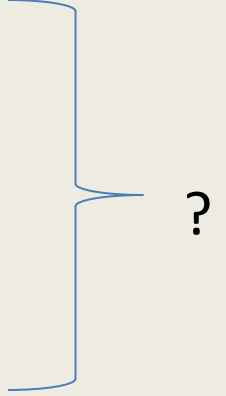
Acute osteomyelitis



so rapid that bone resorption does not occur



radiolucency may not be present on a radiograph



Clinical features



CRITERIA

Acute osteomyelitis → after approximately two weeks

↓
chronic stage,

← enough bone resorption

→ radiographic mottling and blurring of bone.
(diffuse radiolucency with mottled & indistinct margins of the bone due to involvement of the trabeculae)

Surrounded by involucrum →

No vascular supply

↓
formation of pieces of sequestra or necrotic bone surrounded by pus.

fistulous tract may develop

→ overlying skin

→ mucosa

Chronic osteomyelitis: it is a chronic inflammatory process involving bone trabeculae & bone marrow, occurs in response to a low-grade process rather than a destructive & intense destructive inflammation caused by virulent bacteria.

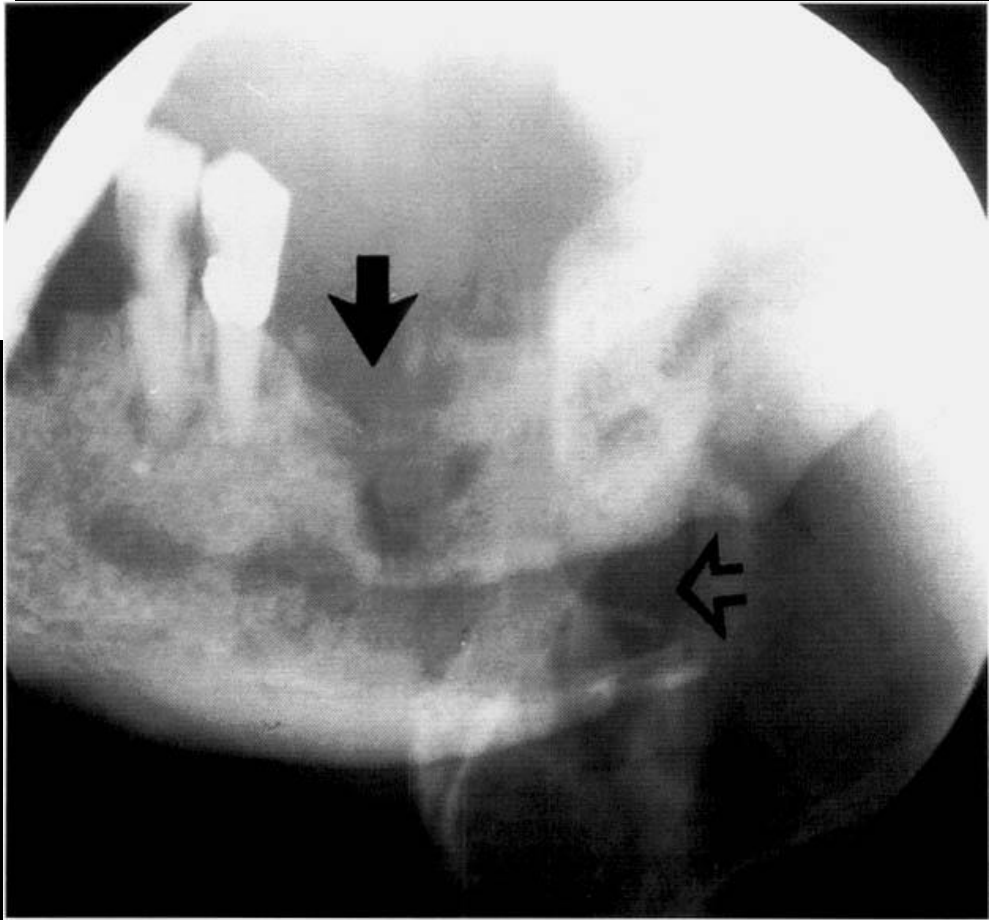
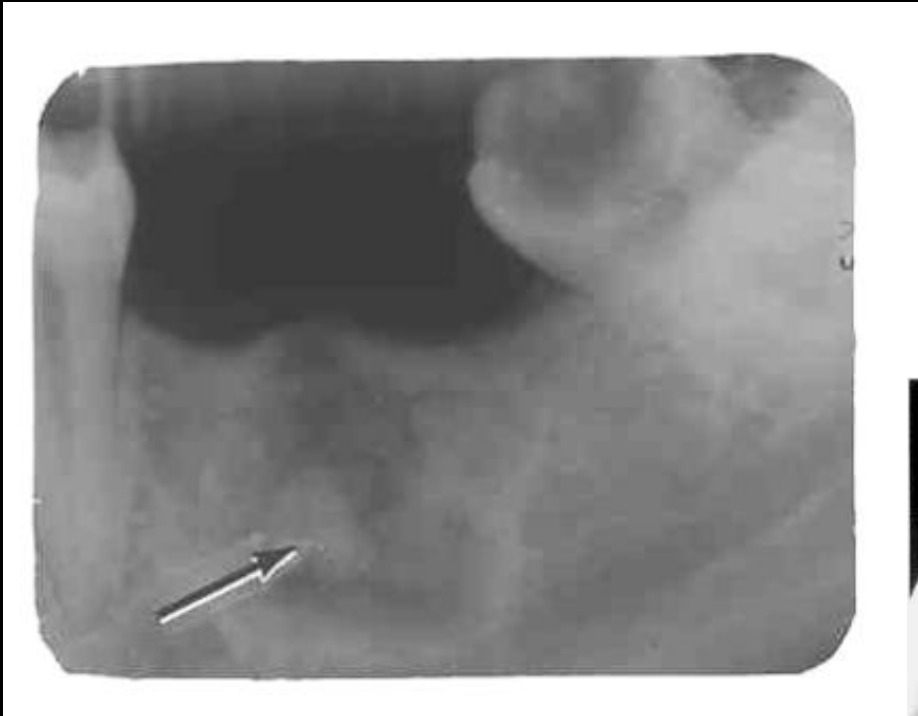
Clinically:

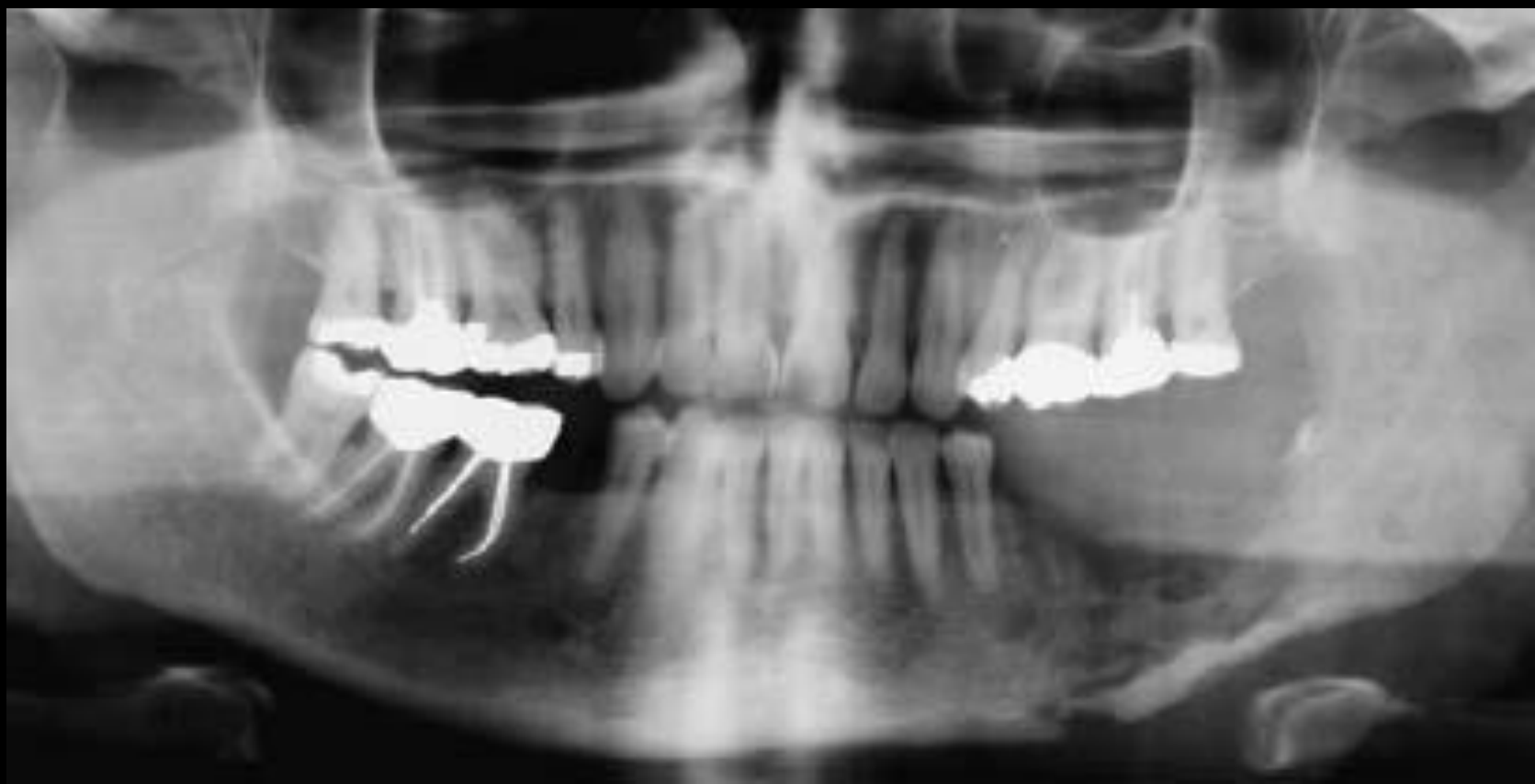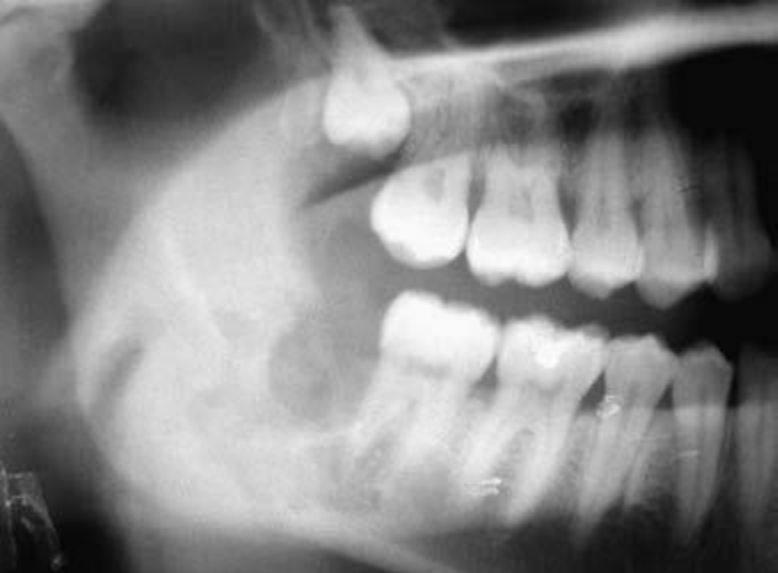1-there is little or no pain

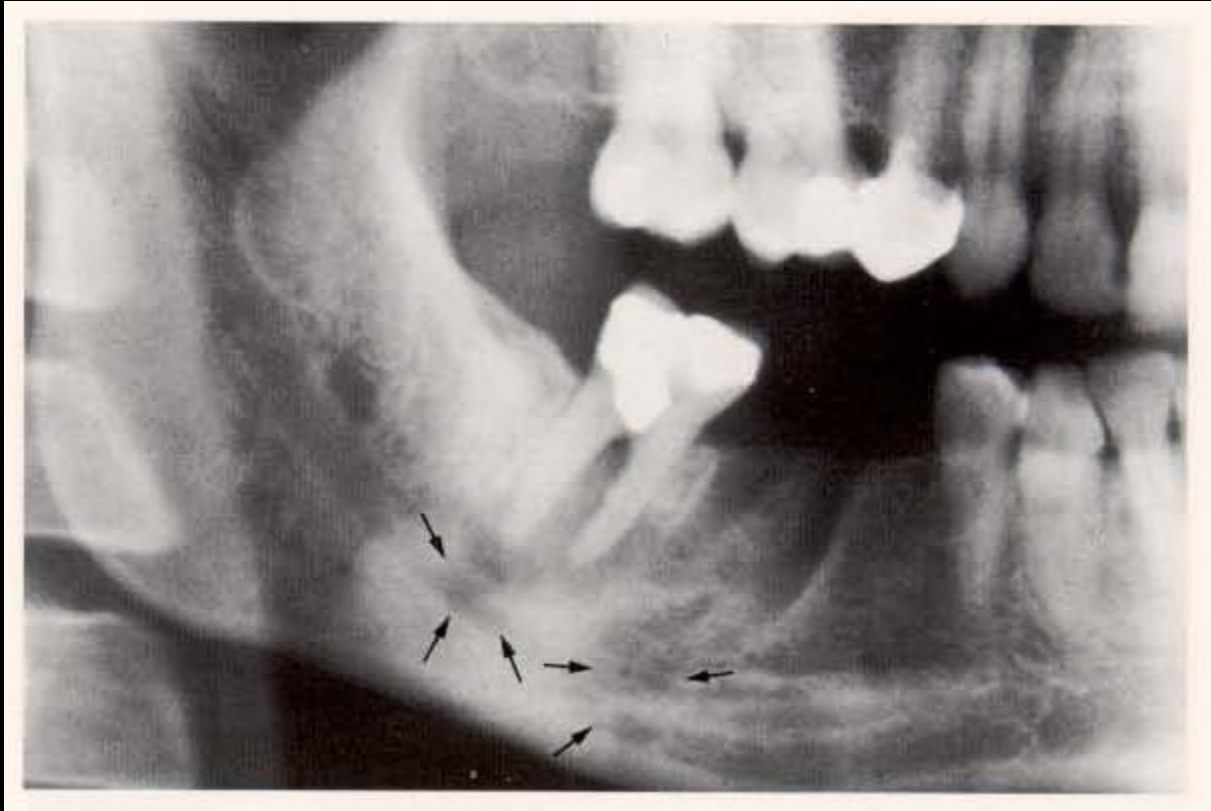
2-hard swelling because the irritant may be so mild result in dense trabeculae & even lay down additional bone

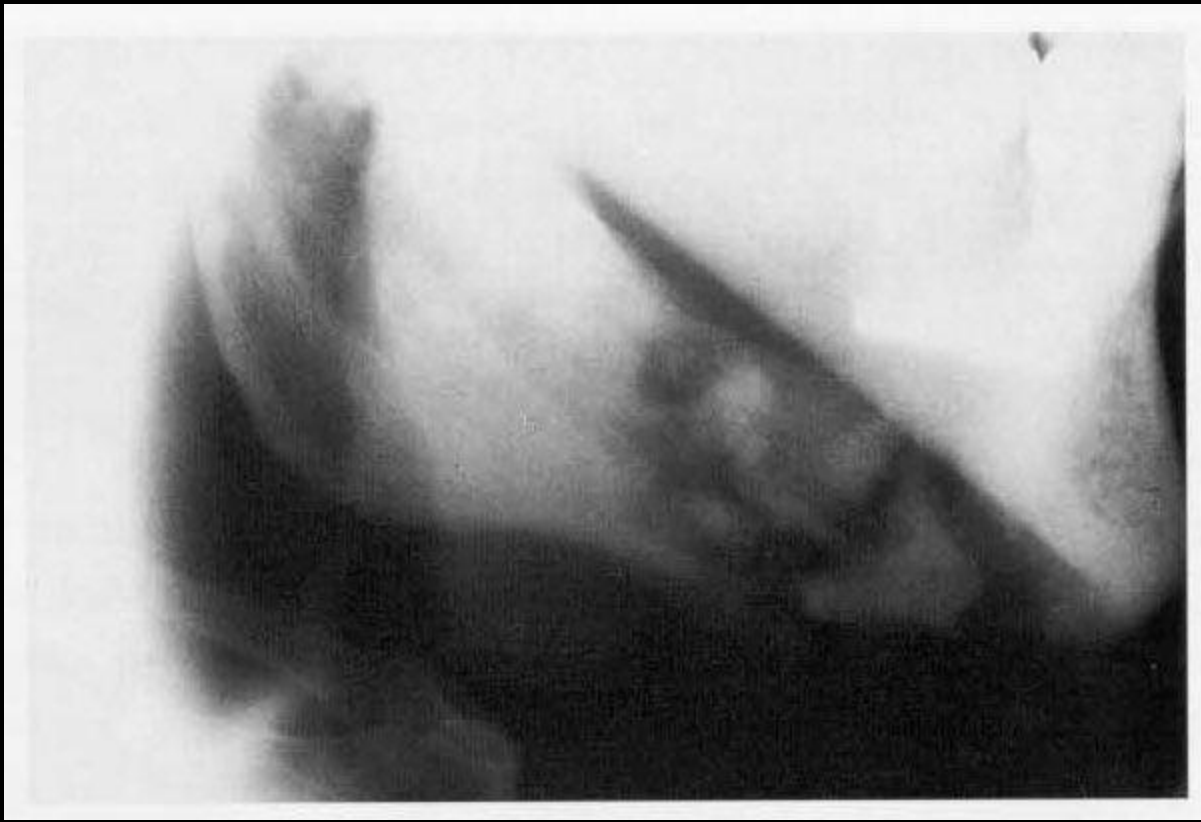Main radiographic features of chronic osteomyelitis

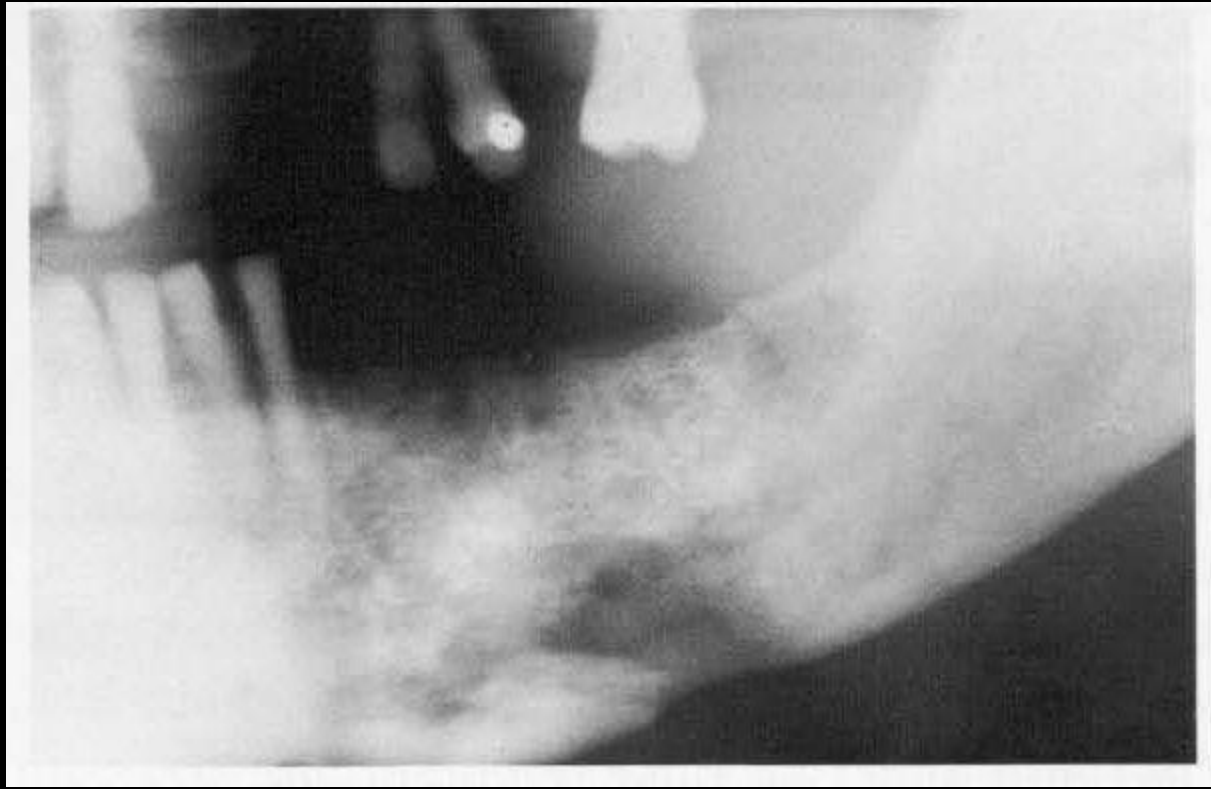- Localized patchy or moth-eaten areas of bone destruction
- Sclerosis of the surrounding bone
- Evidence of small radiopaque sequestra of dead bone sometimes within the area of bone destruction
- Evidence of an involucrum surrounding the area of destruction following extensive subperiosteal bone formation

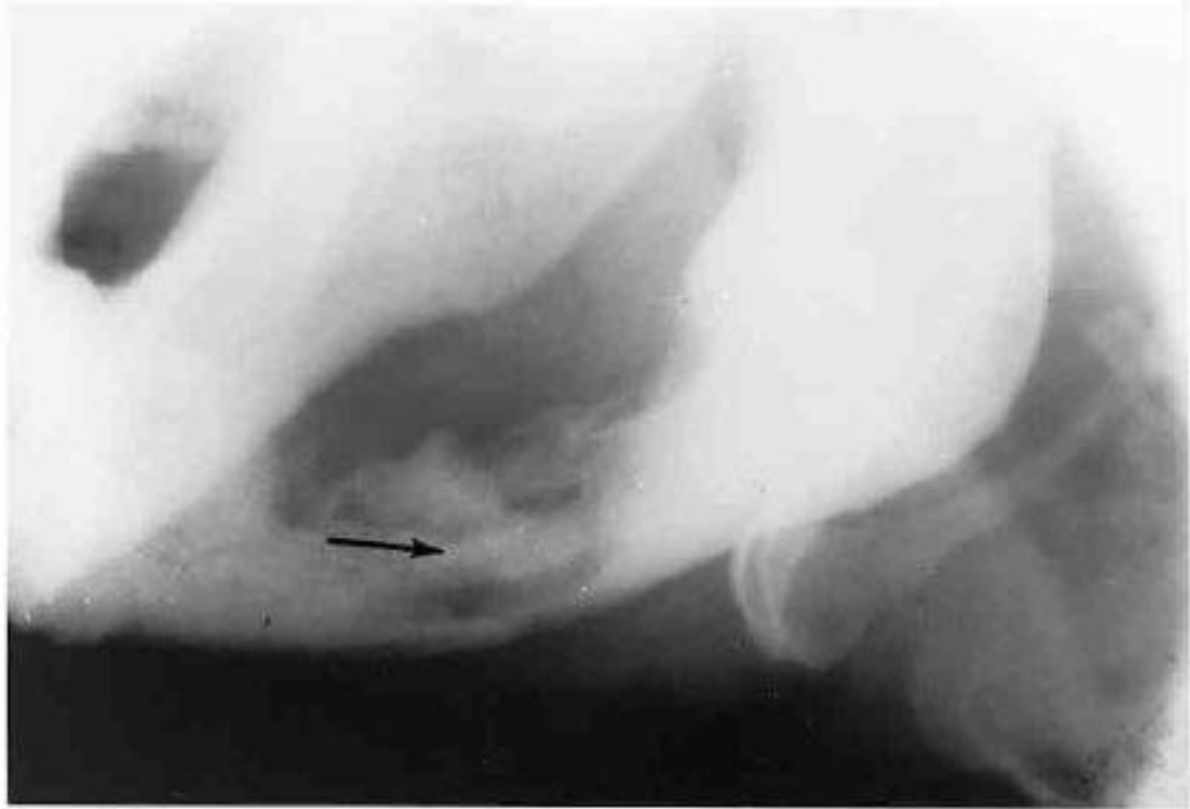


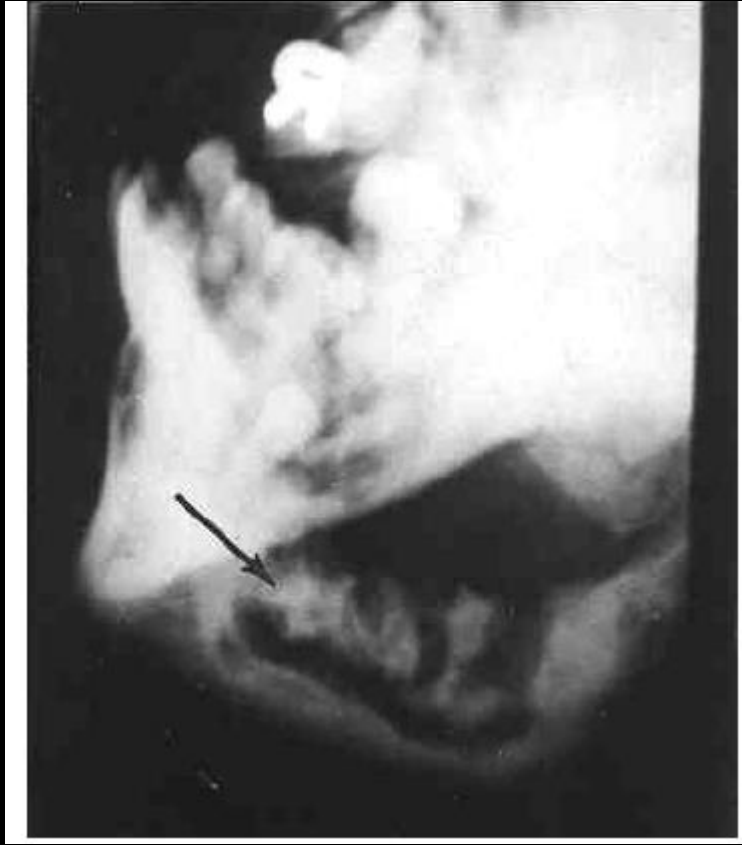


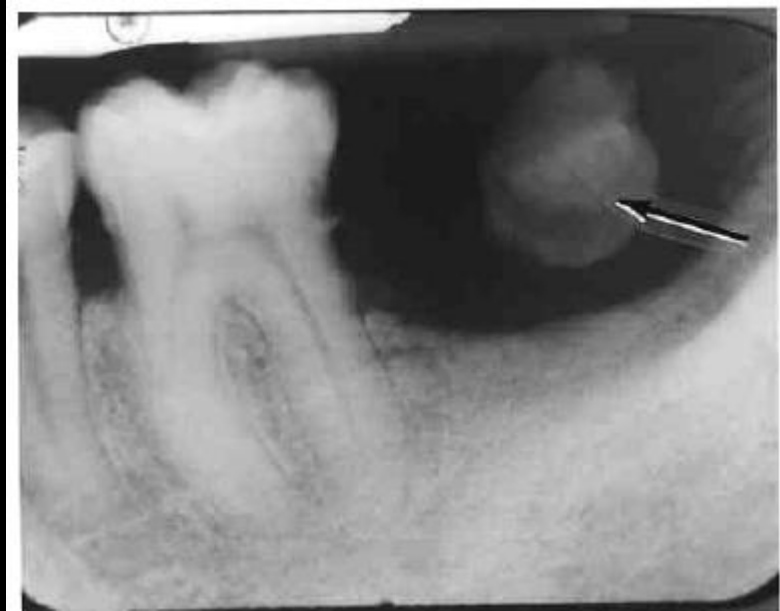






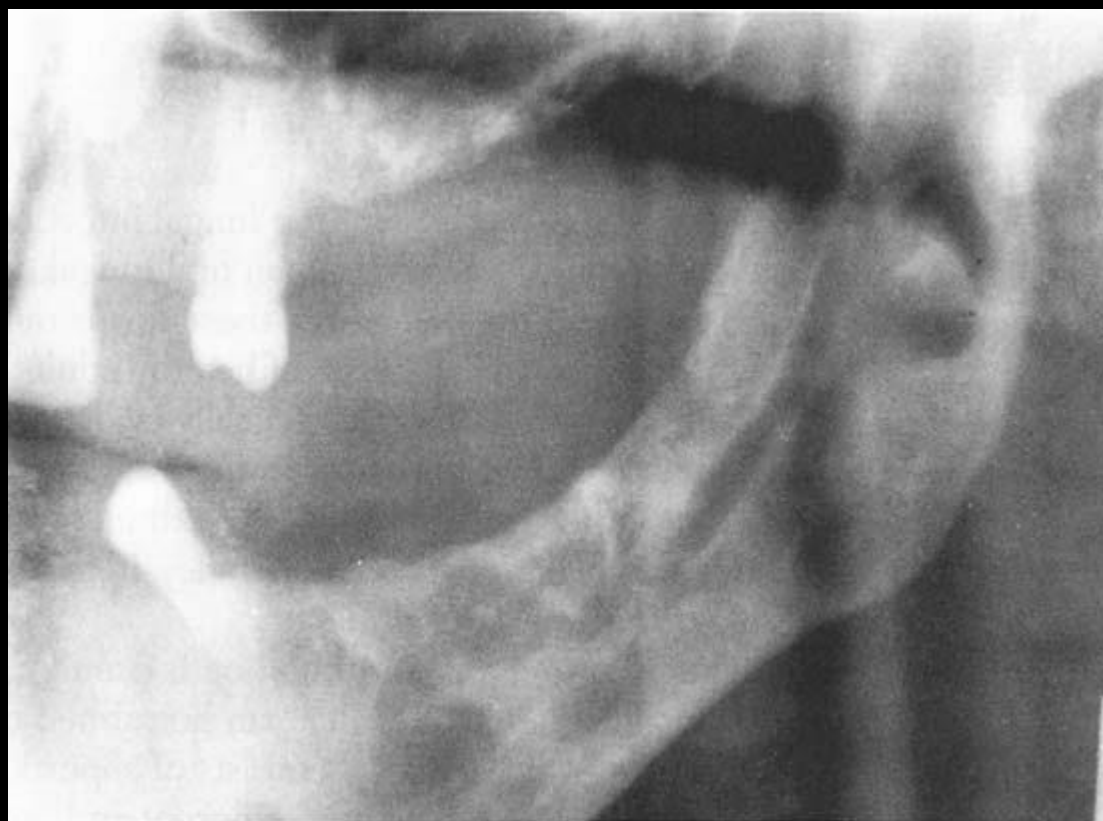




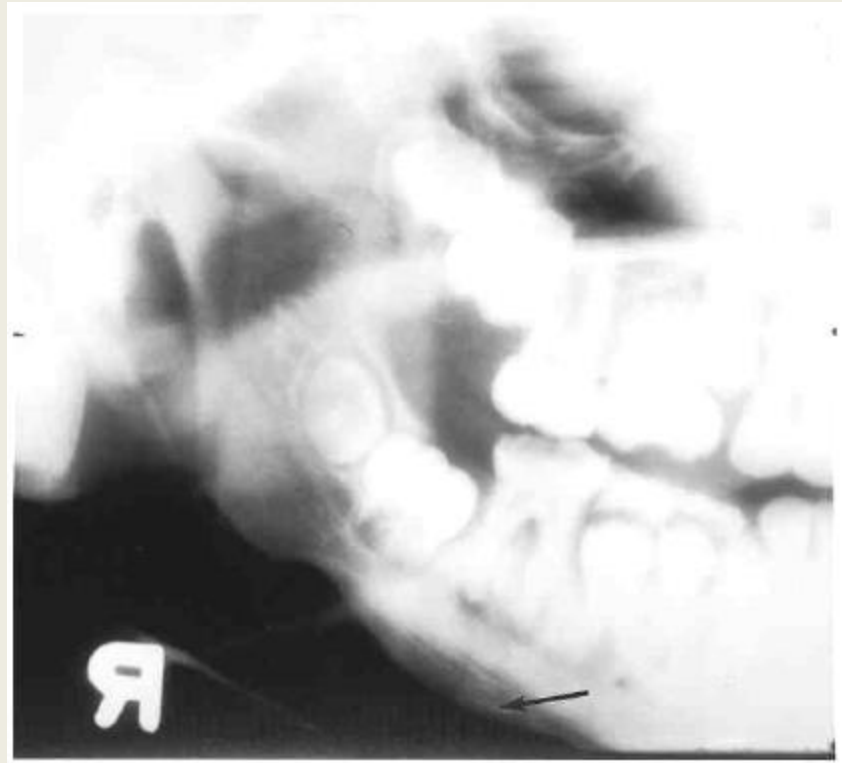Main radiographic features of chronic osteomyelitis

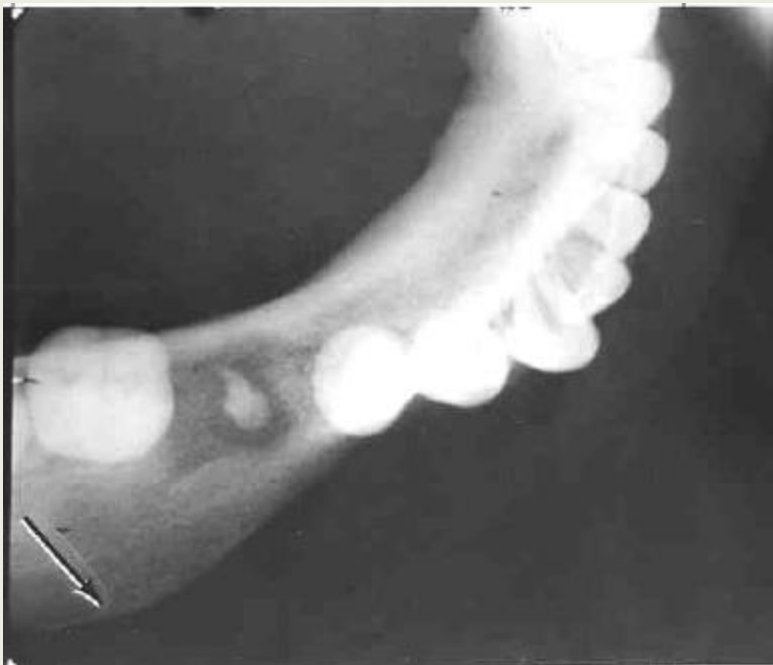
- Localized patchy or *moth-eaten areas of bone* destruction
- Sclerosis of the surrounding bone
- Evidence of small radiopaque sequestra of dead bone sometimes within the area of bone destruction
- Evidence of an involucrum surrounding the area of destruction following extensive subperiosteal bone formation

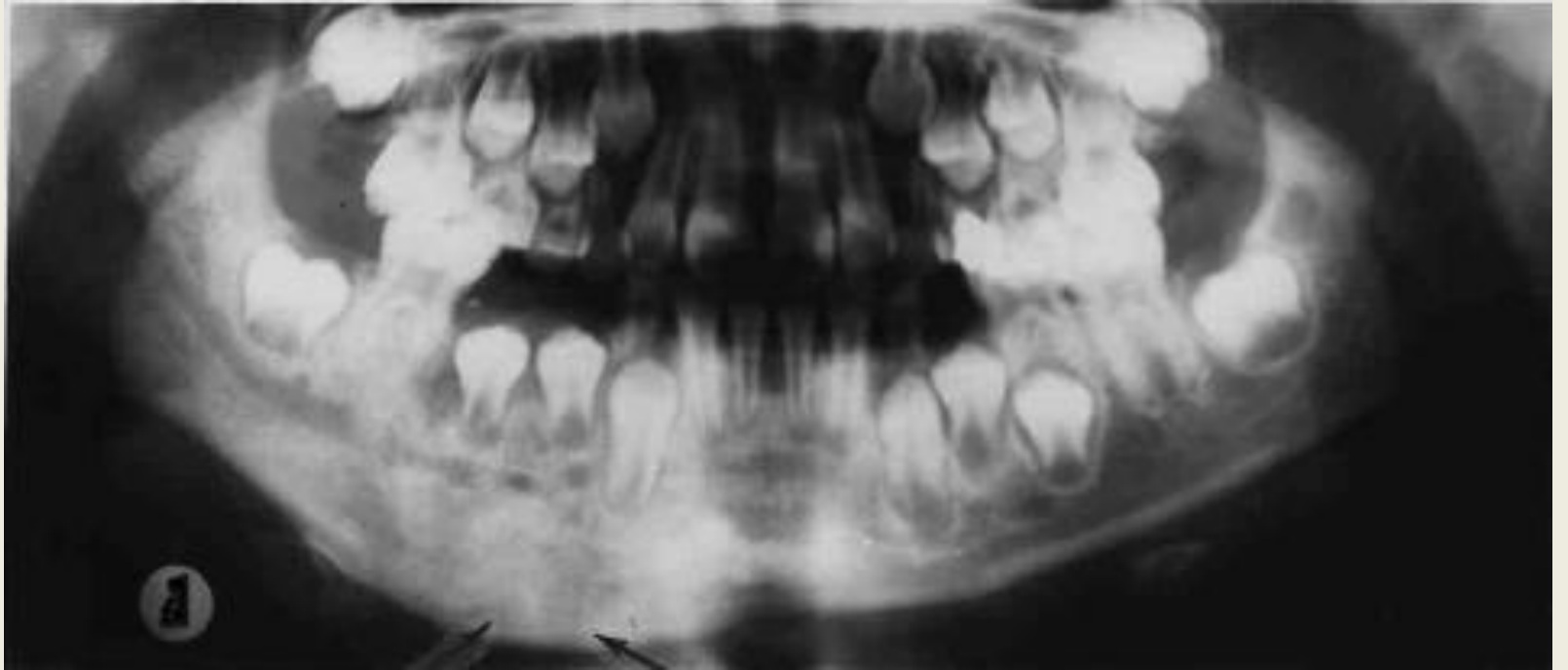


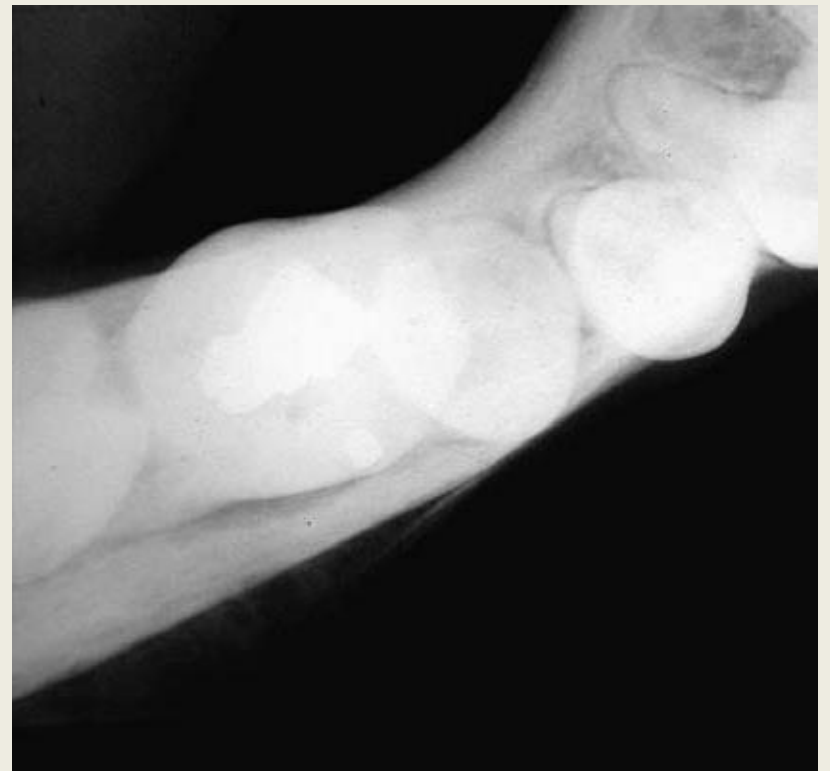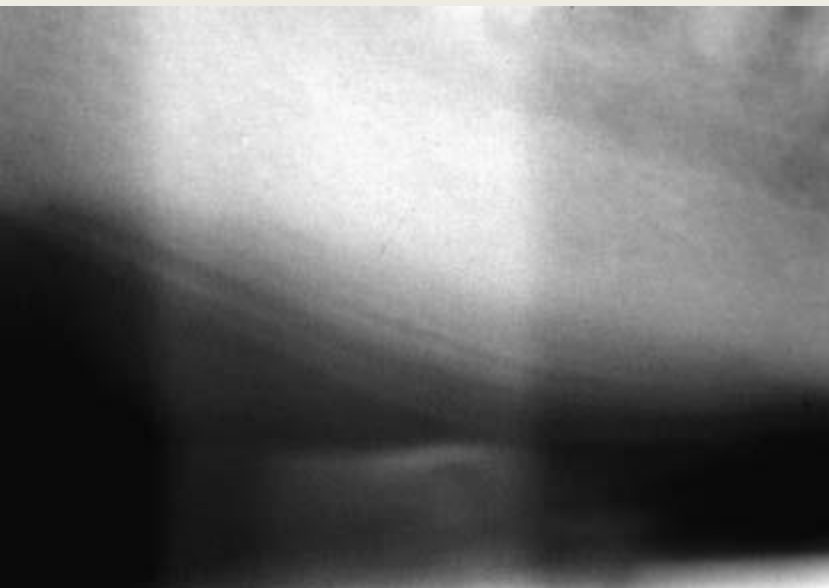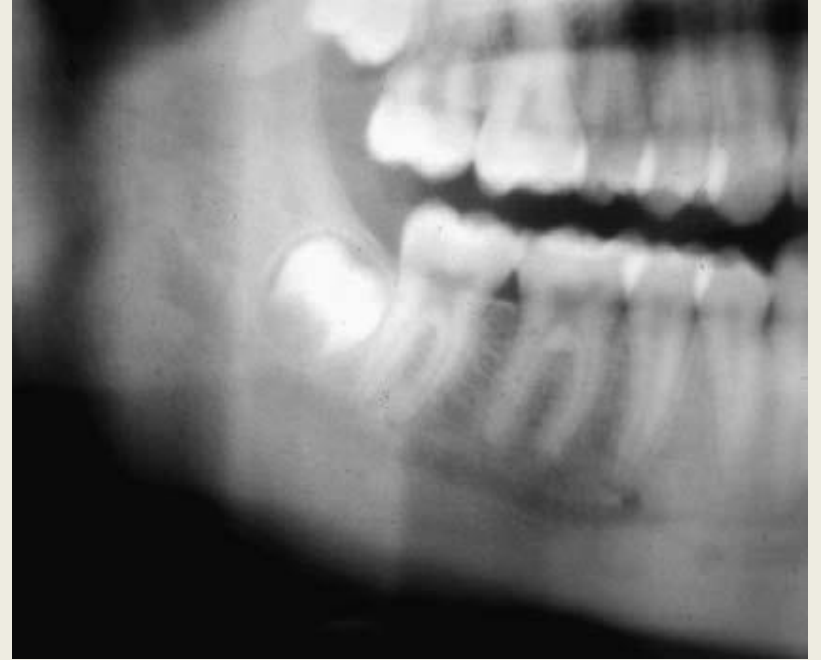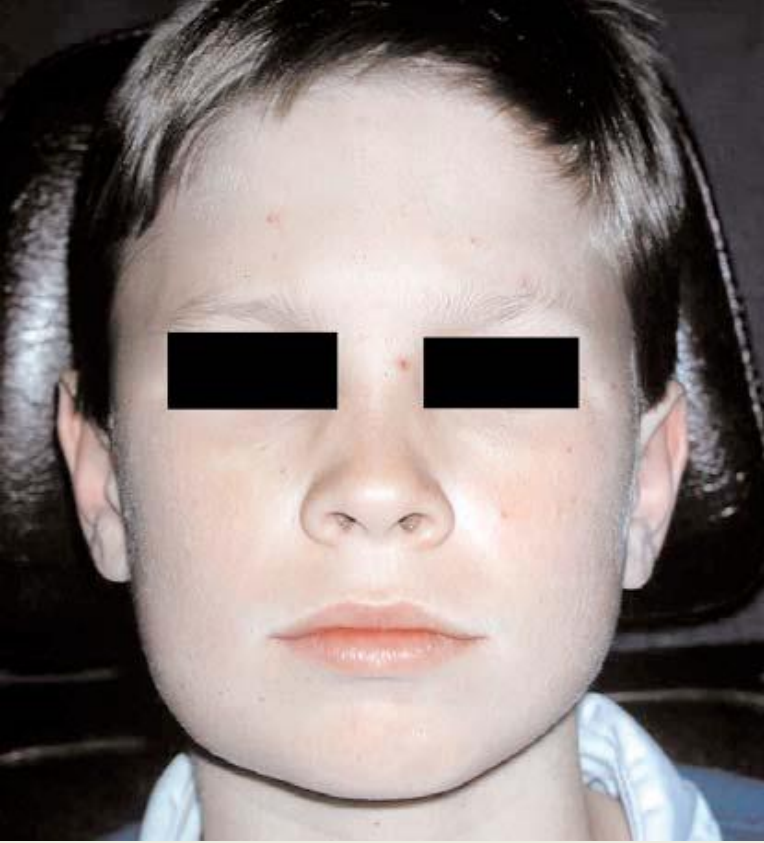Garre's osteomyelitis/ proliferative periostitis

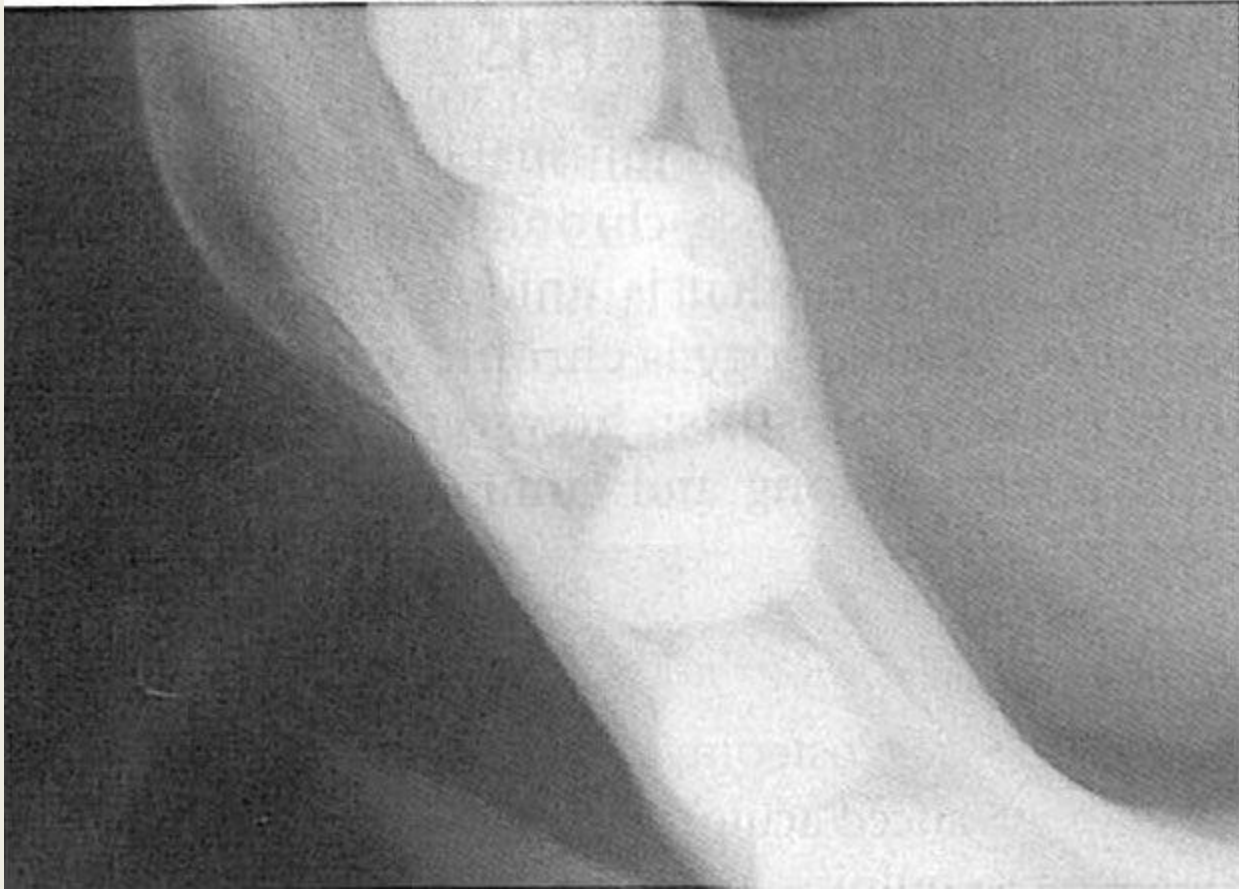- chronic osteomyelitis, nonsuppurative
- almost exclusively in children and young adults
- low-grade chronic infection,
- usually from the apex of a carious mandibular first molar
- infection spreads towards the surface of the bone
- inflammation of the periosteum
- new bone underneath the periosteum
- occlusal view, "onion-skin" appearance.

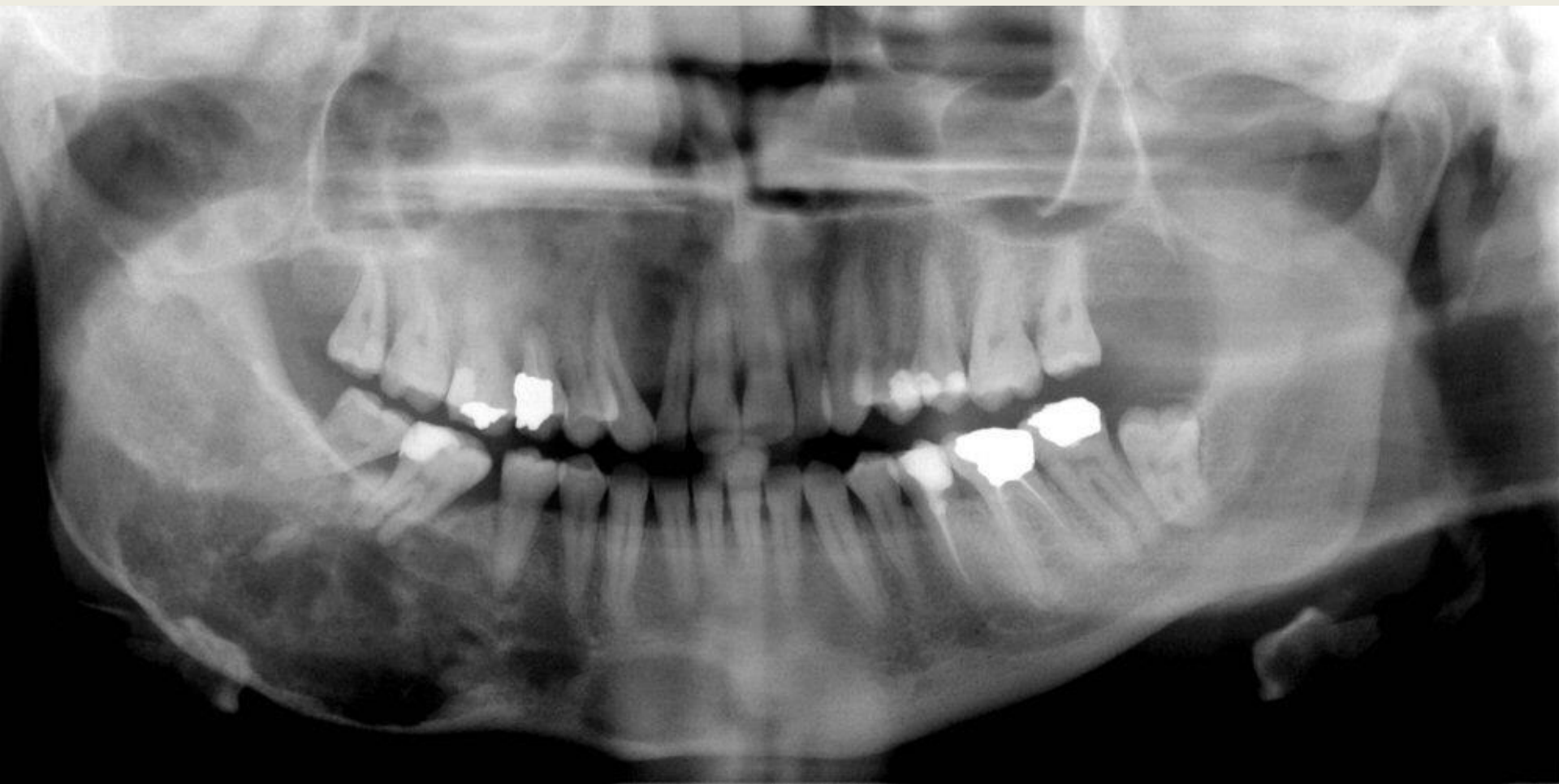


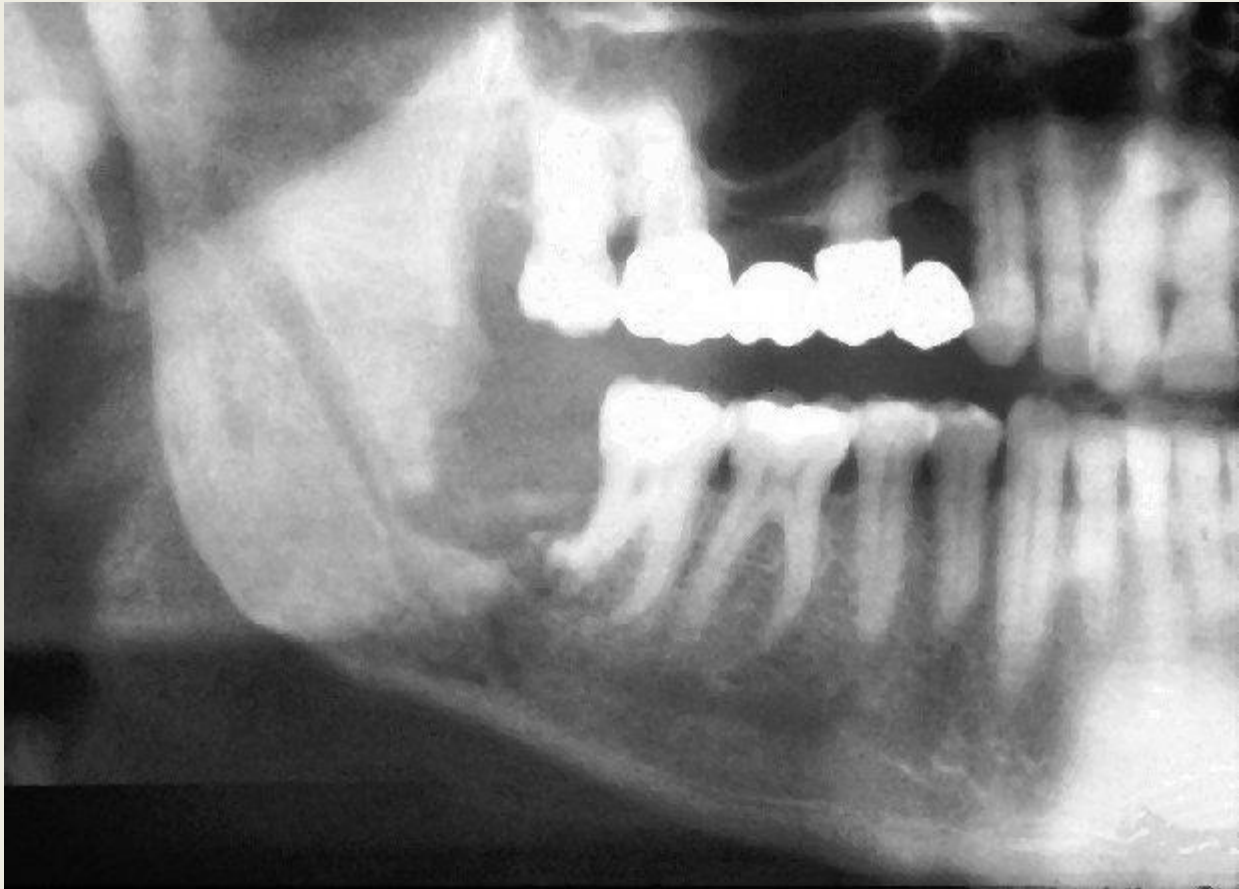






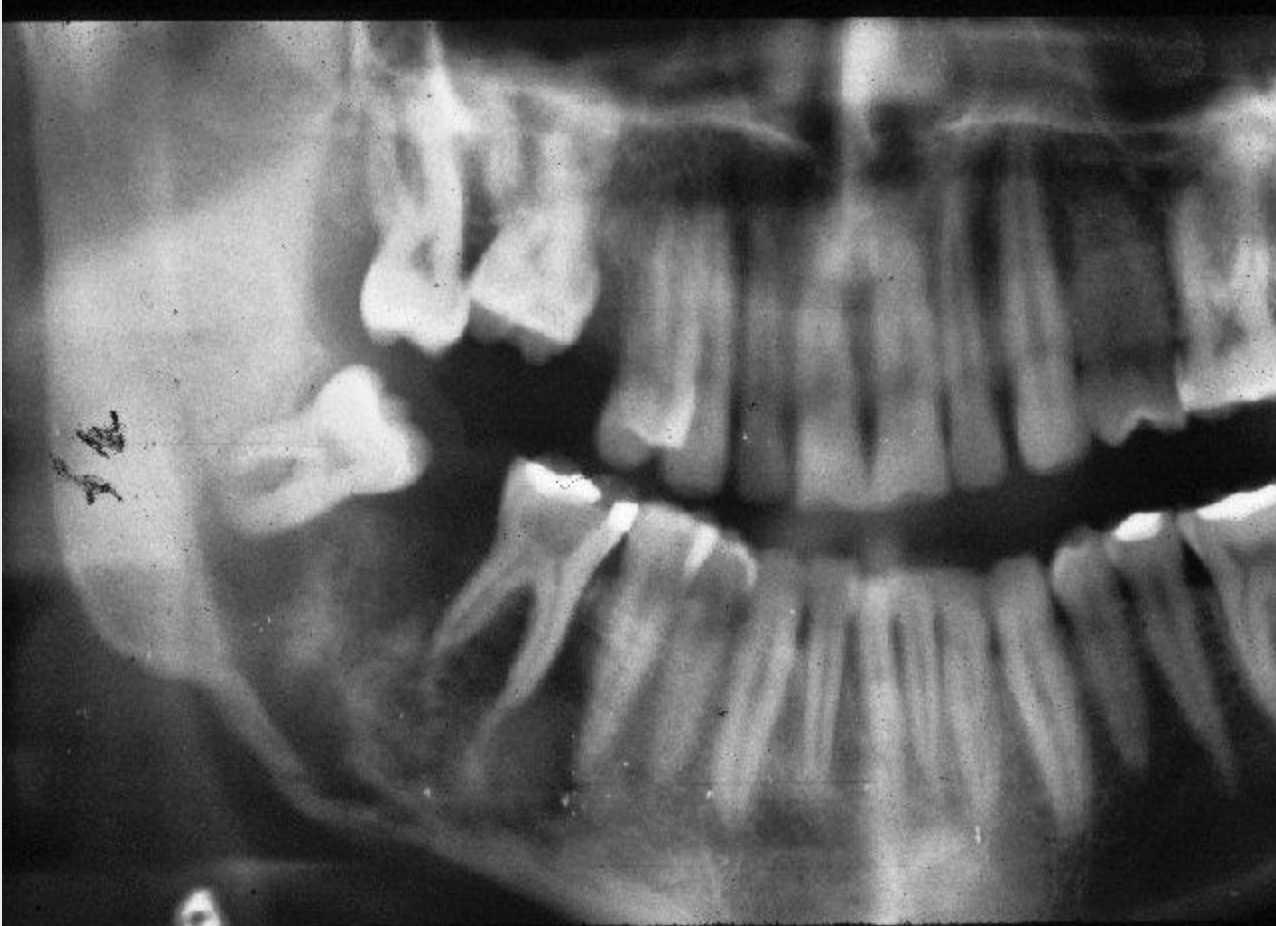



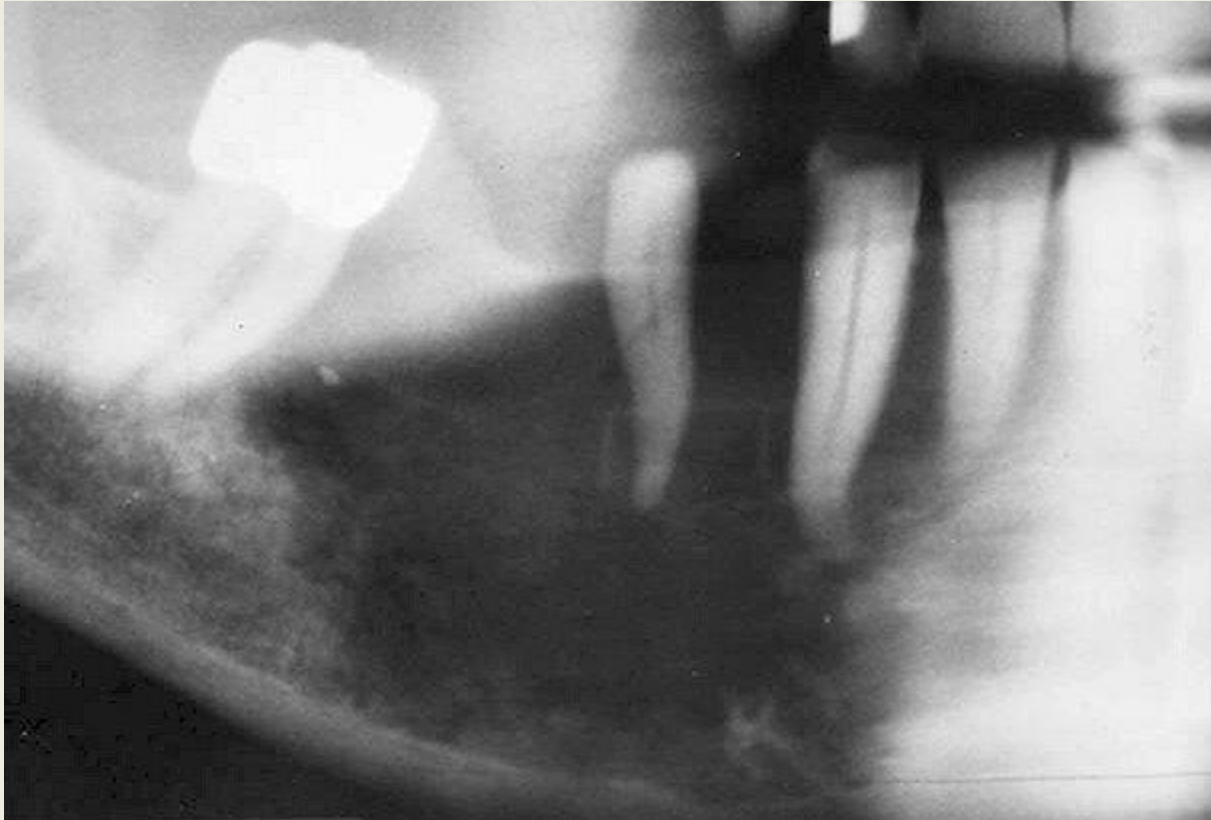
Differential Diagnosis

Osteogenic sarcoma



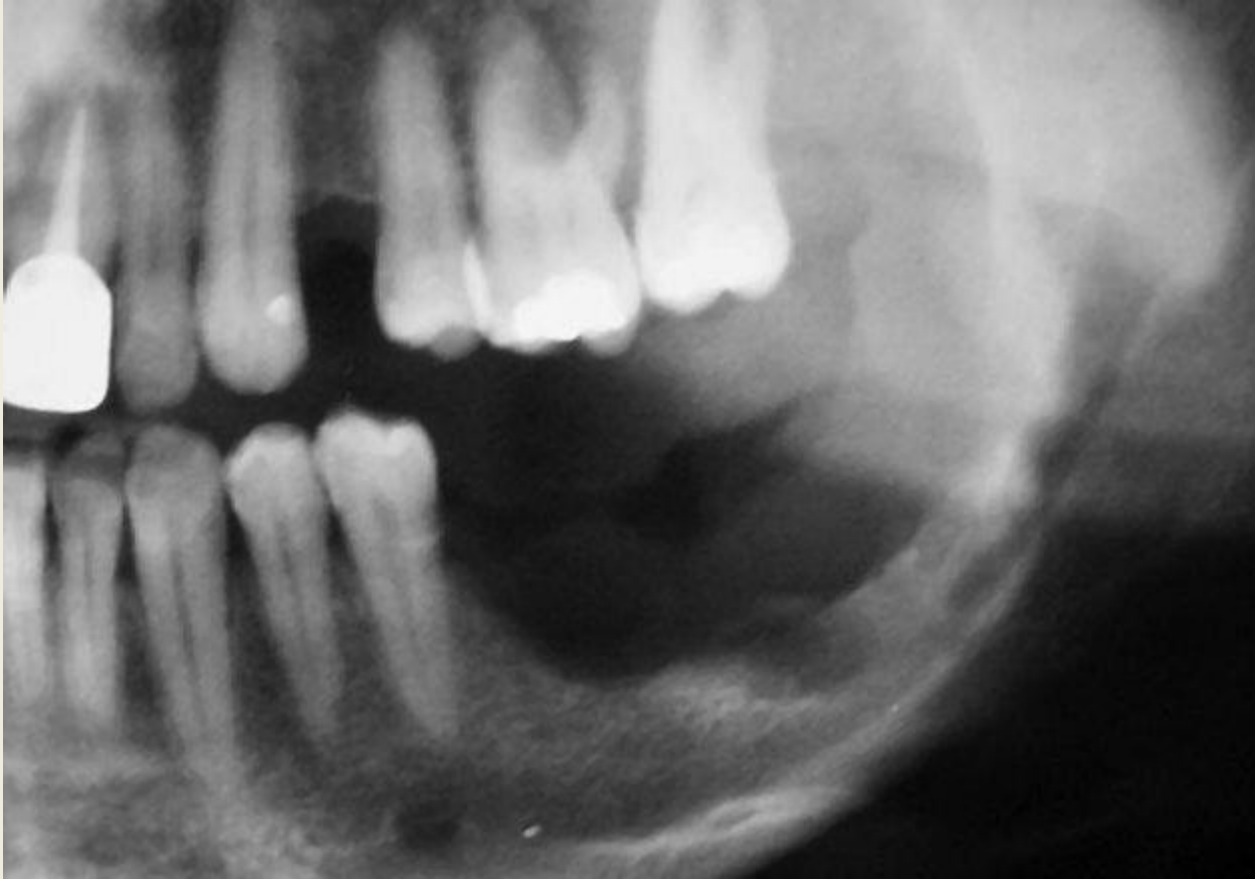
Osteogenic sarcoma

Metastatic carcinoma



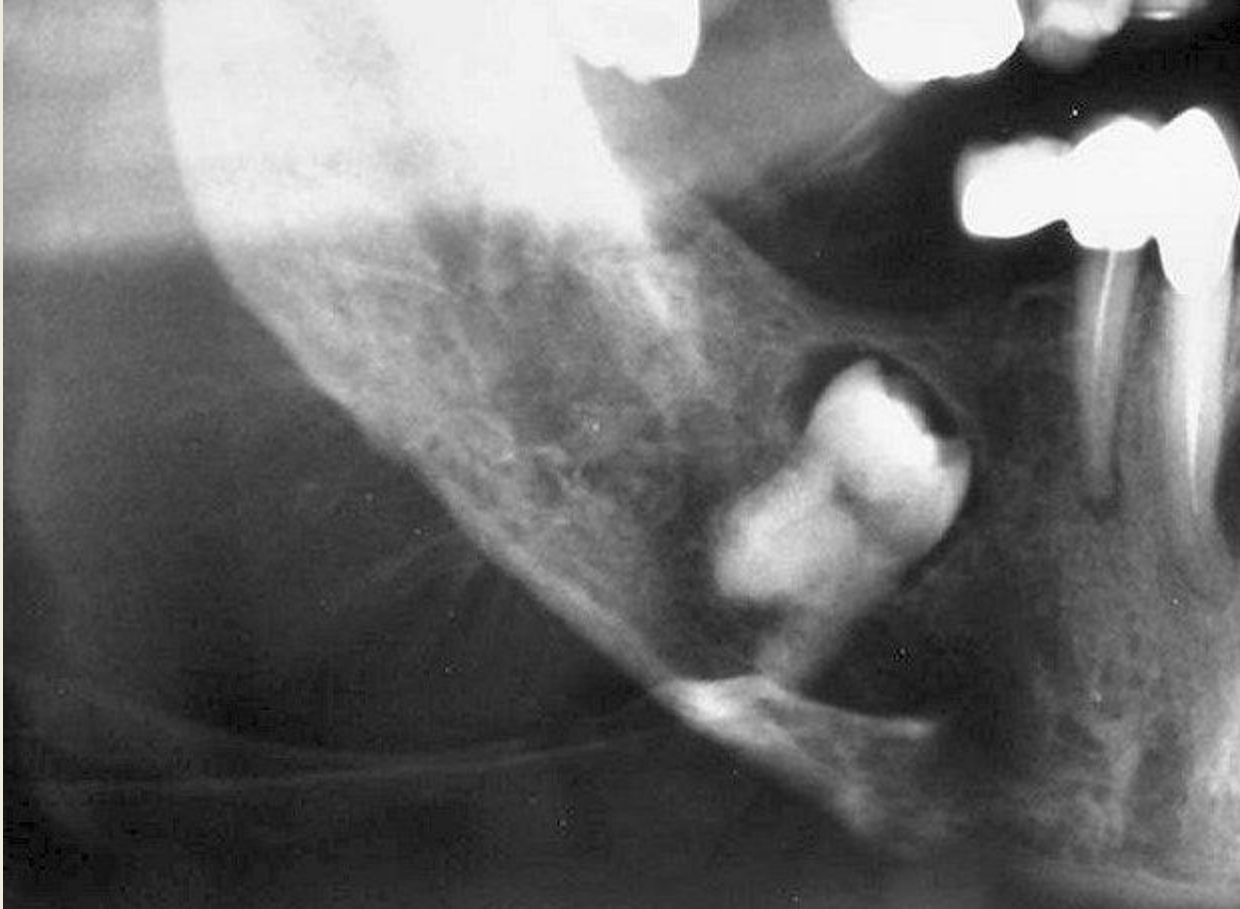Metastatic lesion

Squamous cell carcinoma



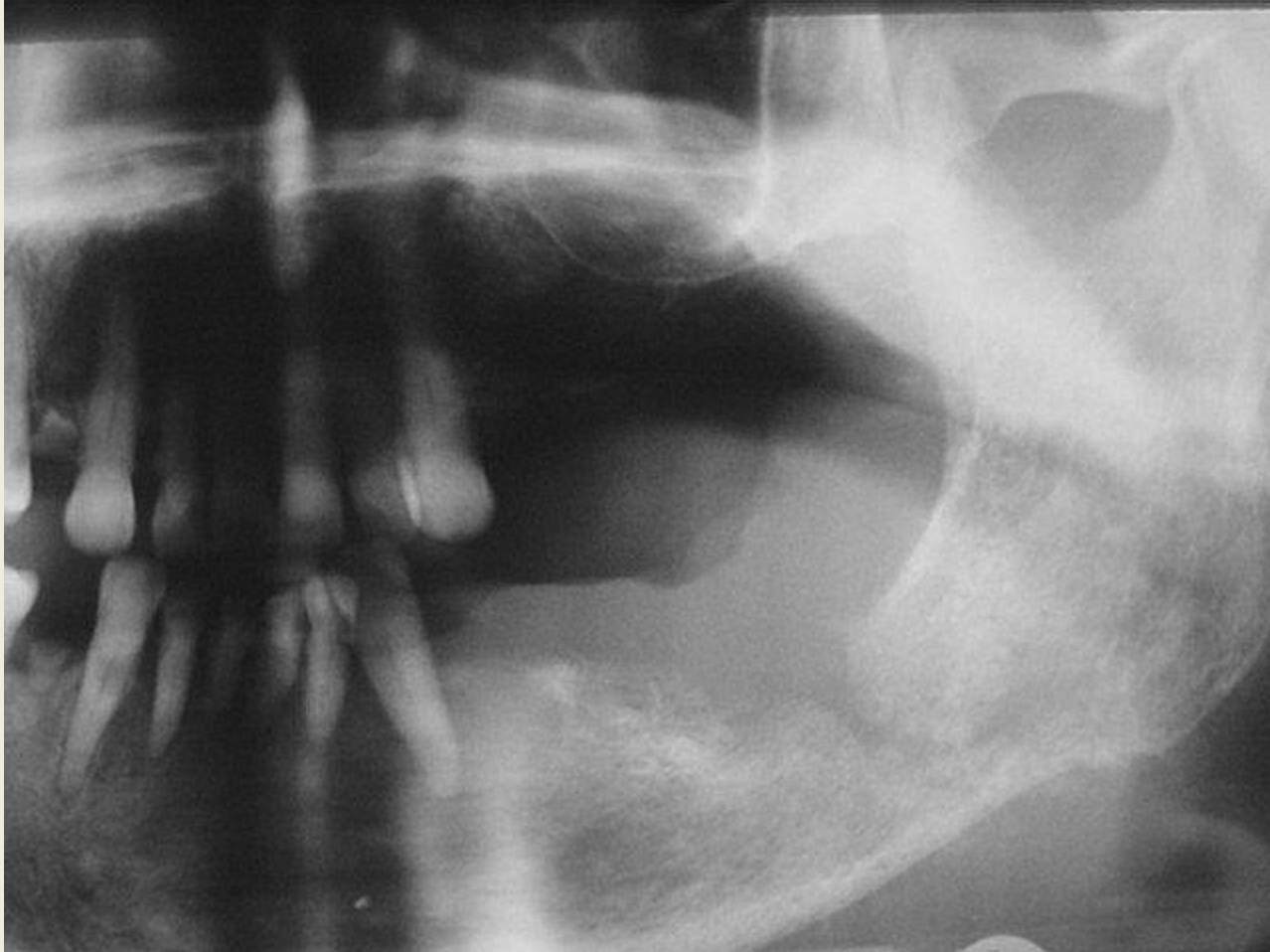
Squamous cell Ca

Osteogenic sarcoma



Primary malignant tumor of bone

Malignant lymphoma



Malignant lymphoma