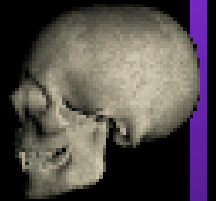
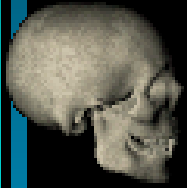
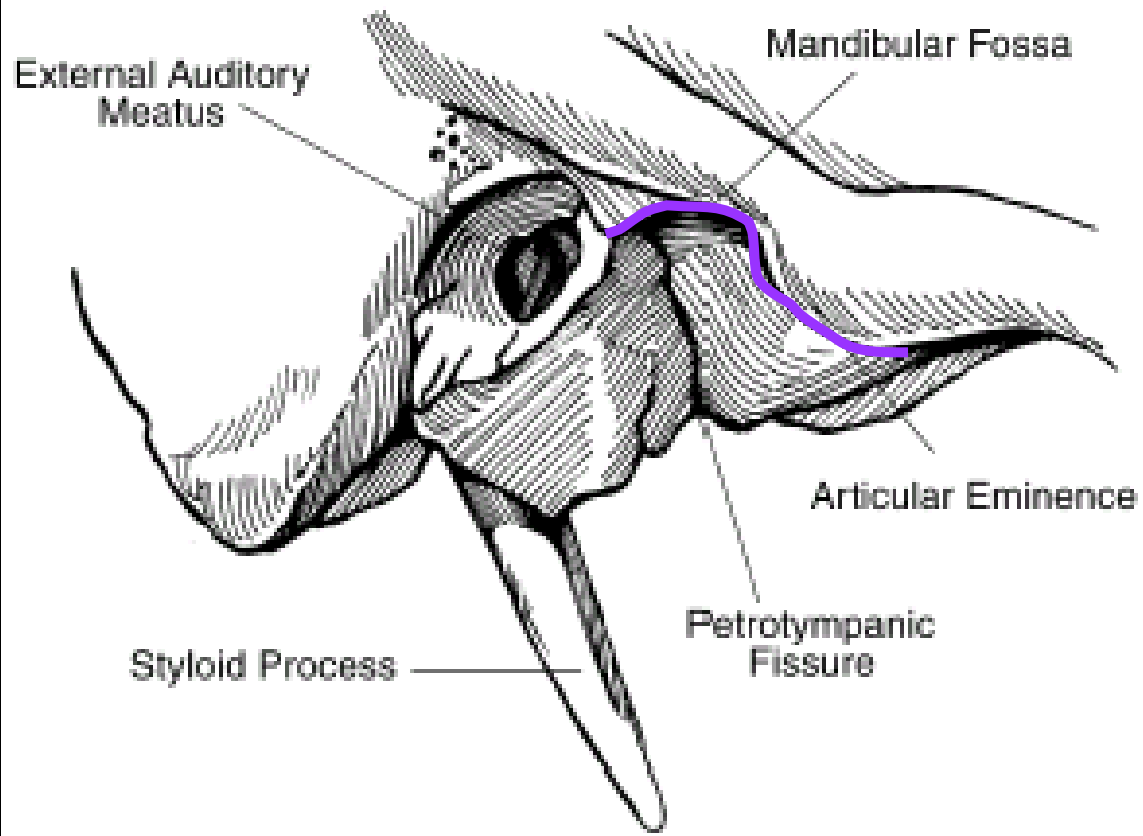
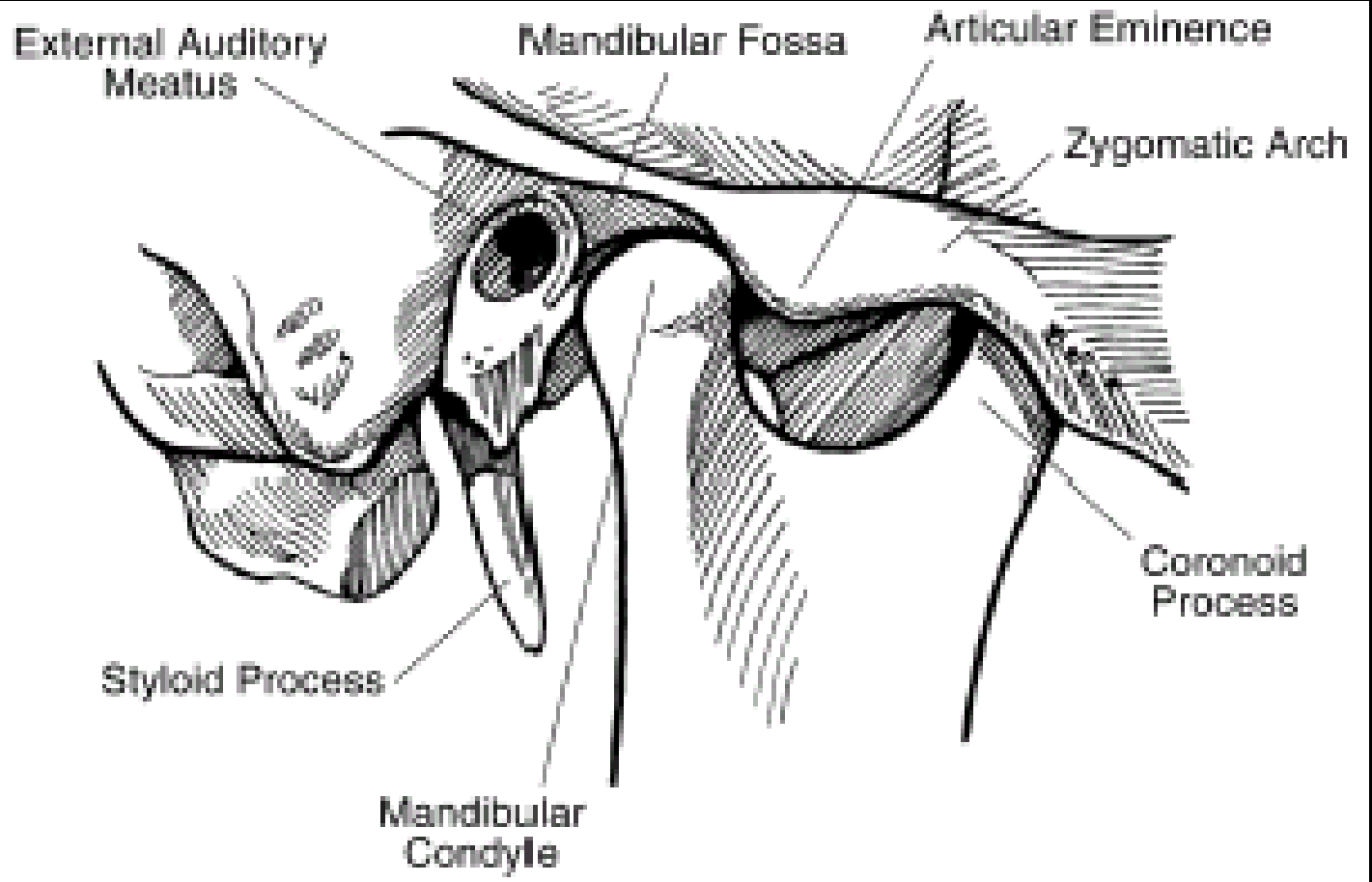
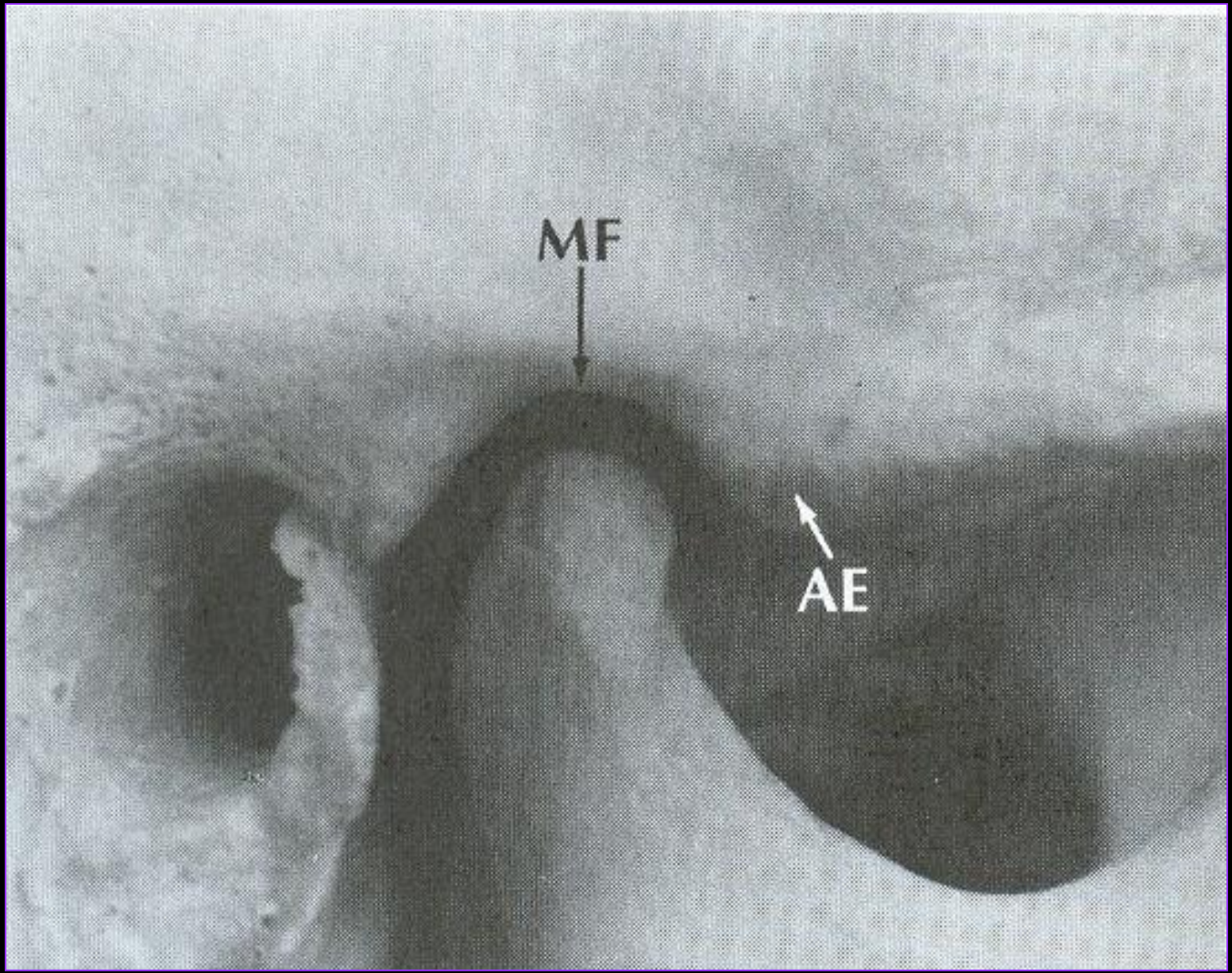


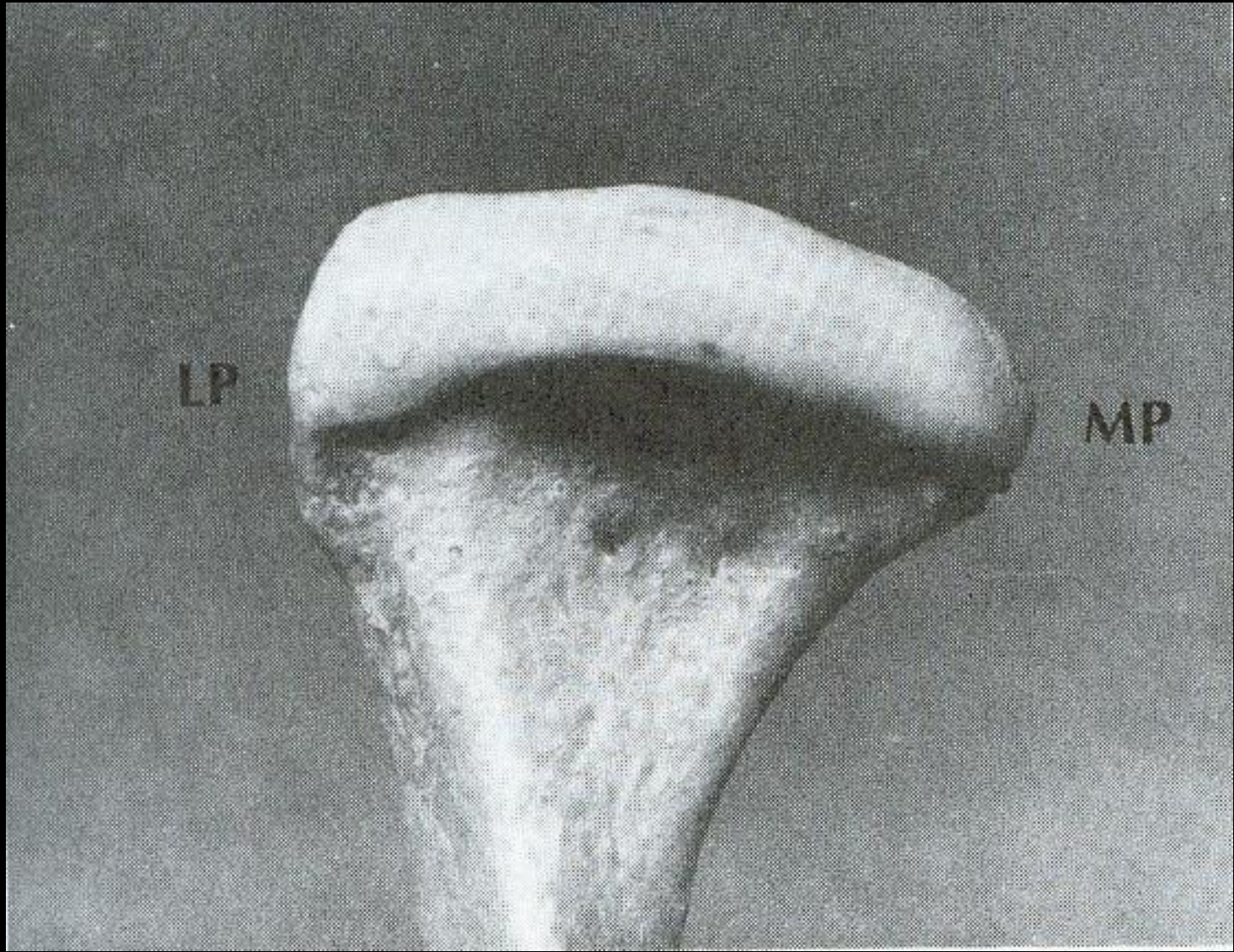
**TEMPORO  
MANDIBULAR  
JOINT  
DISORDERS**

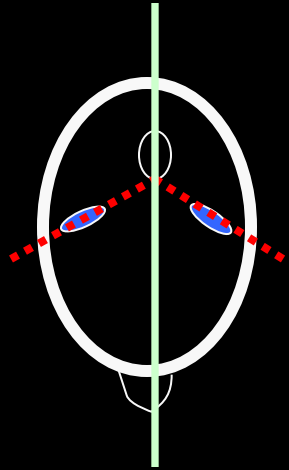
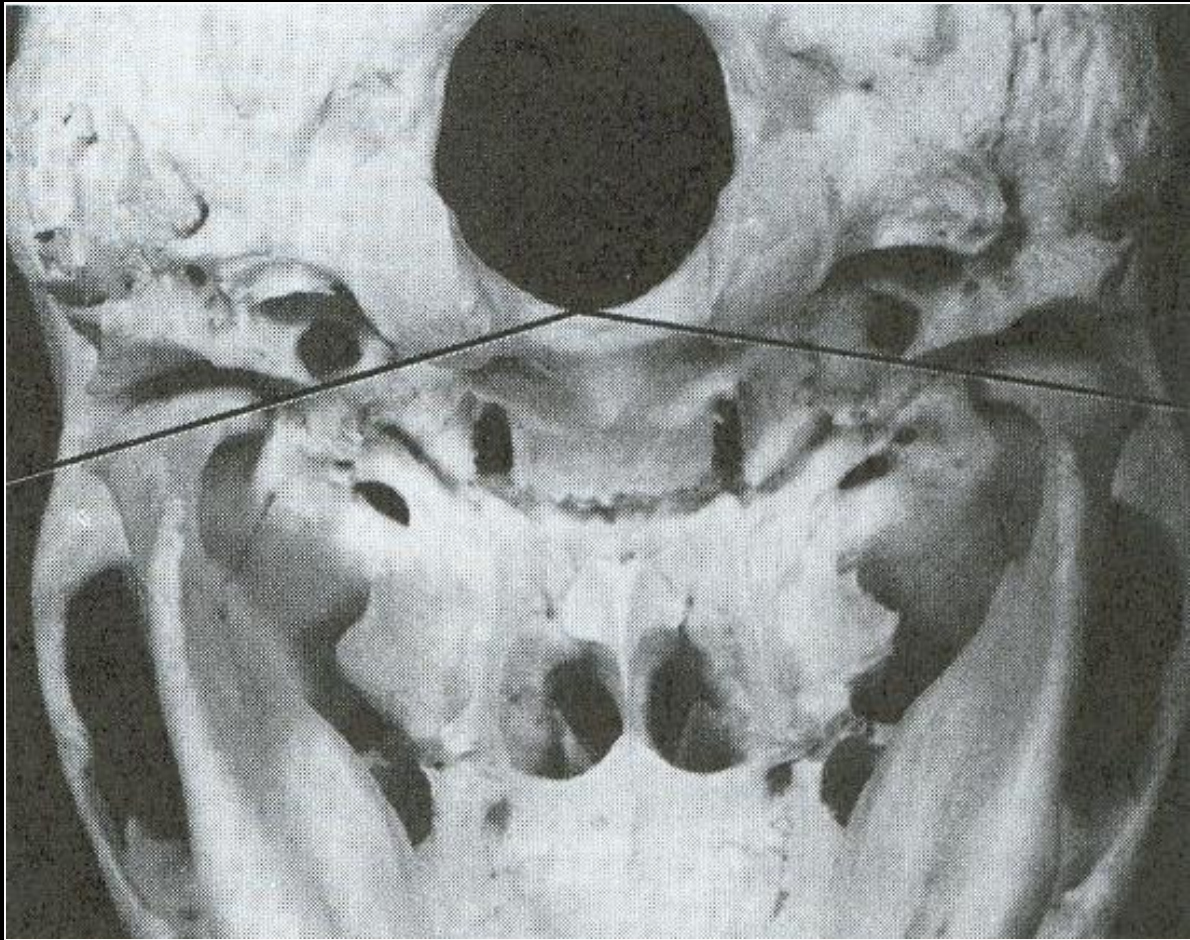


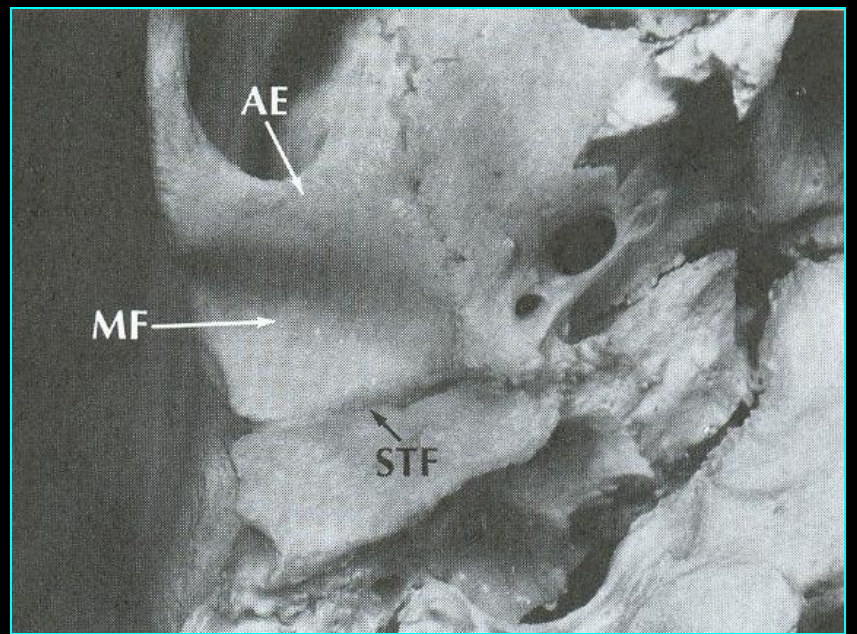
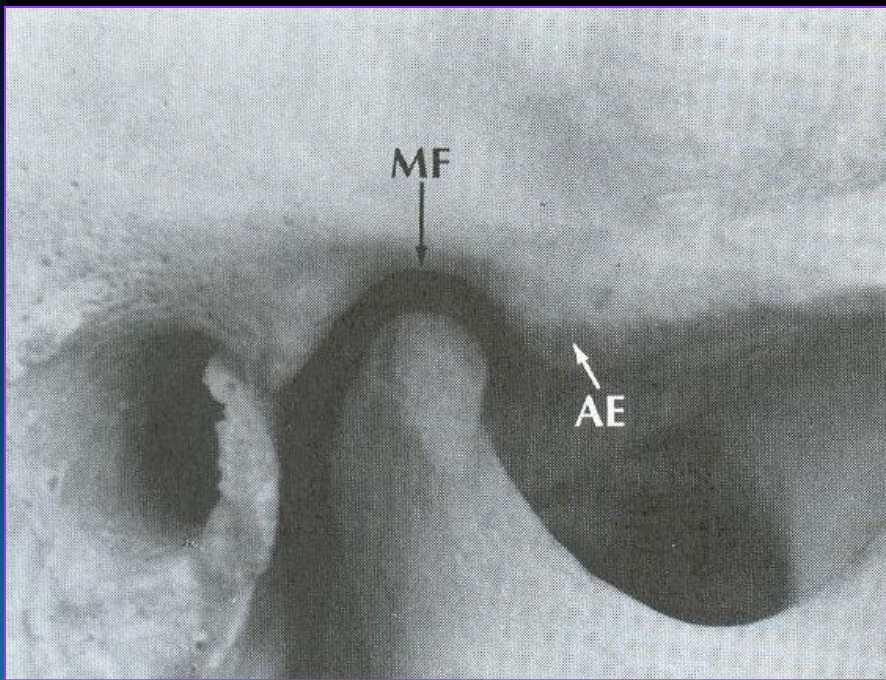


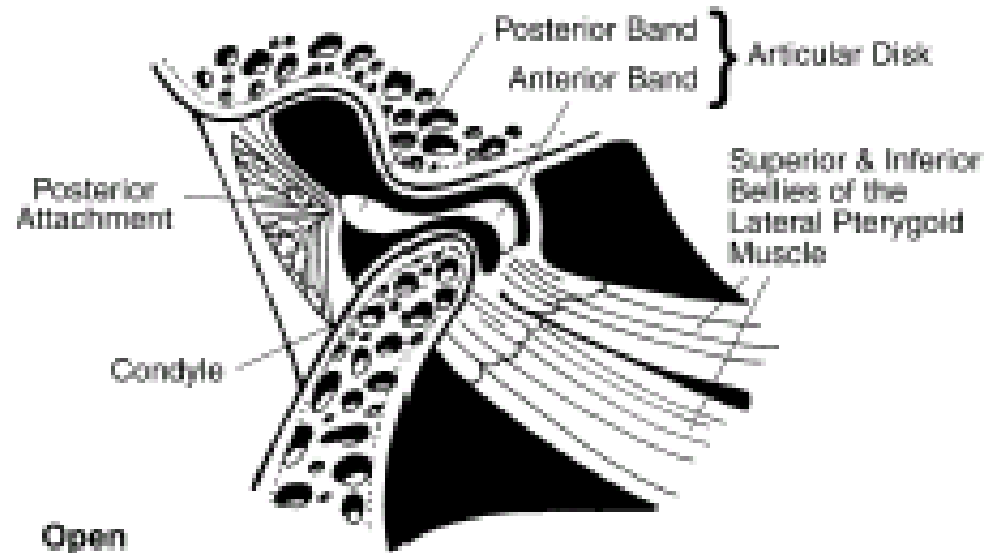
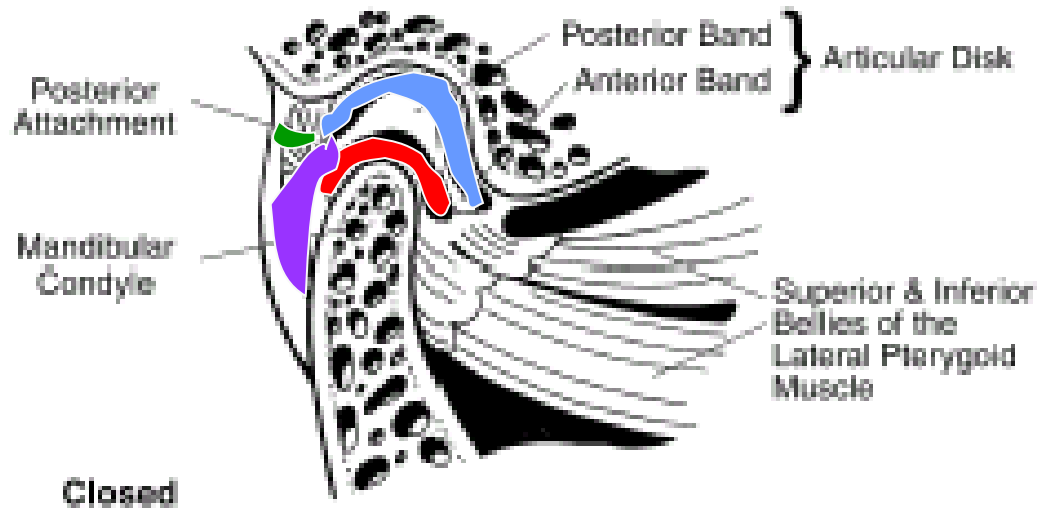


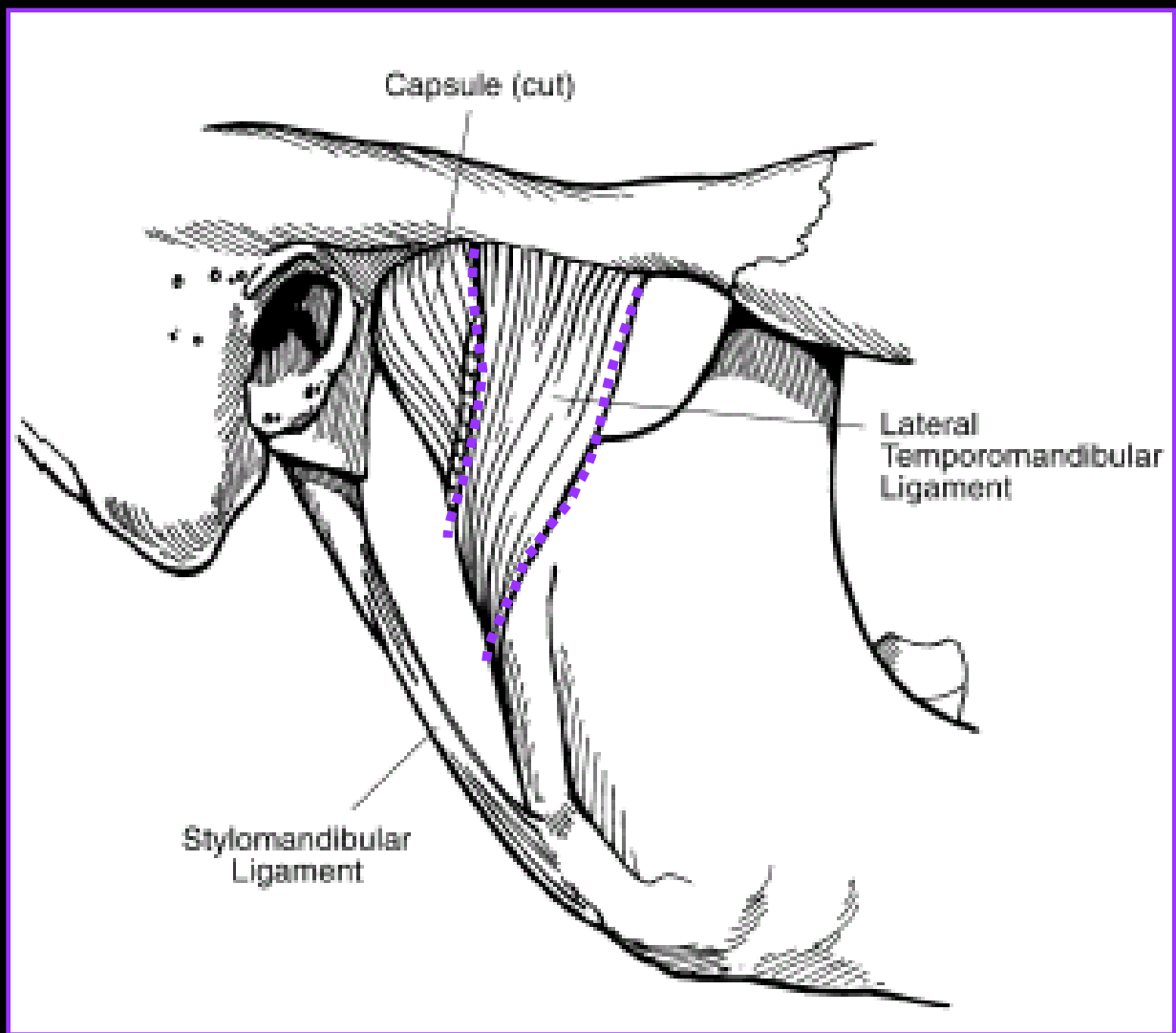






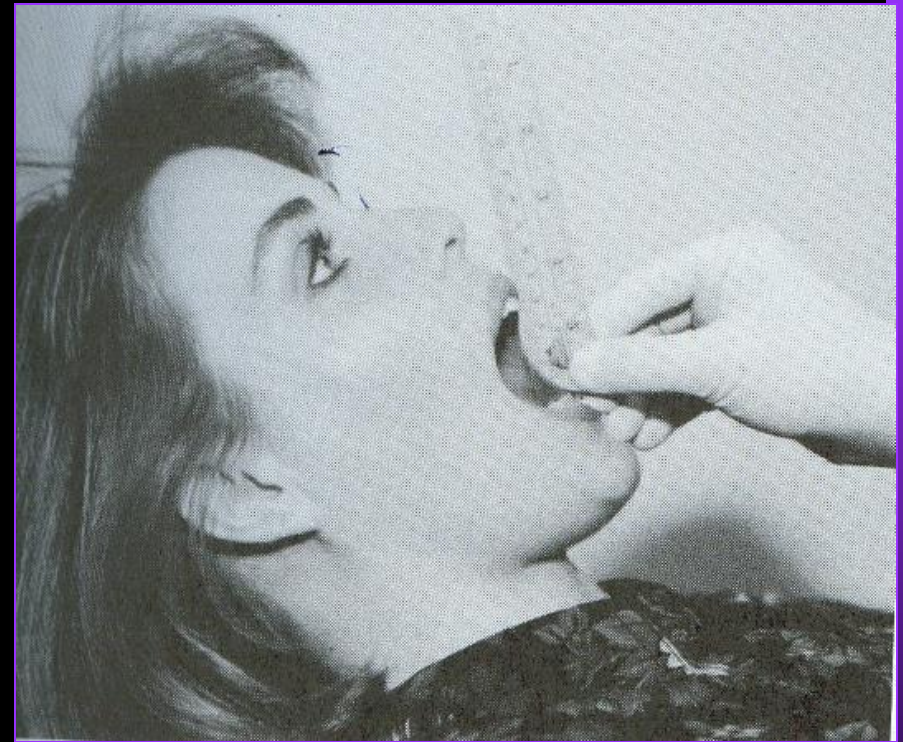
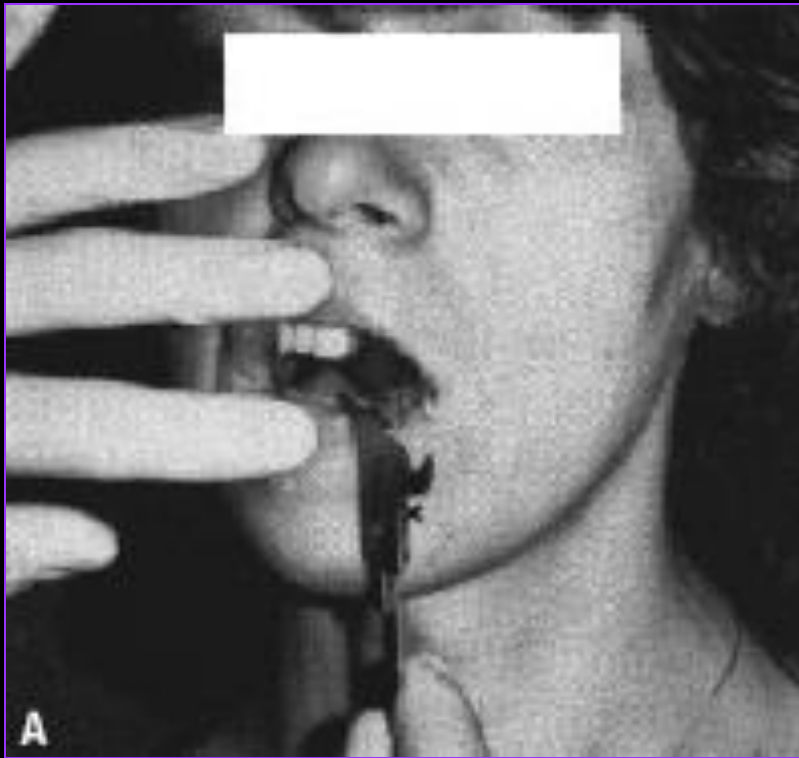




# TMJ Examination

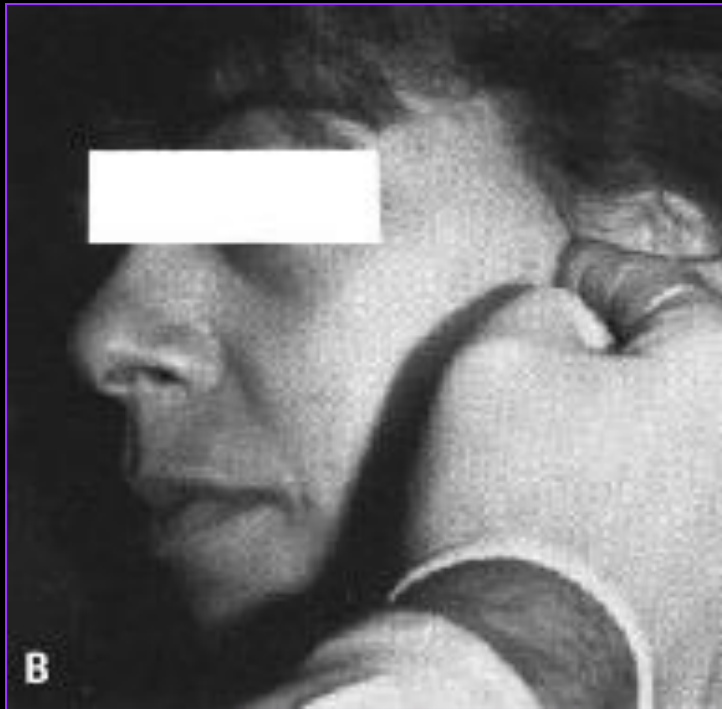## I. Assessment of range of motion



Normal interincisal -  $\geq 40$  m.m

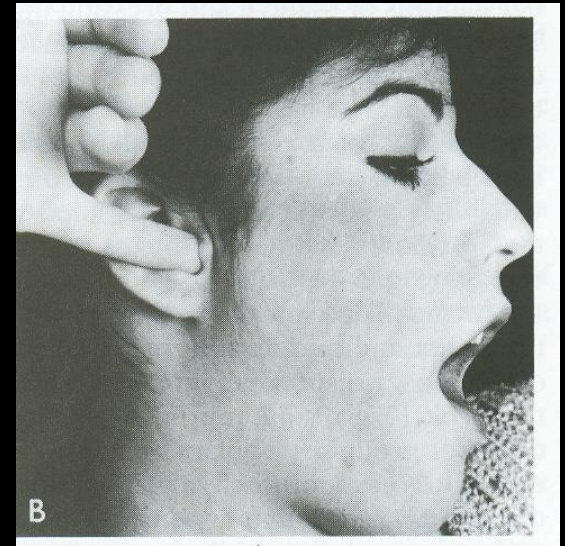
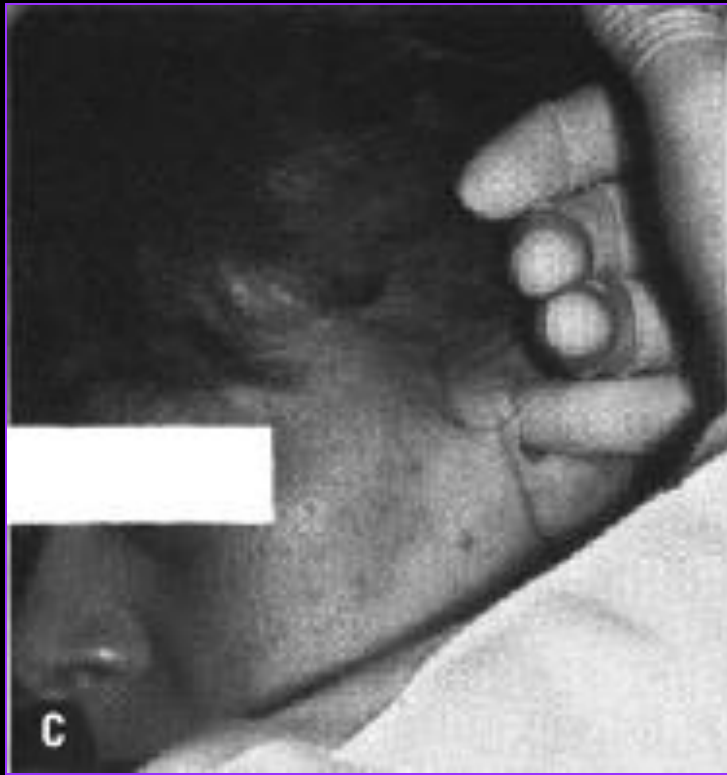
Normal protrusive, lateral  $\geq 7$  m.m

## Palpation of joint - Preauricular



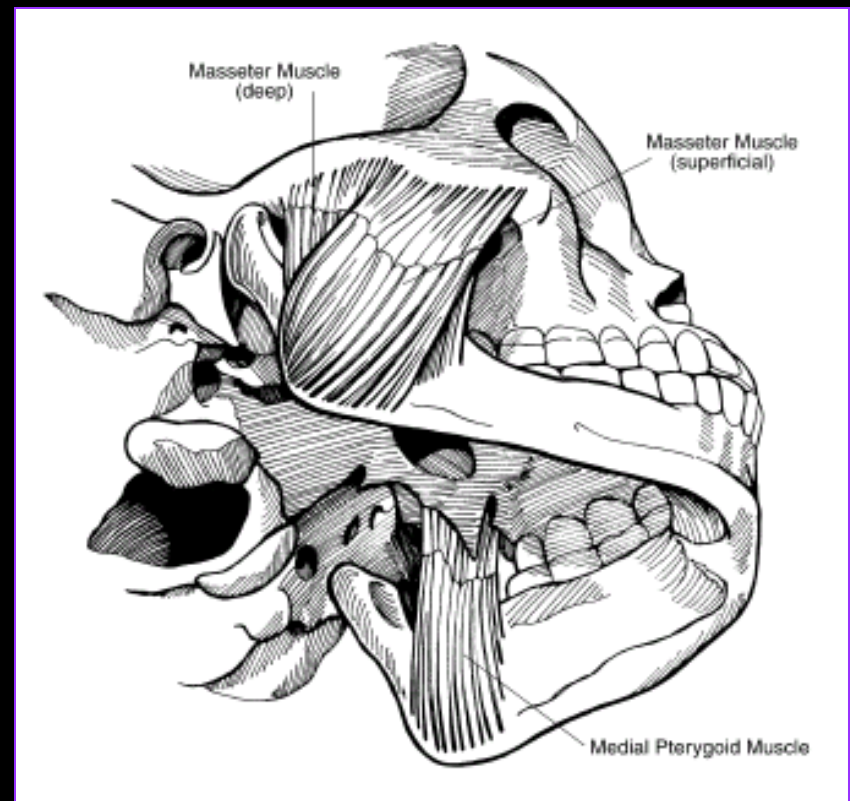
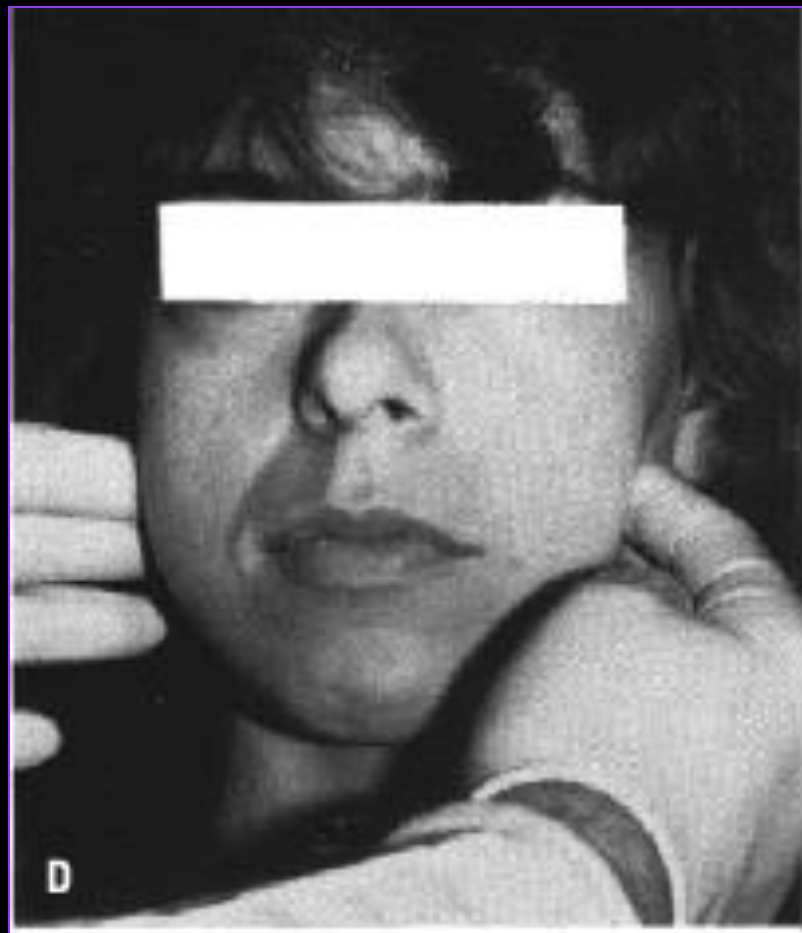
- Pain in lateral pole just ant & post.
- Difference in form – L v/s R
- Joint noises- clicking and crepitus
- Condyle not translating – not palpable during opening and closing

## Palpation of joint – Intra auricular

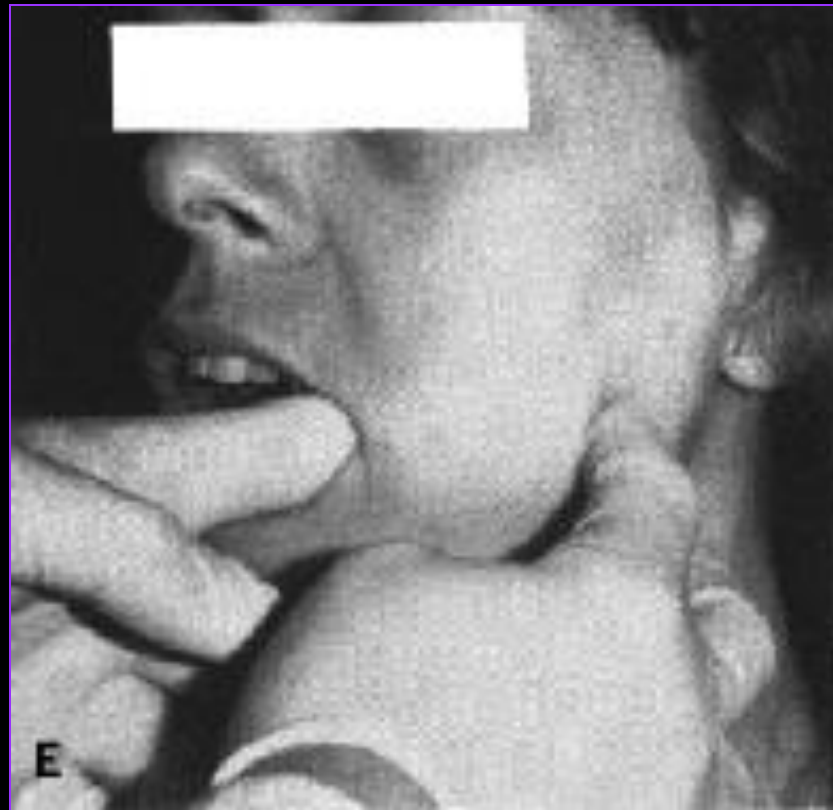

- Posterior aspect of TMJ
- Translation

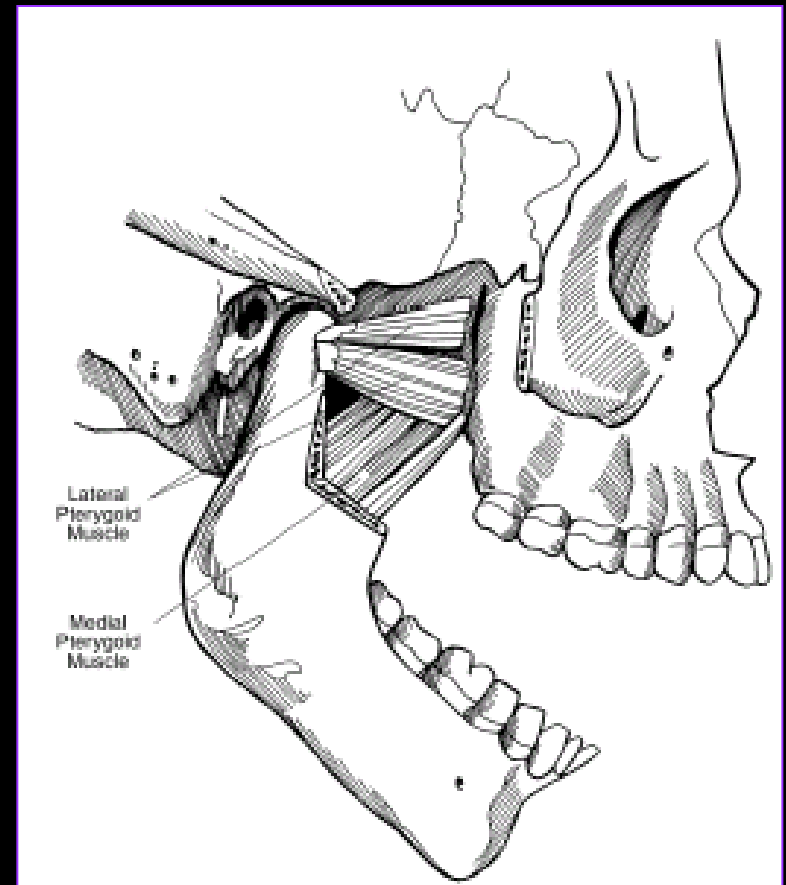
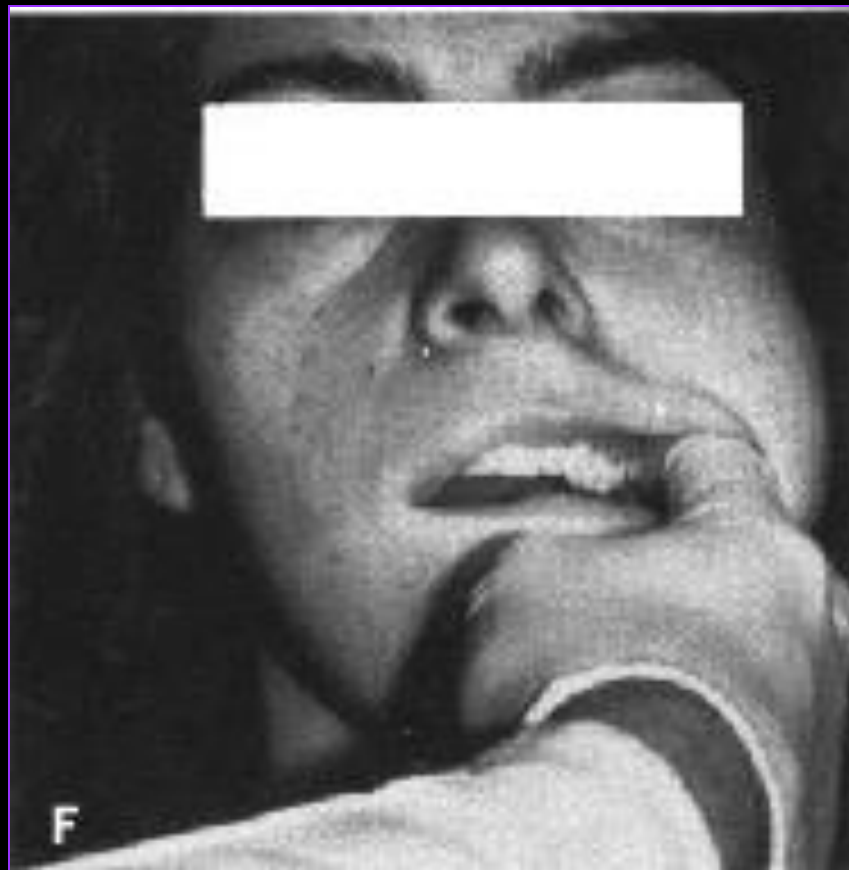# Palpation - Masseter



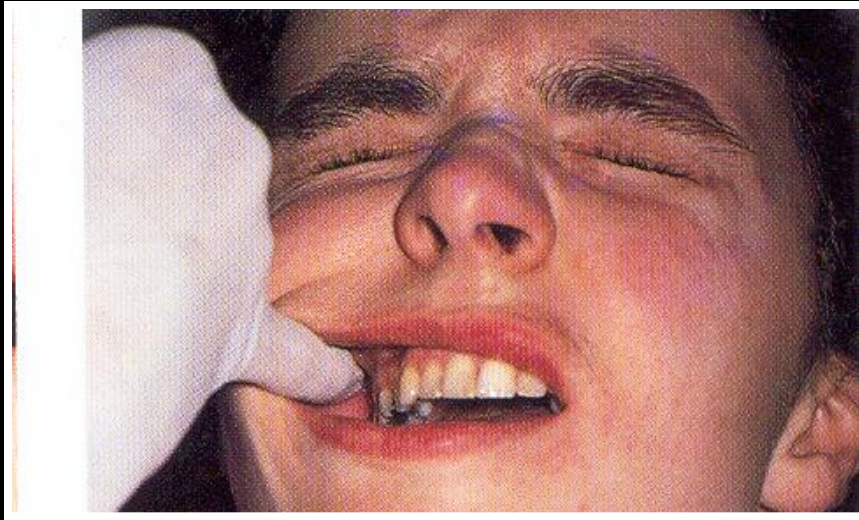
## Bimanual palpation - Masseter



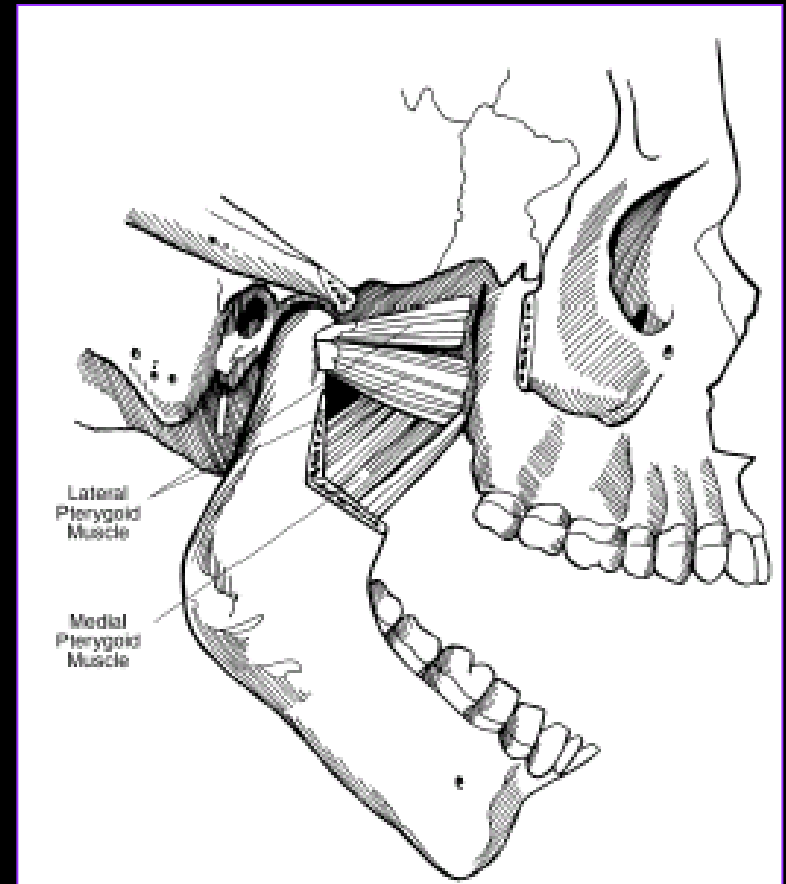
## Palpation – Lateral pterygoid



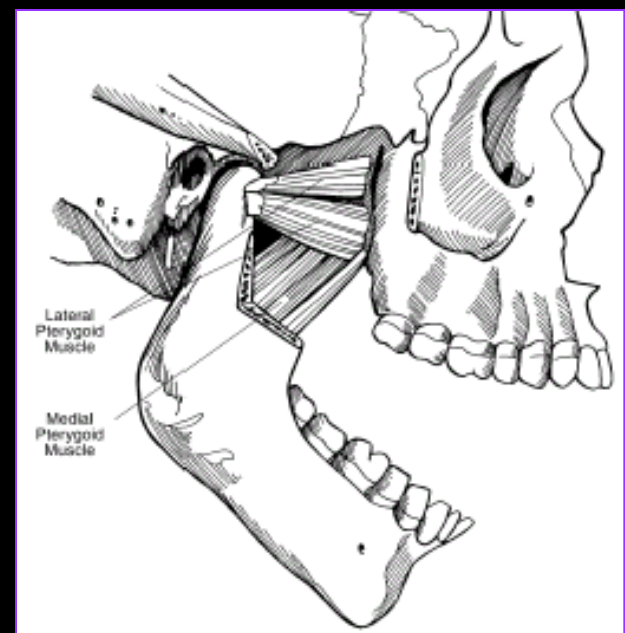
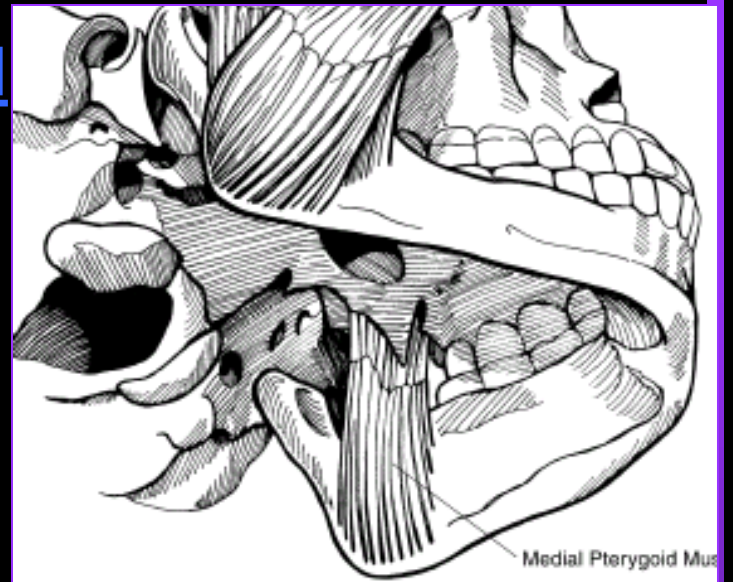
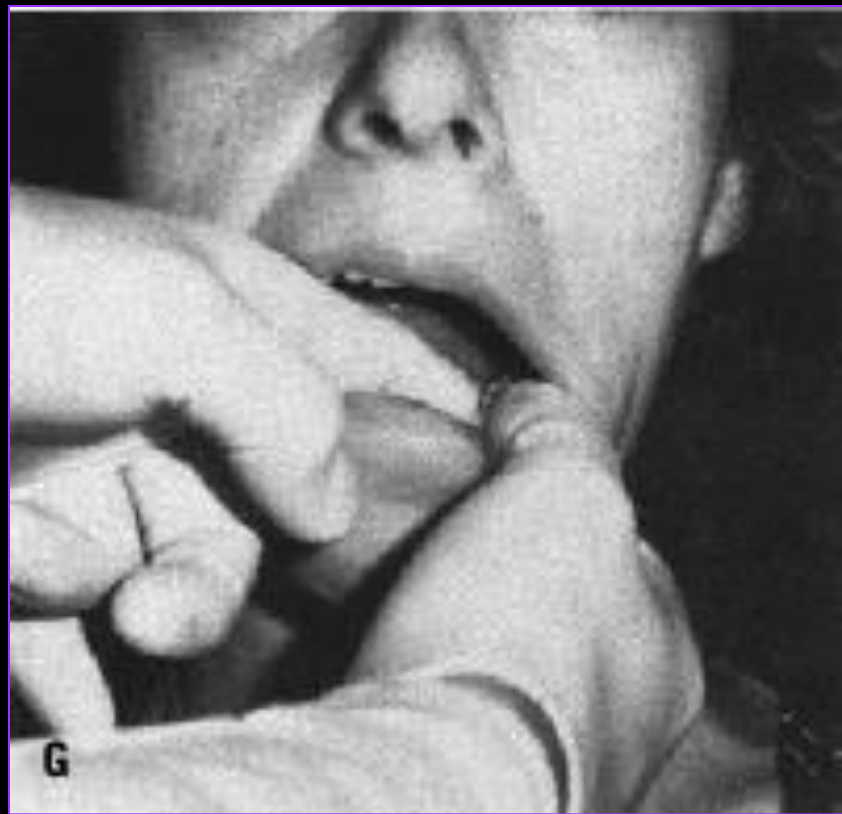## Palpation – Lateral pterygoid



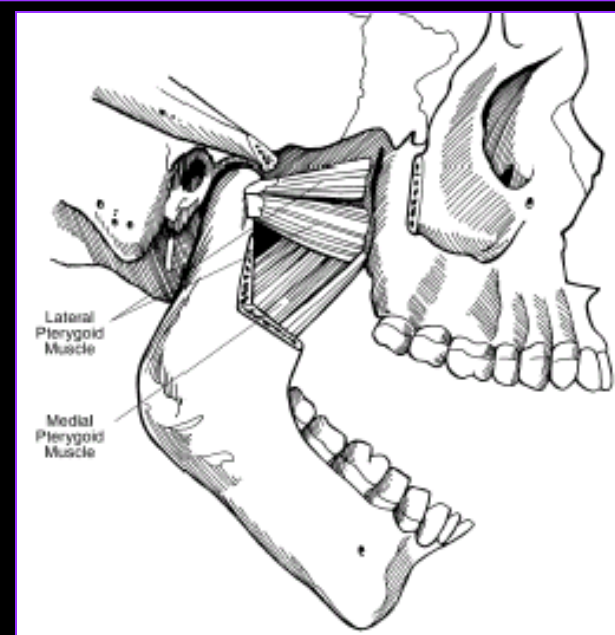
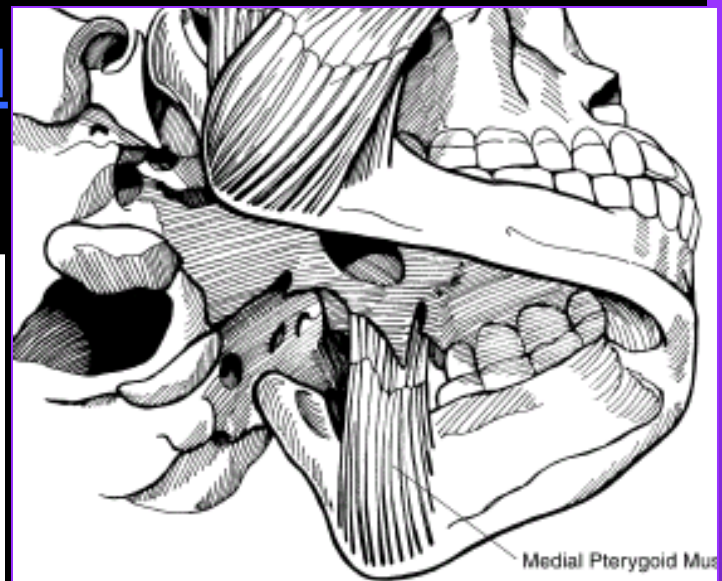
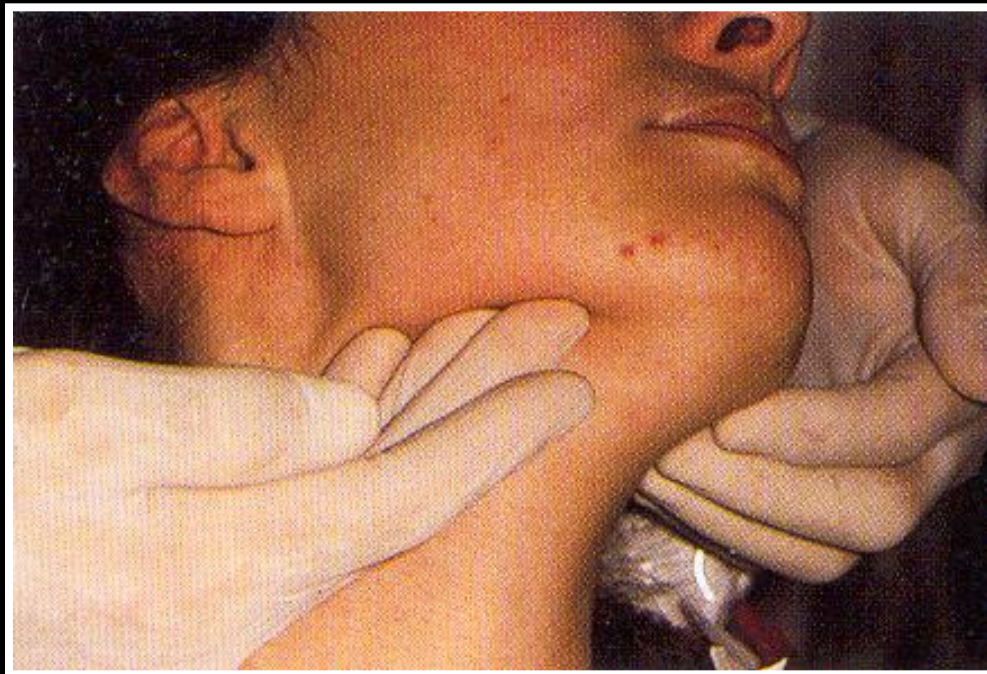
**Response when  
tender**



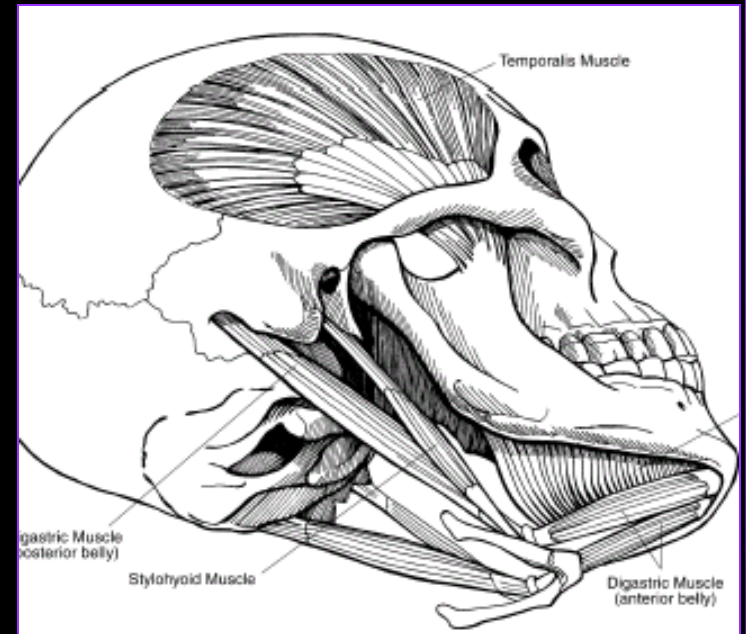
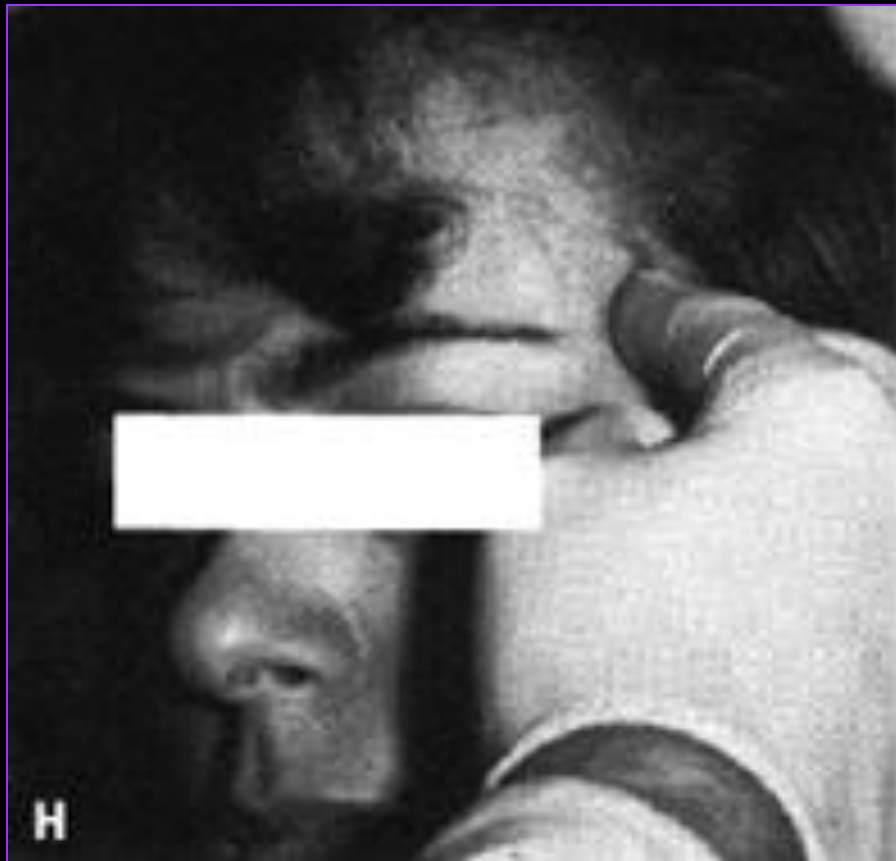# Palpating – Medial pterygoid



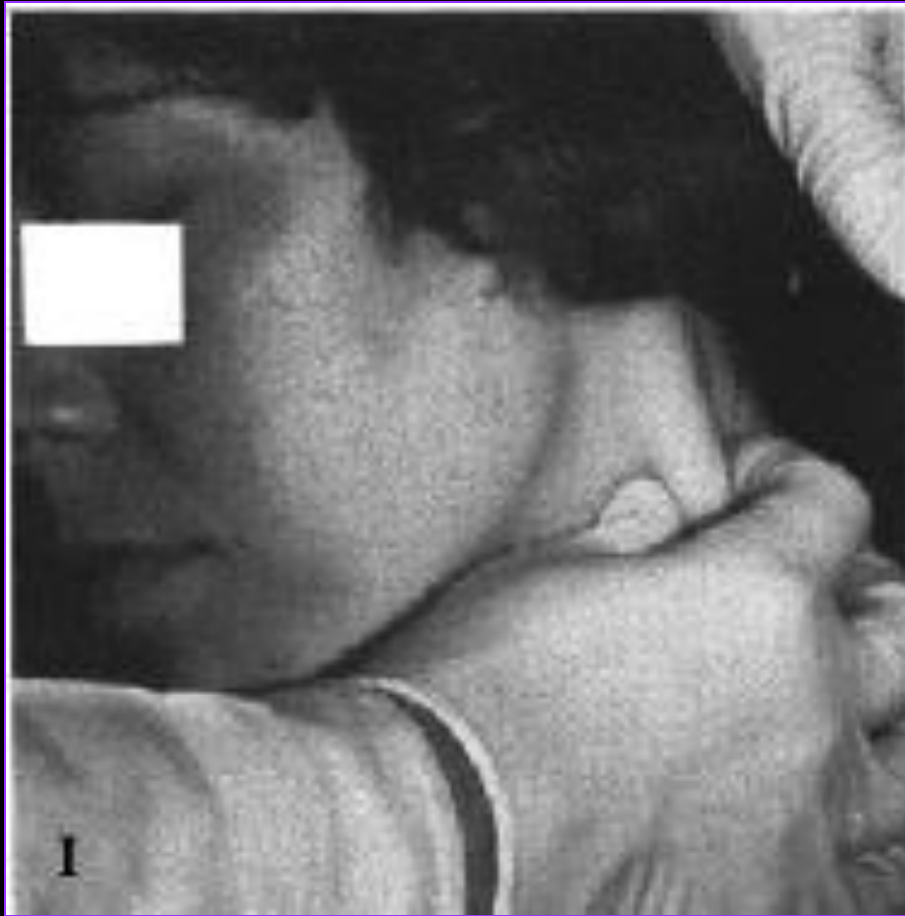
# Palpating – Medial pterygoid



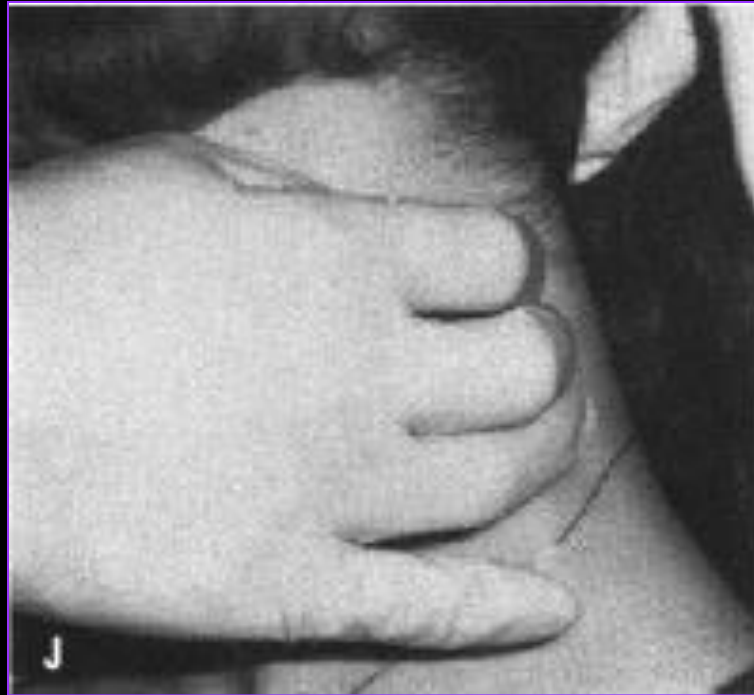# Palpating - Temporalis



## Palpating – Sternocleidomastoid



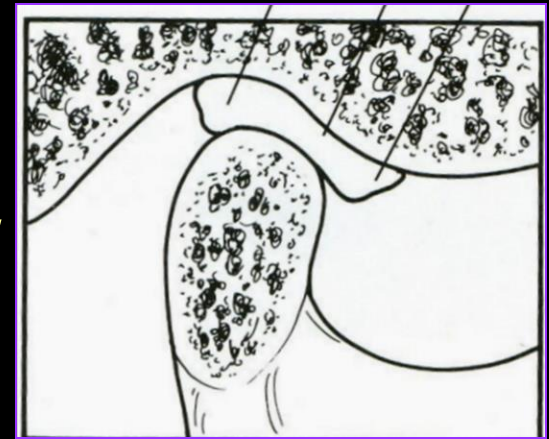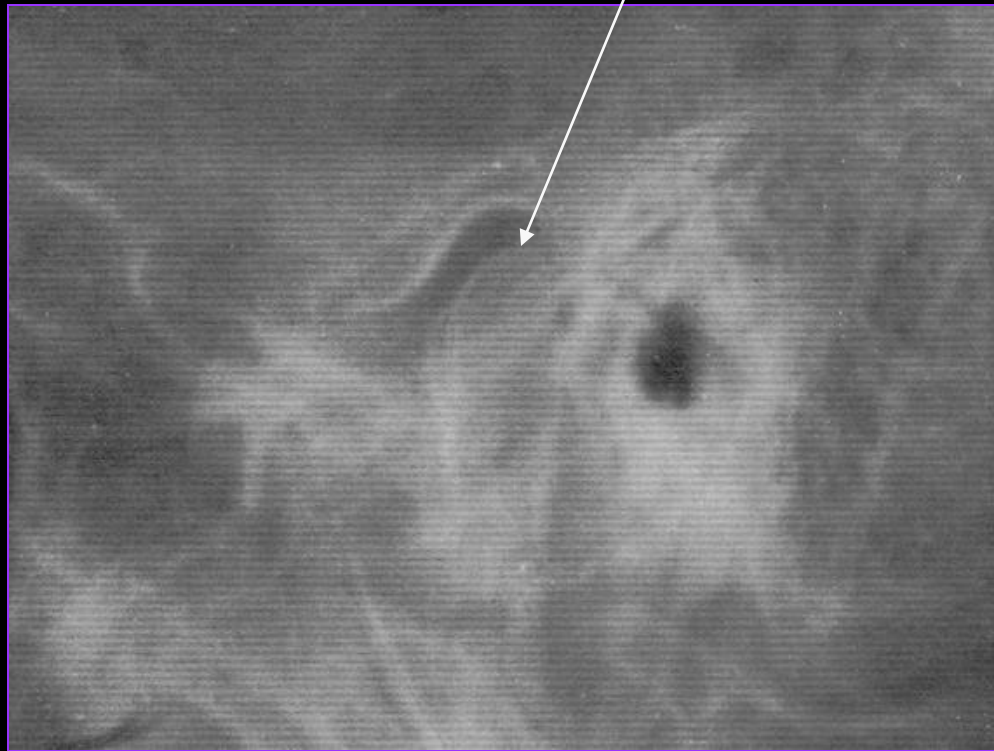
## Palpating - Trapezius



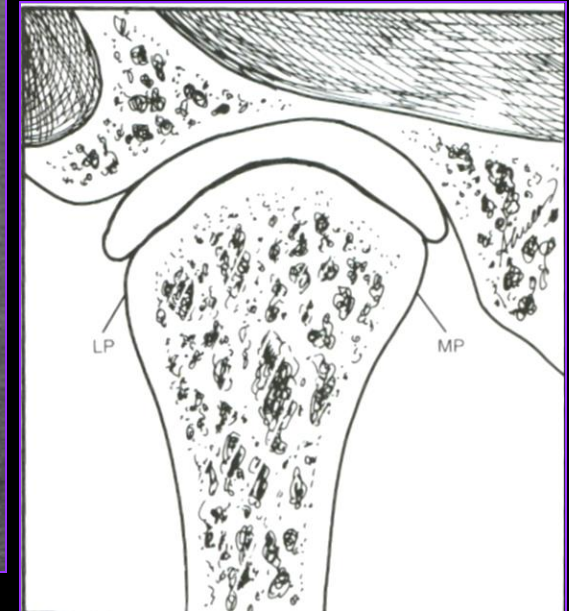## Lateral view

# Radiographic Evaluation

Superior surface – Transcranial view



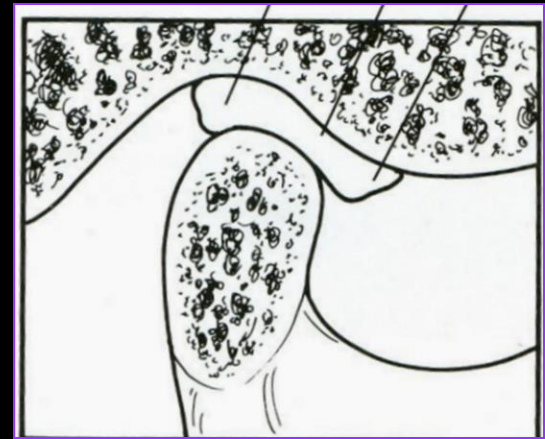## Frontal view



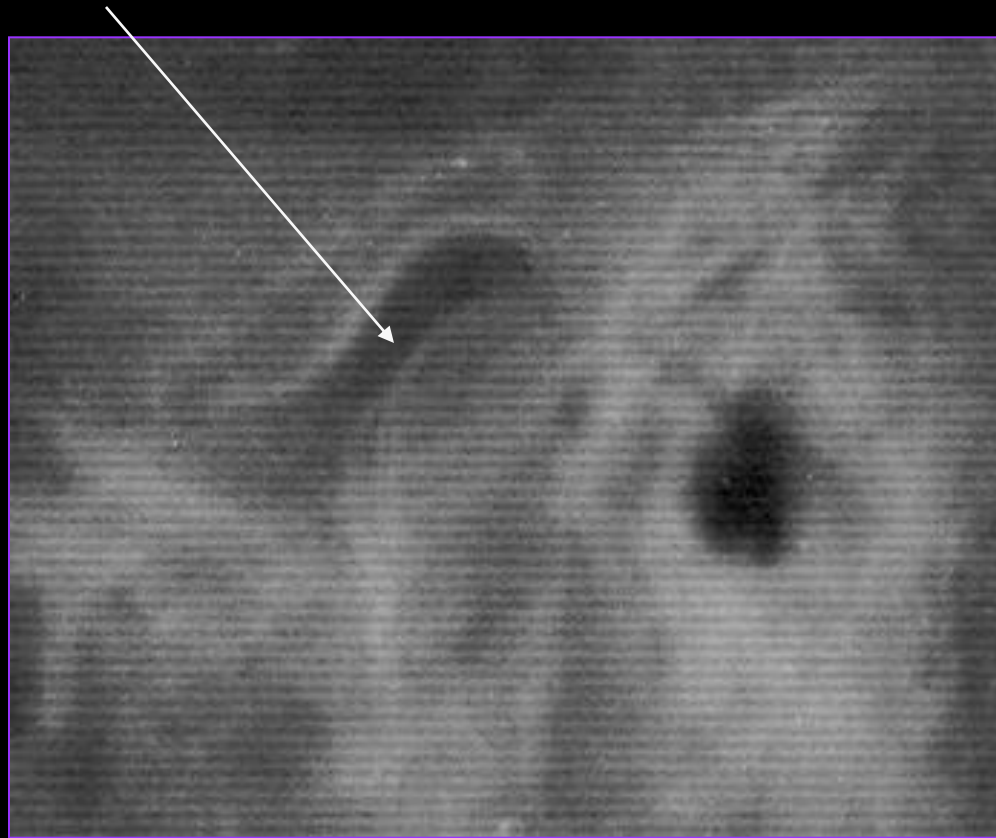
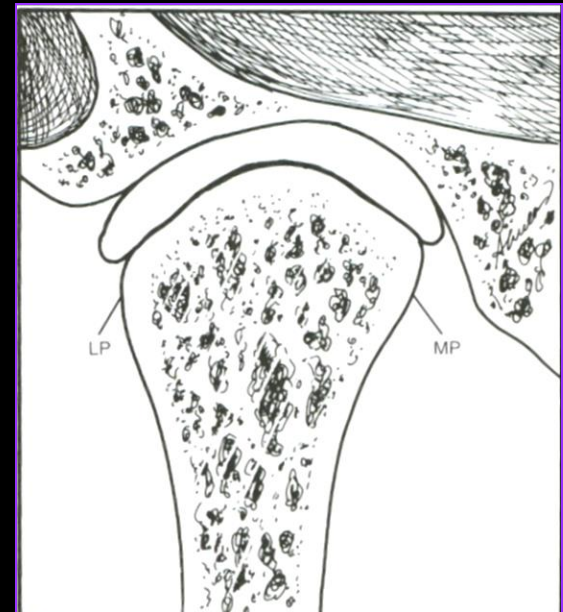
## Lateral view

# Radiographic Evaluation

Anterior and posterior surface -  
Transcranial and submento vertex



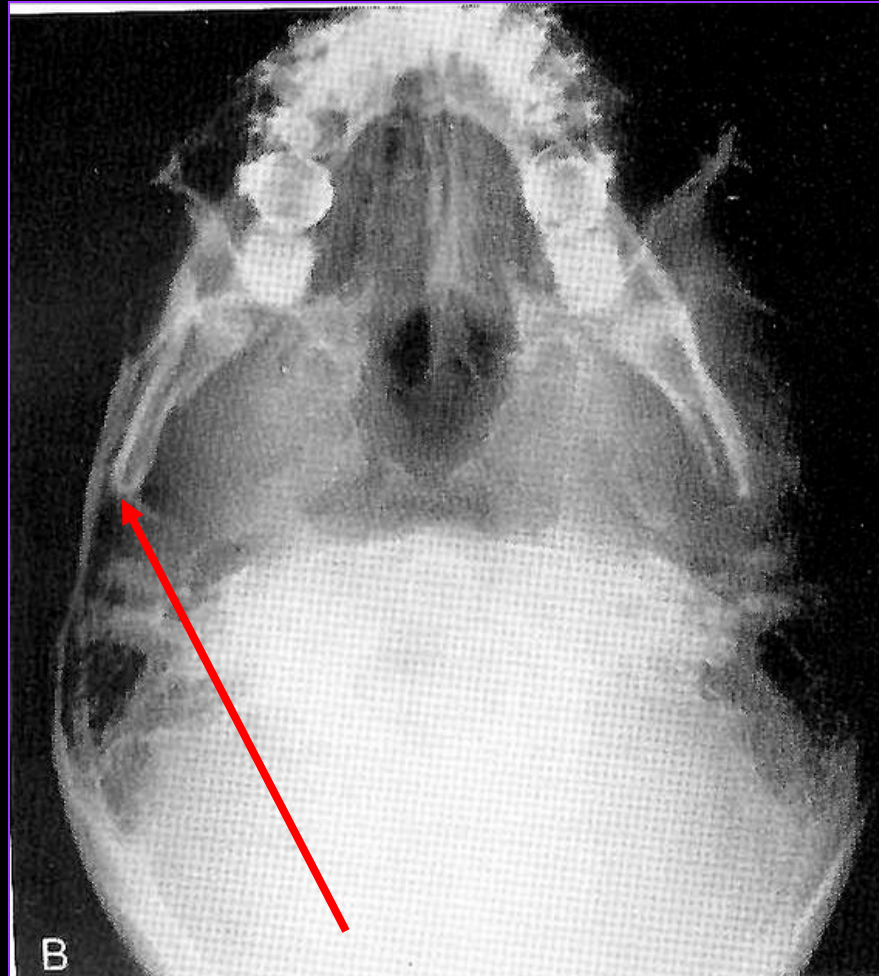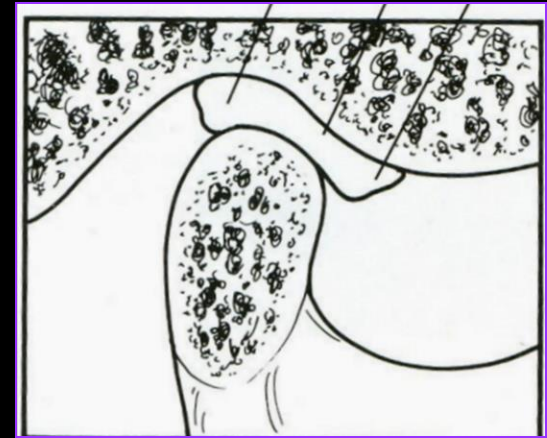## Frontal view



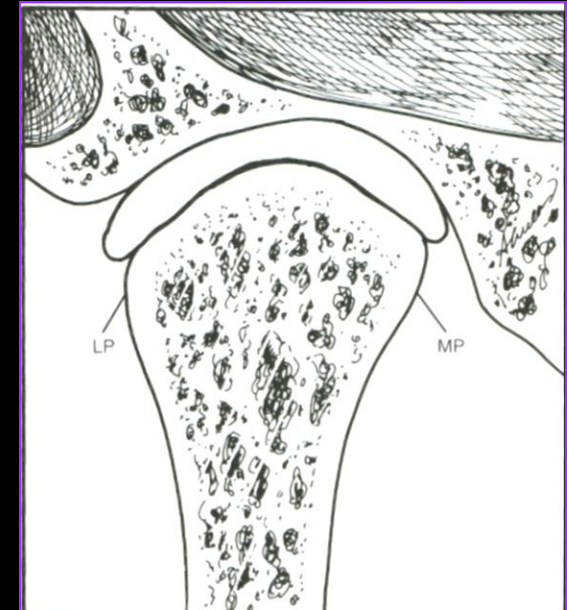## Lateral view

# Radiographic Evaluation

Anterior and posterior surface -  
Transcranial and submento vertex



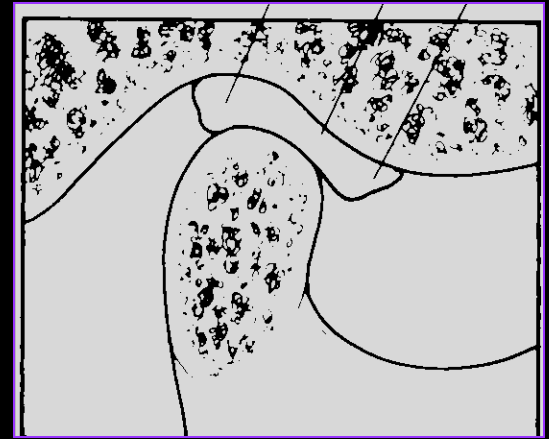## Frontal view



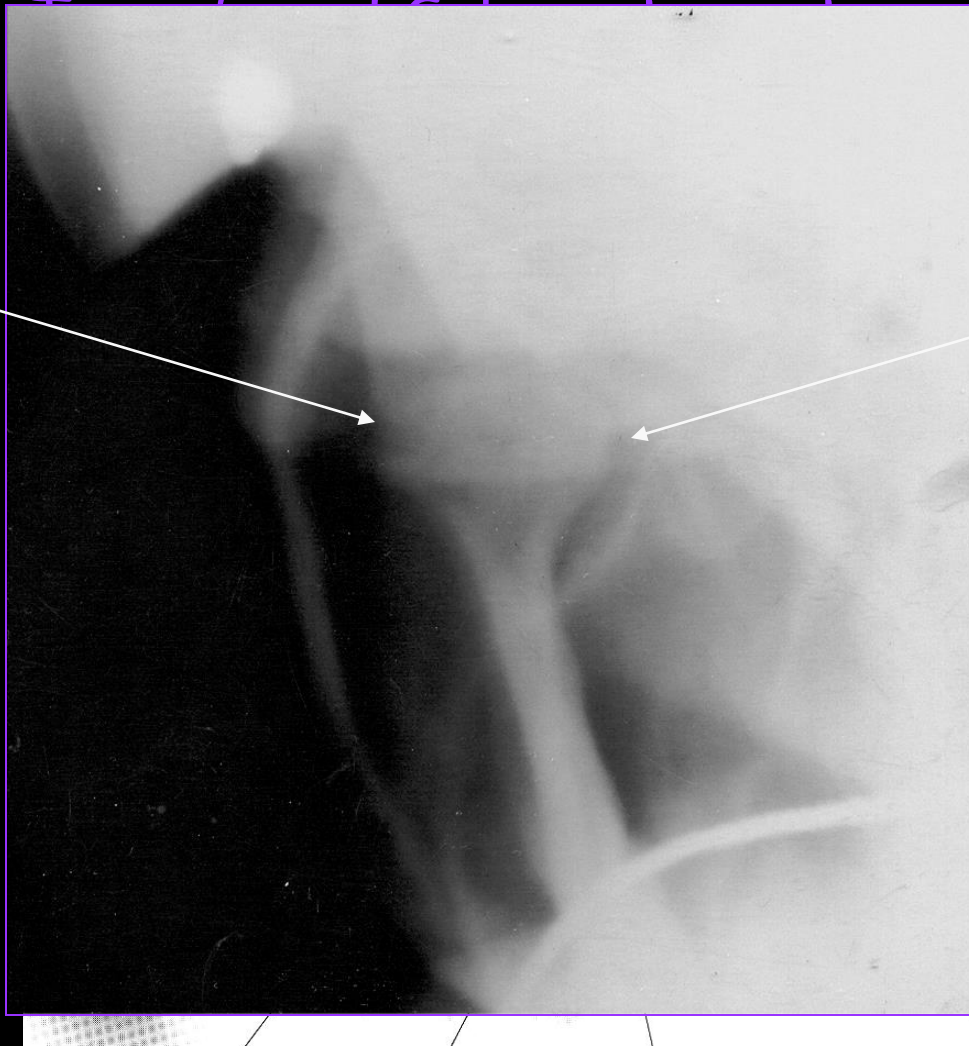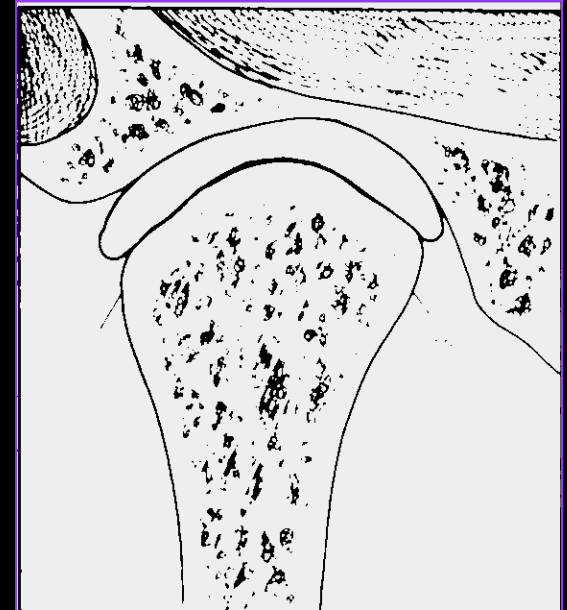
## Lateral view

# Radiographic Evaluation

Lateral and Medial pole -



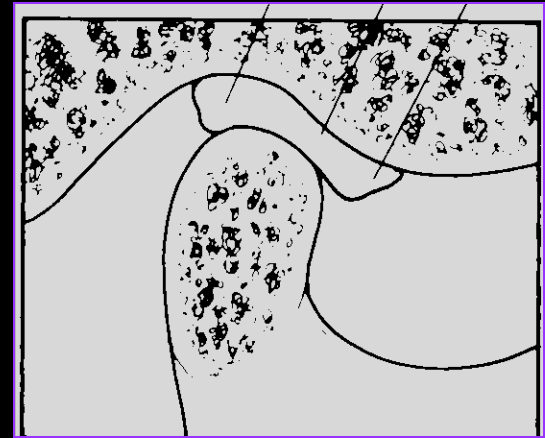
## Frontal view



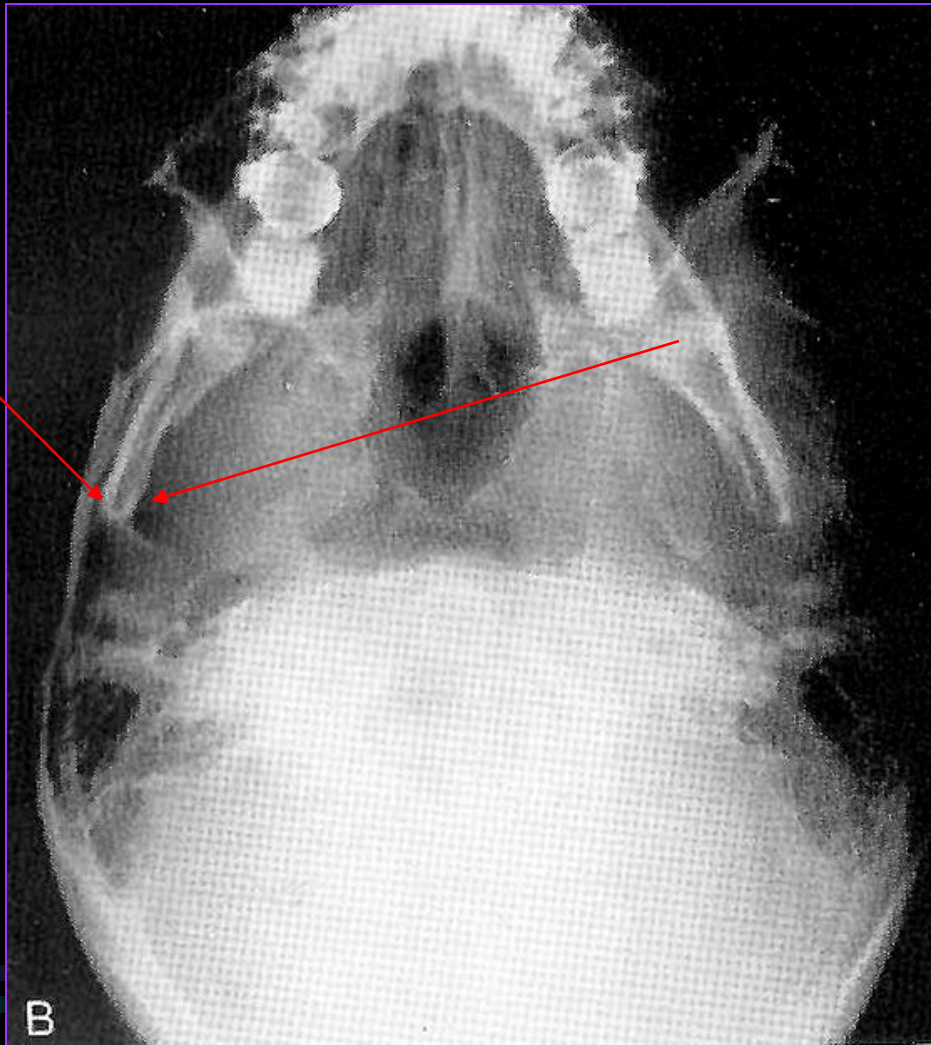
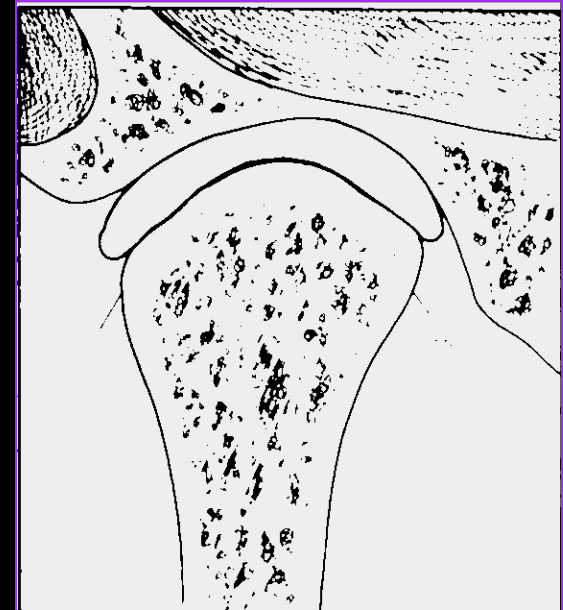
## Lateral view

# Radiographic Evaluation

Lateral and Medial pole -  
Towne's and Submento vertex

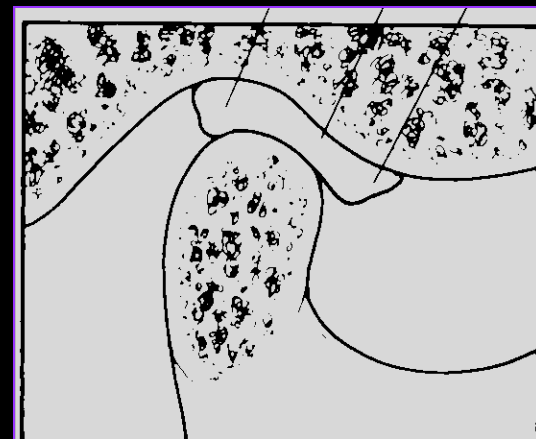

## Frontal view



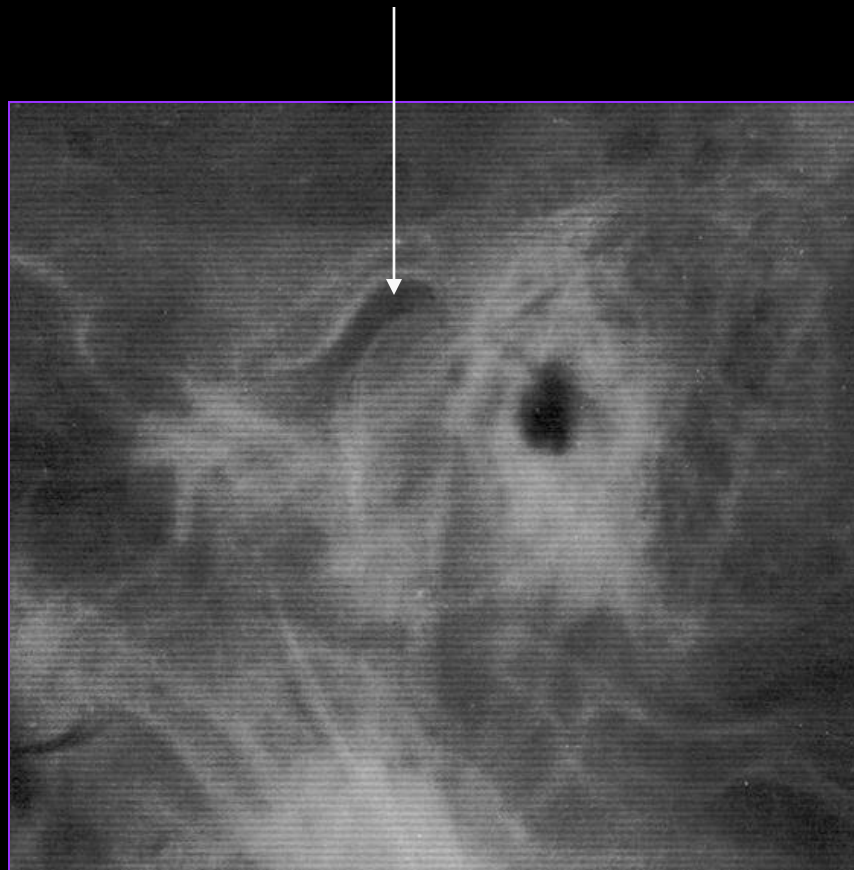
B

## Lateral view

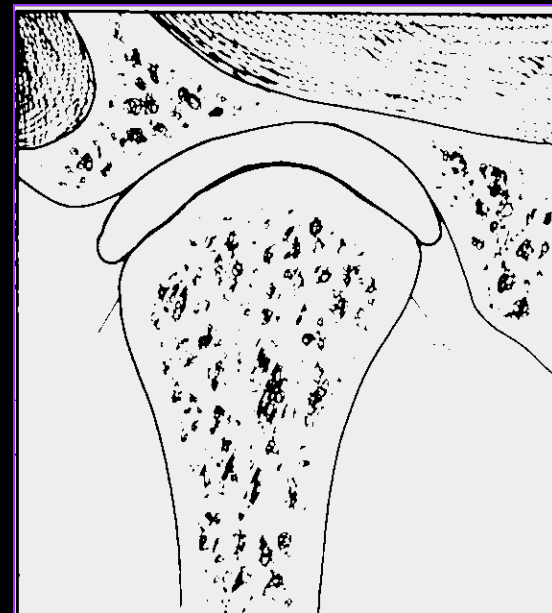


## Radiographic Evaluation

Joint space - Transcranial



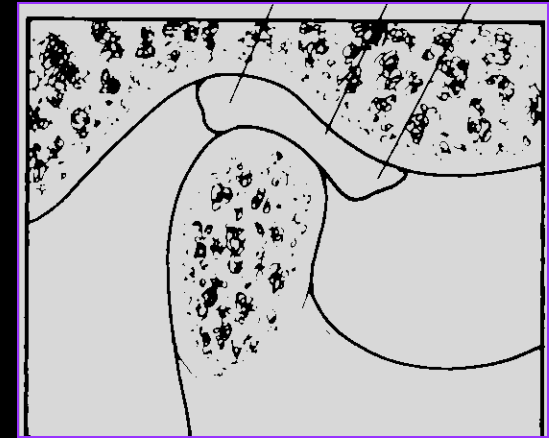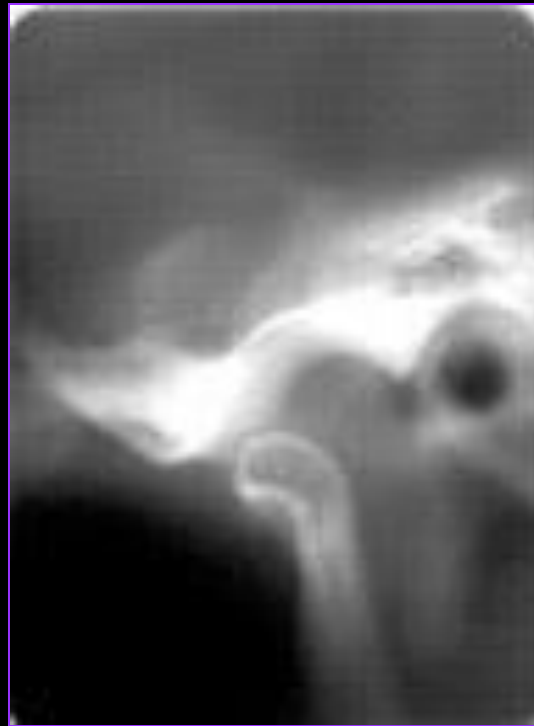
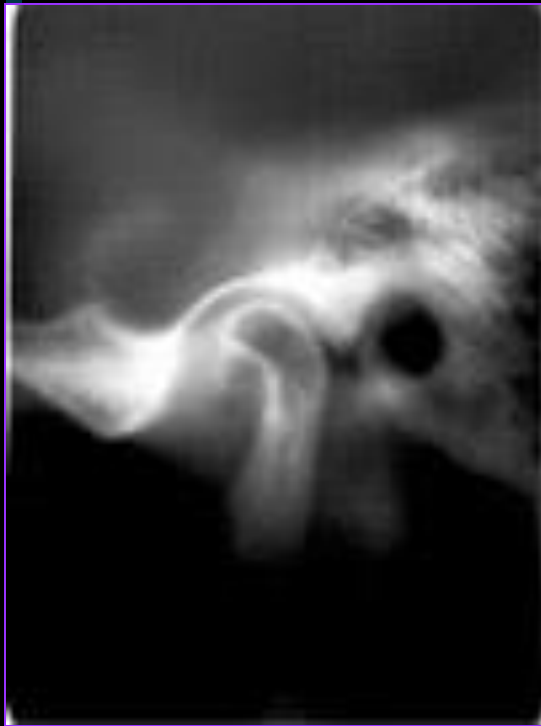## Frontal view



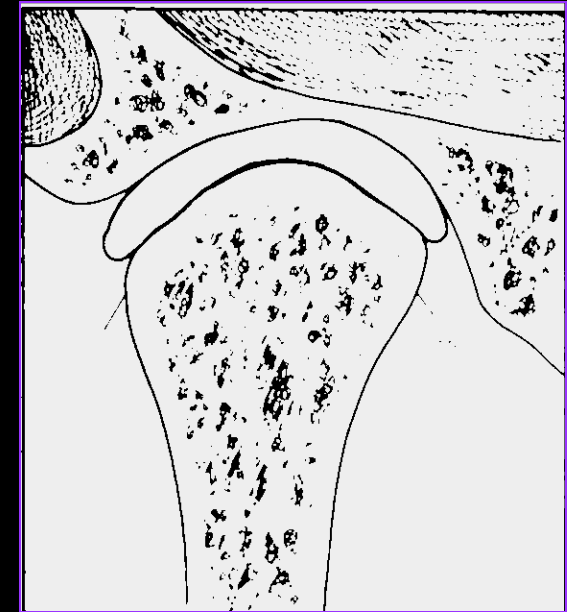
## Lateral view

# Radiographic Evaluation

Range of motion - Transcranial




## Frontal view



# Radiographs

## Conventional

- Transcranial
- Transpharyngeal
- Transorbital
- PA Water's view
- Reverse townes




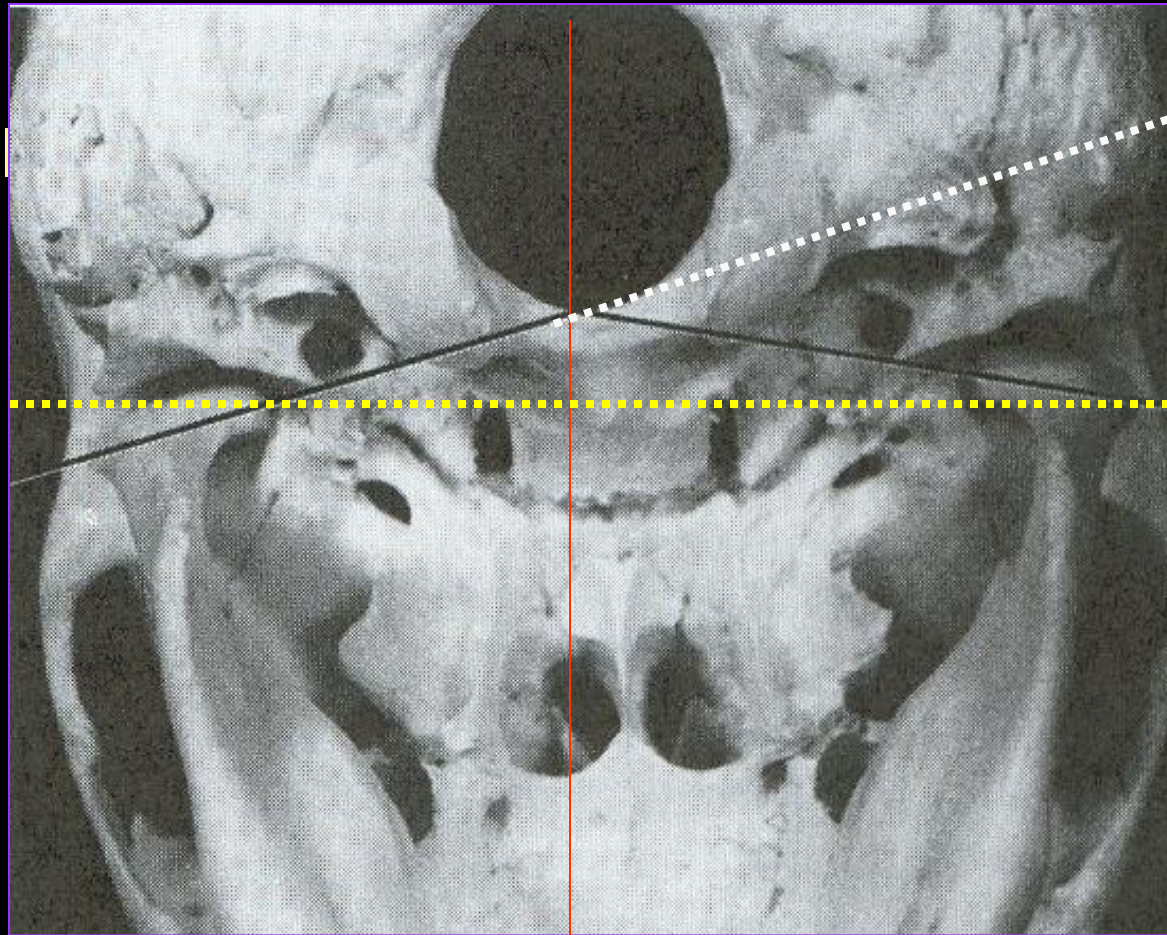
Specific for T M J

# Radiographs

## Specialized

- Corrected tomogram

F  
I  
L  
M

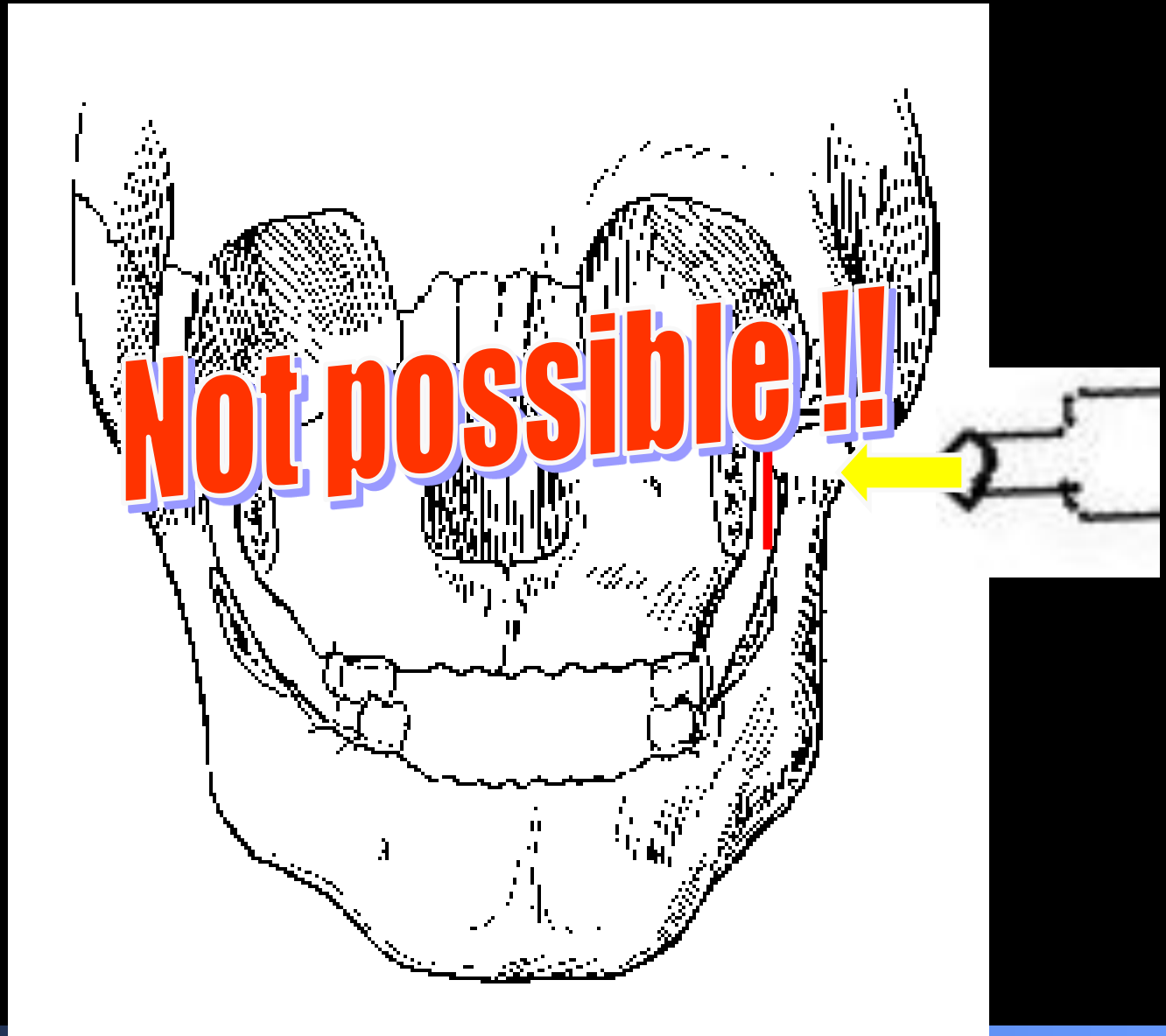


# Radiographs

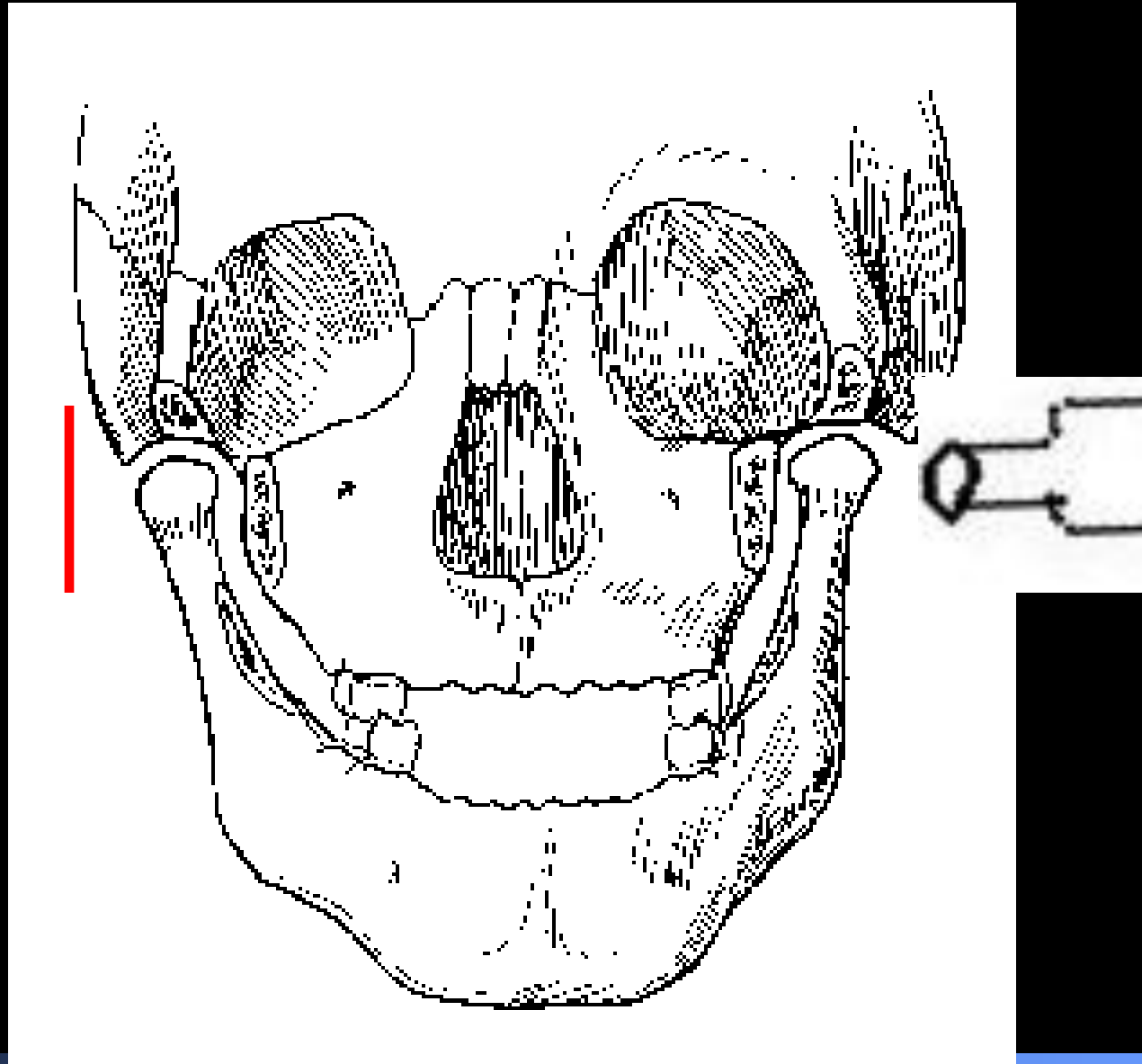
## Specialized

- Corrected lateral tomogram
- Corrected frontal tomogram
- Panoramic
- Arthrography
- C T or C A T
- Magnetic resonance imaging

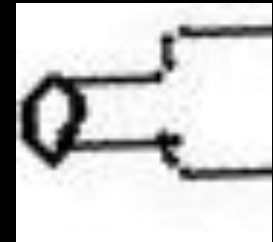
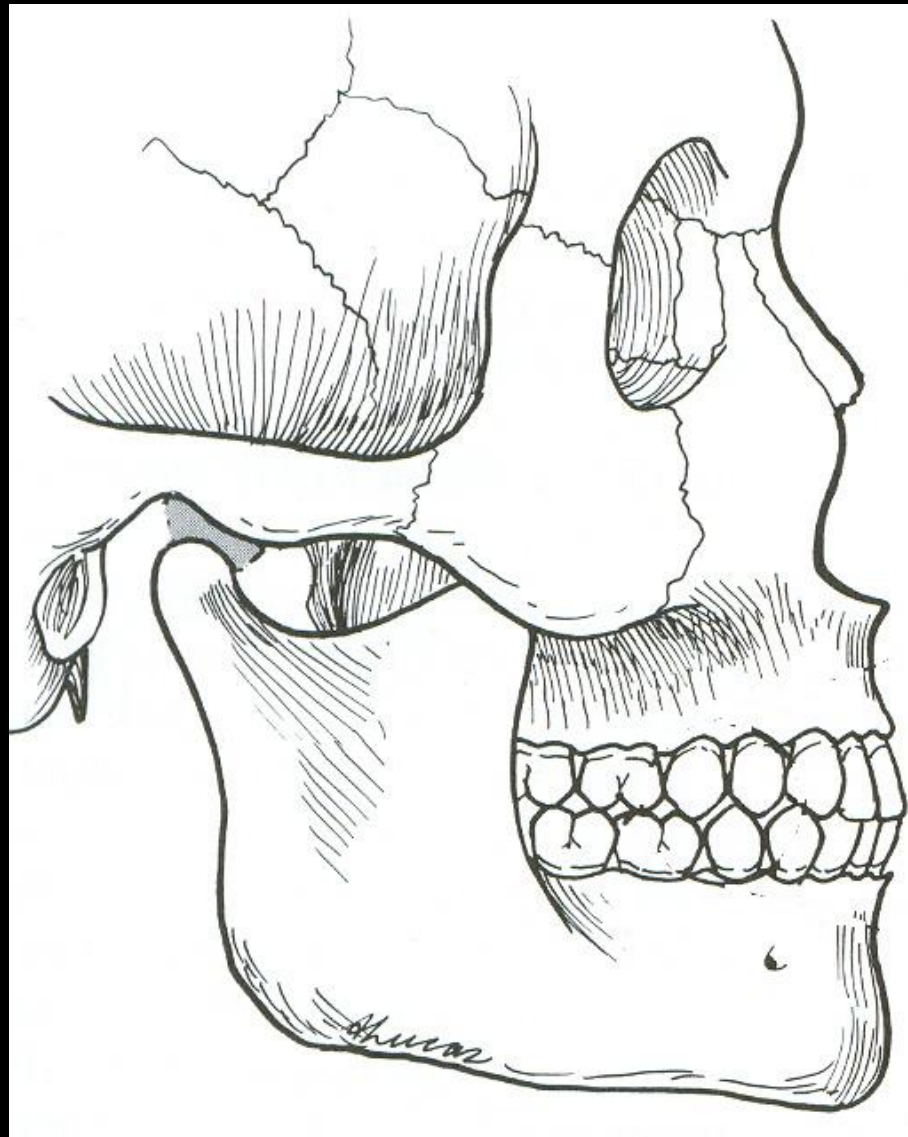
# T M J Radiography- Conventional



# T M J Radiography- Conventional

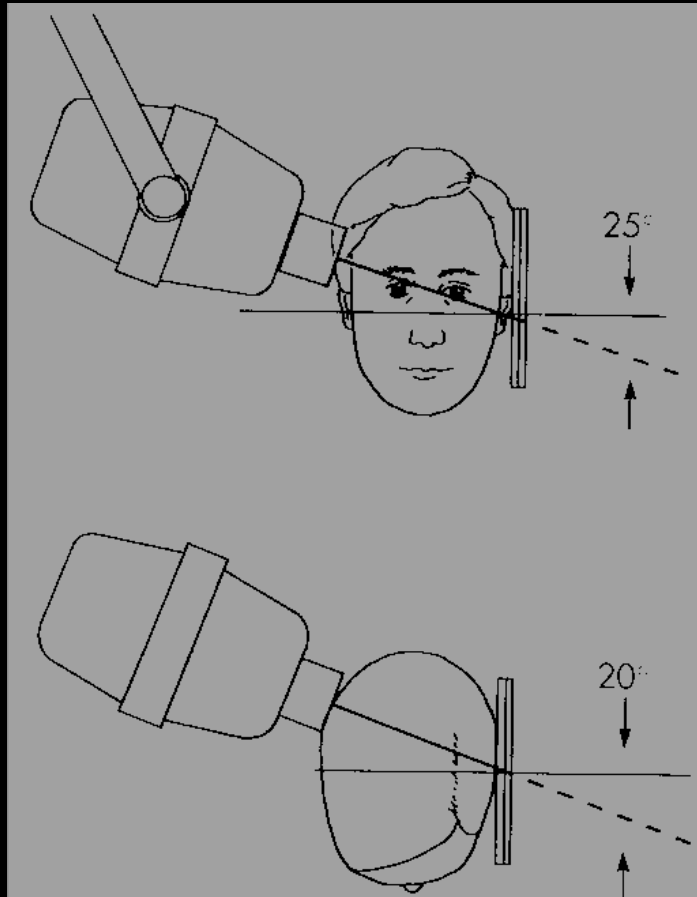


# T M J Radiography- Conventional

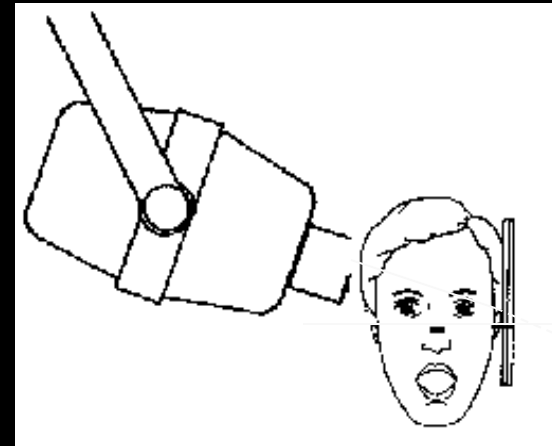


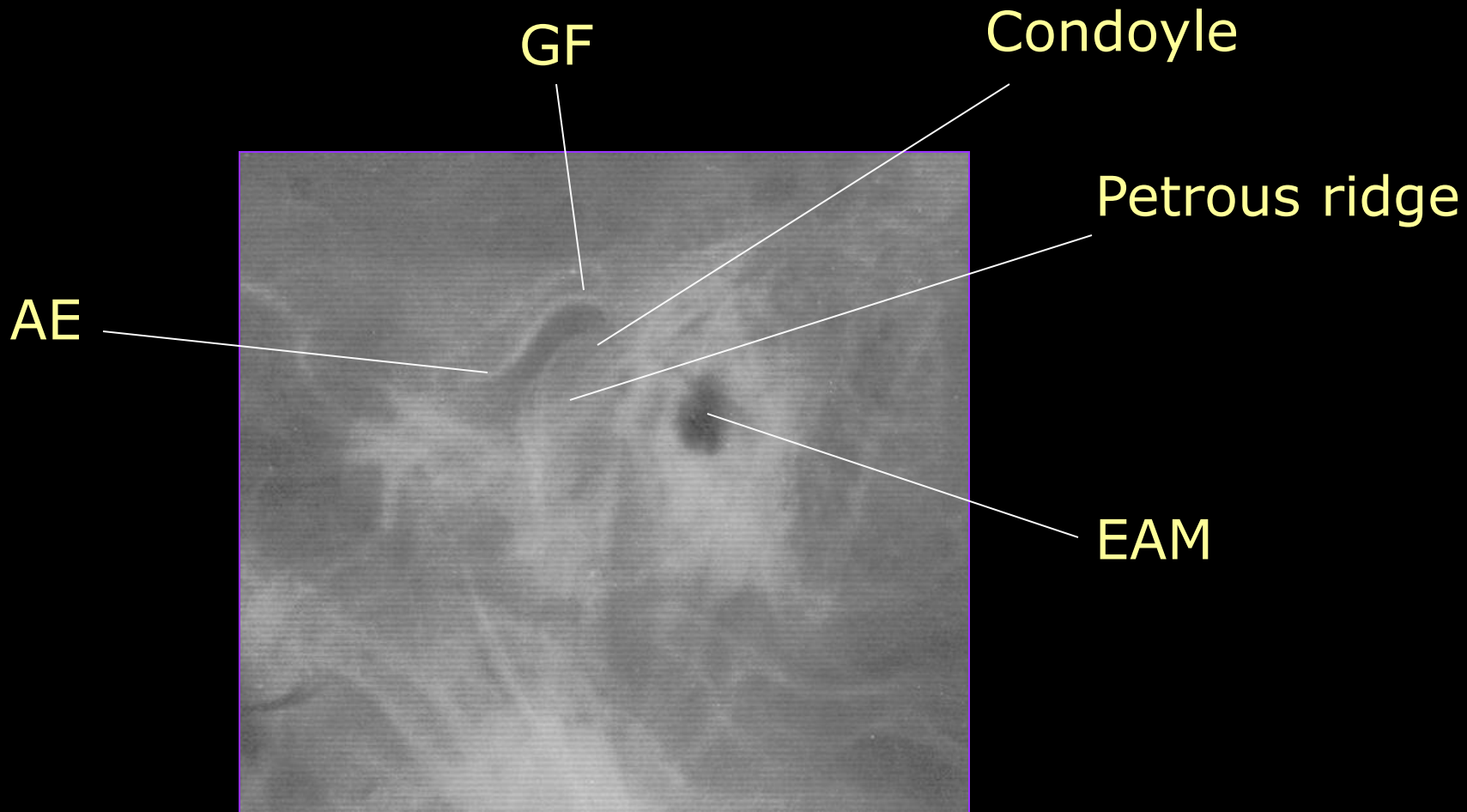
# Transcranial Projection

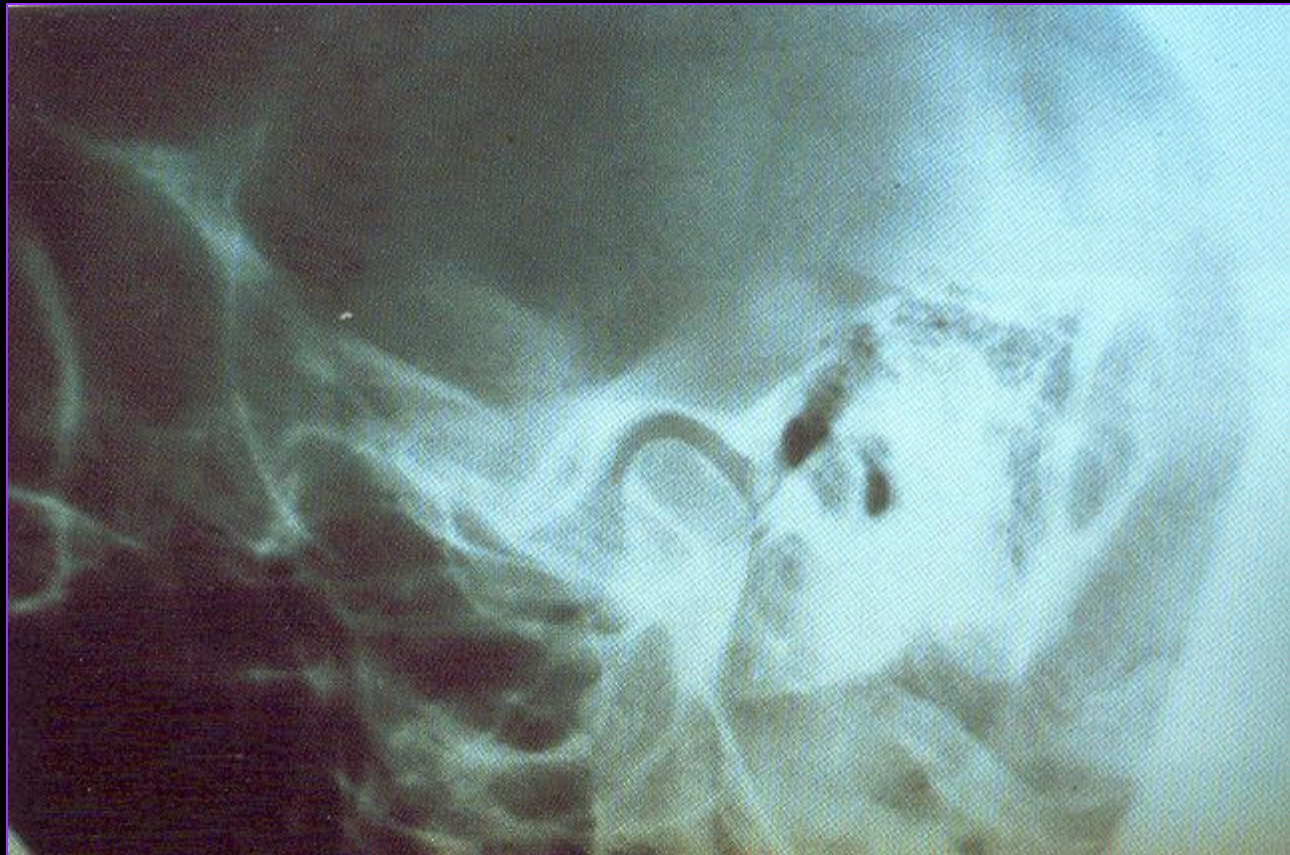Closed

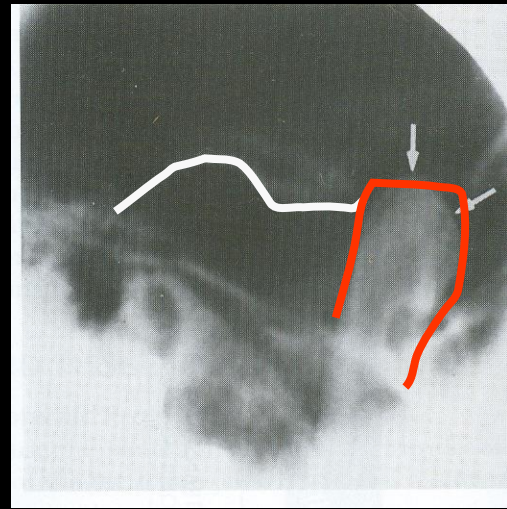
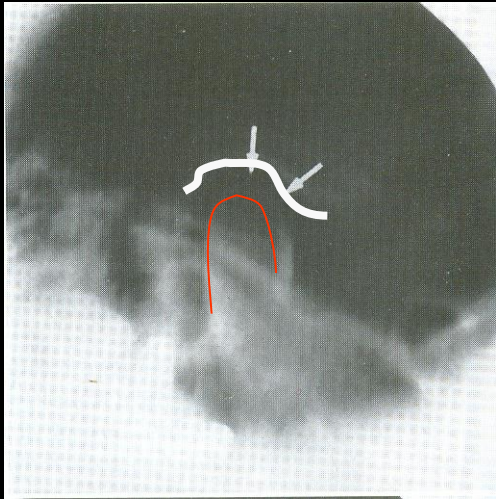


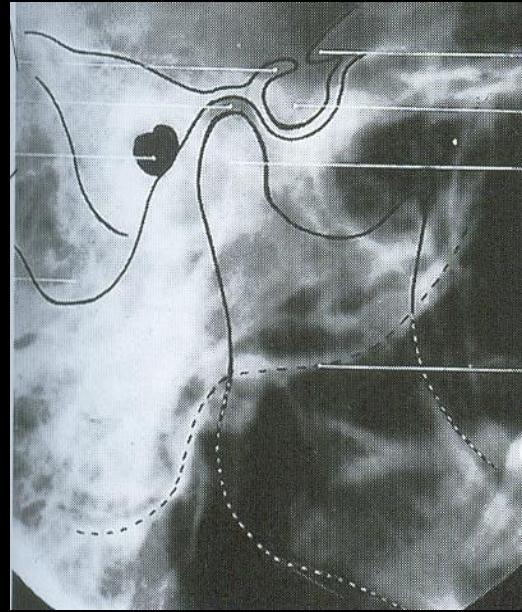
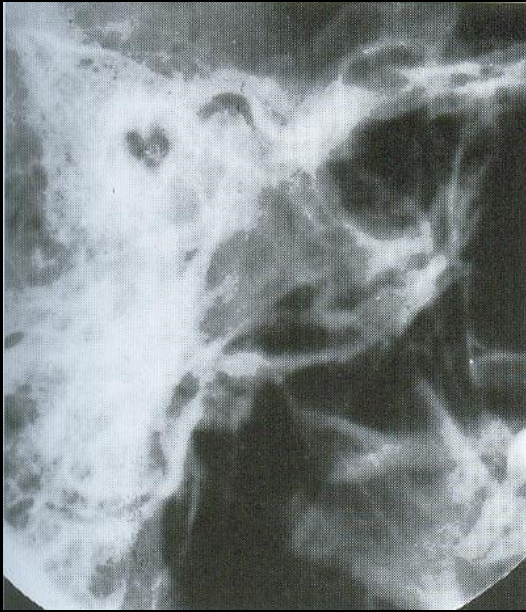
Open



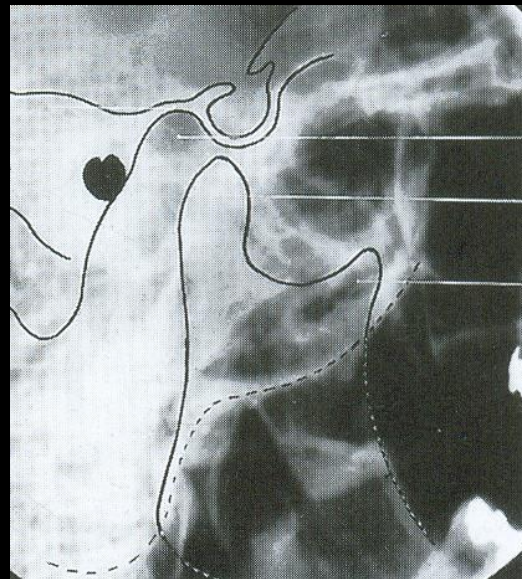
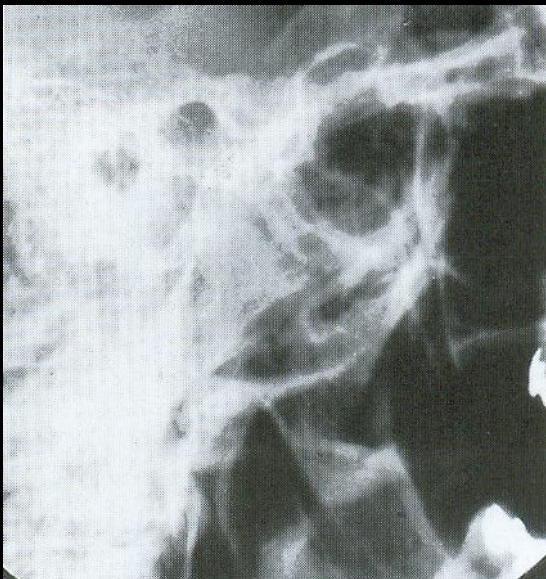








**Closed**



**Open**

# Transcranial Projection

## Image field

- Articular fossa
- Articular eminence
- Discal space
- Condoylar head

## Indications

- Trismus
- Dislocation
- Bony ankylosis
- TMJ arthritis
- Assessment of joint space

# Transcranial Projection

Head position : Cantho-meatal line  $\circ$  to floor

: Mid- sagg. Plane perp. to floor

**1. Open**

**2. Closed**

Film position : Perpendicular to floor

: Centered over condyle

Projection of central ray :  $25^{\circ}$  downward

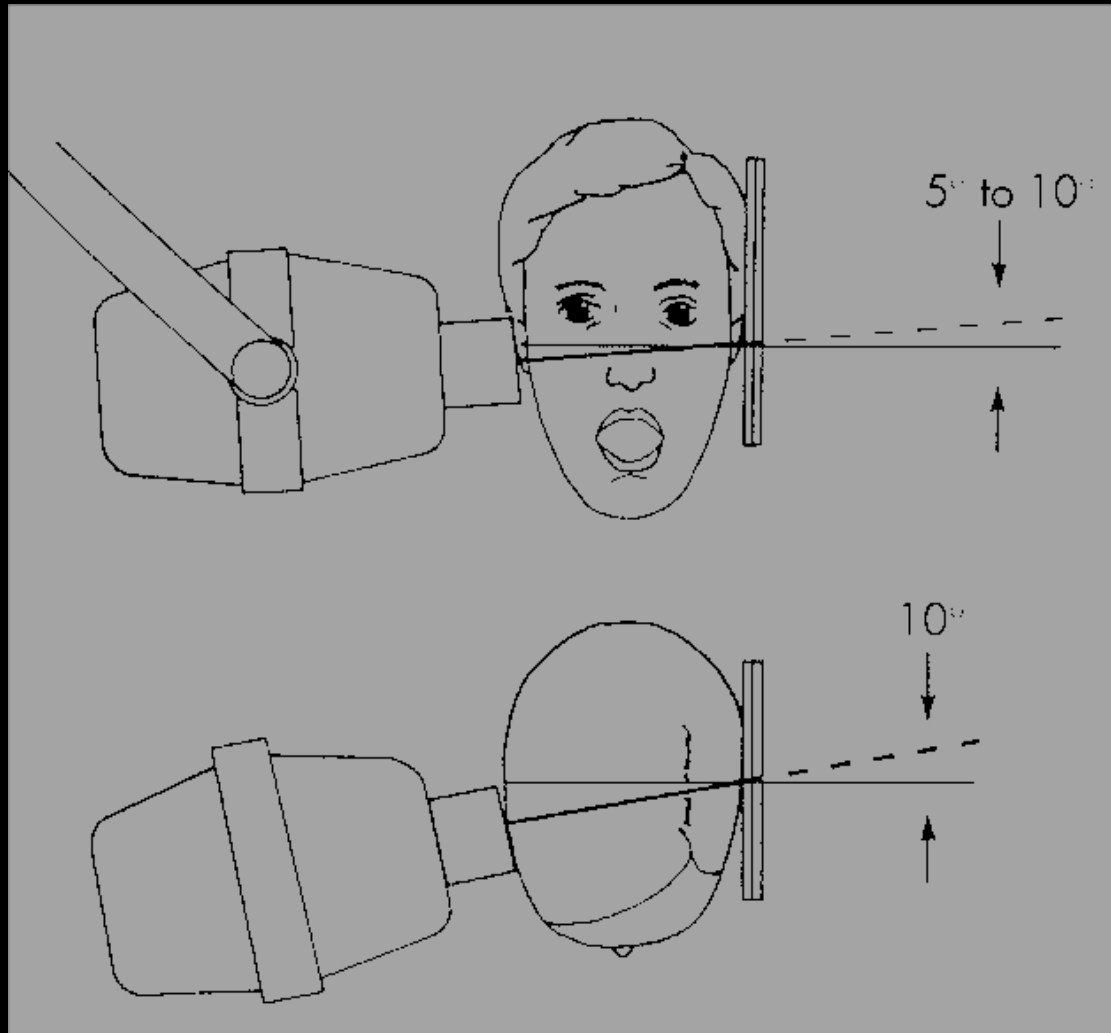
$20^{\circ}$  anteriorly

S F D :  $8'' + 6''$  ( $14''$ )

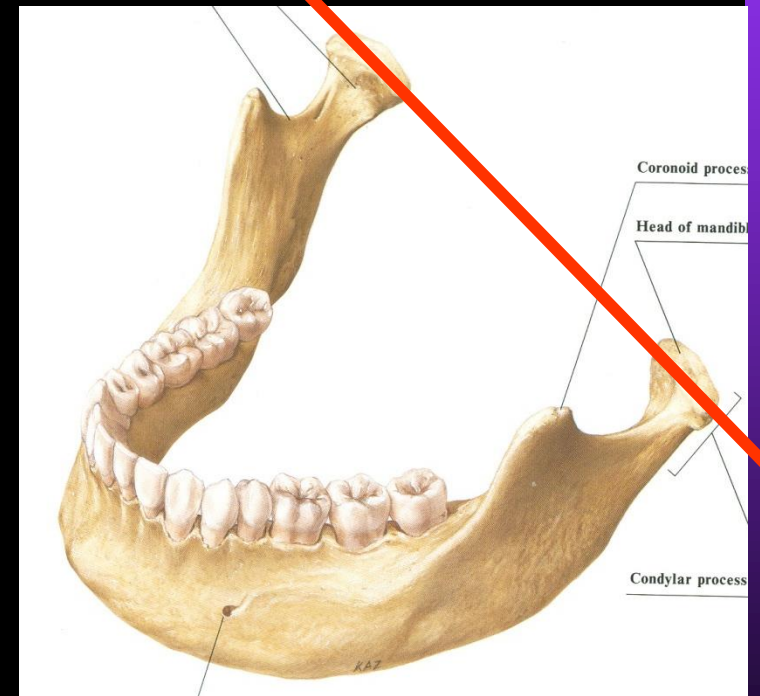
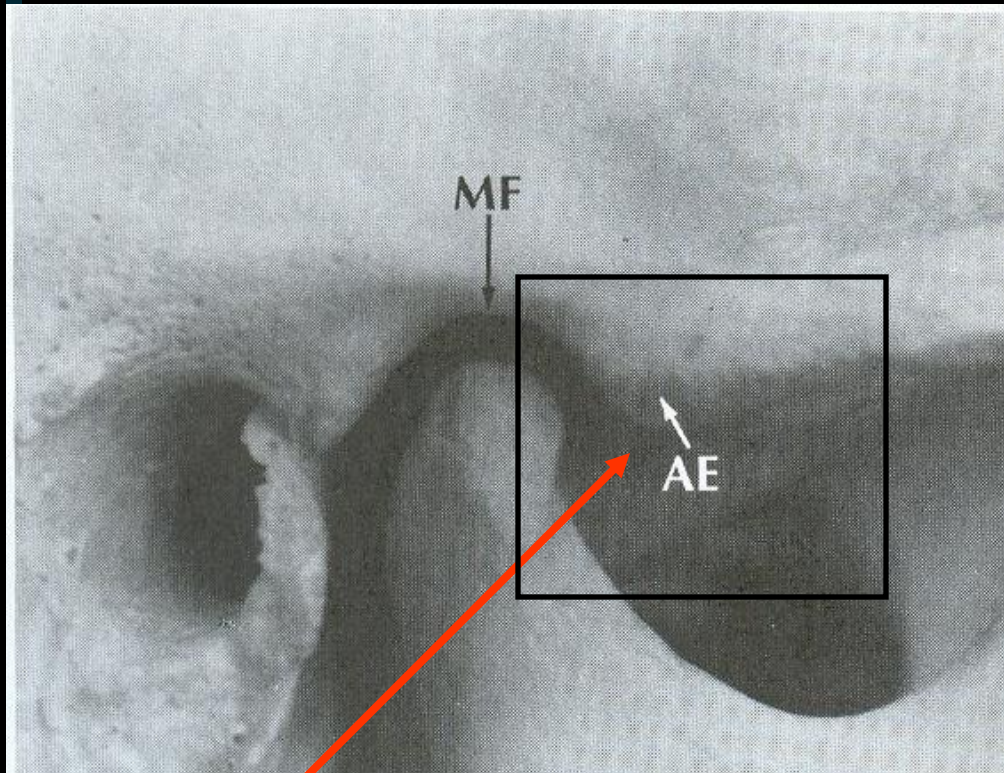
Exposure: Type of patient, screen-film combo. used

70 Kv, 7 Ma, 1.0 sec

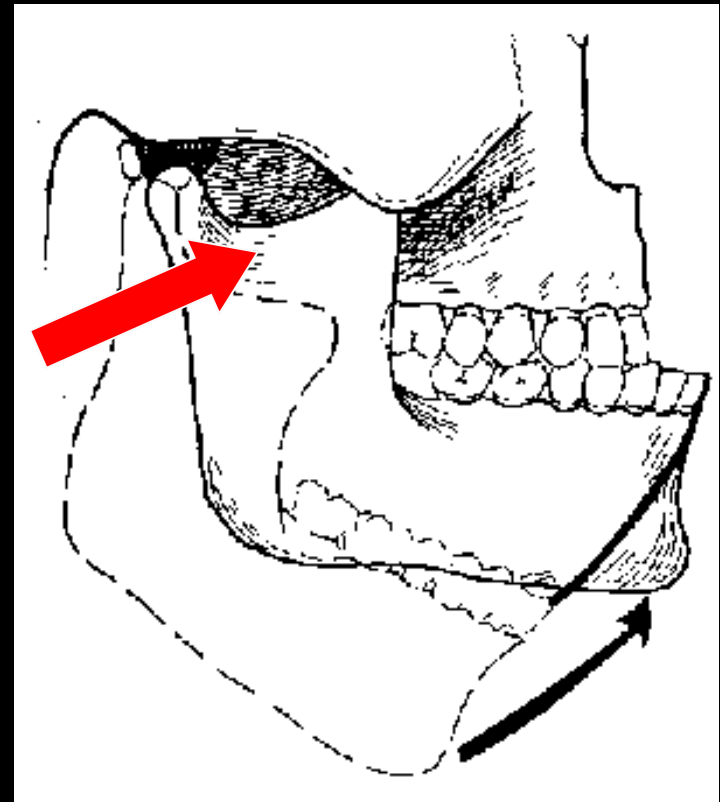
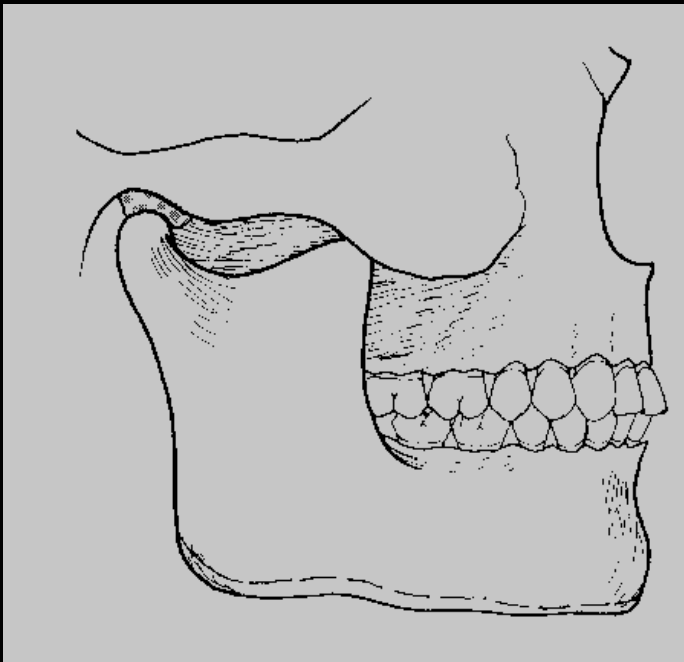
# Transpharyngeal Projection



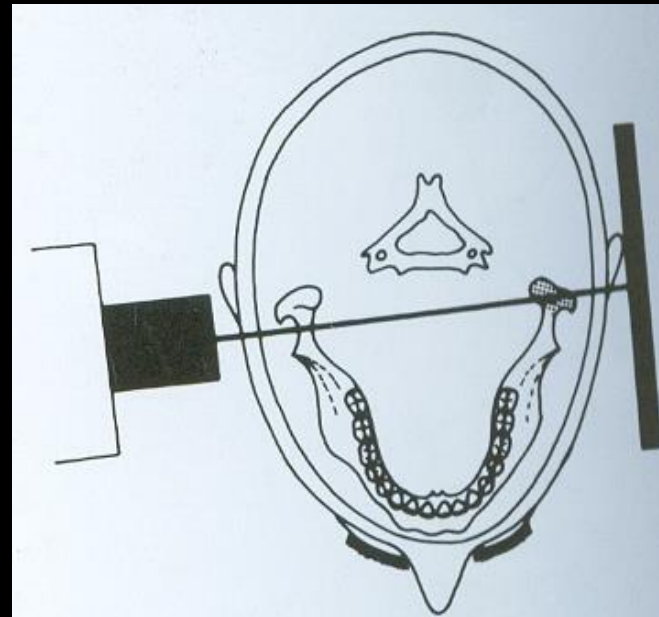
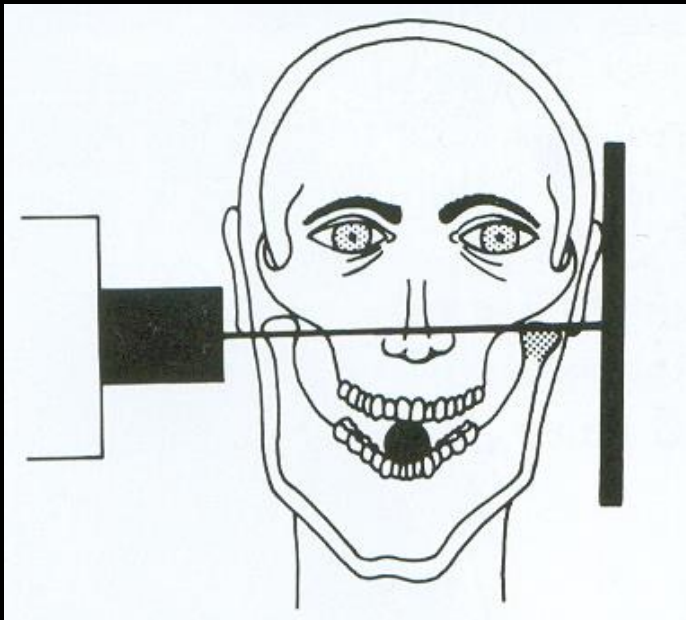
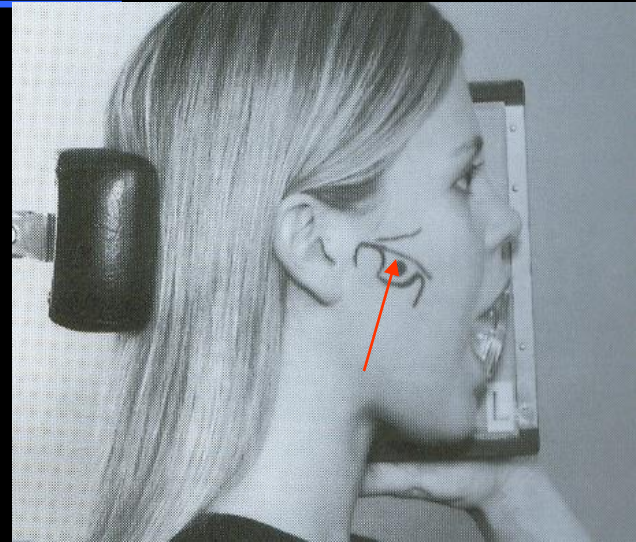

# Transpharyngeal Projection



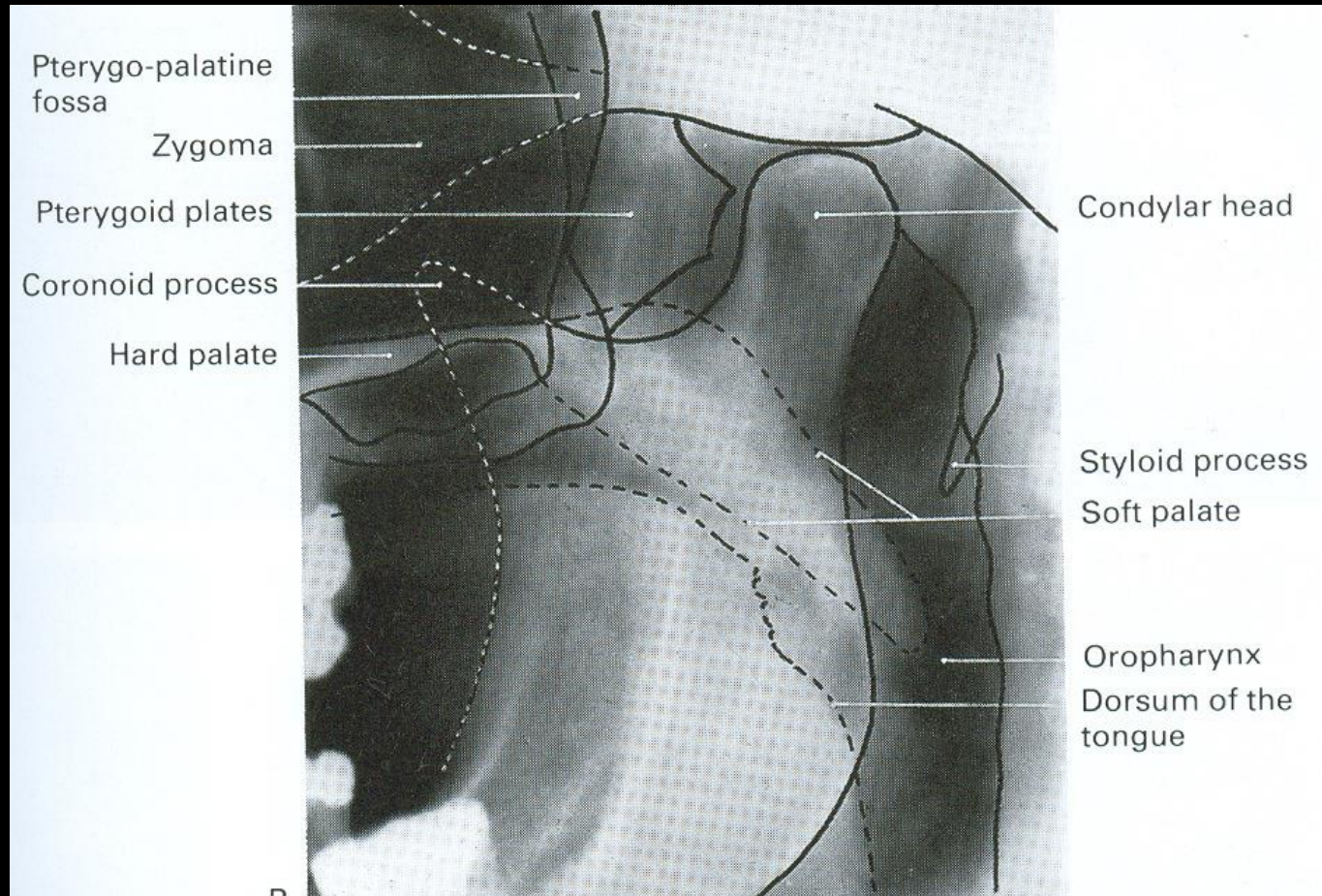
# Transpharyngeal Projection



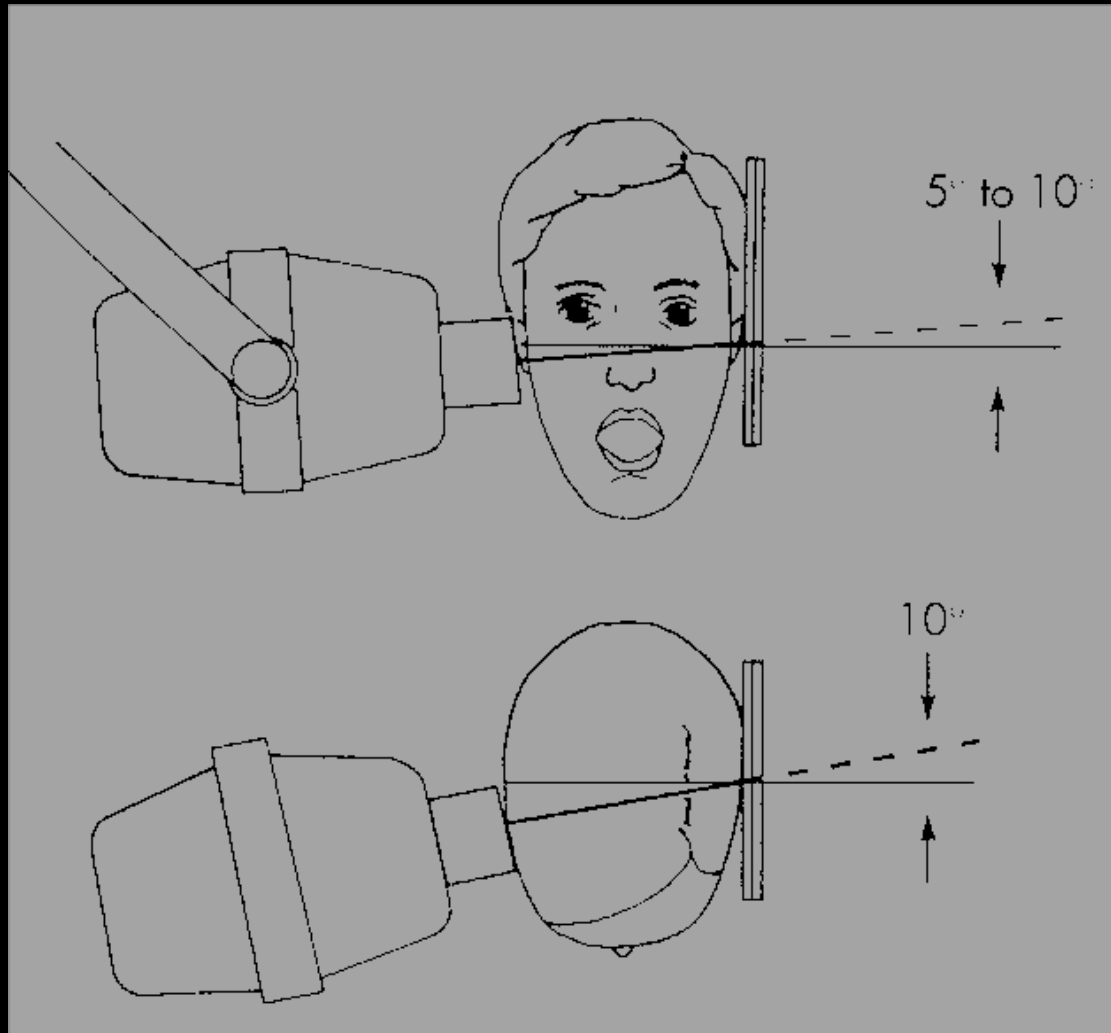
# Transpharyngeal Projection



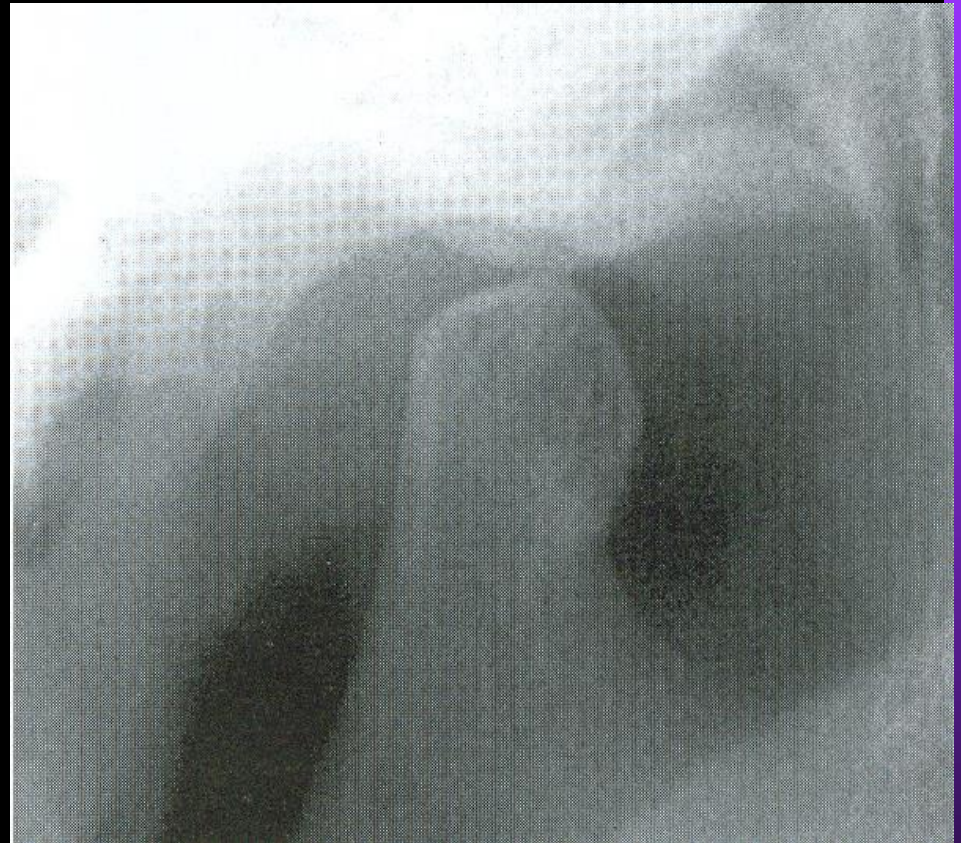
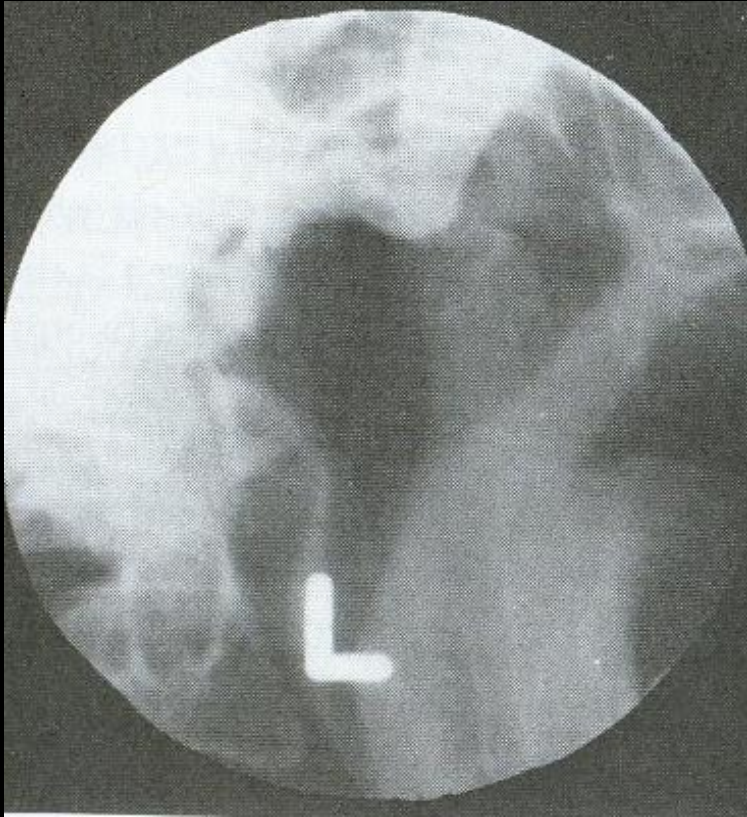# Transpharyngeal Projection



# Transpharyngeal Projection



# Transpharyngeal Projection



# Transpharyngeal Projection

## Image field

- Articular fossa and eminence
- Condoylar head, neck, ramus

## Indications

- # condoylar neck
- Ant- post displacement
- Changes in osseous structure on anterior and superior surface

## Transpharyngeal Projection

Head position : Cantho-meatal line  $\circ$  to floor

: Mid- sagg. Plane perp. to floor

### **1. Open**

Film position : Perpendicular to floor

: Centered over condyle

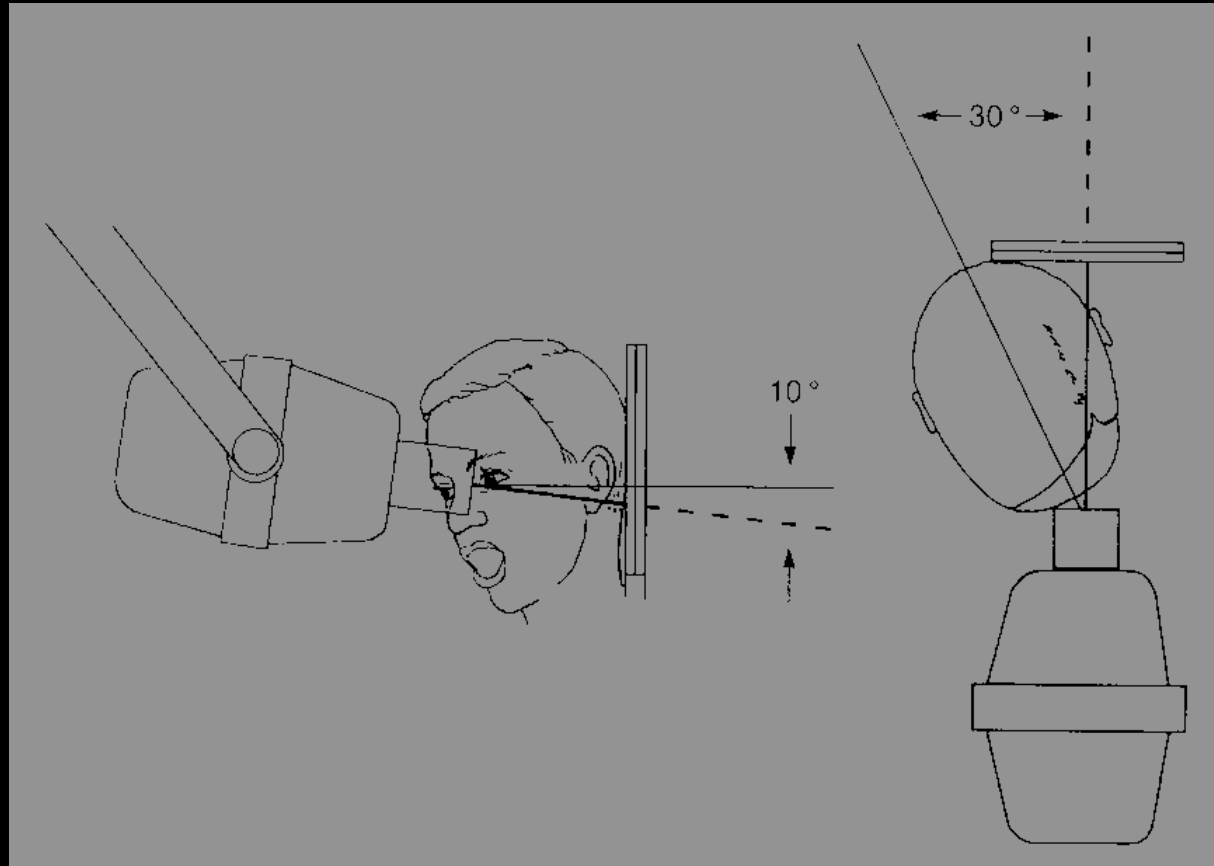
Projection of central ray :  $5^{\circ}$  to  $10^{\circ}$  upward

$10^{\circ}$  backward

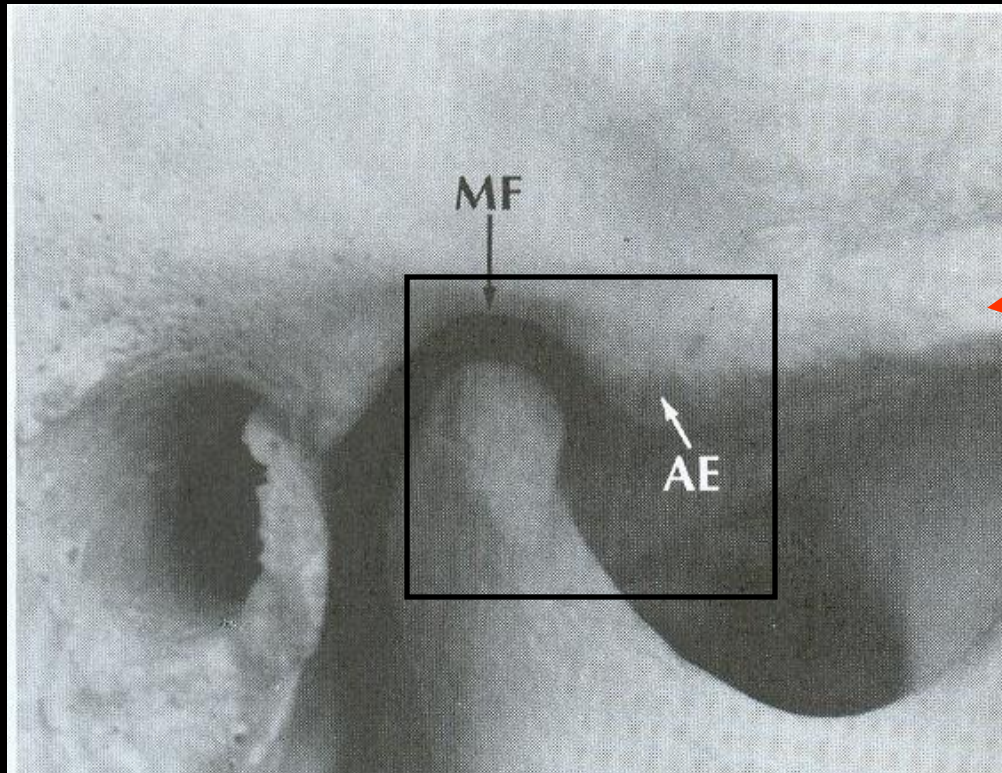
S F D : 8" + 6" (14")

**Exposure:** Type of patient, screen-film combination used ; 70 Kv, 7 Ma, 1.0 sec

# Transorbital Projection



# Transpharyngeal Projection



# Transorbital Projection

## Image field

- Medial & lateral poles of condoylar head
- Condoylar neck
- Mastoid air cells

## Indications

- # condoylar neck
- Medio- lateral displacement
- Changes in osseous structure on anterior border

# Transmittance Spectroscopy

Head

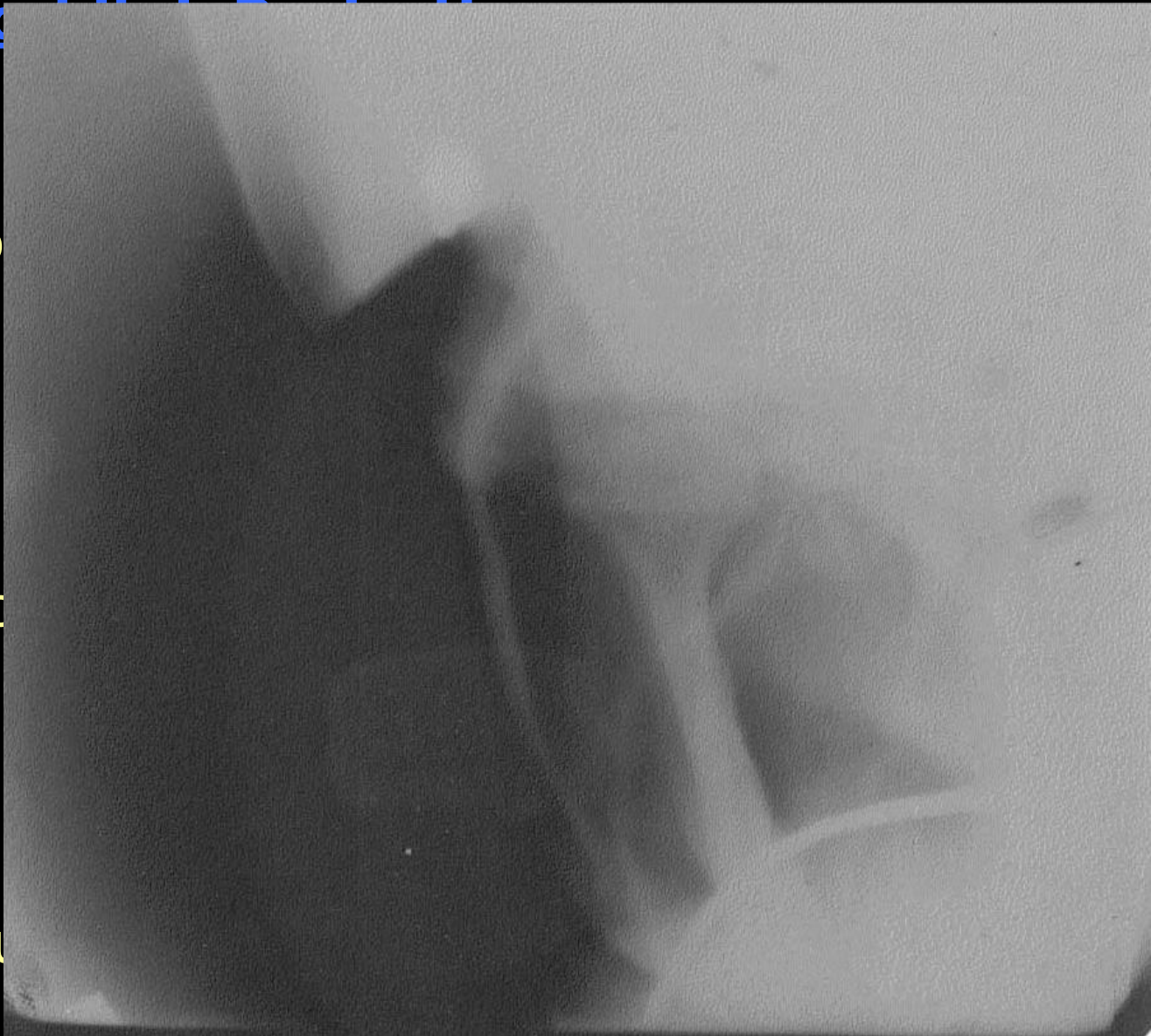
## **1. Op**

Film po

Project  
perpe

S F D :

Exposu  
used;




or

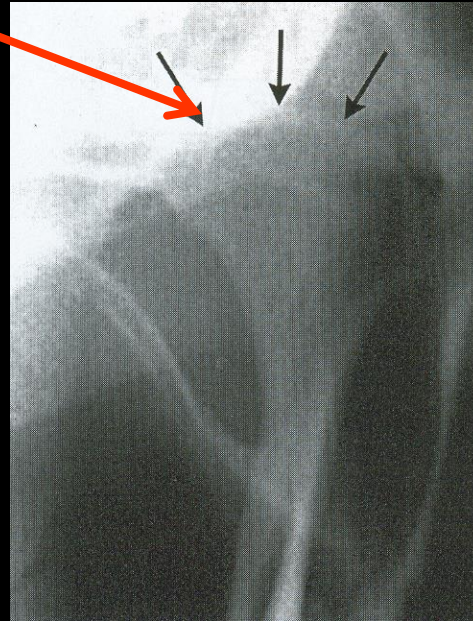

orbit

ation

# Transorbital Projection



Mastoid process



# CLASSIFICATION

- I. Masticatory Muscle disorders
- II. Internal joint derangement
- III. Degenerative disease  
(Osteoarthritis, Osteoarthrosis)
- IV. Trauma – Fracture
  - Dislocation
  - Traumatic arthritis
  - Synovitis

# CLASSIFICATION

## Uncommon disorders

- Inflammatory
  - a) Infection (following trauma, spread from middle ear or other adjacent structures)
  - b) Rheumatoid arthritis
- Ankylosis – following trauma or infection
- Congenital & developmental defects -  
Hypoplasia and hyperplasia of condyle
- Neoplasia – Osteoma, Chondroma

## Myofascial pain

### Myofascial Pain dysfunction syndrome

Muscle spasm along with dysfunction & pain

- C/o pain or ache in jaw, temples, face, preauricular area, or inside ear at rest or during function,
- pain on palpation in three or more muscle sites
- Opening may/ may not be limited
- Areas of referred pain


## Myofascial pain

### Myofascial Pain dysfunction syndrome

Muscle spasm along with dysfunction & pain

Laskin's criteria

- Unilateral pain worse on awakening
- Muscle tenderness
- Clicking or popping noise in TMJ
- Limitation of jaw function or deviation on opening



- Absence of clinical, rad. or biochemical change
- Lack of tenderness on pal. Thru' EAM

# FACTORS

1. Para functional habits (eg, nocturnal bruxing, tooth clenching, lip or cheek biting)
  - may be initiated by dental irritation
2. Emotional distress (anger, anxiety, depression)
  - Oral habits that cause structural damage or periodontal disease
3. Acute trauma from blows or impacts
4. Trauma from hyperextensor oral intubation for general anesthesia (e.g., during surgery, etc.)




# FACTORS

## 5. Instability of maxillomandibular relationships

- Bilateral loss of posterior teeth
- Faulty complete & P.D's
- Malocclusion

## 6. Laxity of the joint

- Hypermobility
- Steep angulations of eminence



## 7. Presence of other rheumatic or musculoskeletal disorders

- Deg. Arthritis- cont. jaw func, with condyle in abnormal position

## 8. Poor general health and an unhealthy lifestyle

diet, sleep, alcohol, smoking, overwork

# Management

## Education & information

- Explain source of pain and varied nature of symptoms
- Patient to give attention to activities like tooth clenching, jaw posturing, jaw tooth tensing
- Habit reversal, jaw relaxing


## Physiotherapy

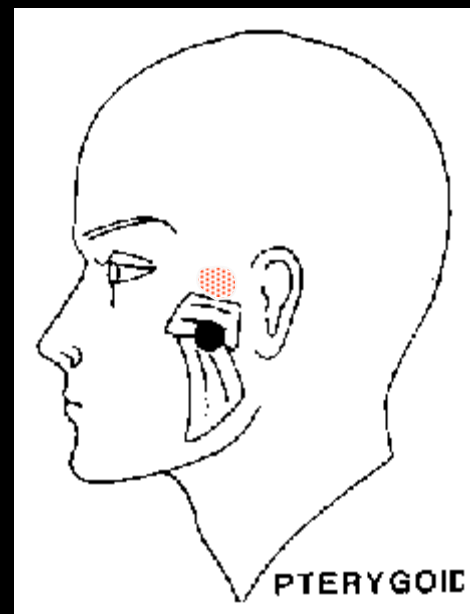
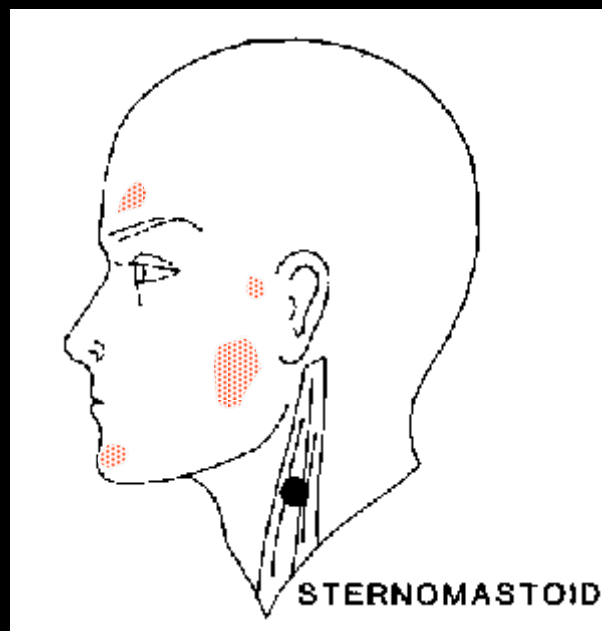
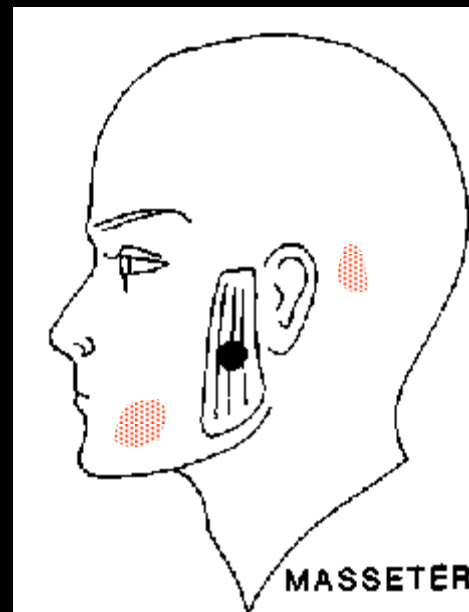
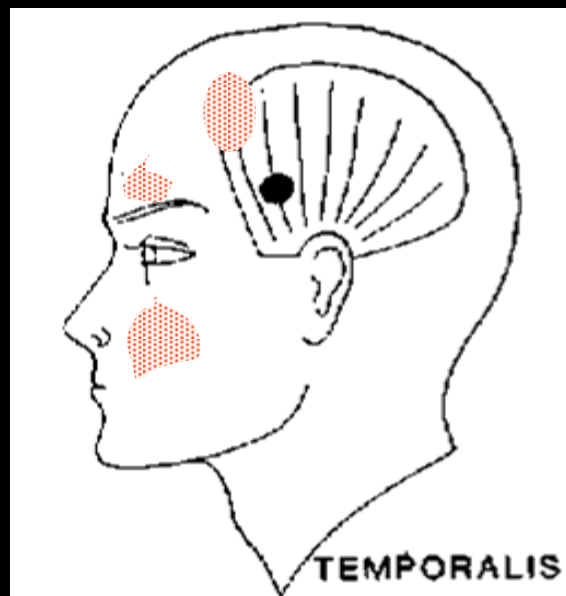
- Active and passive
- Postural therapy

# Management

## Physical

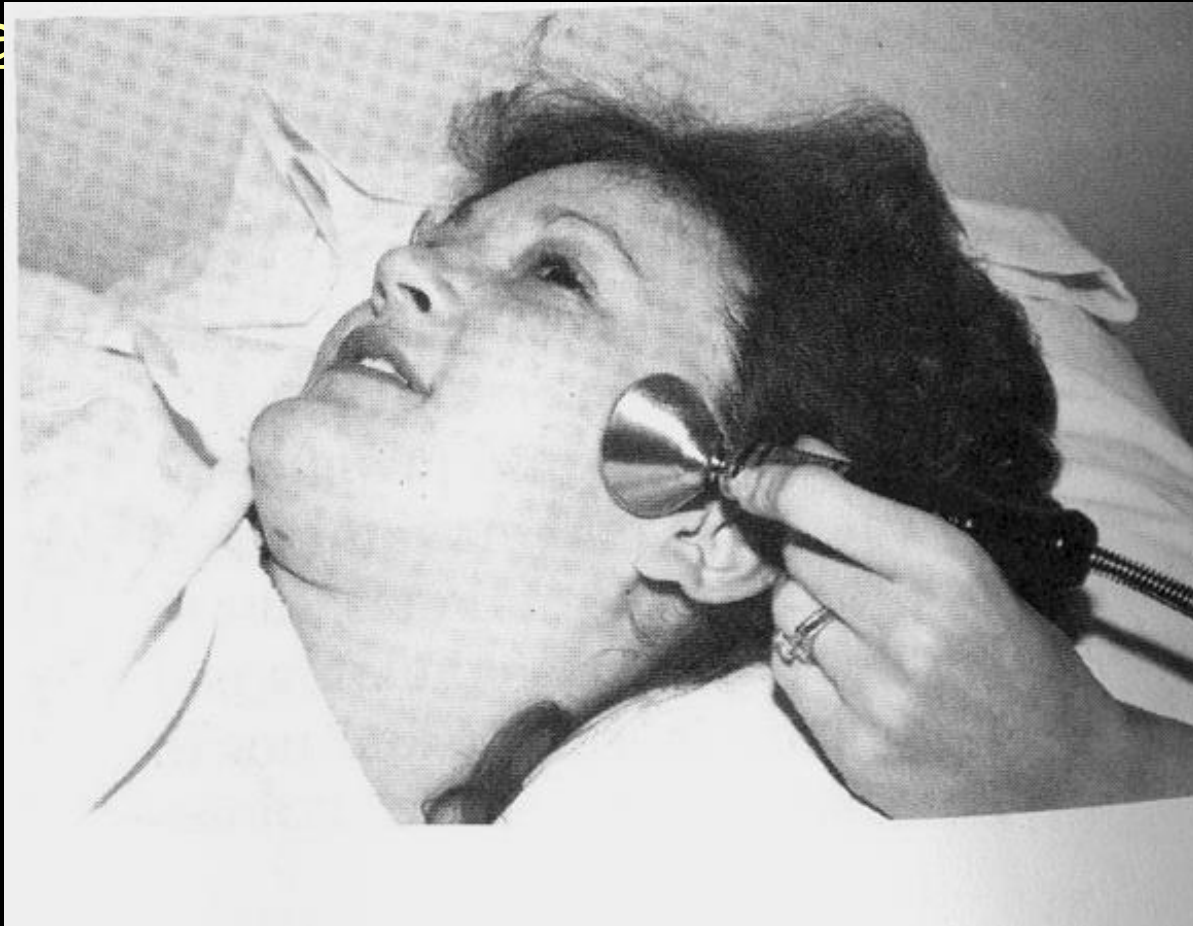- Warm to hot compresses
- Limit opening mouthfuls, so
- Aspirin and c
- Injecting trig muscles in sp without adre spasm
- Acupuncture





# Management

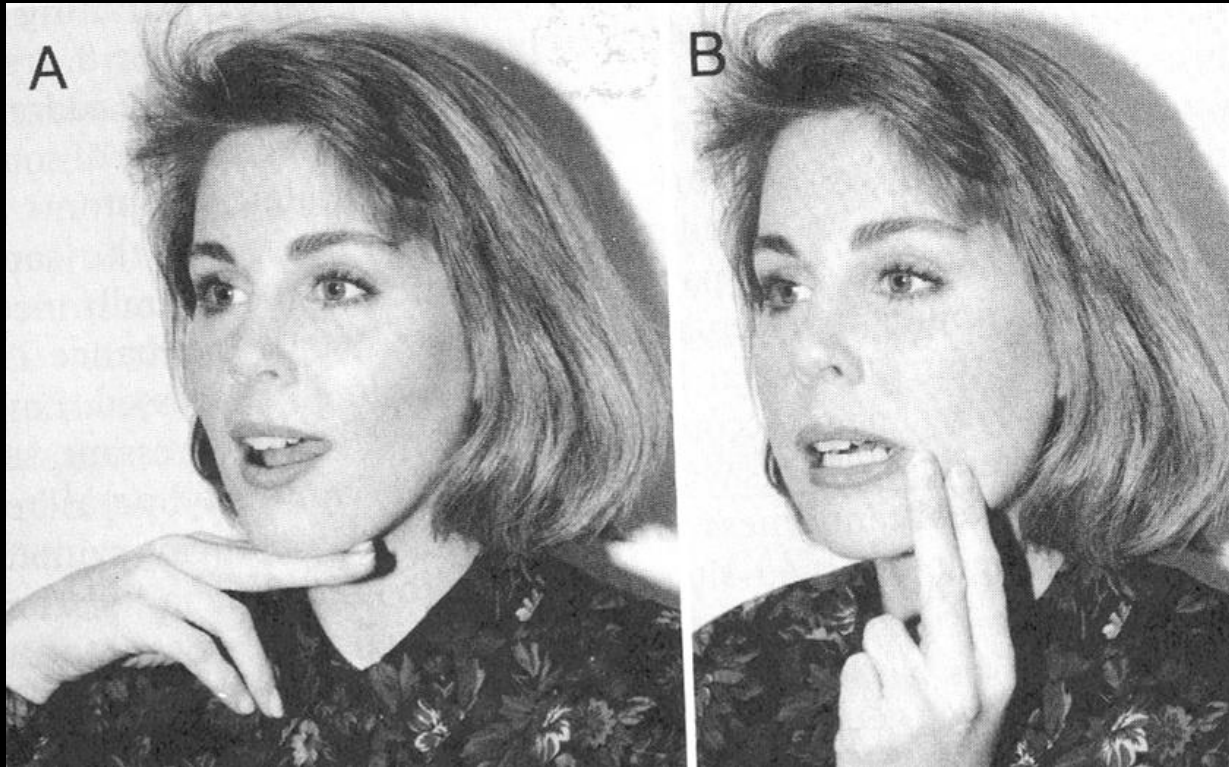
Ultra



High frequency oscillations → Heat

# Management

## Isometric jaw exercises



# Management

## TENS



Sensory counterstimulation

# Management

## TENS

### Neurologic

(Gate Control theory)

- C fibers blocked
- A fibers - light touch sensation

### Physiologic

Rhythmic muscle movement

- ↑ circulation
- ↓ edema
- ↓ resting muscle activity

### Pharmacologic

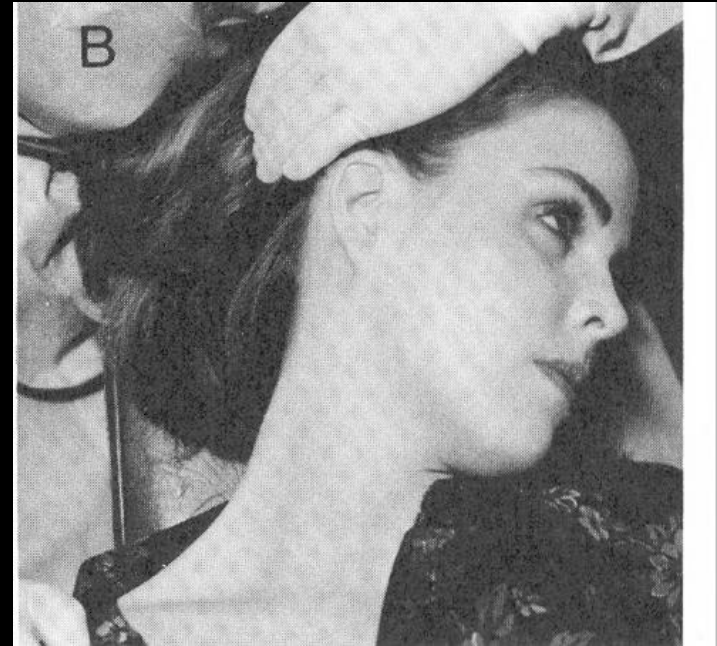
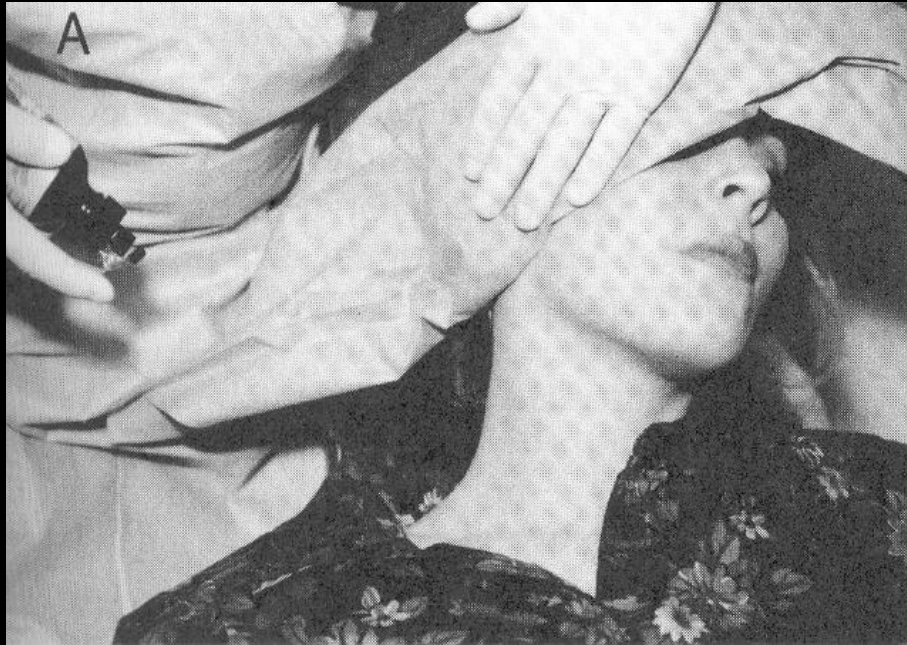- Stimulated release of endorphins

### Psychologic

Placebo

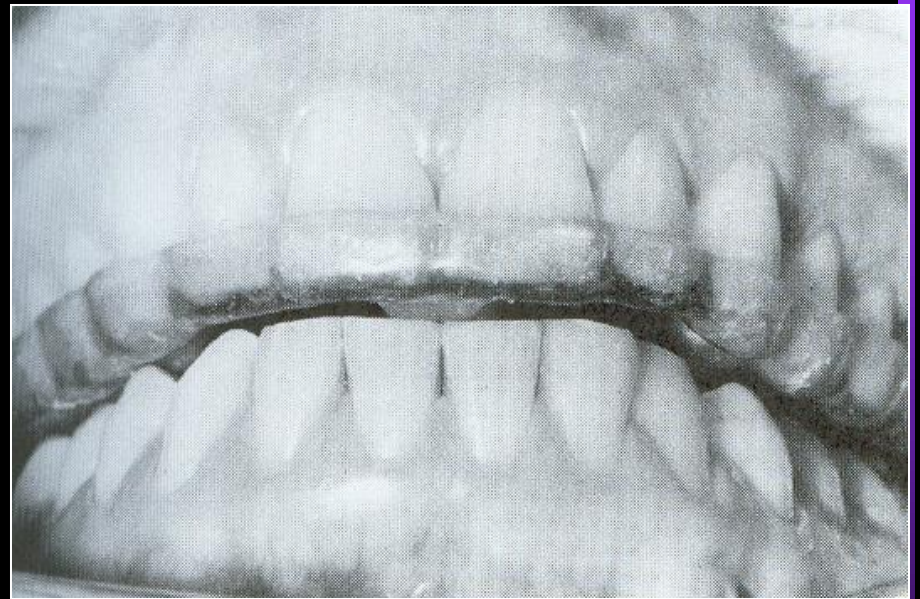
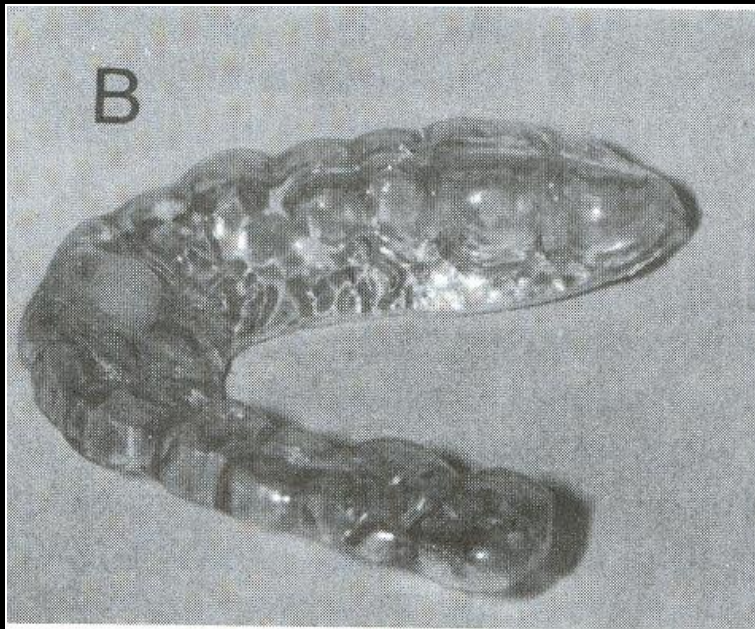
# Management

## Spray and stretch technique




# Management

## Occlusal splint



# Management Biofeedback



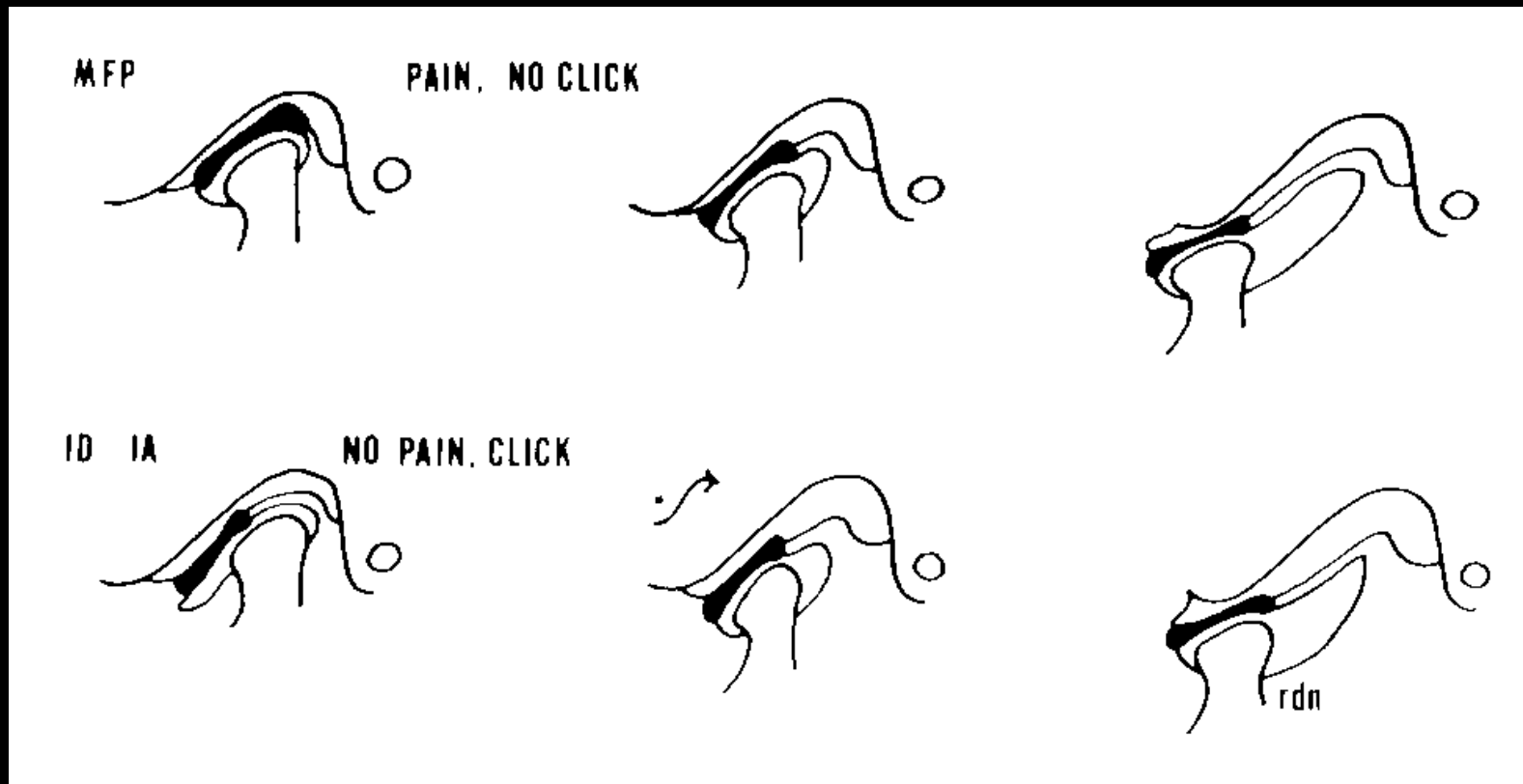
# Management

## Pharmacotherapy

- Mild analgesics, nonsteroidal anti-inflammatory drugs (NSAIDs)
- antianxiety agents, tricyclic antidepressants
- muscle relaxants

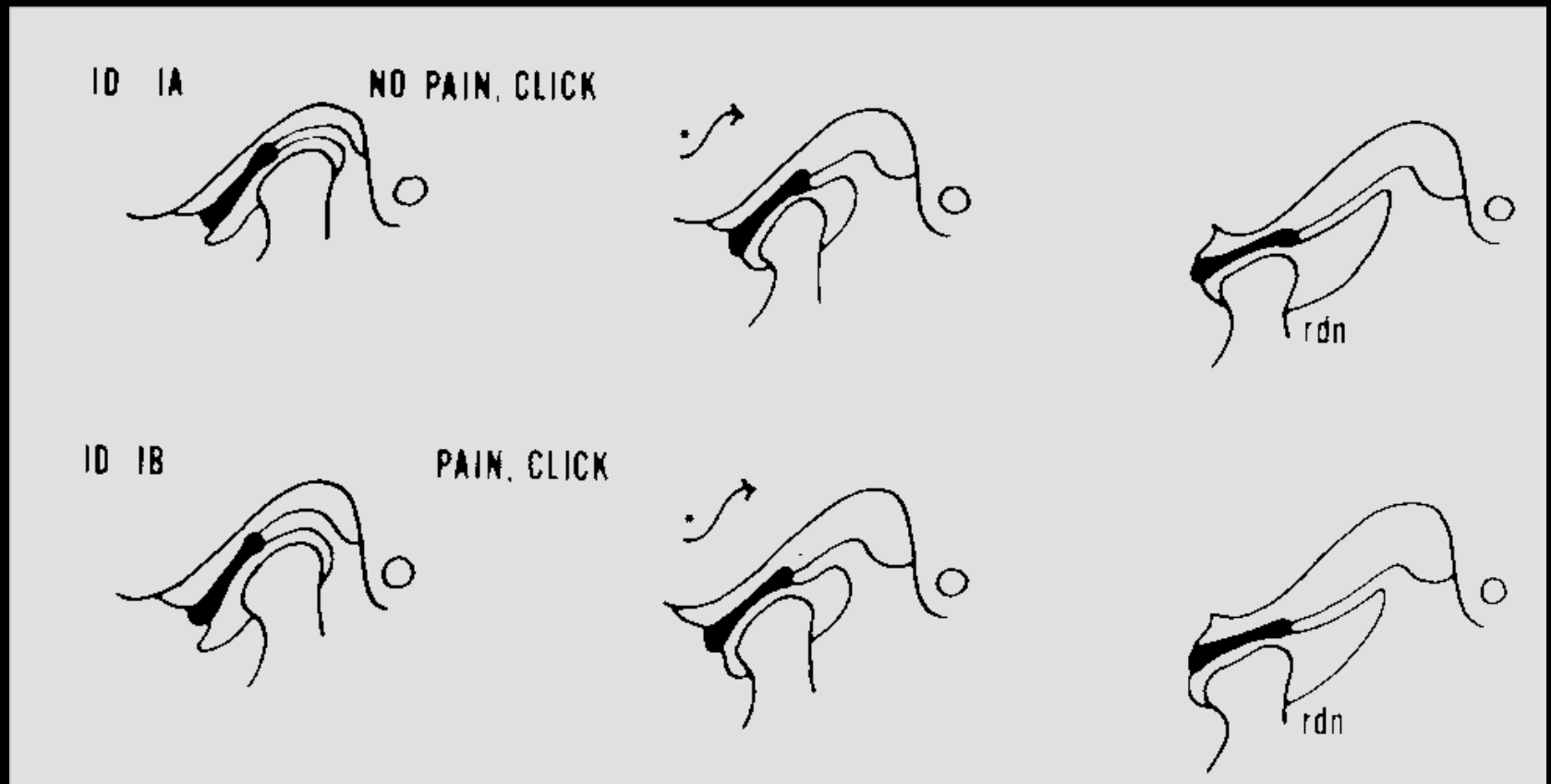
# Internal Joint Derangement

Derangement of normal disc-condoyle relationship



# Internal Joint Derangement

Derangement of normal disc-condoyle relationship



## Internal Joint Derangement

Derangement of normal disc-condoyle relationship

### Type I

Anterior displacement  
of disc with clicking



Without pain – Type I A

With pain – Type I B

- Constant dull ache in joint area, usually unilateral
- No H/o locking
- Concurrent myospasm with trigger point tenderness of masticatory or strap muscles ( I B)

## Internal Joint Derangement

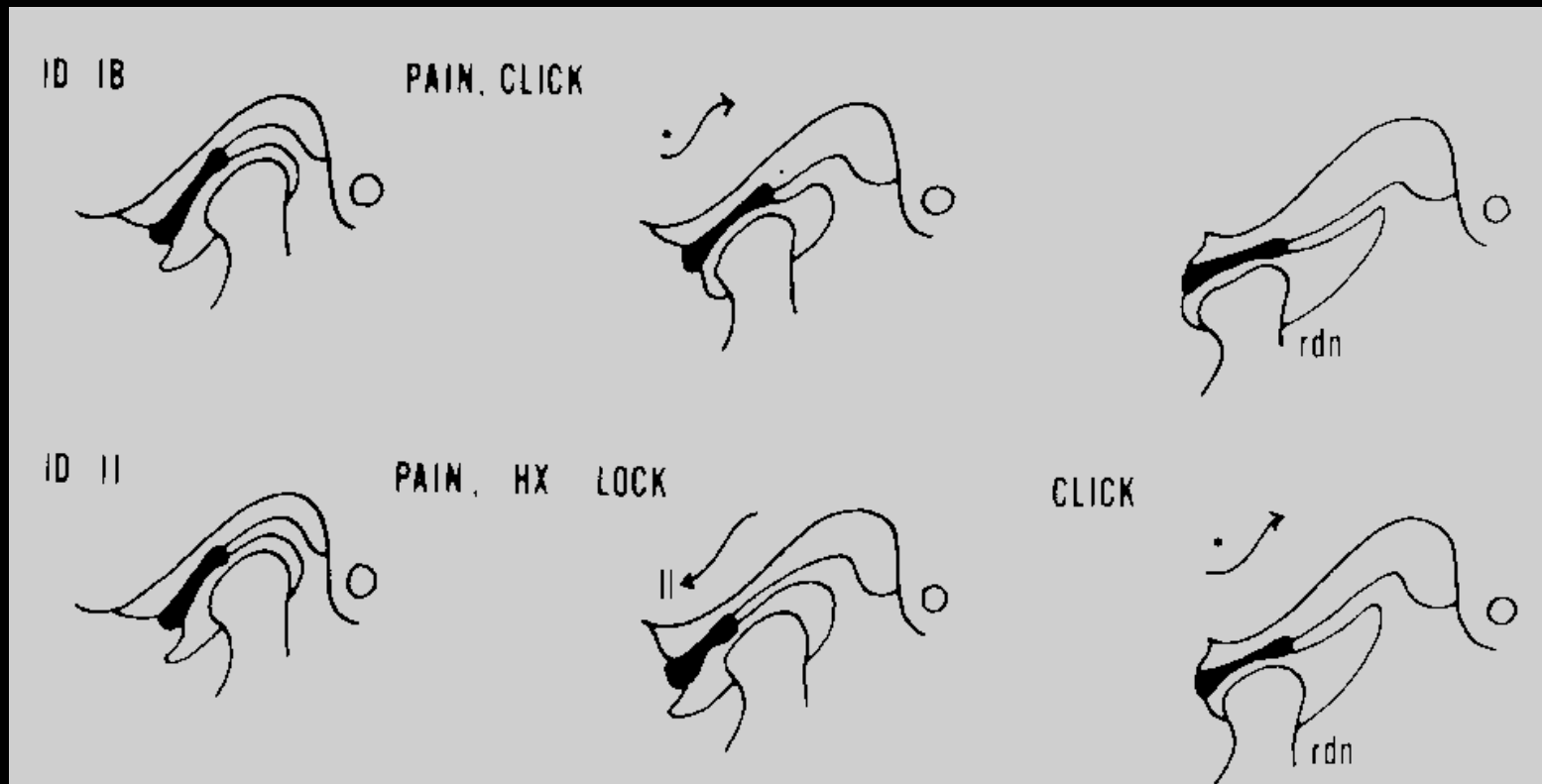
Derangement of normal disc-condoyle relationship

### Management – Type I

- Splint therapy + muscle relaxation + stress management
- E M G to investigate myospasm
- Occlusal equilibration if necessary

# Internal Joint Derangement

Derangement of normal disc-condoyle relationship



# Internal Joint Derangement

## Type II

Anterior displacement of disc with clicking and H/o locking

- Retrodiscal tissues have been overdistended
- Meniscus cannot be positioned over condyle head

## Clinical features

- Transient open 'lock'
- Transient closed 'lock'

# Internal Joint Derangement

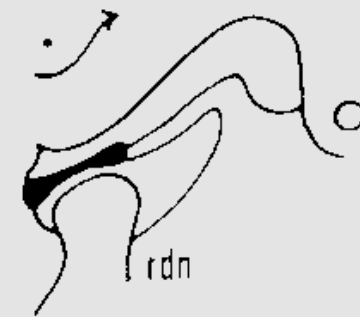
## Type III

ID II

PAIN, HX LOCK

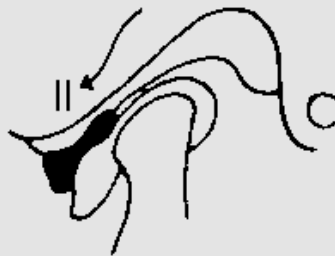

CLICK



ID III

PAIN, LOCK



NO CLICK

no rdn

# Internal Joint Derangement

## Type III

Disc is displaced forward

- Not possible to reposition disc over condyle

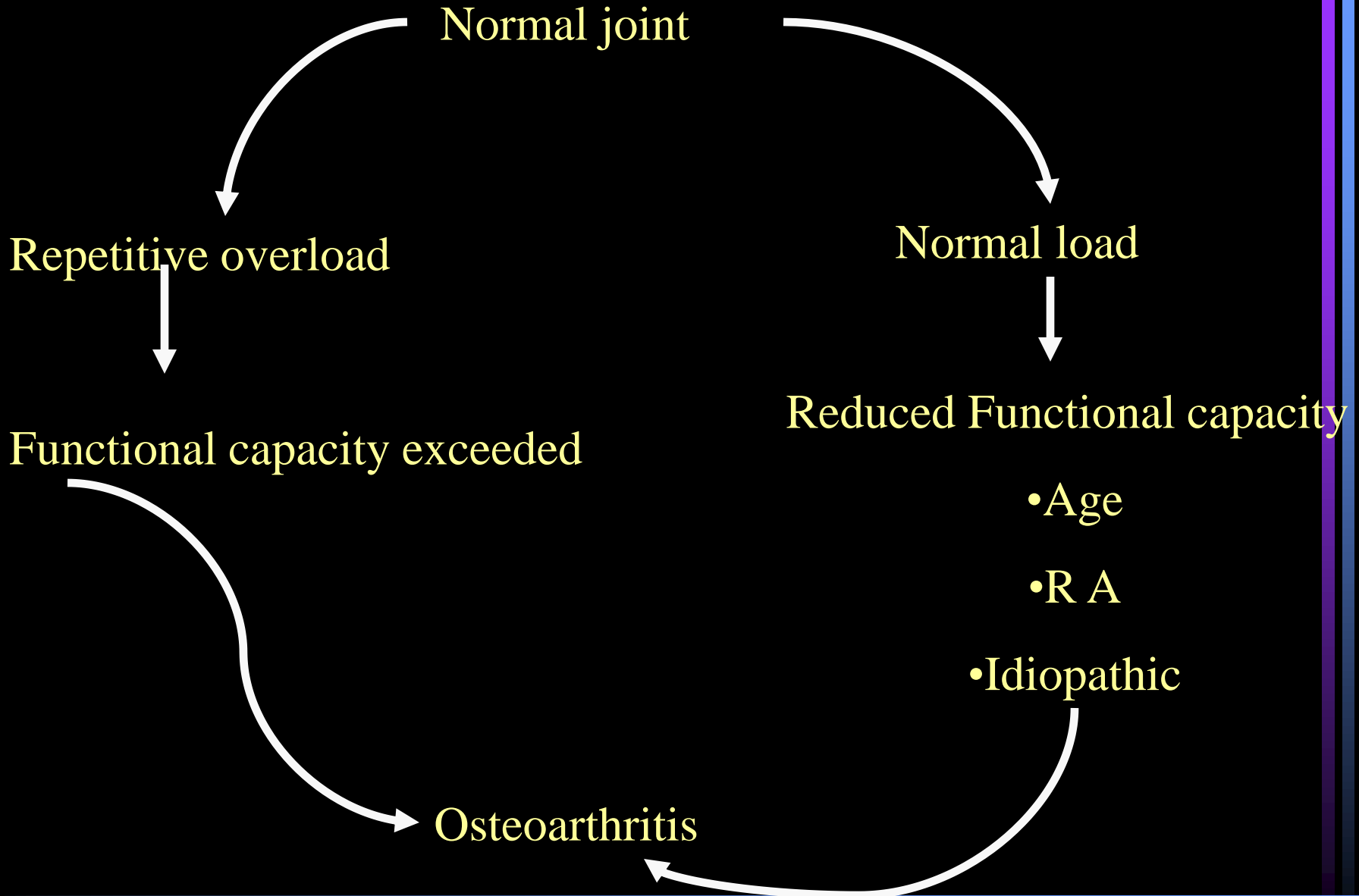
## Clinical features

- Locking with pain
- Average jaw opening is 20 m.m

## Management

Meniscus reattachment surgery

# Osteoarthritis



## Osteoarthritis

50% of patients > 40 years, 85% > 70 years

Symptoms if present

- Unilateral pain over joint
- Joint sensitive to palpation
- limited opening
- Crepitus
- Deviation of jaw towards affected side
- Stiffness in jaw as day wears on

# Osteoarthritis

## Pathogenesis

Initial destruction of soft tissue



Subsequent erosion



Hypertrophic change in bone

Connective tissue wear



Disc breaks down



Bone surface resorption



Underlying bone sclerotic

# Osteoarthritis

Normal



Loss of cortical outline



Erosion



Remodeling

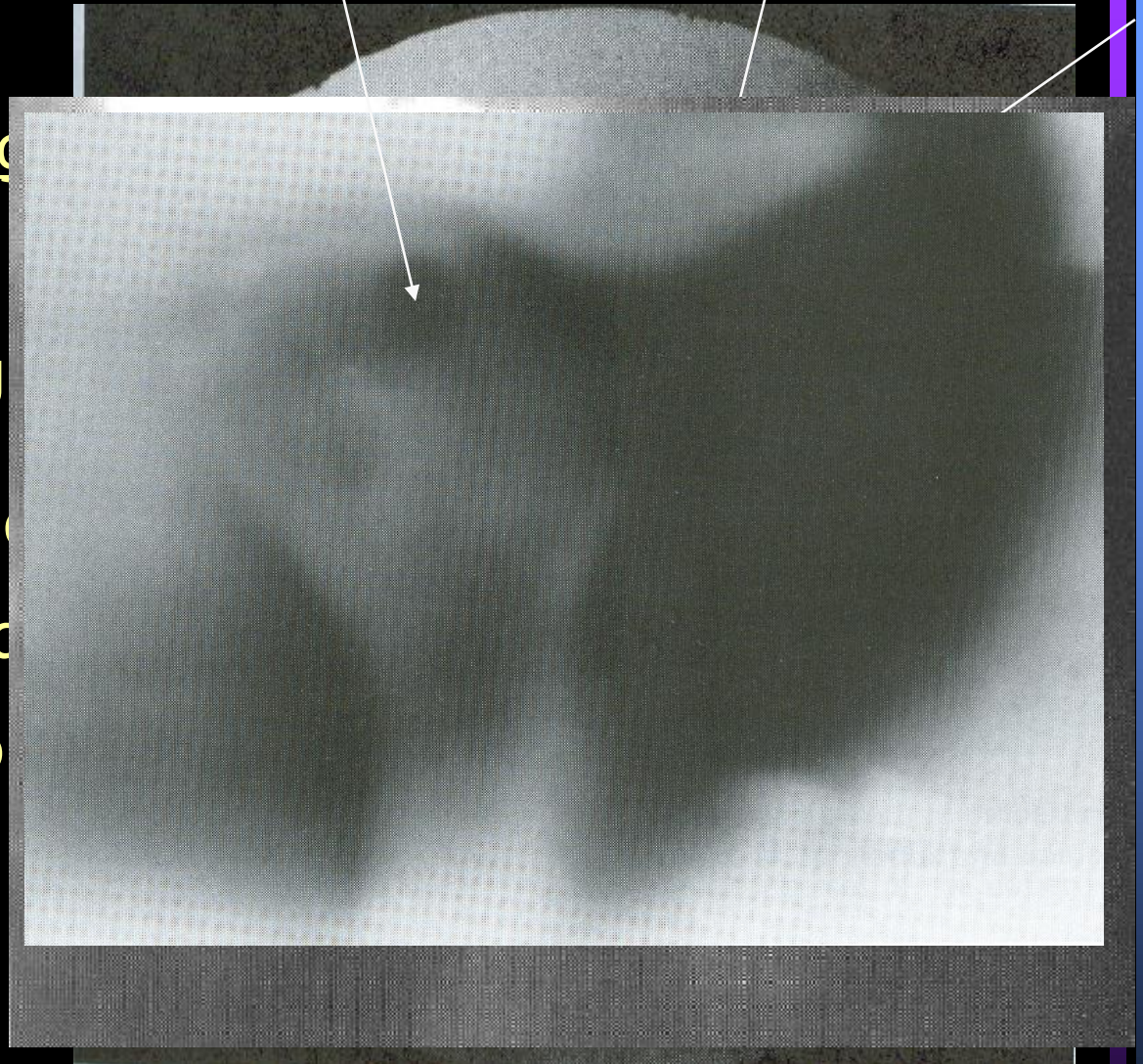


Destruction

# Osteoarthritis

## Radiographic changes

- Loss of bone
- Erosion with irregular margins
- Eminence flattened
- Condyle flattened
- Lipping on anterior surface
- Osteophytes
- Ely's cysts
- Narrowing of space, disk thinned



## Osteoarthritis

Progression of  
osteoarthritis



- Further narrowing of joint
- Limitation of motion

## Trauma

- Condoylar head / neck
- Pain, edema in joint area
- Limitation & deviation to injured side on opening
- Bilateral condoylar #
  - open bite



Radio. examination – change only if displacement

- Towne's, panoramic, Lat. Oblique, Transorbital

## Dislocation

Condoyle forcefully dis

### Etiology

- Wide yawning
- Dental procedure
- Trauma, rarely

### Clinical features

- Patient in wide mouth open condition
- Pain on attempting to close
- Patient comes to dentist in open mouth condition



## Dislocation

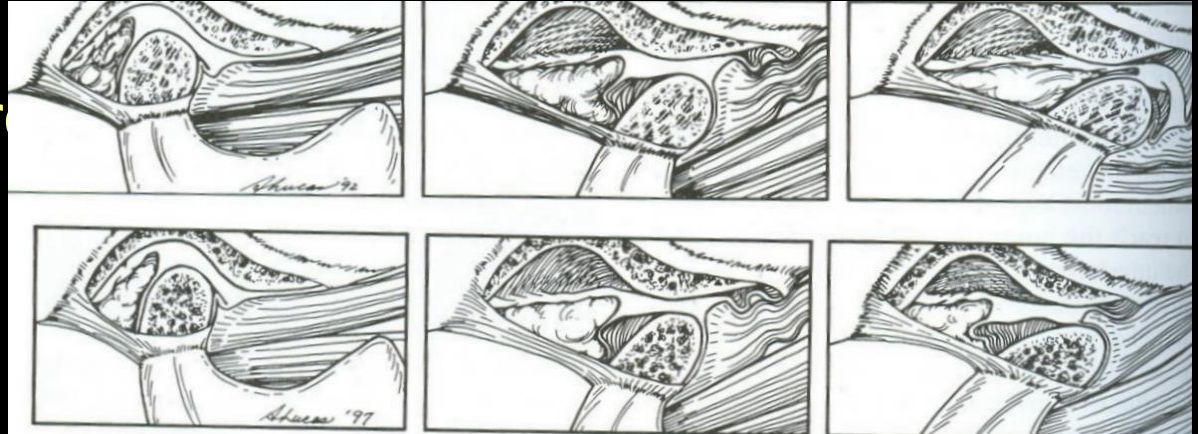
Condyle for

### Etiology

- Wide yawning
- Dental procedure
- Trauma, rarely

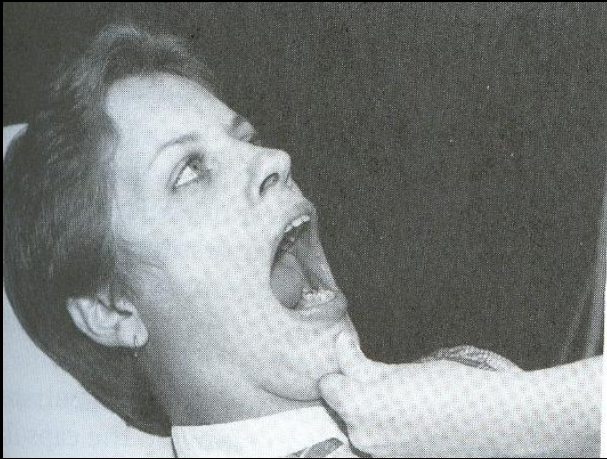### Clinical features

- Patient in wide mouth open condition
- Pain on attempting to close
- Patient comes to dentist in open mouth condition

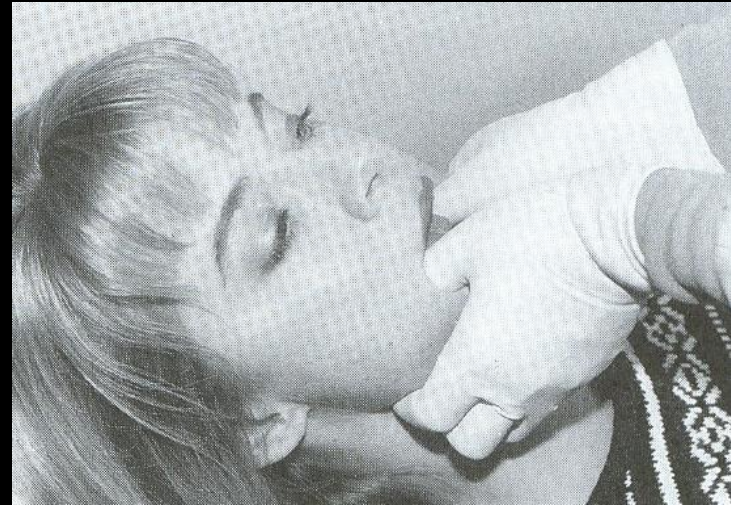


# Dislocation

## Management



Slight posterior pressure to the chin + patient tries to **open** ?



Downward force on the molars, upward pressure on chin

## Infectious arthritis

Haematogenous spread of gonococci

Direct extension of middle ear infection

### Clinical features

- Redness and swelling over joint
- Severe pain when joint moved
- Inability to place teeth in occlusion
- Large tender cervical lymph nodes

# Rheumatoid Arthritis

Polyarthritits – common in women over age 40 years

Radiographic and clinical signs in other joints before TMJ

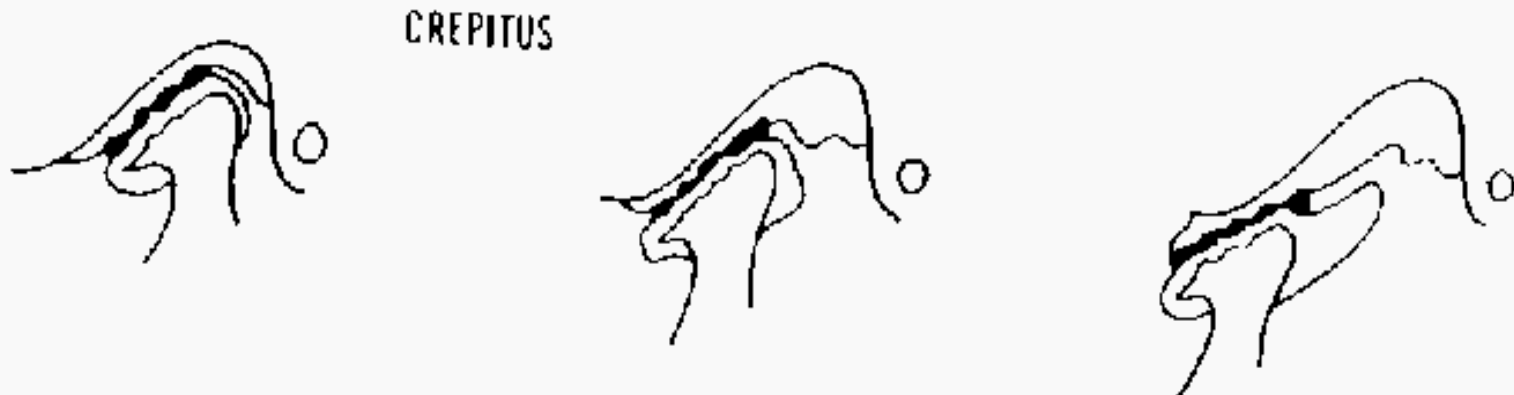## Clinical features

- Bilateral stiffness, more in the morning, ↓ with day
- Crepitus, tenderness, swelling over joint

# Rheumatoid Arthritis

## Radiographic Features

- Flattening of head of condyle
- Erosion, reduced mobility of condyle
- Condylar outline ragged & irregular
- Severe Condyle- completely resorbed-ant.open bite



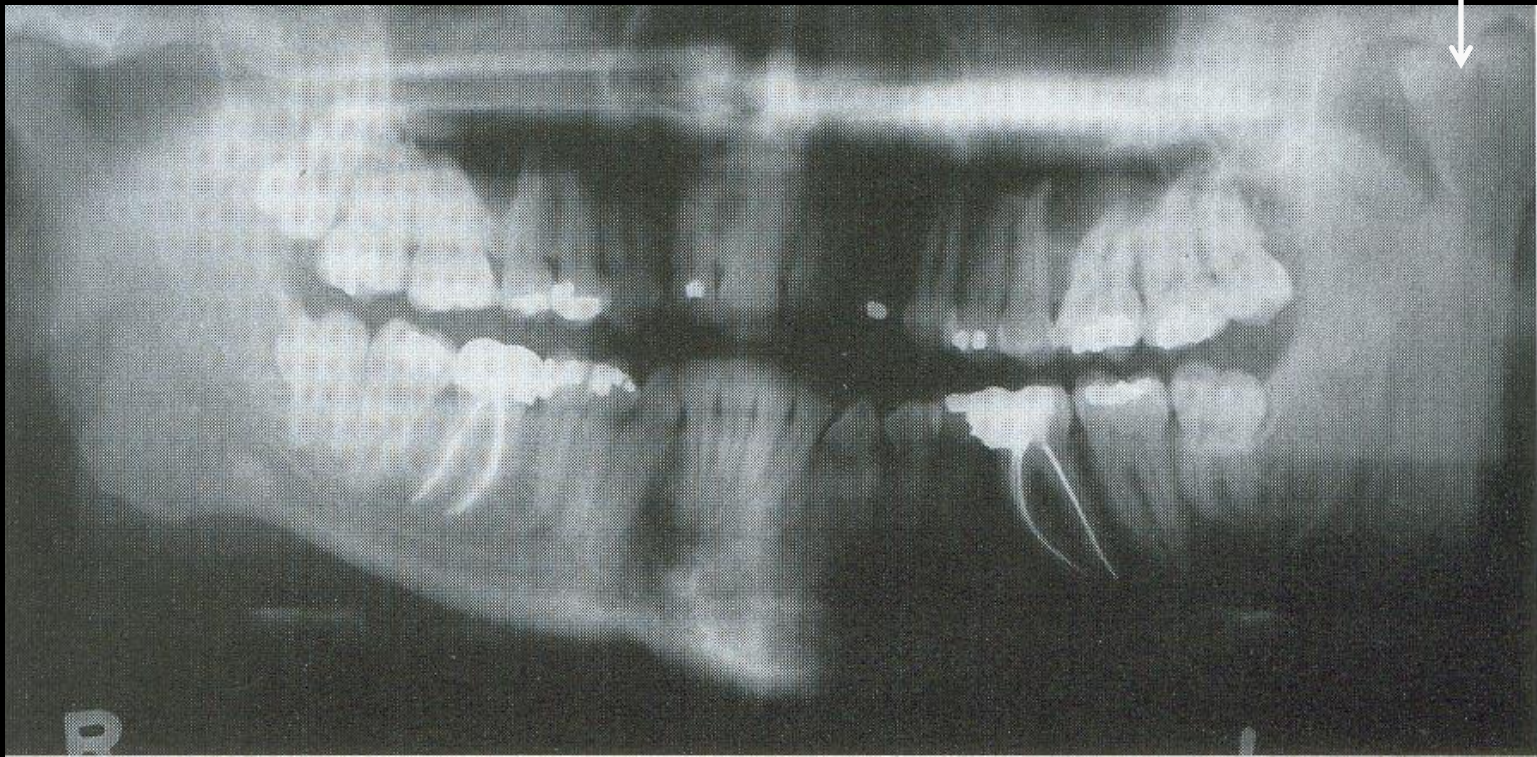


# Ankylosis

If ankylosis before completion of growth

- Mandibular assymetry
- Reduction in length of body and ramus
- Prominent antegonial notch

## Condoylar hyperplasia



Facial assymetry with deviation to opposite side

# Neoplasia

## Benign

- Osteoma, osteochondroma, chondroma, benign giant cell lesion

## Clinical features

- Facial asymmetry
- Malocclusion
- Prognathic deviation of mandible to opposite side

## Malignant

- Primary malignant tumors- chondrosarcoma, synovial sarcoma
- Direct extension of parotid or other regional carcinomas

**THE END**