

# MIDFACE TRAUMA

**DR. ANAGHA**



# **RADIOLOGICAL ASSESSMENT OF MIDFACE TRAUMA**

## **Radiological assessment- diagnostic challenge**

- Complex nature of normal facial radiographs
- Patient un-cooperation
- Failure to correlate clinical & radiographic findings
  
- Combination of plain, tomographic, panoramic, zonographic & CT correlations
  
- Pre-radiographic assessment

- 4 “**S**” approach by **Delbalso-**
- **S**ymmetry
- **S**harpness
- **S**inus
- **S**oft tissues

- 3 absolutely essential views-

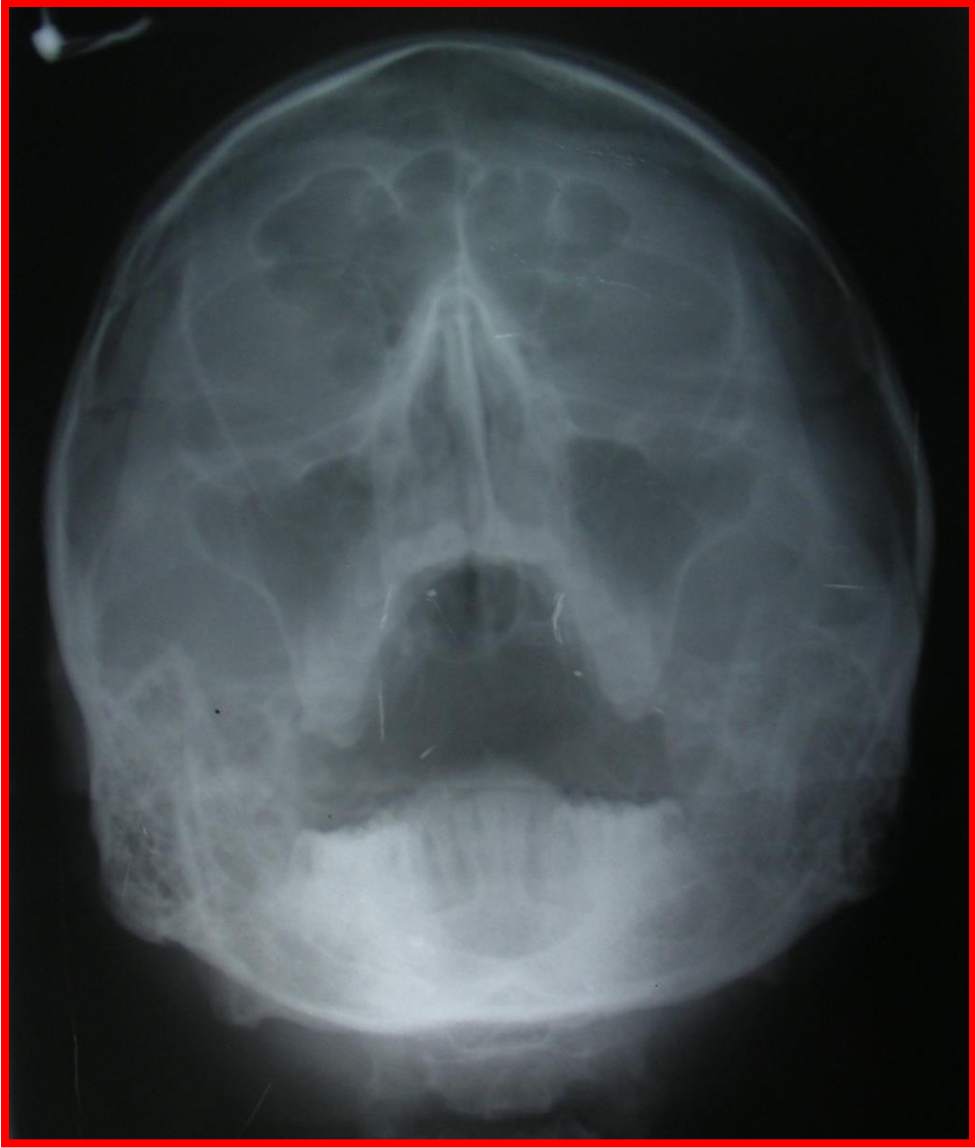- 1. PA Water's view
- 2. PA Caldwell view
- 3. Lateral view

- Additional views-

- SMV
- Towne's view
- OPG
- Nasal bone & mandibular series etc.

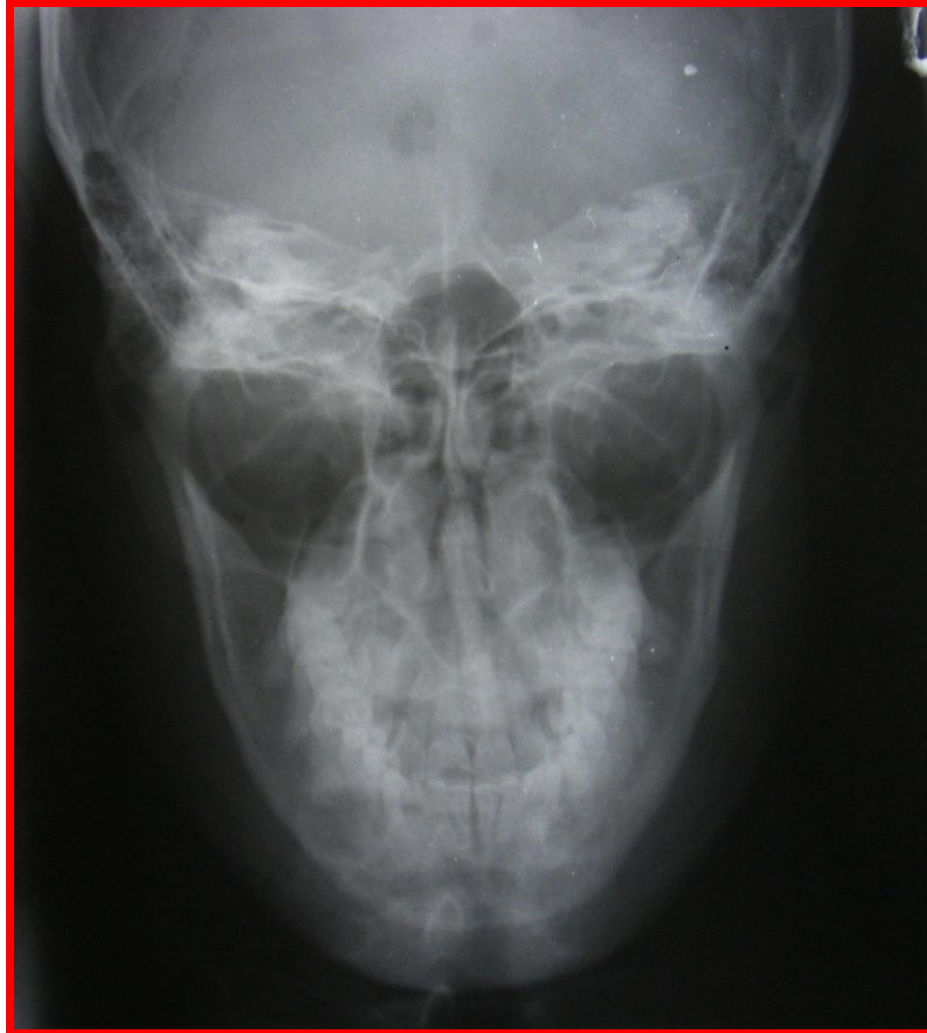
# PA WATER'S VIEW

- Projection details
- Frontal view
- Provides best demonstration of maxillary sinus & anterior facial structures
- *Potter & Gold*- usefulness in assessment of zygoma, orbital rims, nasal bones, anterior lamina papyracea, ethmoidal air cells & maxillary sinuses
- Best demonstrates maxillary line- starting point for evaluation of Water's view

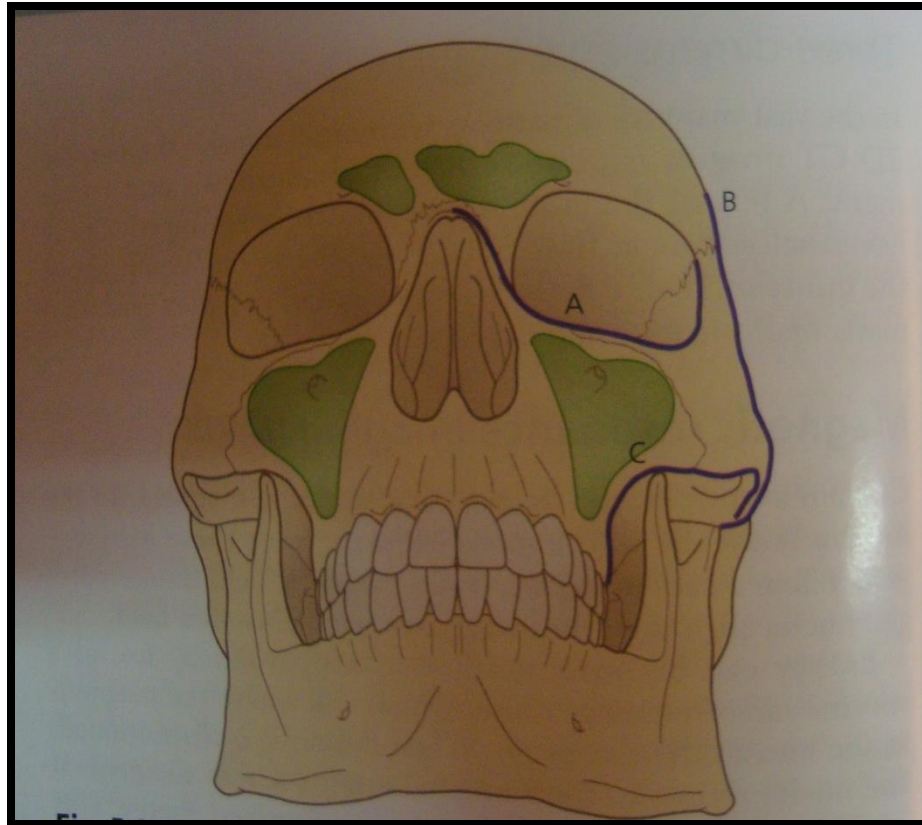


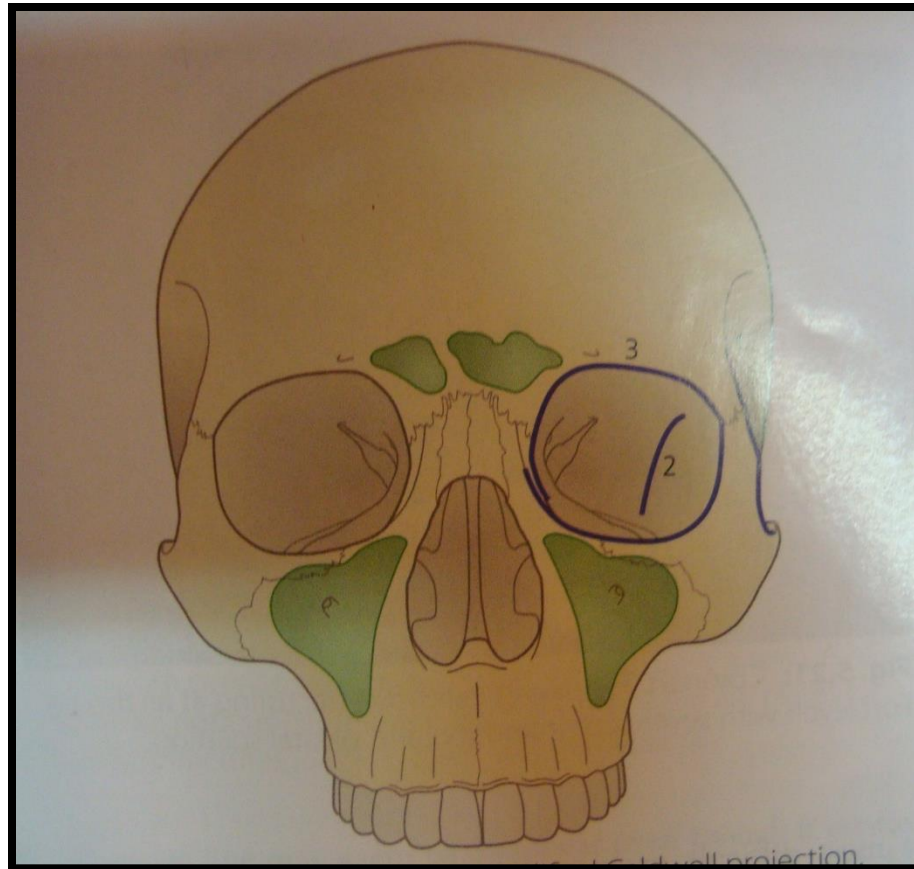
# CALDWELL VIEW

- Projection details
- Frontal view
- Best demonstrates orbits & posterior and middle facial structures
- *Potter & Gold*- projection of choice in evaluation of frontal & ethmoidal sinuses and nasal fossa
- Provides best visualization of orbits & their osseous components, frontal bones & sinuses, nasal fossa, pyriform aperture, posterior portion of lamina papyracea & ethmoidal air cells and posterior orbital floors
- Well demonstrates zygomatic and orbital lines

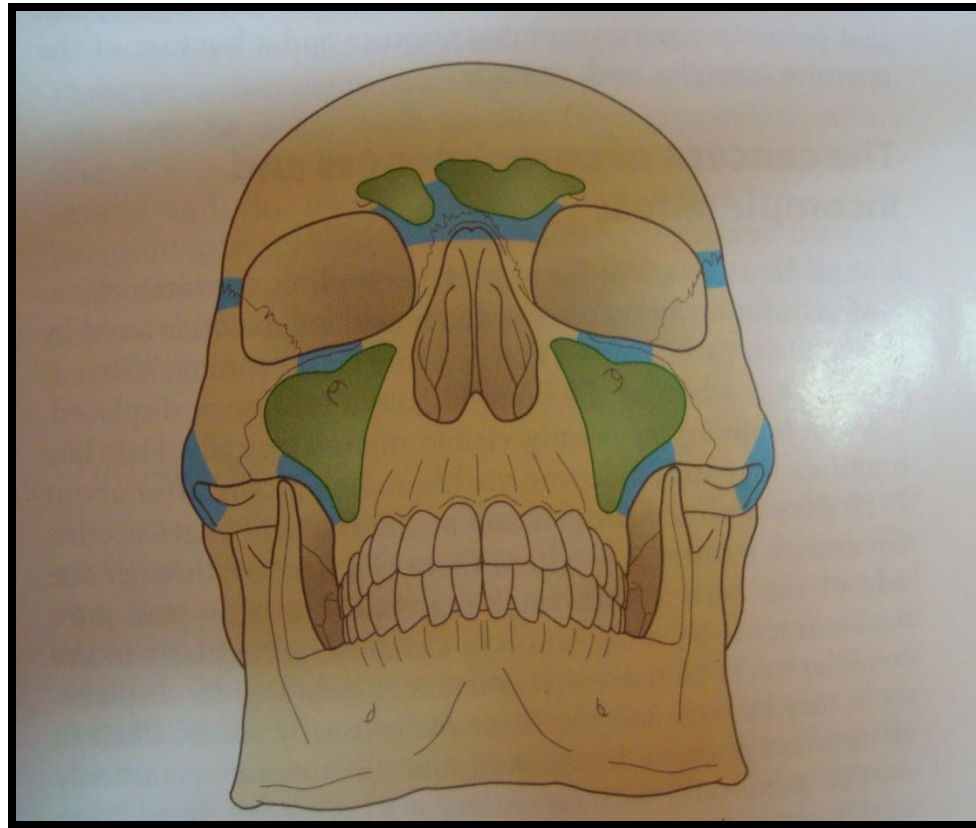


- **Dolan & Jacoby**- 3 lines that facilitate evaluation of zygoma, orbit, nose & major segments of zygoma on Waters & Caldwell views-
- Maxillary line
- Zygomatic line
- Orbital line
- Best views for the lines





# HOT AREAS

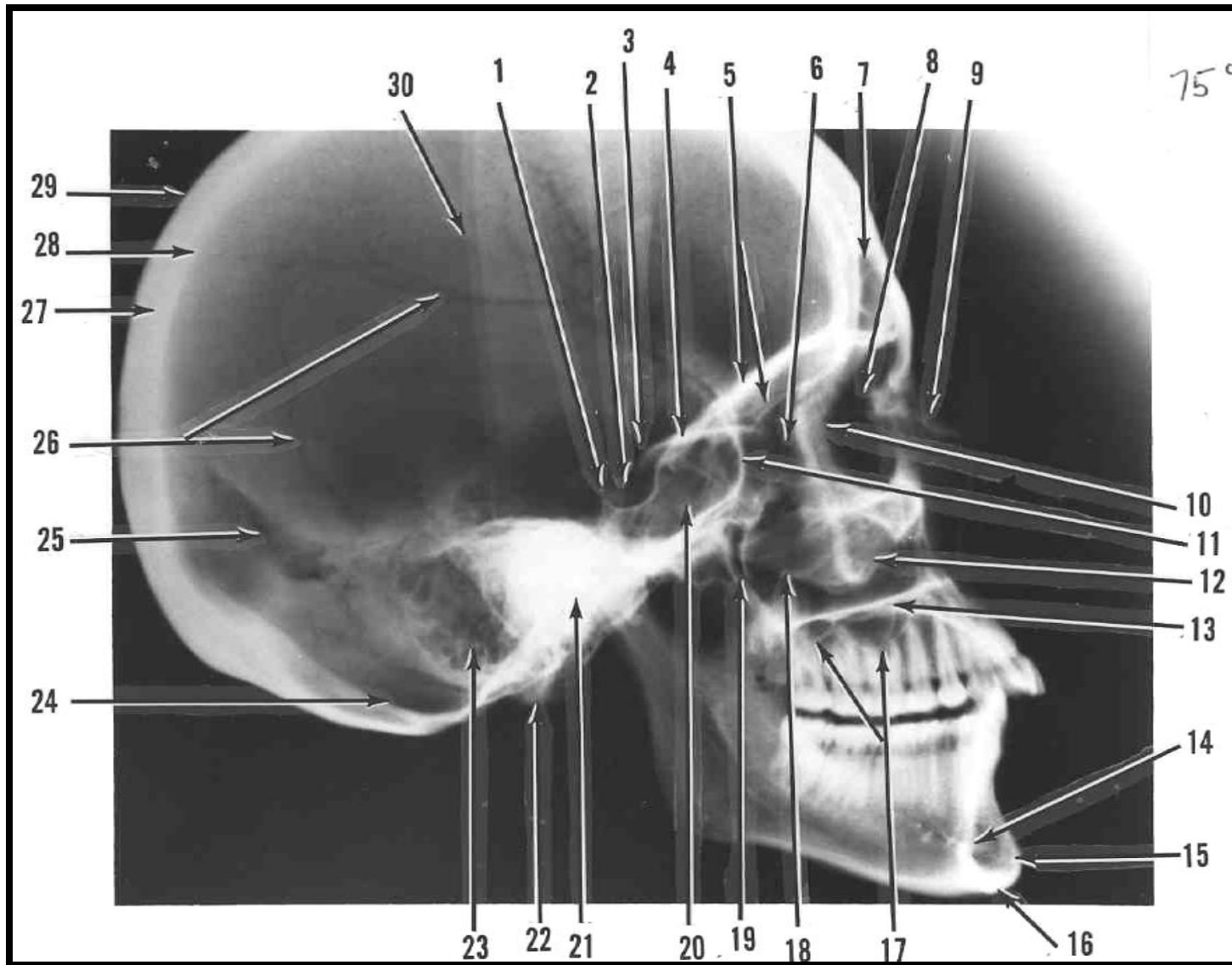


## • **EVALUATION OF RADIOGRAPHS**

- It should start laterally & proceed medially in a systematic fashion.
- Check for 4 “S”.
- Maxillary line –zygomatic line– orbital line
- Evaluate maxillary sinuses for 4 “S”.
- Thorough examination of mandible & TMJ region
- Non-displaced, minimally displaced & displaced fractures

# LATERAL VIEWS

- Projection details
- Should be obtained with the most traumatized side closest to the film to enhance detail & minimize distortion
- Important in evaluation of anterior & posterior walls of frontal sinus, anterior walls of maxillae & pterygomaxillary region
- Starts with examination of cervical segment-cervical fractures, patency of airway, radiopaque foreign bodies

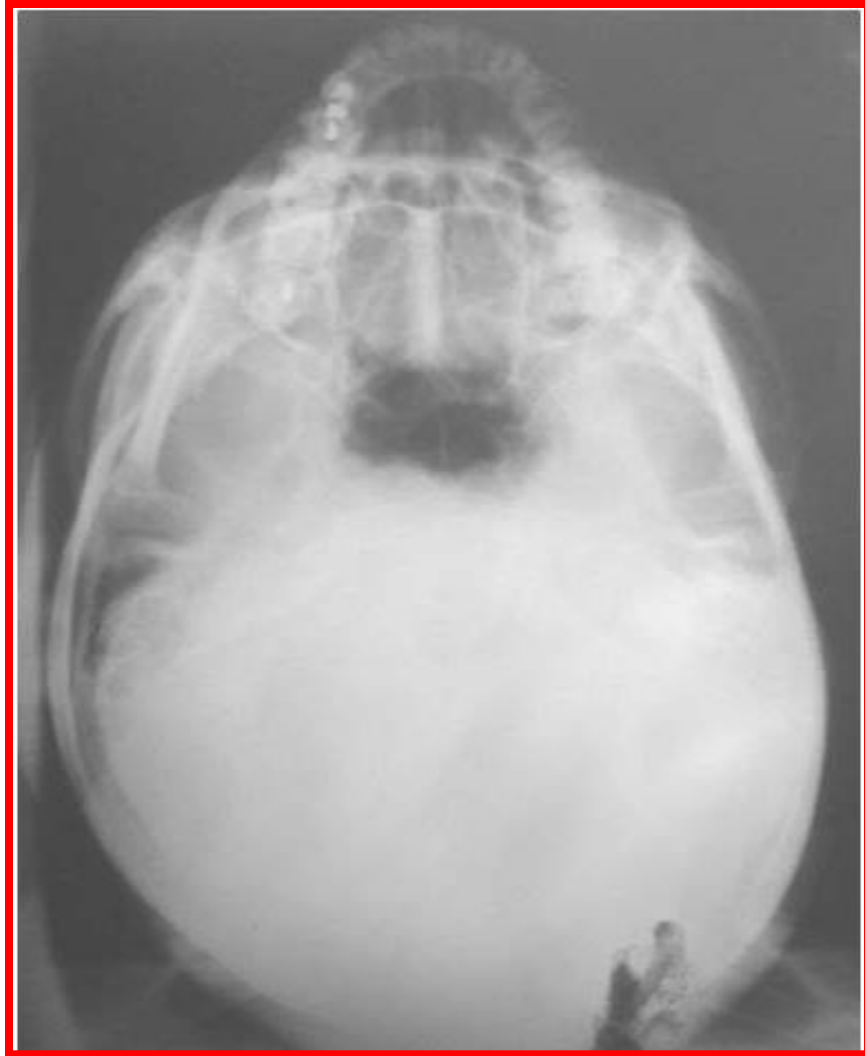

- Importance of open bite- only definite radiographic sign of non- or minimally displaced midface # as Le-Fort I
- Posteriorly along occlusal plane- pterygomaxillary buttresses
- Represented by pterygoid plates & posterior walls of maxillary sinuses
- Normal appearance & changes

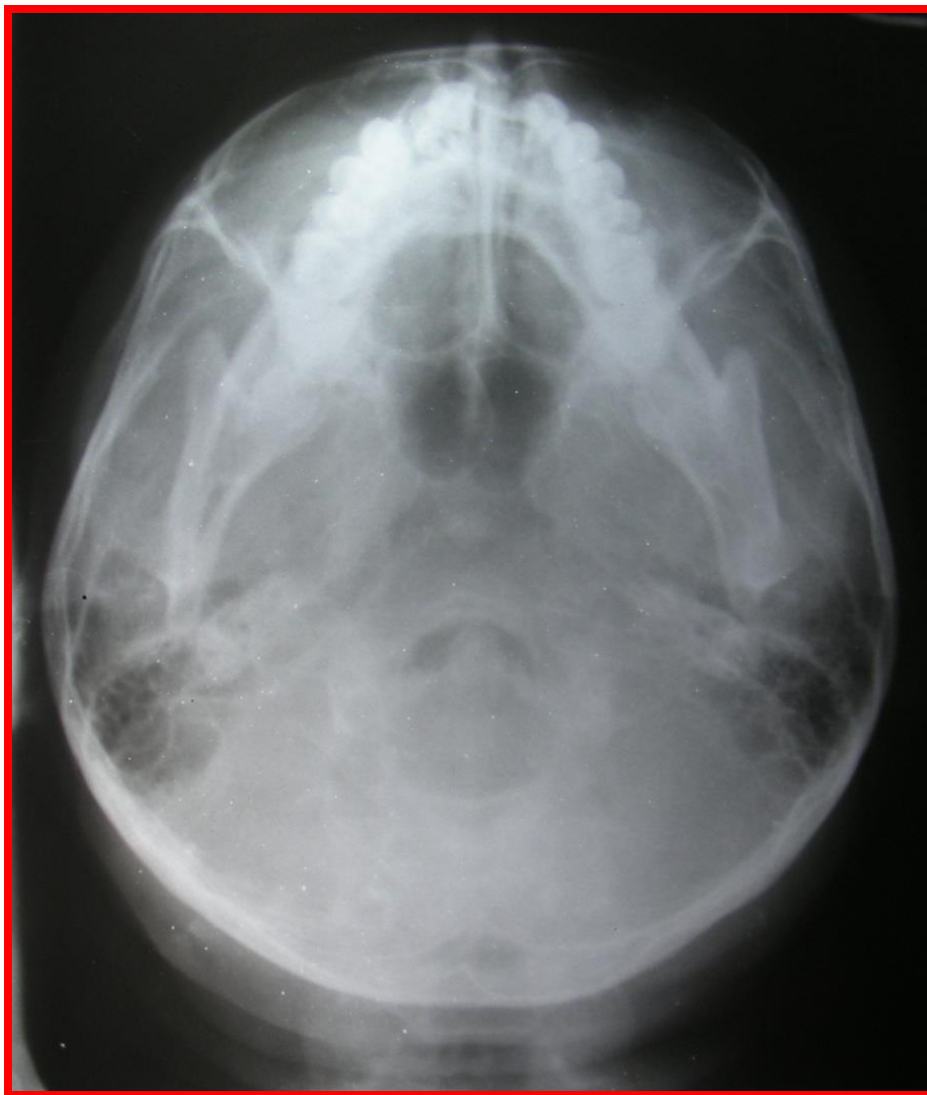
- Superiorly to level of planum sphenoidale & orbital roofs
- Forward to posterior wall of frontal sinus
- **Check for-**
  - Air-fluid level in sphenoid sinuses
  - Pneumocephalus
  - #s of planum sphenoidale, orbital roofs, walls of frontal sinus
  - Intraorbital air
  - Soft tissue abnormalities

# SMV

- Taken in prone / upright position
- **Underexposed view (bucket-handle, jug-handle)**
- # s of zygomatic arch
- lateral or medial displacement of #s of nasal bones
- #s of anterior wall of maxillary sinus

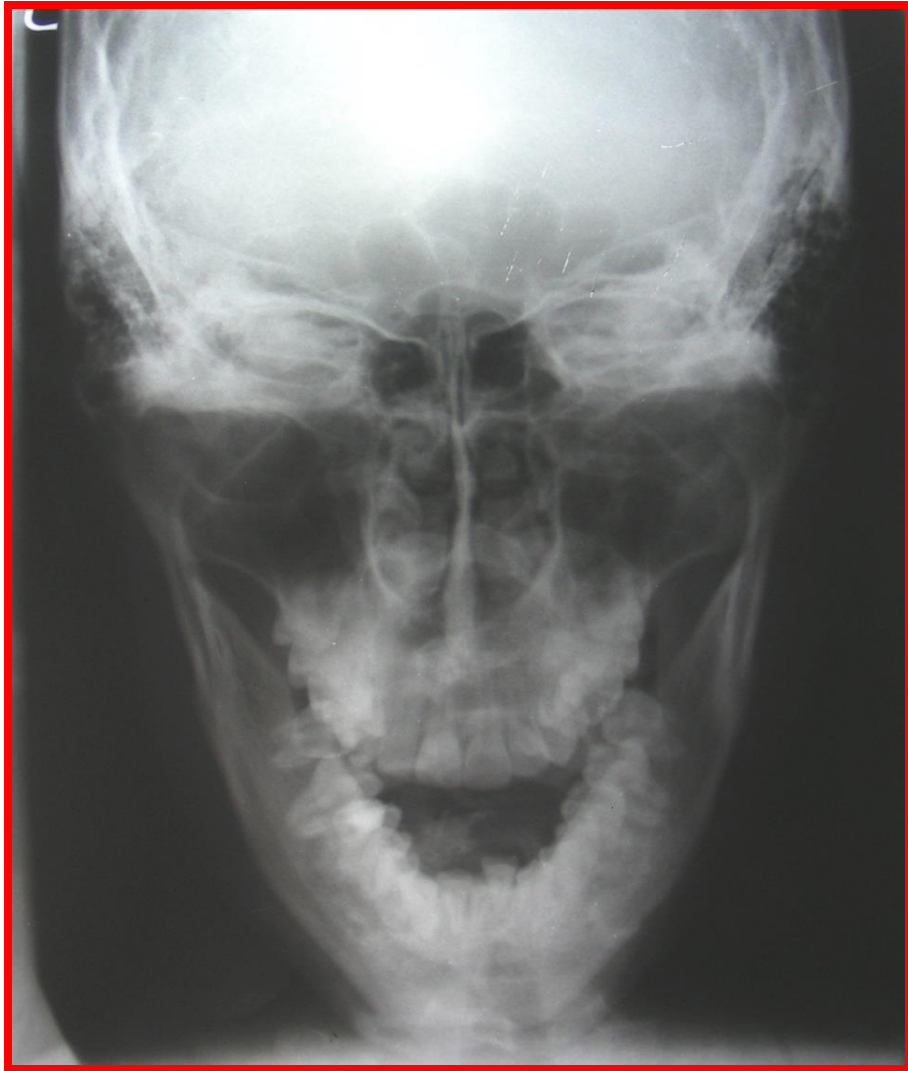

- **Penetrated view-**
- Lateral orbital walls
- Anterior & lateral walls of maxillary sinus
- Sphenoid surface of temporal fossa
- Only projection that optimally demonstrates sphenoid sinuses individually



# TOWNE'S VIEW

- Projection details
- Useful in assessment of basilar skull structures, especially mastoid air cells
- Important in evaluation of subcondylar #s
- Orbit- inferior orbital fissure (floor)
- Additional projection of maxillary sinuses, inferior orbital rims
- Rotation & posterior displacement of inferior orbital rim & tripod #s



# FRACTURES OF FACIAL SKELETON

- **Divided as-**
- Isolated
- Complex
- **5 key structures to be examined-**
- Zygoma
- Orbit
- Nose
- Maxillary sinuses & maxillae
- Mandible

# ZYGOMATIC FRACTURES

- 5 articulations of zygoma
- Divided as-
- Tripod #s
- Isolated zygomatic injuries- zygomatic process, body #s

# TRIPOD #s

- 3 principal disruptions
- Classic & non-classic #s
- Extension along orbital floor-lateral aspect of inferior fissure, displacement & rotation of zygoma- Towne's view
- Role of panoramic radiography

## • **WATER'S VIEW**

- Opacification of maxillary sinus due to intrasinus hematoma
- Diastases of FZ & ZM articulations
- Loss of contiguity or disruption of maxillary line
- Displacement & rotation of entire zygoma
- Decrease / increase in transverse diameter of maxillary sinus
- Increased vertical height of orbit due to inferior displacement of zygoma

- Fracture of inferior orbital rim and floor of orbit
- Absence of infraorbital foramen due to fracture extending through it
- Railroad track sign in the orbit
- Accentuation of lateral orbital margin
- Signs of zygomatic arch fractures
- Intraorbital or subcutaneous air

- **CALDWELL VIEW**

- Fracture of frontal process of zygoma or zygomatic process of frontal bone
- Diastasis of FZ suture
- Fracture of inferior orbital rim and floor of orbit
- Lateral , medial or inferior displacement of zygoma
- Signs of zygomatic arch fracture

- **3 signs**
- Trap door sign
- Bright light sign
- Railroad track sign

- **SMV AND TOWNE'S VIEW**

- Fracture or deformity of zygomatic arch
- Depression of inferior orbital rim
- Posterior displacement and rotation of zygoma
- Fracture of orbital floor extending to the region of inferior orbital fissure

# ZYGOMATIC ARCH FRACTURES

- **Under penetrated SMV and routine waters view**
- Signs-
- Depression of zygomatic arch
- Vertical radiopaque band lateral to body of zygoma
- W shaped deformity
- Diastasis of ZT suture
- Displaced and nondisplaced fracture

# NASAL FRACTURES

- Must include **Water's view** to access integrity of nasal arch, bilateral lateral view of nose and inferior displacement of nasal bone.
- Signs-
- Lucencies of nasal bone
- Loss of symmetry between respective halves of nose
- Separation of nasomaxillary suture
- Depression of nasal bone
- Deviation of nasal septum and septal haematoma

- **Underpenetrated SMV –**
- Lateral or medial deviation of fracture bones
- **Lateral view-**
- Depression of nasal bones
- Lucencies perpendicular to nasomaxillary sutures
- Avulsion of lateral nasal cartilage
- Diastasis of nasofrontal suture

# ORBITAL FRACTURES

- **Oblique orbital views-**
- Assessment of optic foramen orbital margins
- Floor of orbit
- Posterior ethmoidal air cells
  
- Fractures involving inferior orbit-
- **Water's and Towne's view**
- Townes view best demonstrates displacement of orbital rim

- **Radiographic signs of trauma involving orbital rim and floor**
- Disruption of orbital rim and floor
- Fractured fragments displaced into adjacent maxillary sinus (bright light sign)
- Opacification of adjacent maxillary sinus
- Intraorbital air
- Soft tissue swelling over lower orbit or superior aspect of maxillary sinus

- **BLOW-OUT #s**
- Water's view
- Caldwell view
- Towne's view- # line & its relationship to IOF
  
- **Radiographic signs-**
- Increased distance between palpable orbital rim & floor of orbit
- Loss or disruption of orbital floor
- Opacification of adjacent maxillary sinus

- Trap door sign
- Bright light sign
- Soft tissue density on superior aspect of maxillary sinus
- Intraorbital air

- **Medial orbital wall #s-**
- **Caldwell view-**
  - Disruption of lamina papyracea
  - Opacification of adjacent ethmoid air cells
  - Presence of intraorbital air

# MAXILLARY SINUS #s

- **Plain radiographic findings-**
- Opacification of maxillary sinus
- Open bite resulting from alterations in occlusal contacts
- Depression of alveolar ridge
- Disruption of pterygoid plates
- Alteration in alignment / position of teeth

# ETHMOID, FRONTAL & SPHENOID SINUS #s

- **Water's and lateral views-**
- Disruption of sinus margins or walls
- Opacification of sinus
- Intraorbital air- pneumocephalus
- Air-fluid level in the sinus

# COMPLEX MIDFACIAL INJURIES

- **LEFORT I**
- WATER'S & CALDWELL VIEW
- Opacification of maxillary sinuses
- #s involving maxillary sinus walls
- LATERAL VIEW
- Disruption of anterior walls of maxillary sinus & pterygoid plates
- Open bite

# Extent

- Horizontal # in body of maxilla
- #line passes above teeth below zygomatic process—through max. sinuses & tuberosities---- to inf. Portion of pterygoid process
- Unilateral/bilateral
- May exist along with #s of mandible and zygoma

- **LEFORT II**

- **WATER'S & CALDWELL VIEW**

- Disruption of nasion & nasal bones
- Bilateral #s of inferomedial orbital rims

- **LATERAL**

- Disruption of nasion & pterygoid plates

# Extent

- Pyramidal #
- Separates maxilla from base of skull by causing #s of nasal bones & frontal processes of maxilla
- #s extend laterally through lacrimal bones & floor of orbit,
- Inferiorly through ZM sutures
- Through zygomatic complex & base of zygomatic process of maxilla
- Posteriorly along lat. Wall of maxilla, through pterygoid plates & max sinuses

- **LEFORT III**
- **WATER'S & CALDWELL VIEW**
- #s through nasion, posterior orbital wall, vertical & horizontal segments of zygoma and diastases of ZT & ZF sutures
- **LATERAL VIEW**
- Disruption of nasion & pterygoid plates
- Separation between facial skeleton & calvarium

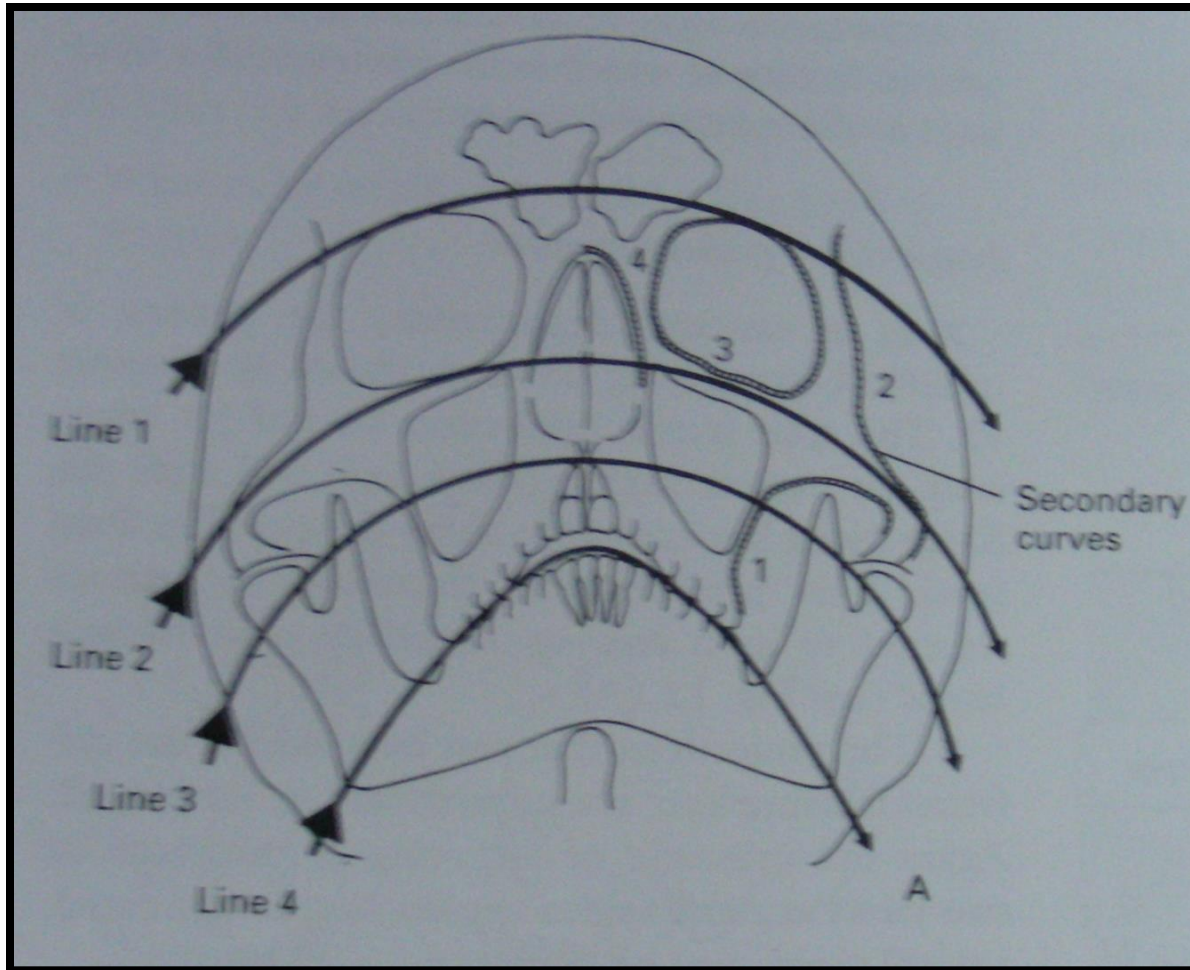
# Extent

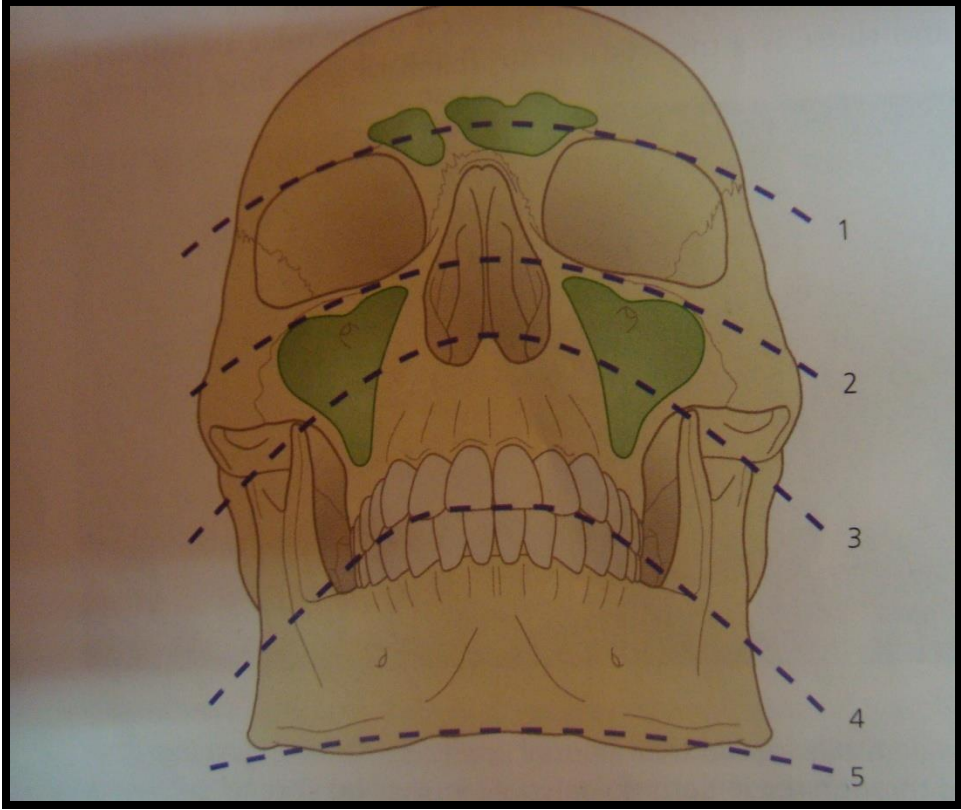
- Craniofacial disjunction
- Complete separation of middle third of facial skeleton from cranium
- #line extends through nasal bones , frontal processes of maxilla, NF & MF sutures, across floors of orbits & through ethmoid, sphenoid sinuses & ZMF sutures
- Passes across ptm fissures & separates pterygoid plates from sphenoid bone
- As a rule a/w multiple max #s or mandi#s

# NASO-ETHMOID-FRONTAL #s

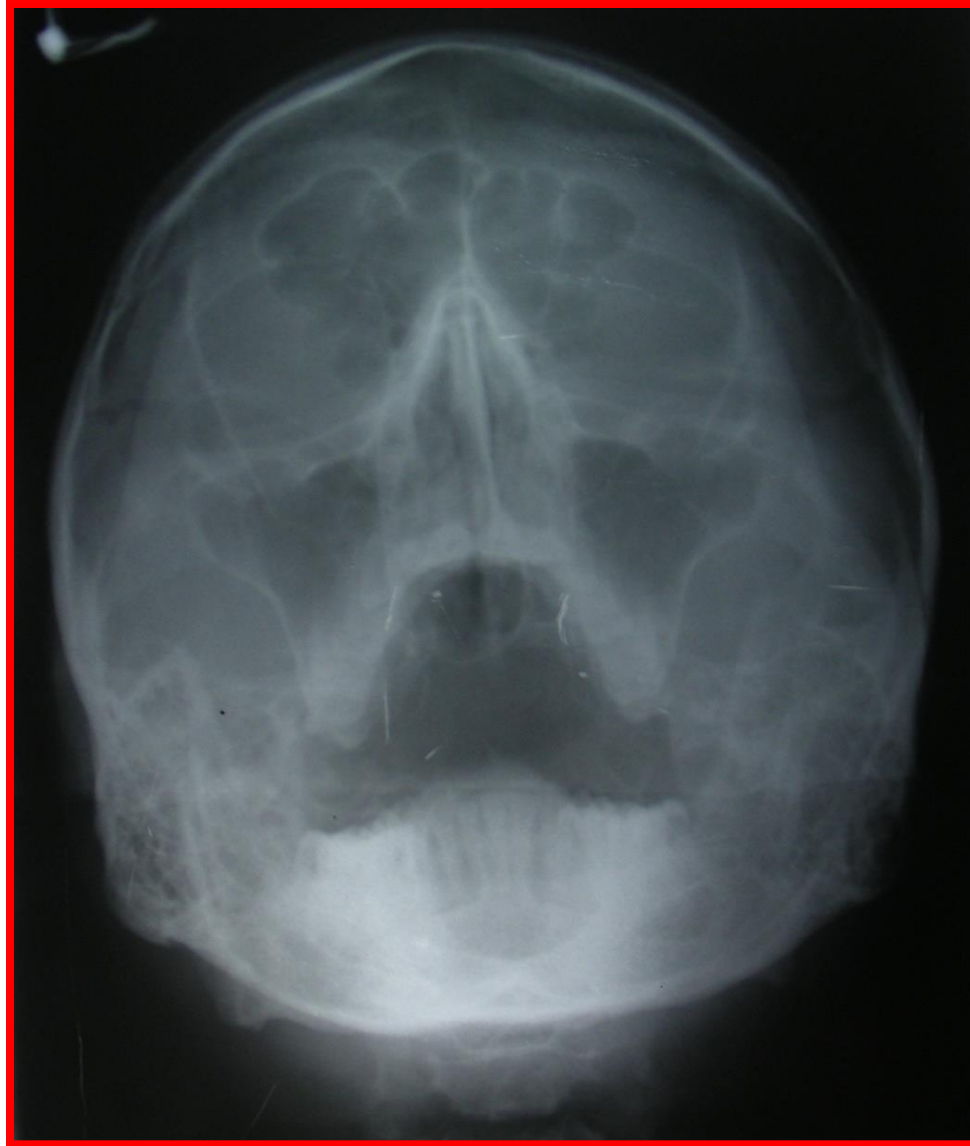
- PLAIN FILM FINDINGS
- Depression of the midface
- #s of lamina papyracea
- Opacification of frontal & ethmoid sinuses
- # of medial orbital & supraorbital rims
- #s of frontal sinuses
- Intraorbital & intracranial air
- Nasal #s

# CAMPBELL LINES & SECONDARY CURVES

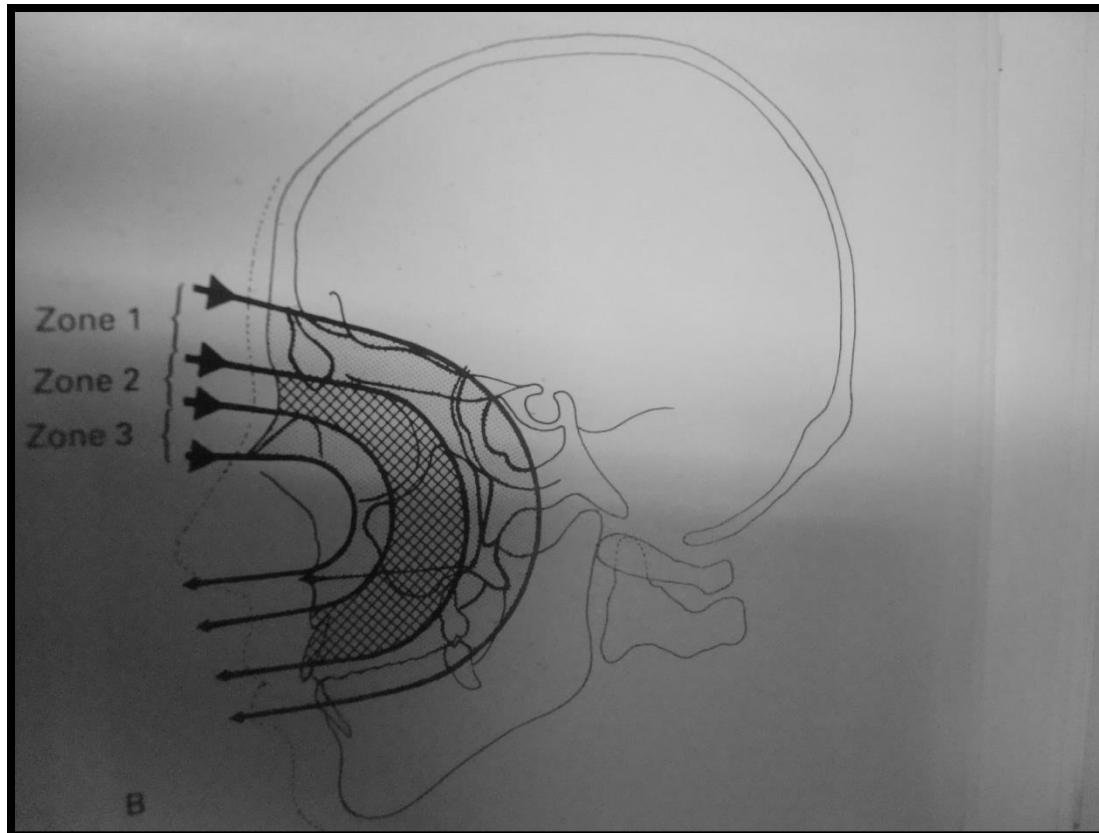








# 3 ZONES



Examine the areas of the radiograph as depicted by the three shaded zones in the shapes of reverse 'C's:

Zone 1: Check the following areas

Frontal sinus

Zone 2: Check the following areas:-

Fronto-nasal suture

Floor of the anterior cranial fossa, including the cribriform plate

Zone 3: Check the following areas:-

Nasal bones

Anterior walls of the middle cranial fossa

Features to note include:-

• Deformities or deviation from the normal contours

• Levels in the maxillary antrum

Anterior wall of the maxillary antrum

Lateral border of the orbit

Sphenoidal sinus

Maxillary antrum

Anterior nasal spine

Vertical walls of the pterygo-palatine fossa

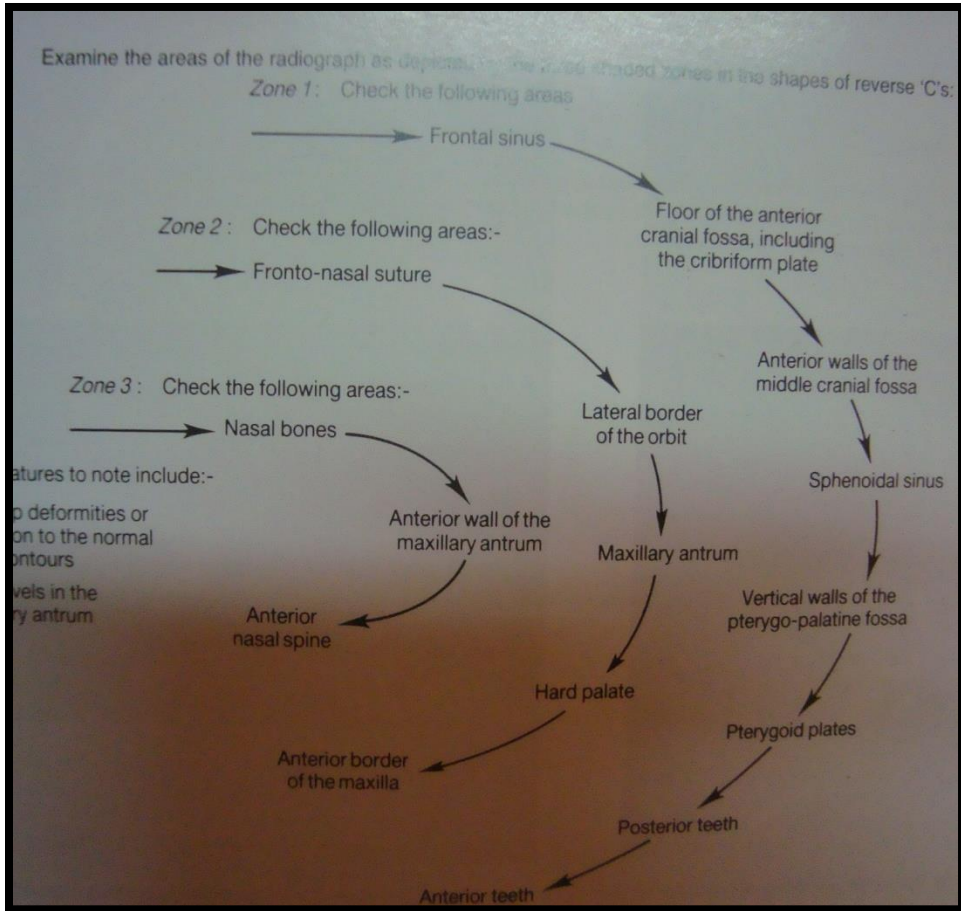
Hard palate

Pterygoid plates

Anterior border of the maxilla

Posterior teeth

Anterior teeth

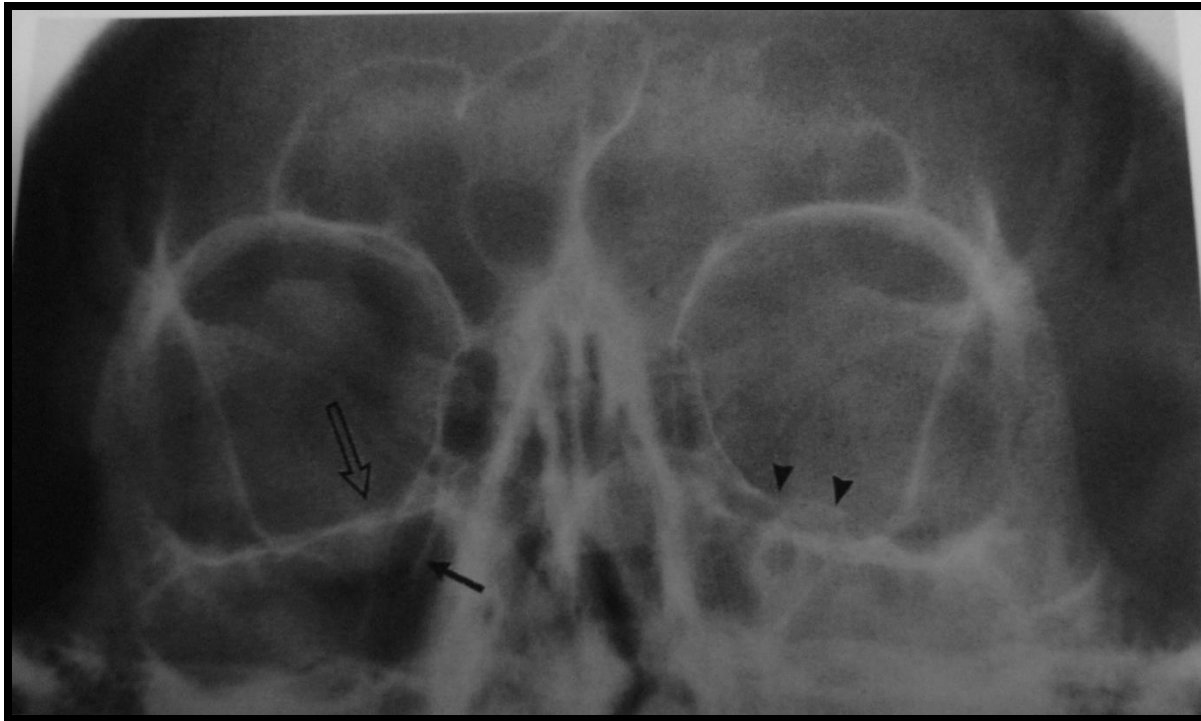


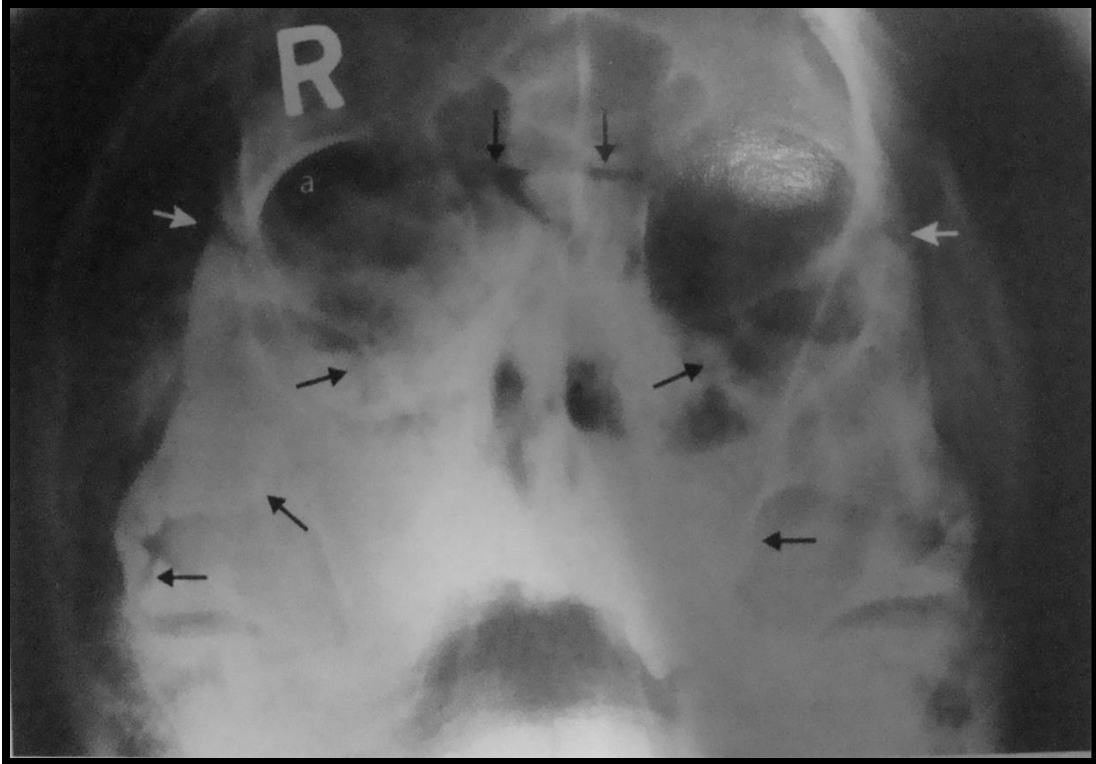
# ROLE OF CT

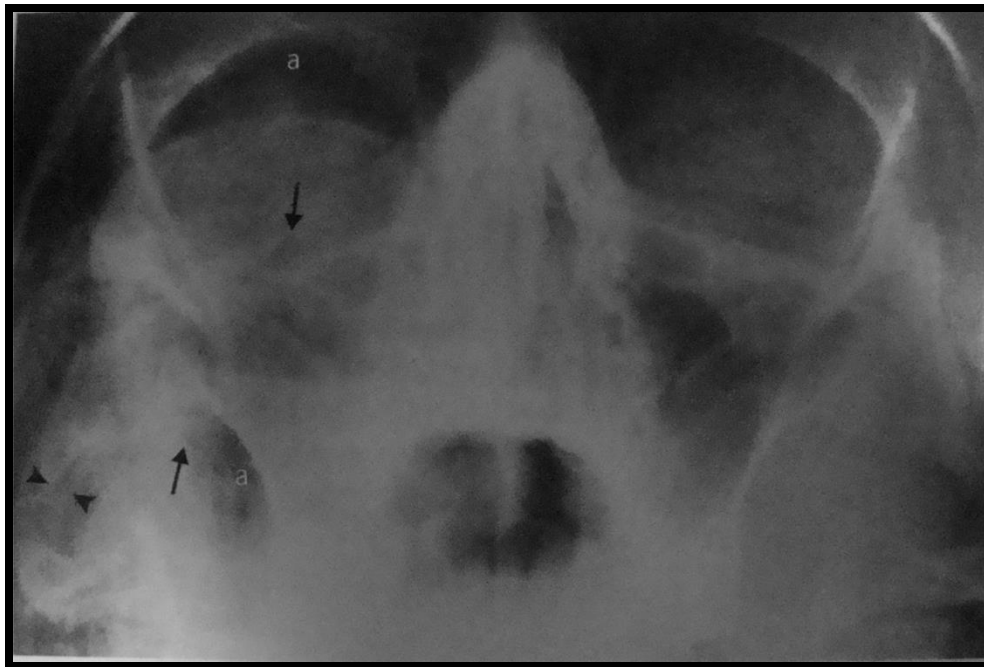
- Indicated when extensive osseous or soft tissue injuries or penetrating trauma is apparent
- Or when optimal plain films cannot be obtained due to patient's physical condition or technical factors
- It demonstrates extensive soft tissue injuries, # complexes & significant intracranial injuries that are not well visualized on plain films.

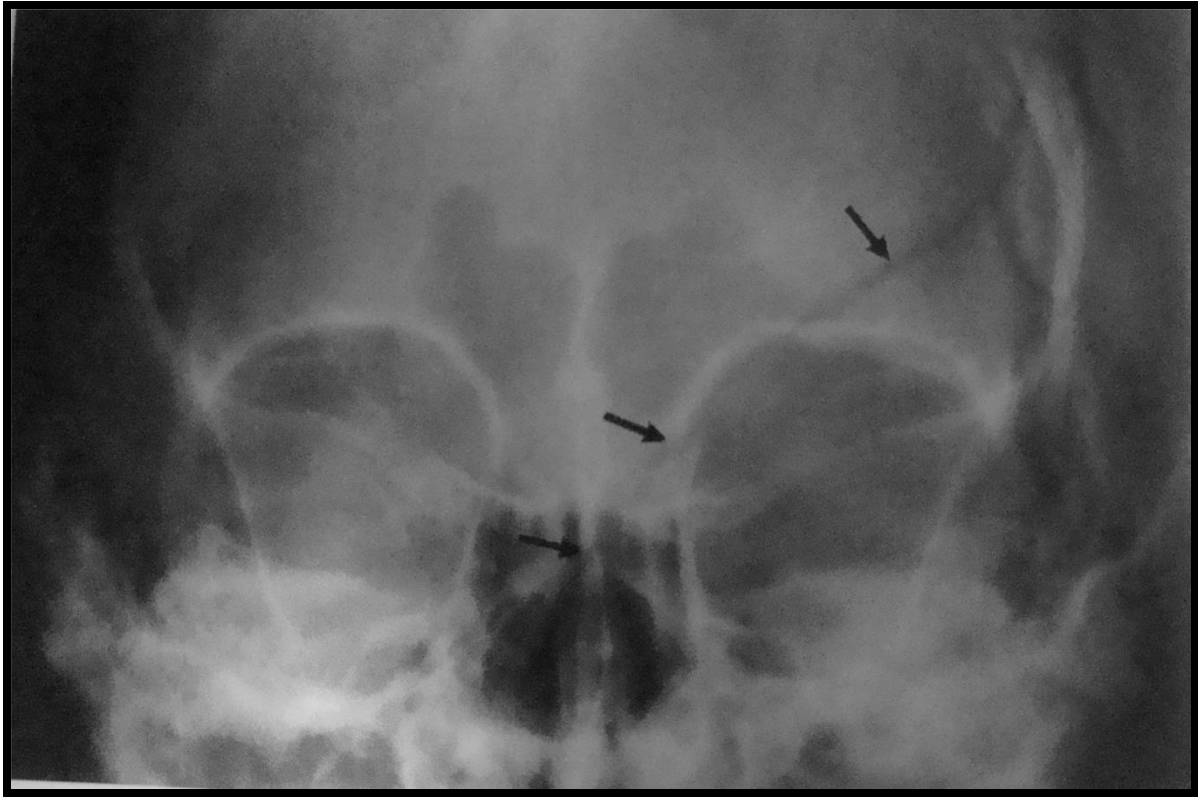
- Indicated in orbital injuries, sinus injuries and all other complex, multiple #s of midface for complete visualization of extent of #s, soft tissues etc
- CT head & CT facial skeleton are the standard procedures in most ER settings.

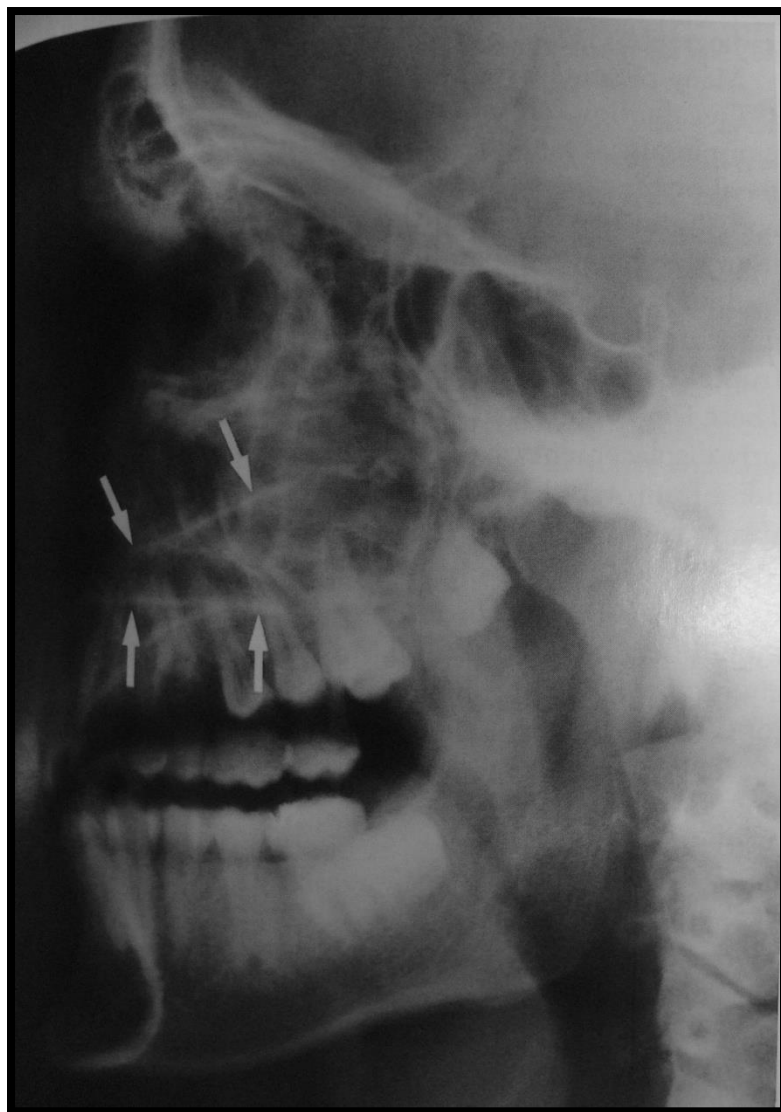
# RADIOGRAPHS

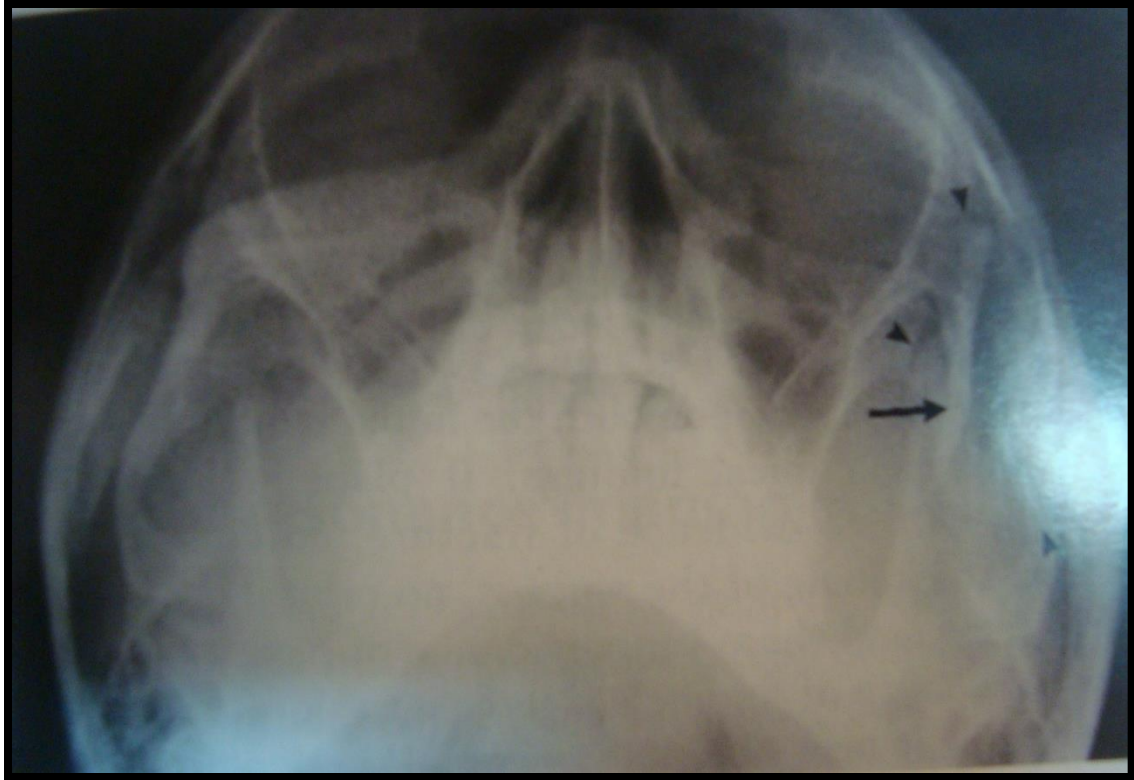


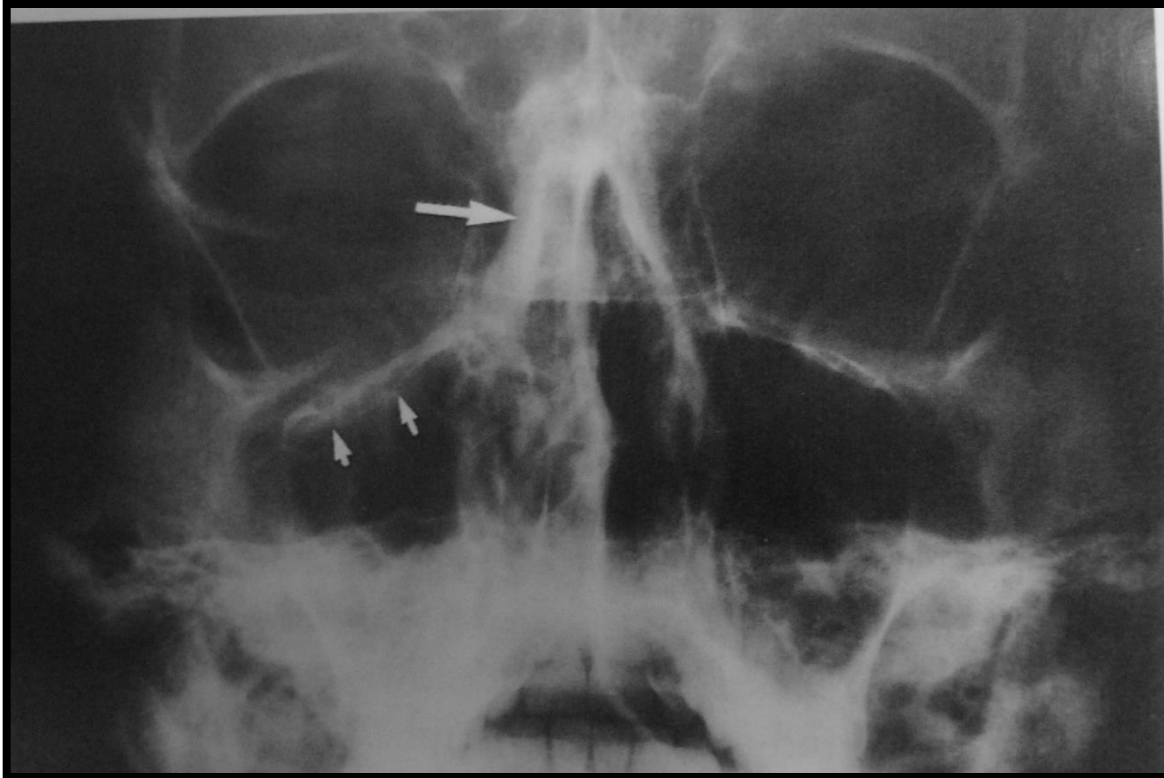


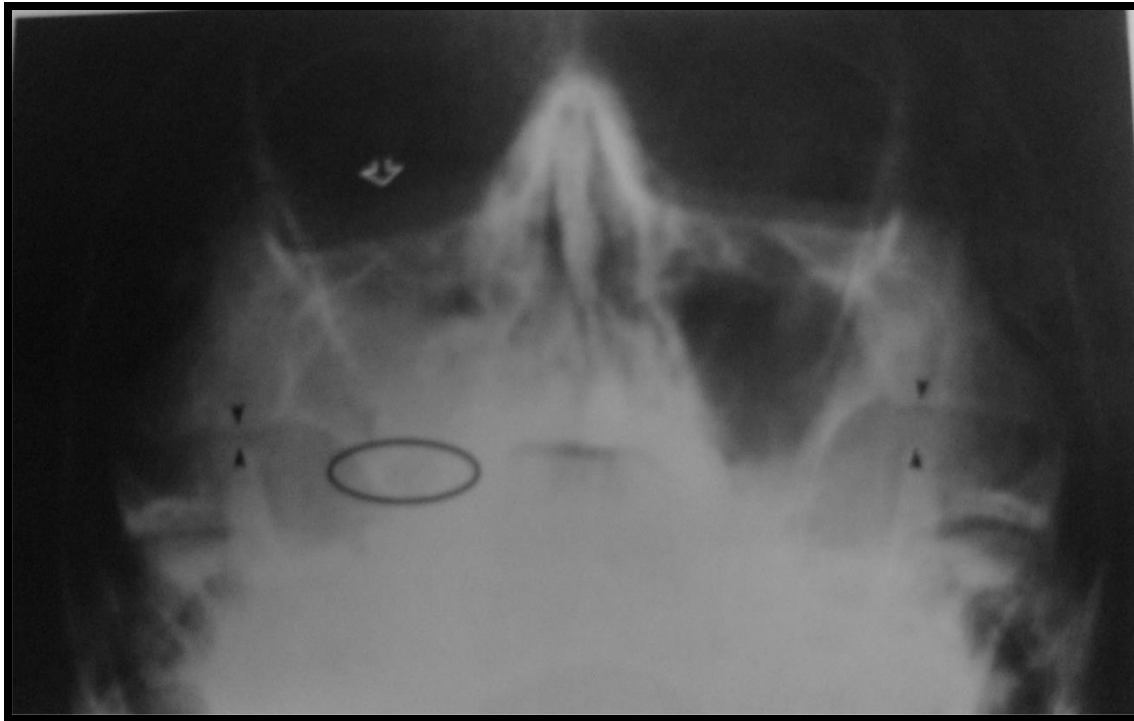


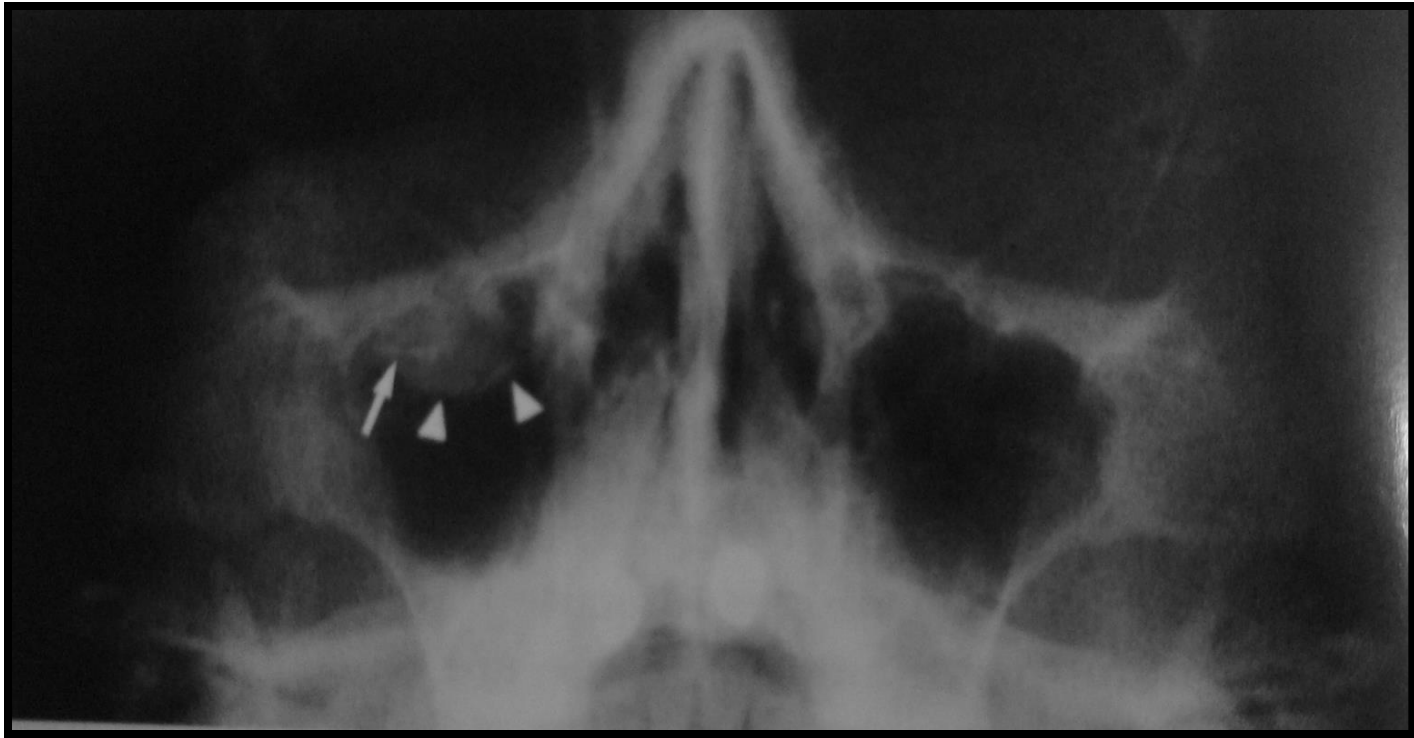

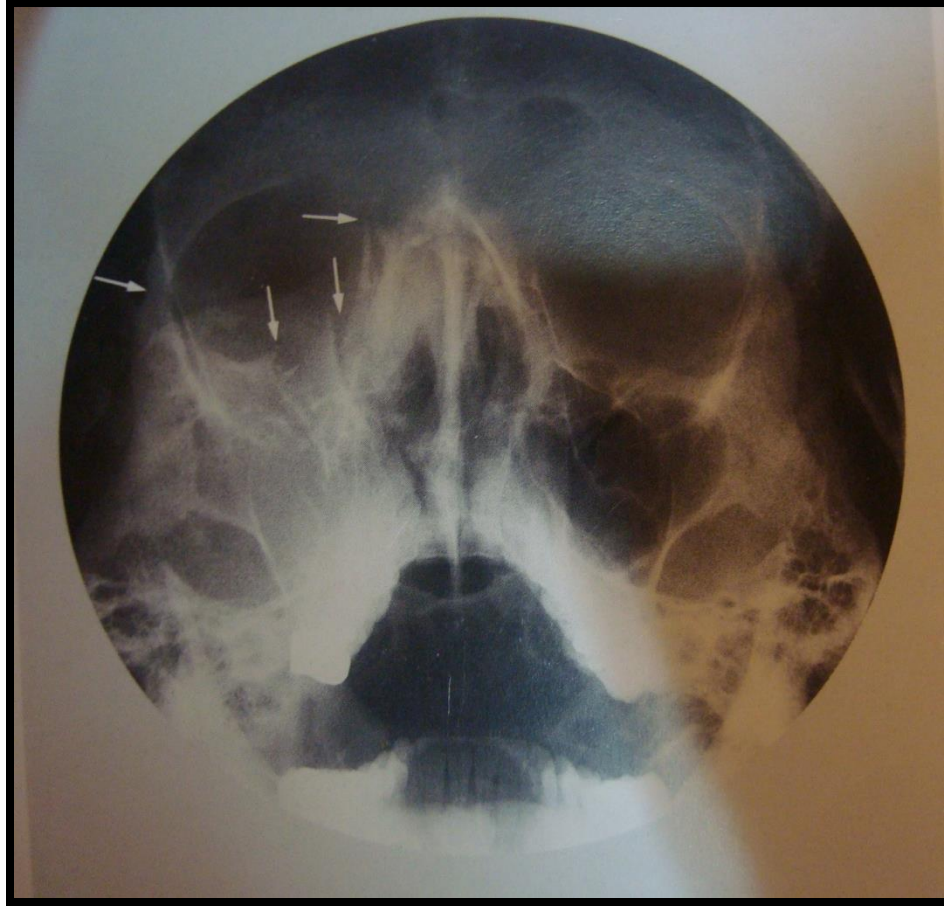



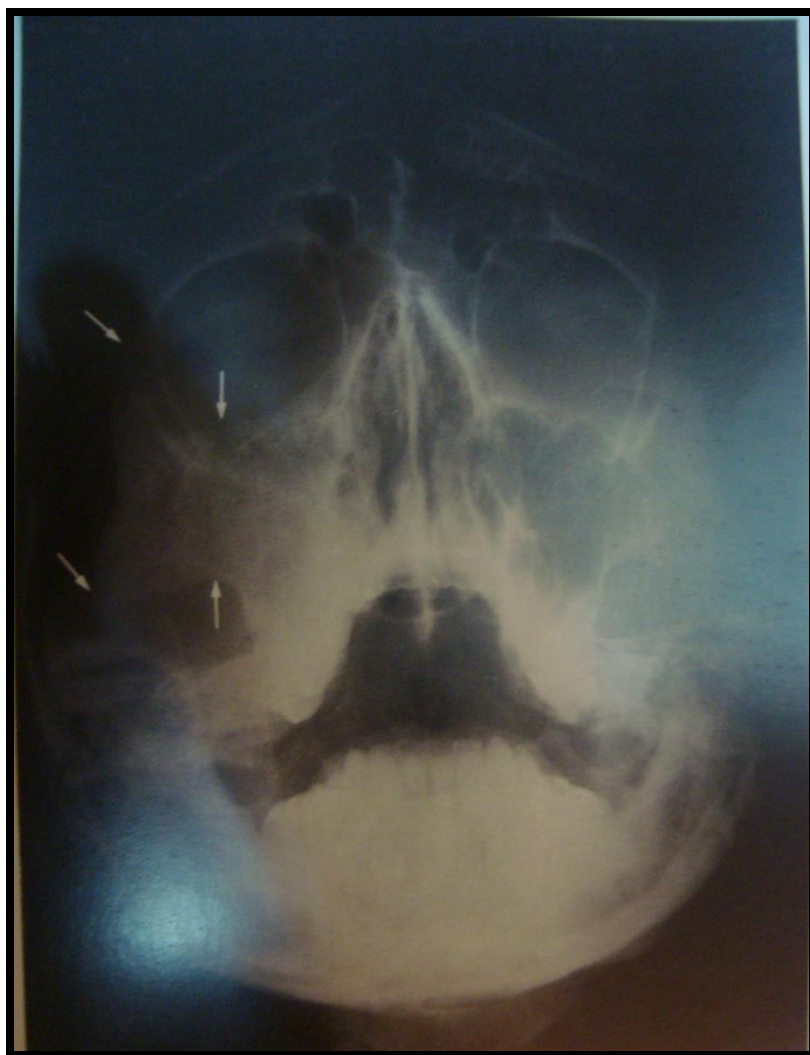


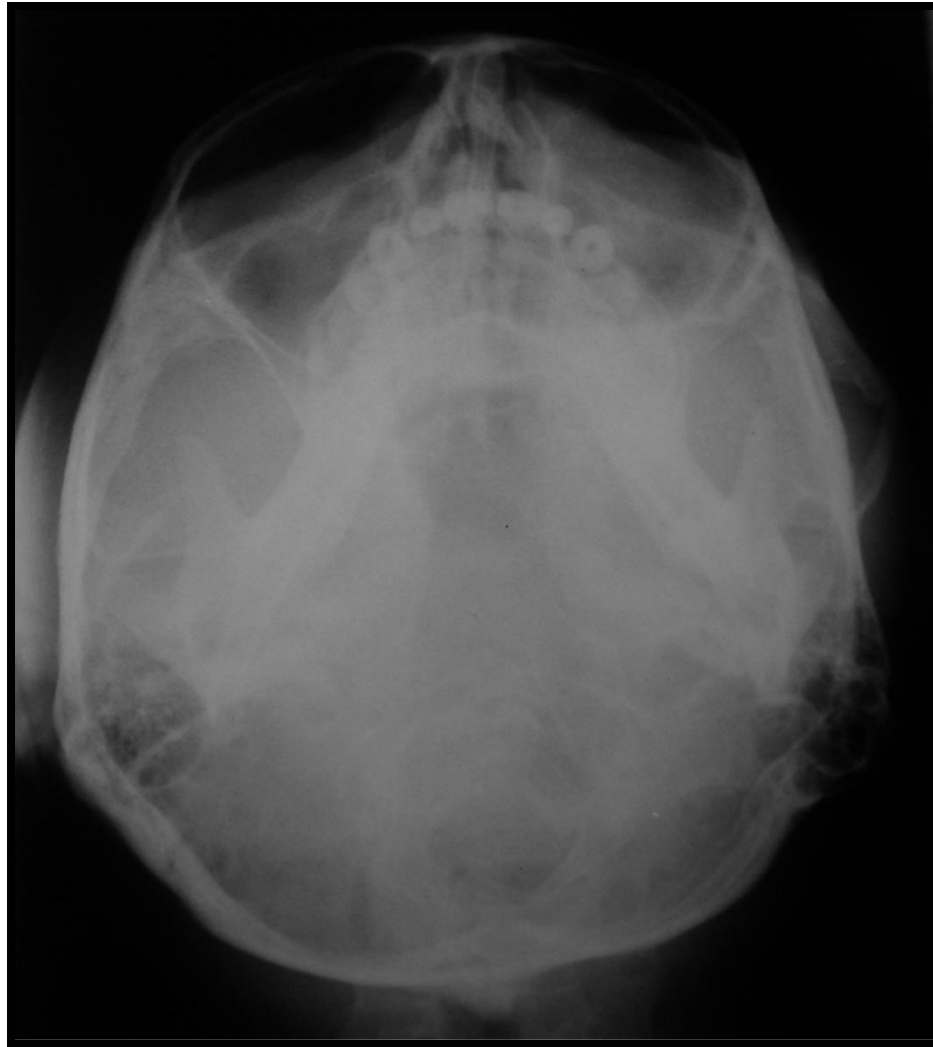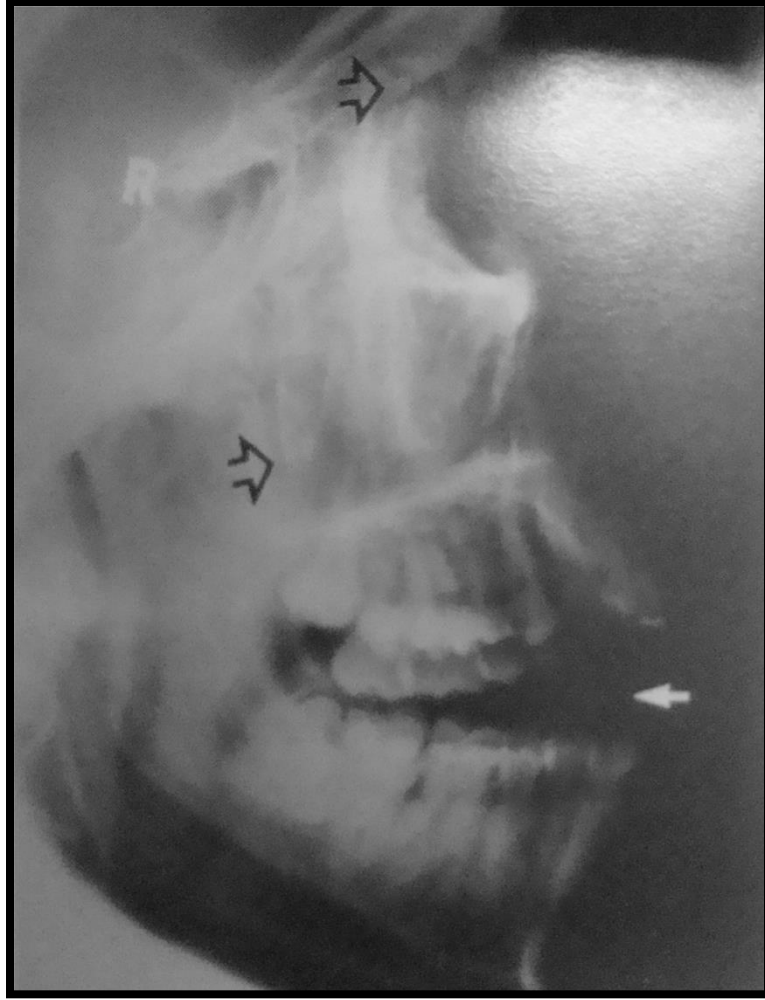




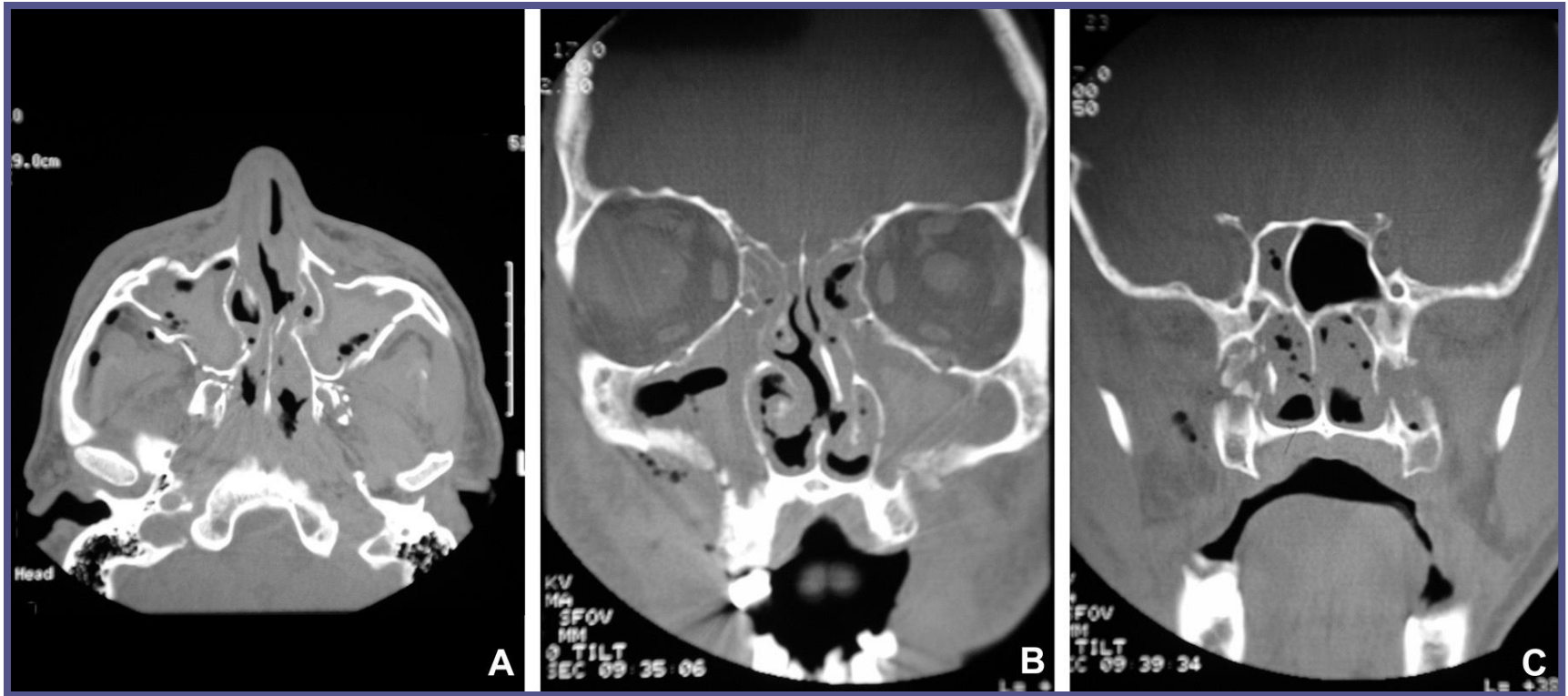


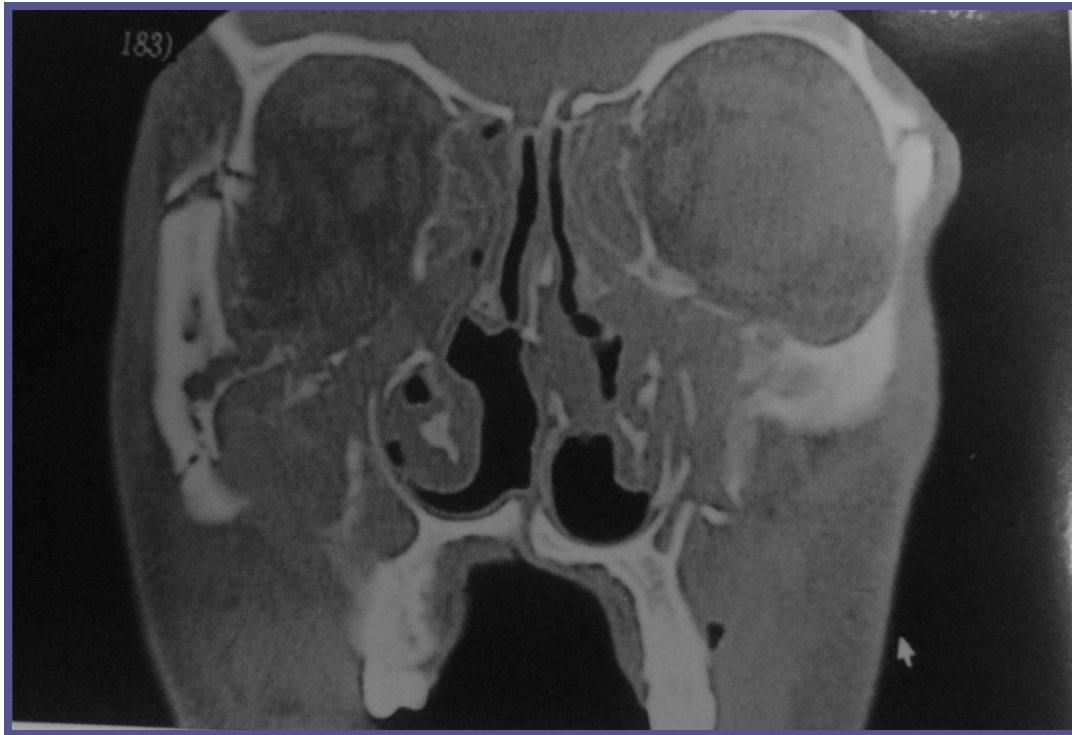





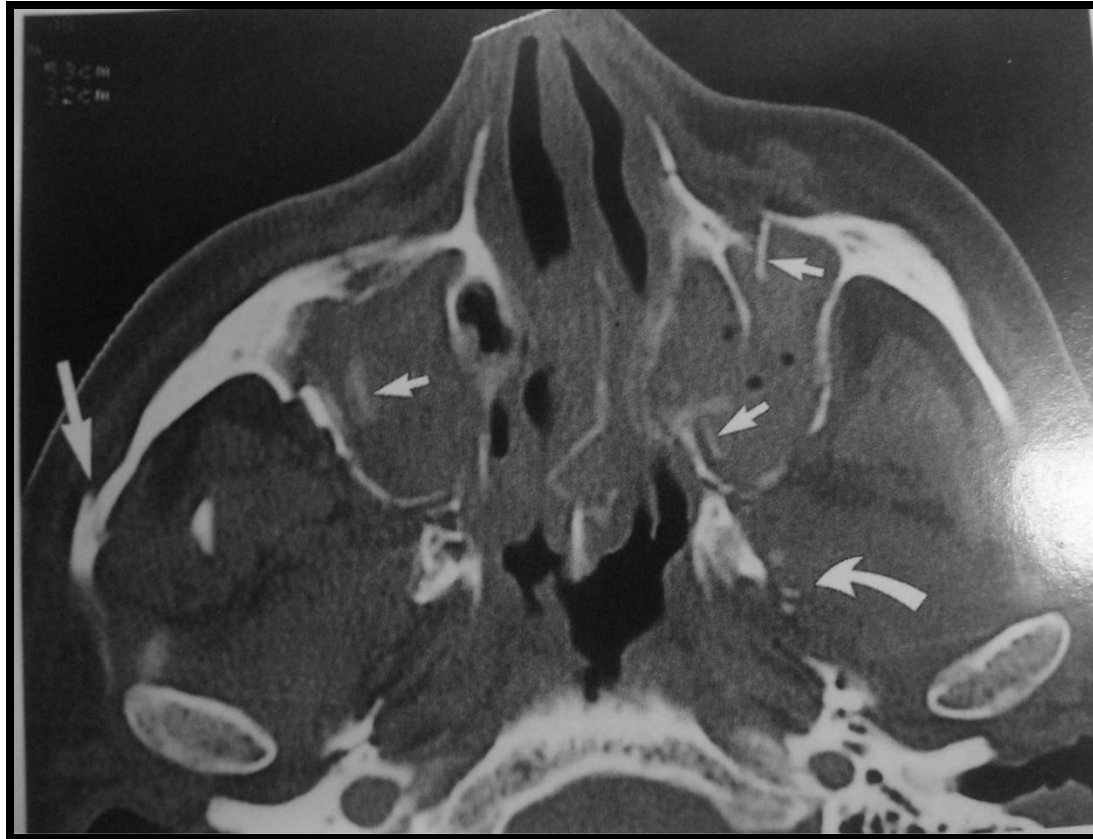
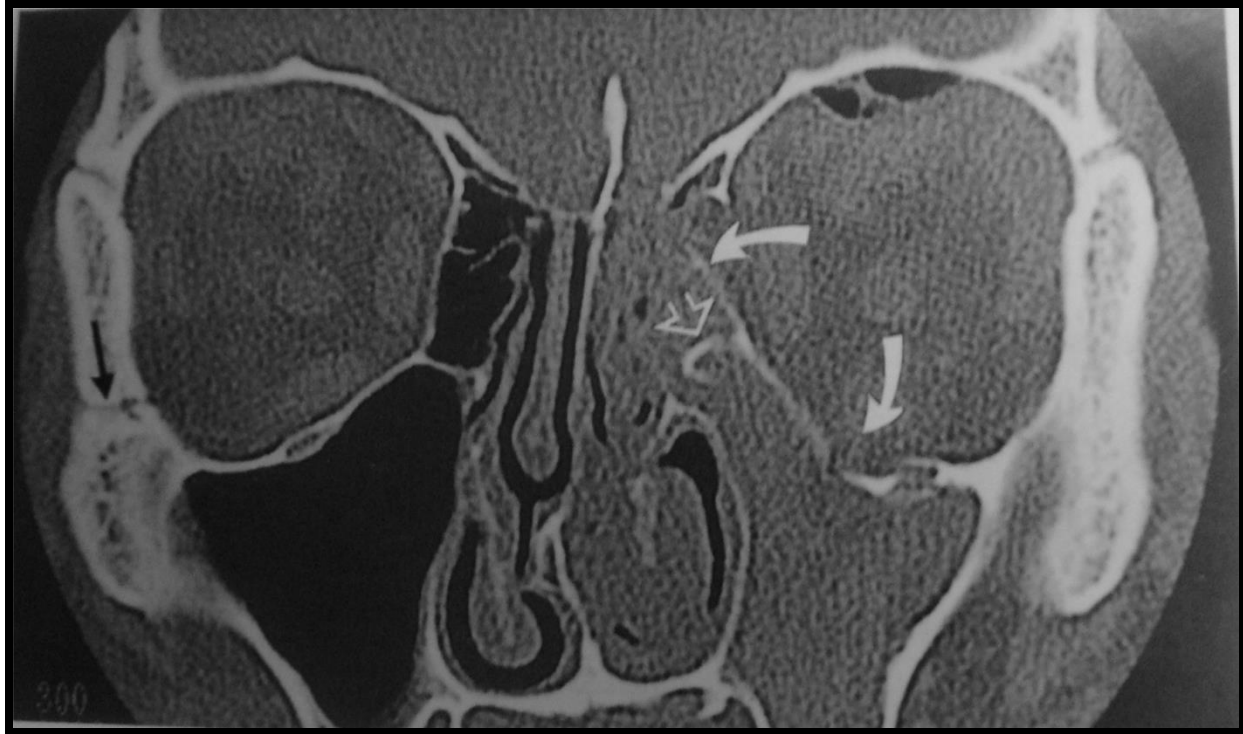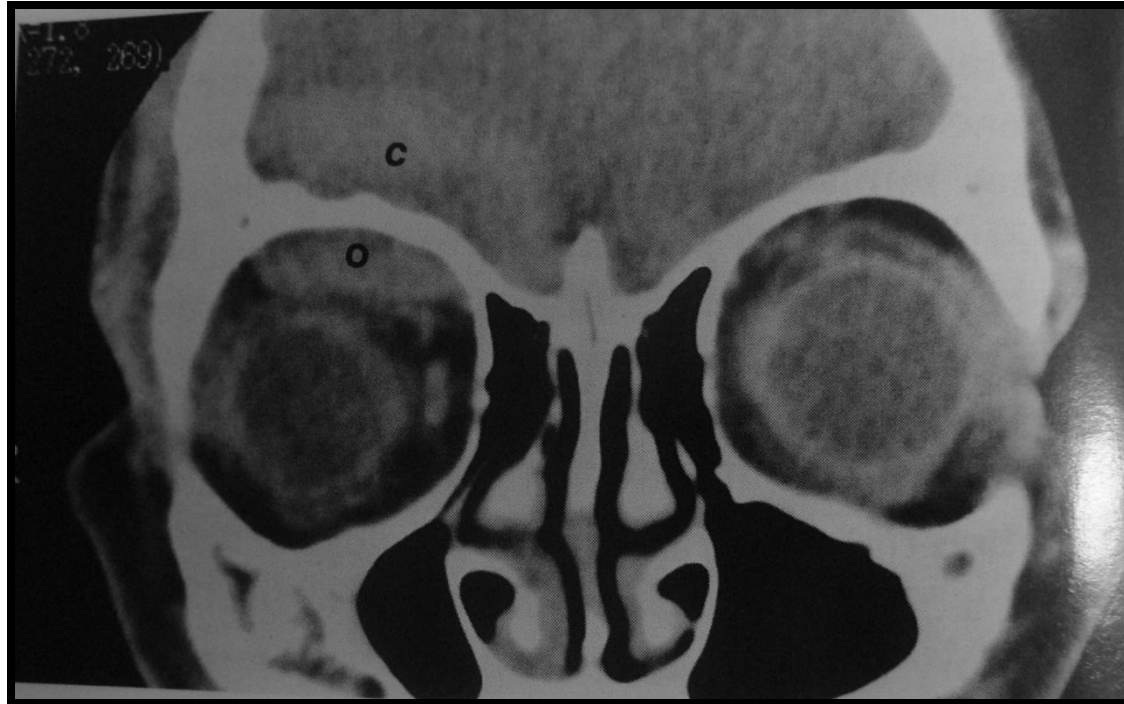# CTs

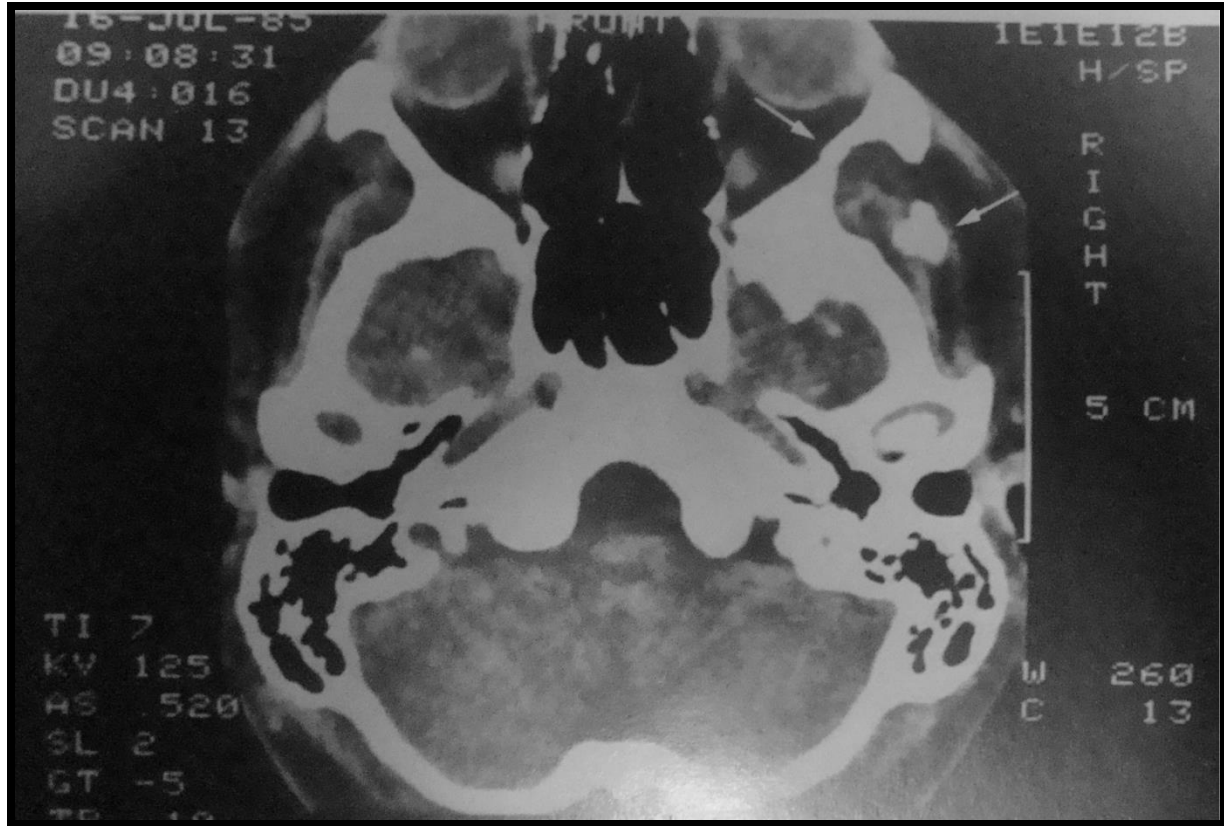


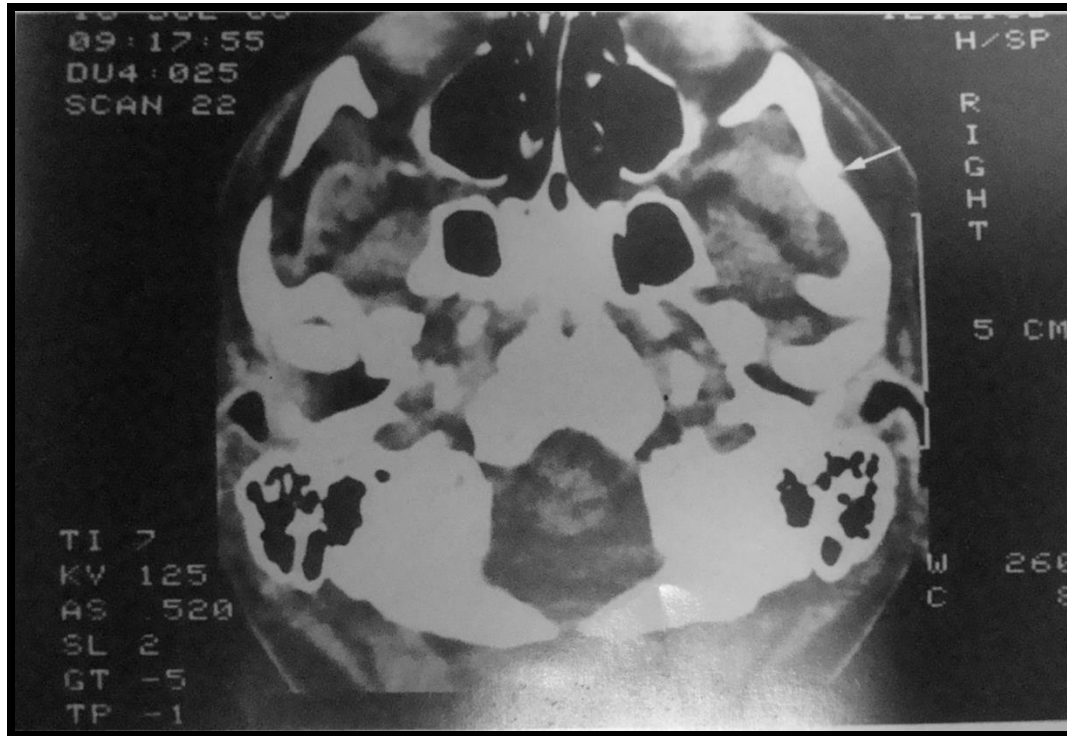
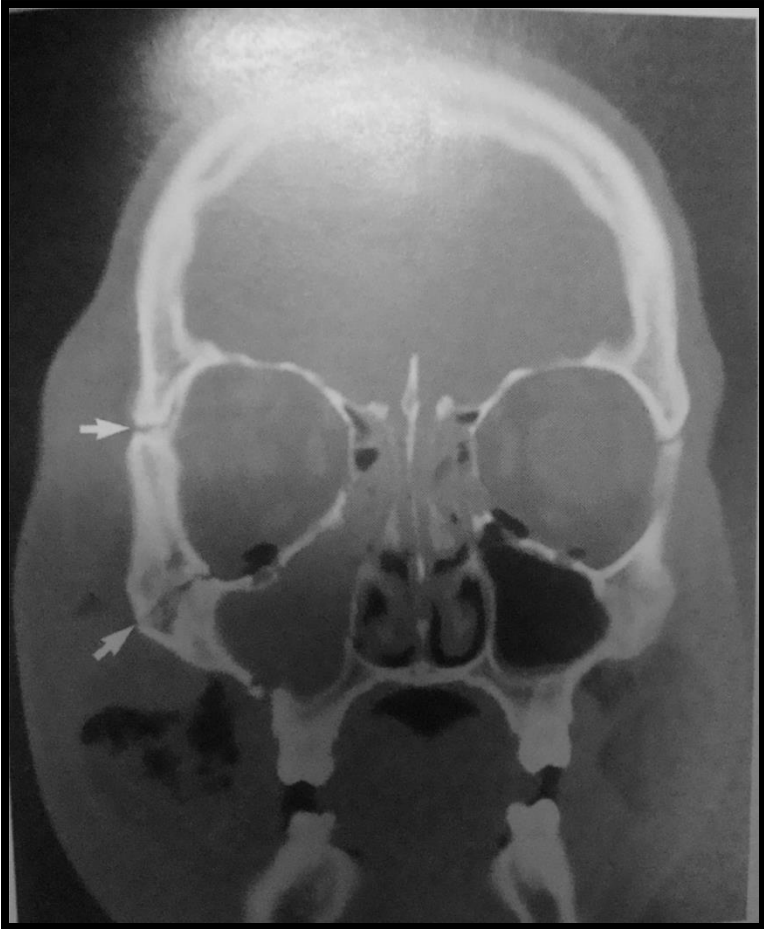


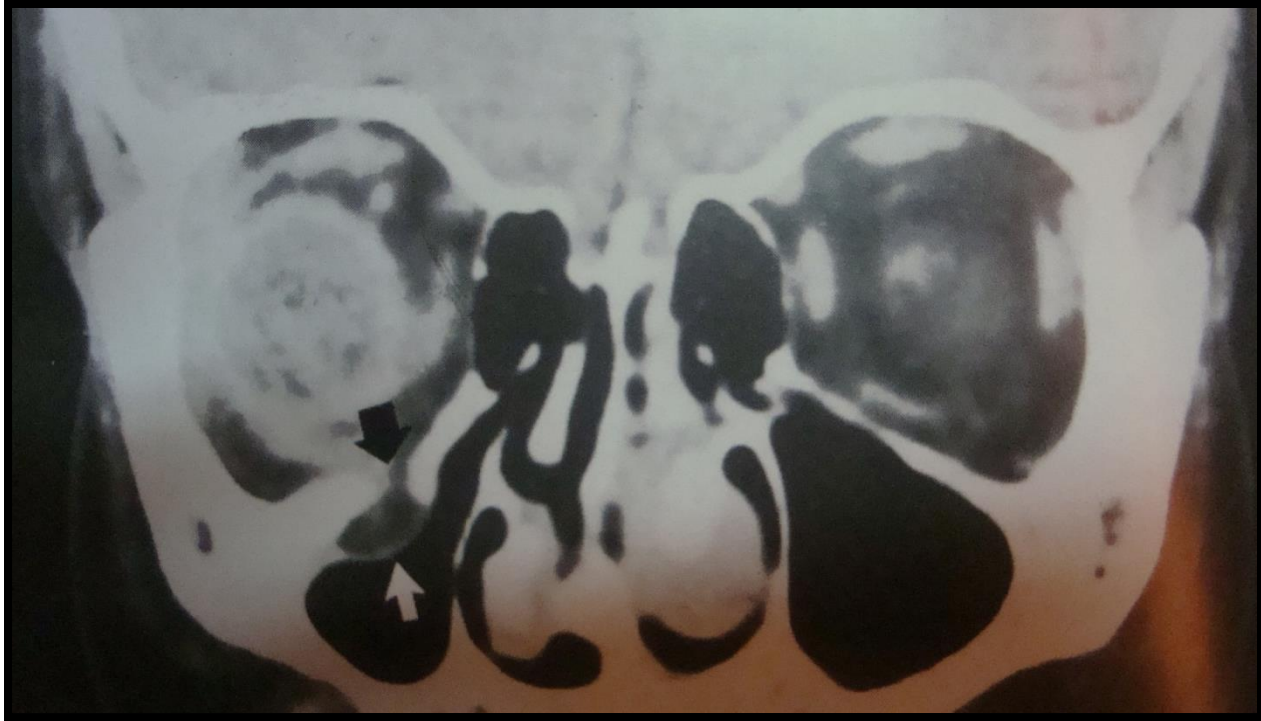














THANK YOU