
INTRA ORAL

RADIOGRAPHIC

TECHNIQUES

Intra Oral Radiography

—— **Periapical**

—— **Bite Wing**

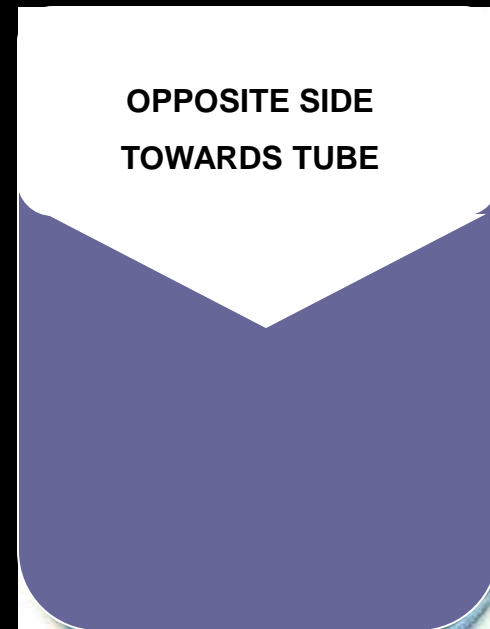
—— **Occlusal**

Intra Oral Periapical Radiography


Recording medium- x ray film

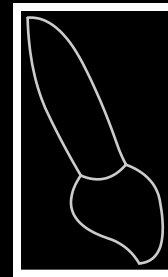

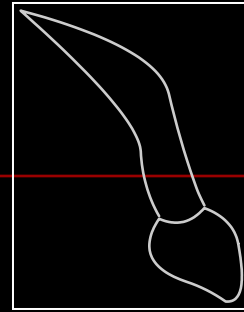
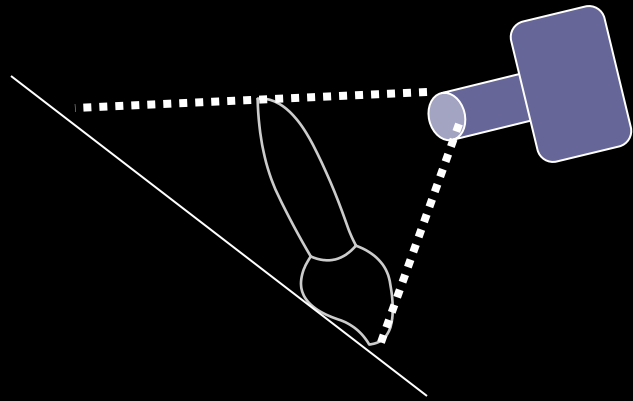


FRONT SIDE



BACK SIDE





Intra Oral Periapical Radiography

- Intra Oral- film placed I.O
- Periapical - Entire tooth + 2 mm surrounding p.a region

IOPA

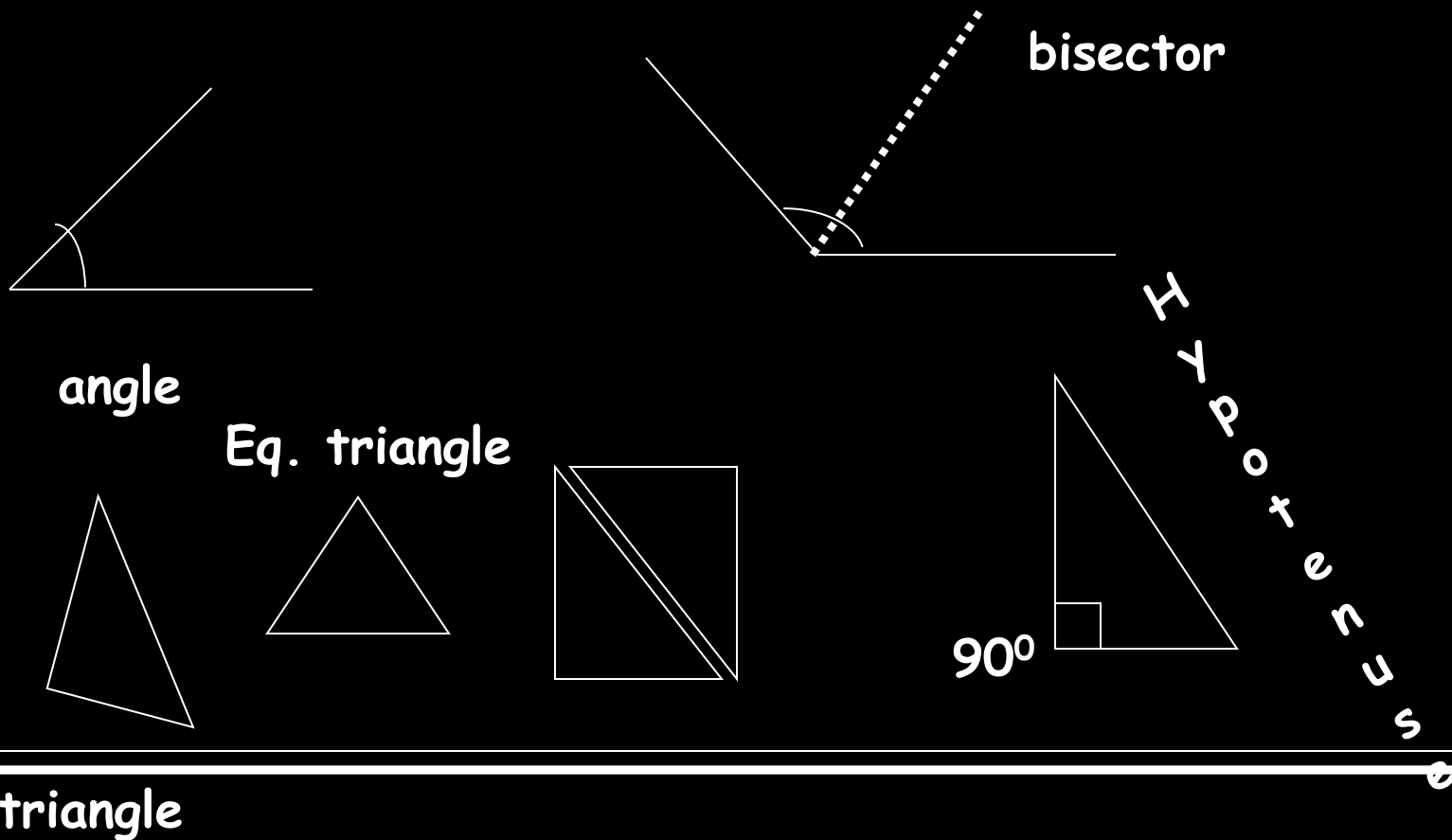
```
graph TD; IOPA[IOPA] --- A[Bisecting angle/ short cone]; IOPA --- B[Paralleling/Long cone/right angle]
```

Bisecting angle/ short cone

Paralleling/Long cone/right angle

Intra Oral Periapical Radiography

Bisecting the angle / Short cone Technique



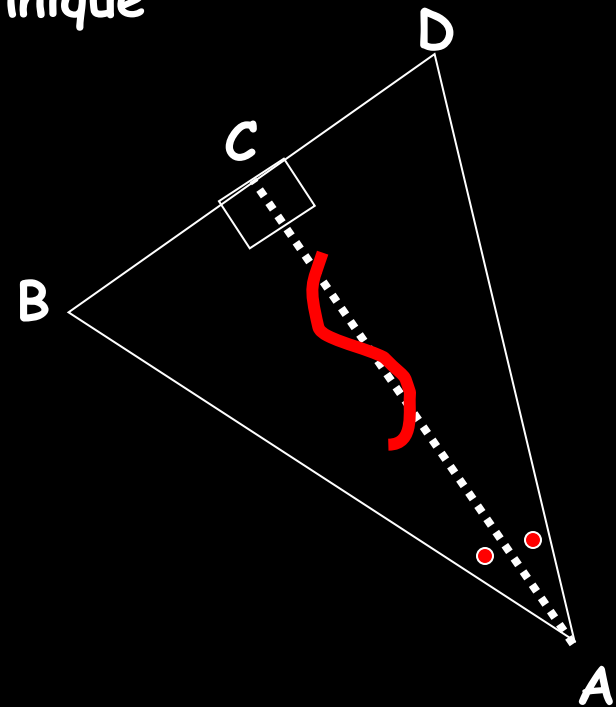
Intra Oral Periapical Radiography

Bisecting the angle / Short cone Technique

Rule of Isometry

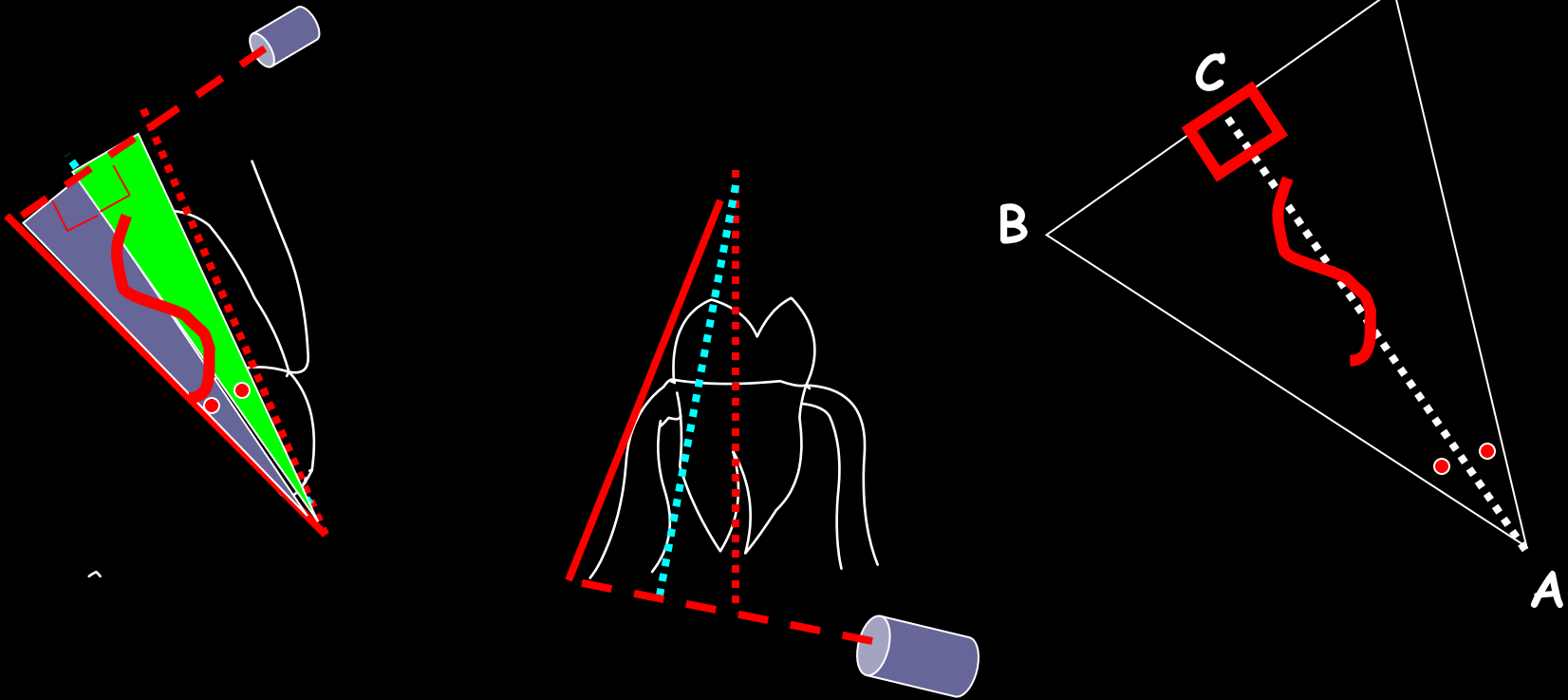


- 2 equal angles
- share common side



Intra Oral Periapical Radiography

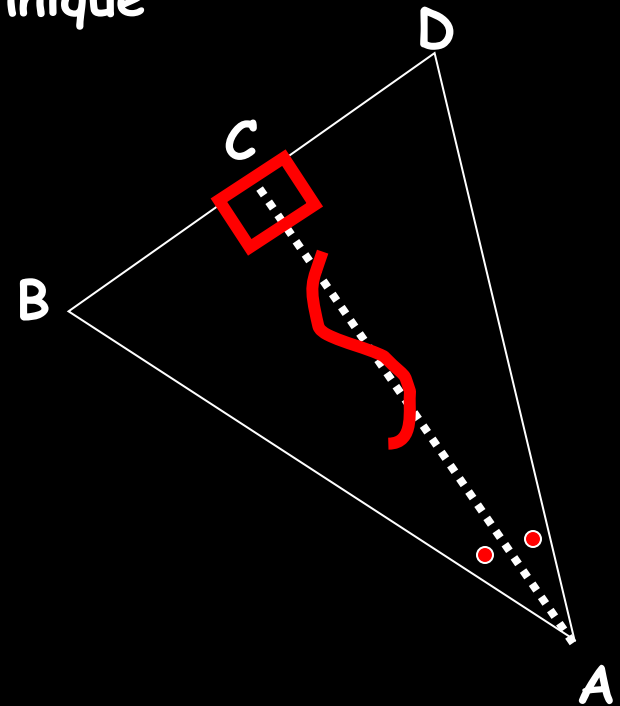
Bisecting the angle / Short cone Technique



Intra Oral Periapical Radiography

Bisecting the angle / Short cone Technique

- 2 right triangles formed
- Congruent
- Hypotenuse of one imag. Triangle rep by long axis of tooth
- Other hypotenuse rep by plane of film

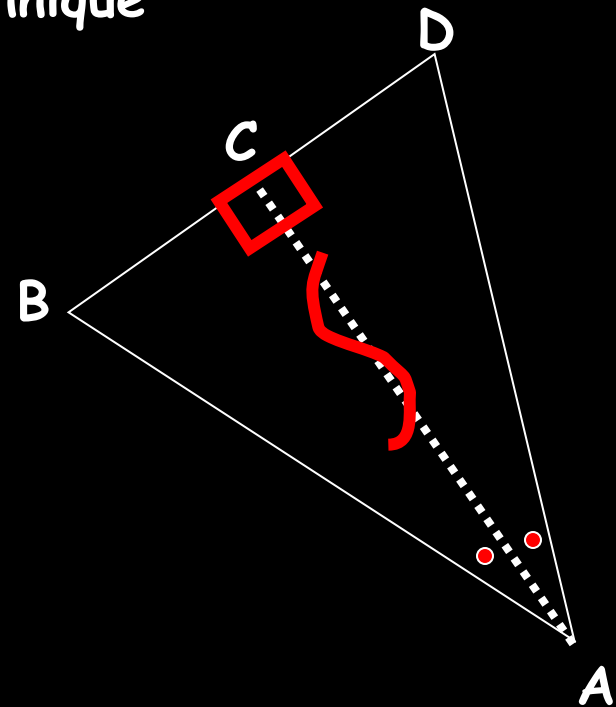
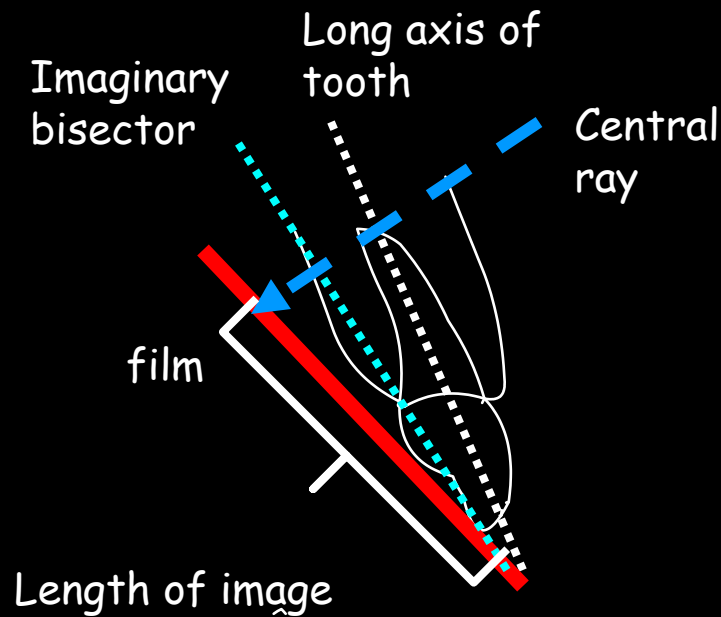


Actual tooth & image on film of same length

Hence

Intra Oral Periapical Radiography

Bisecting the angle / Short cone Technique



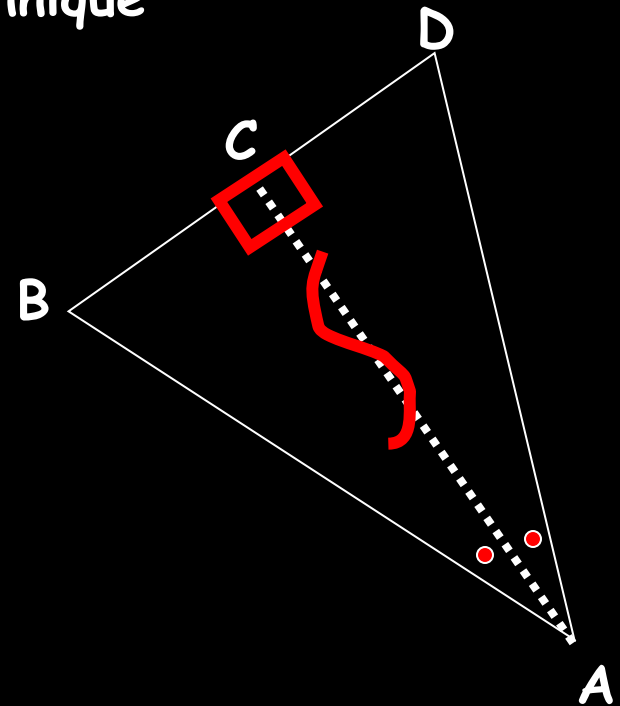
Intra Oral Periapical Radiography

Bisecting the angle / Short cone Technique

Film Stabilization

To position & stabilize film

- Film holding instruments or
- Patient's finger



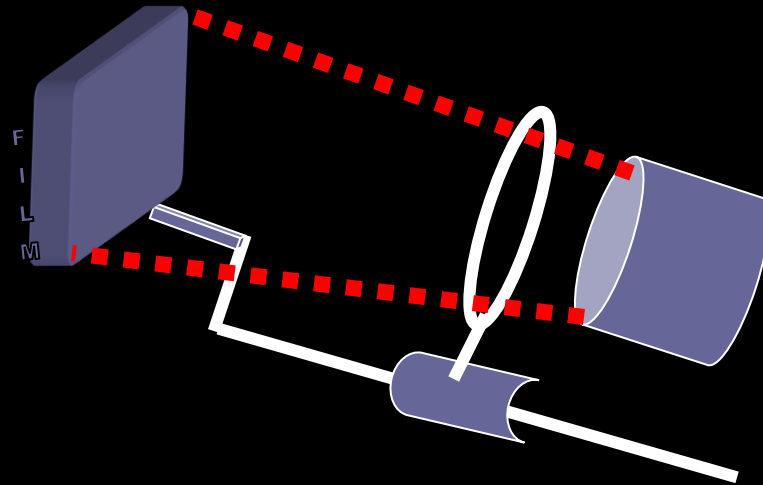
Intra Oral Periapical Radiography

Bisecting the angle / Short cone Technique

Film Stabilization

Film holding instruments

- Rinn BAI Instruments
- Stabe bite block
- EEZEE-Grip film holder



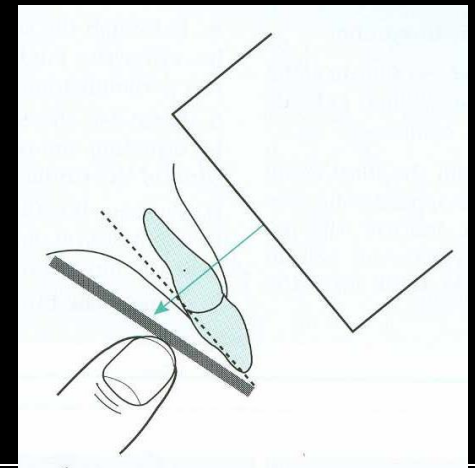

Intra Oral Periapical Radiography

Bisecting the angle / Short cone Technique

Film Stabilization

Finger Holding method

- Also called digital method
- Pt's finger or thumb
- Index finger for mand.
- Always behind the film & teeth
- Left hand for R exp. & vice versa.



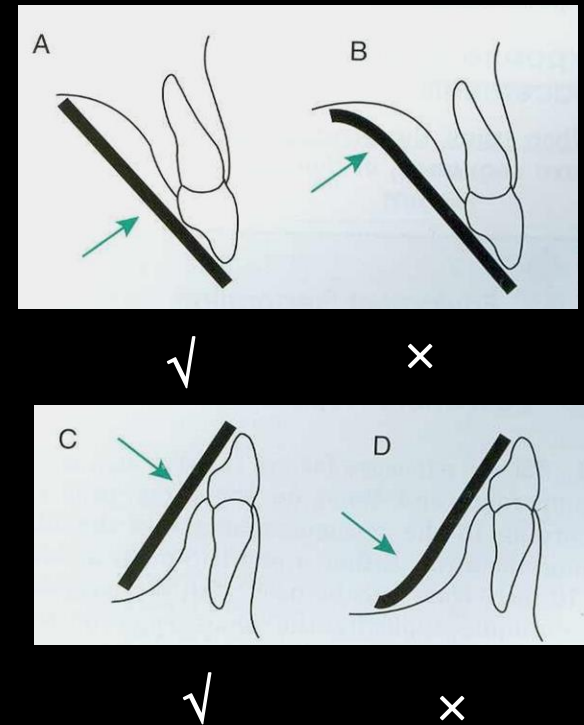
Intra Oral Periapical Radiography

Bisecting the angle / Short cone Technique

Film Stabilization

Finger Holding method

- Also called digital method
- Pt's finger or thumb
- Index finger for mand.
- Always behind the film & teeth
- Left hand for R exp. & vice versa.



Intra Oral Periapical Radiography

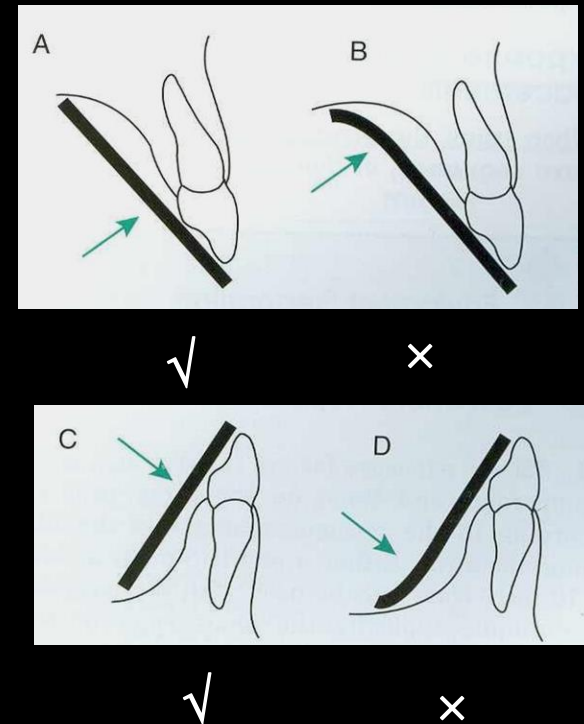
Bisecting the angle / Short cone Technique

Film Stabilization

Finger Holding method

Disadvantages

- Unnecessary hand exposure
- Film may bend → distortion
- film may slip from position
- No aiming ring → cone cut



Intra Oral Periapical Radiography

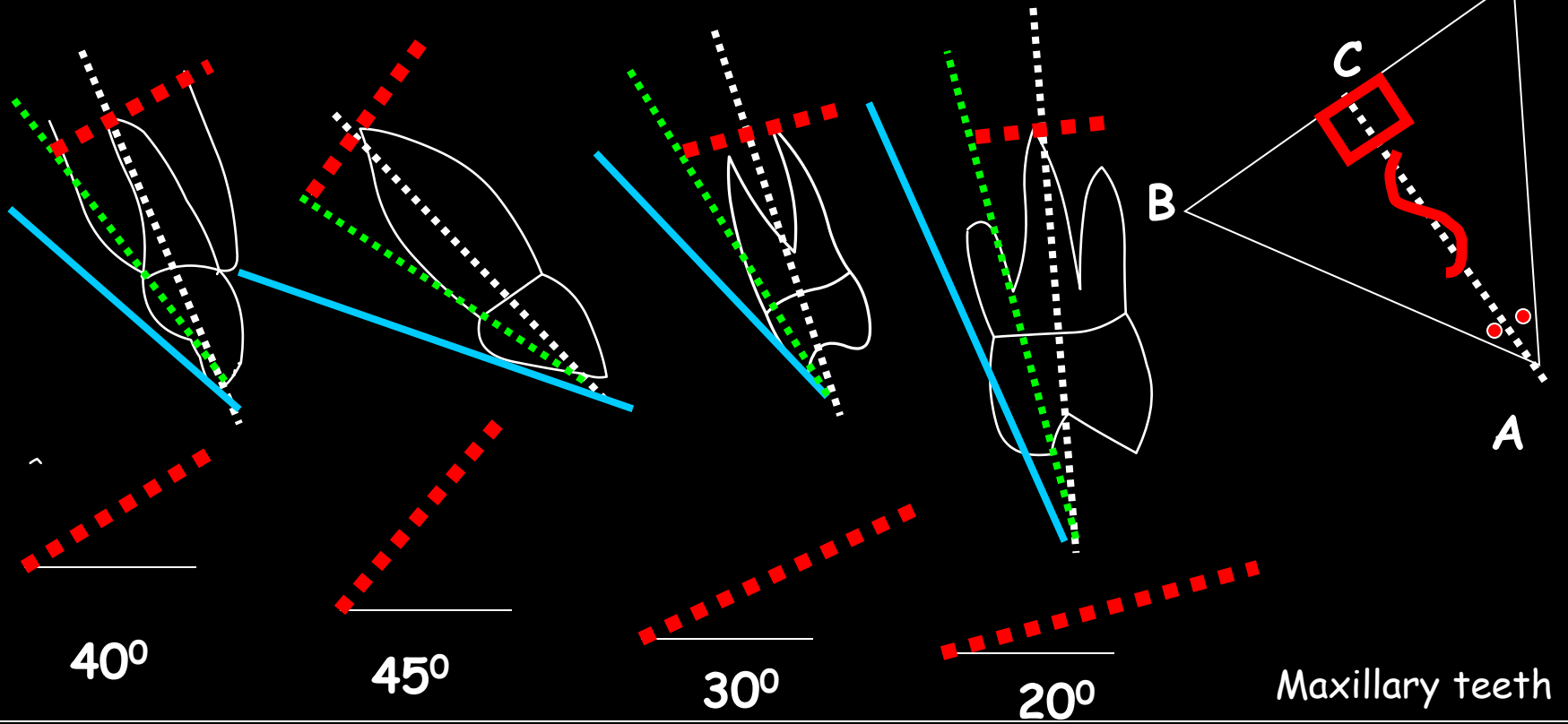
Bisecting the angle / Short cone Technique

Steps in taking radiograph

- Patient positioning
- Immobilization
- Exposure values adjustment
- Angulations - Vertical & horizontal
- Placement of film packets
- Exposure

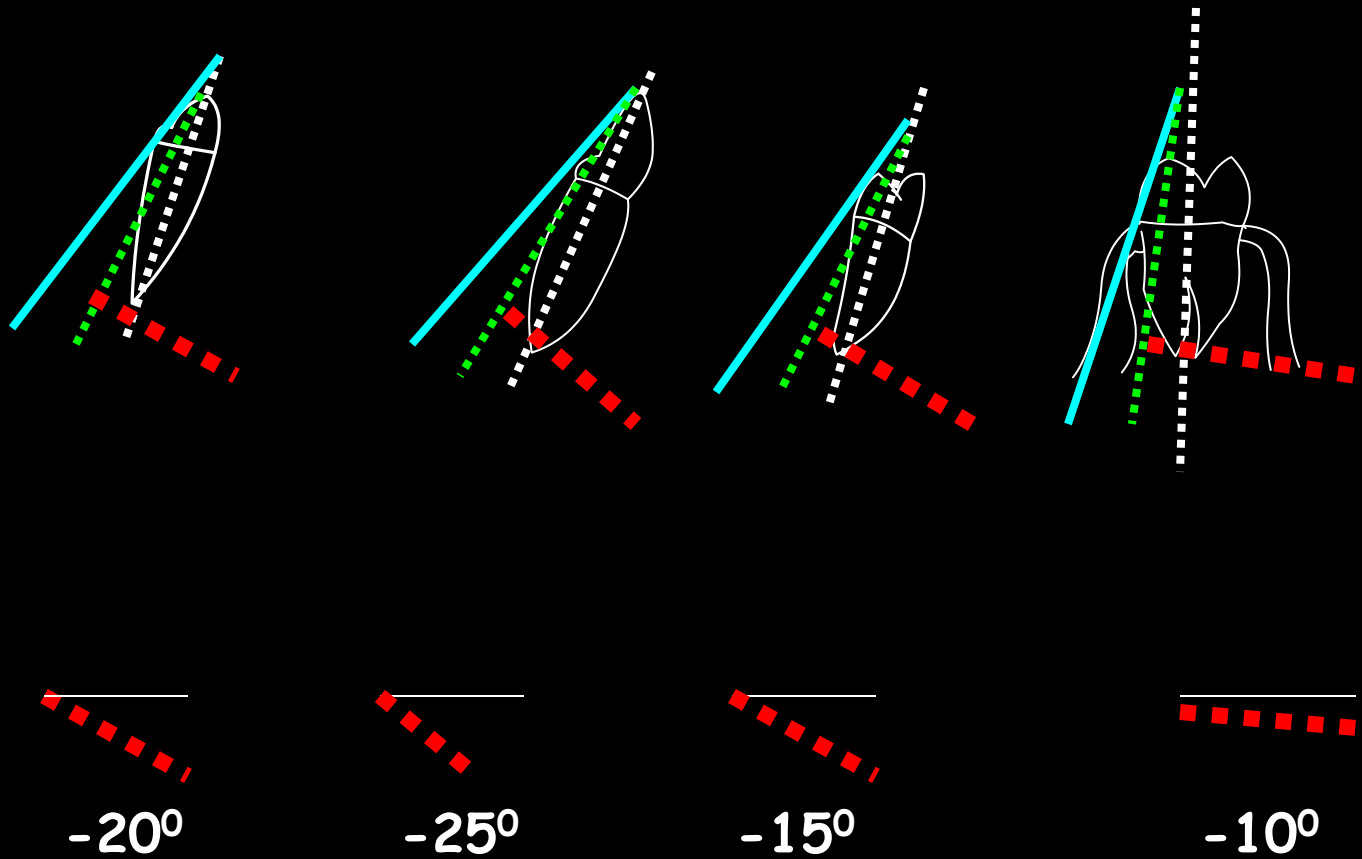
Intra Oral Periapical Radiography

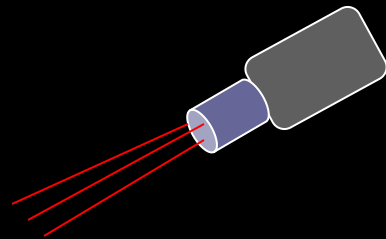
Bisecting the angle / Short cone Technique



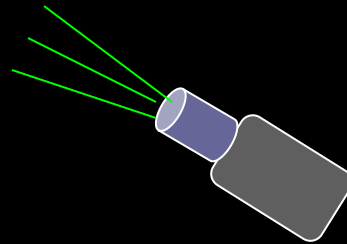
Intra Oral Radiographic Techniques

Mandibular teeth



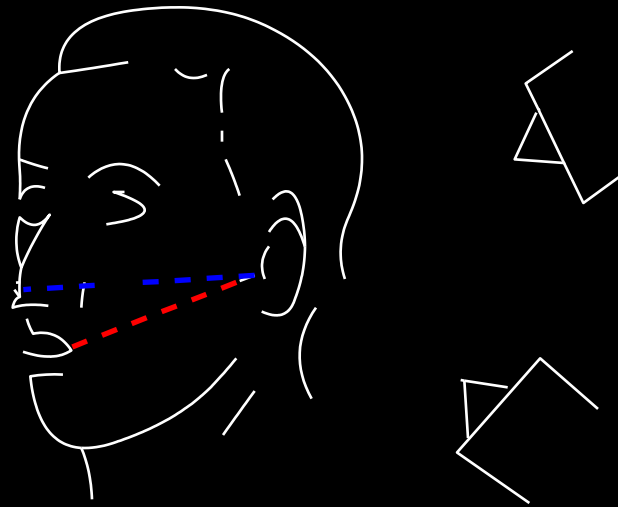


Positive
vertical
angulation

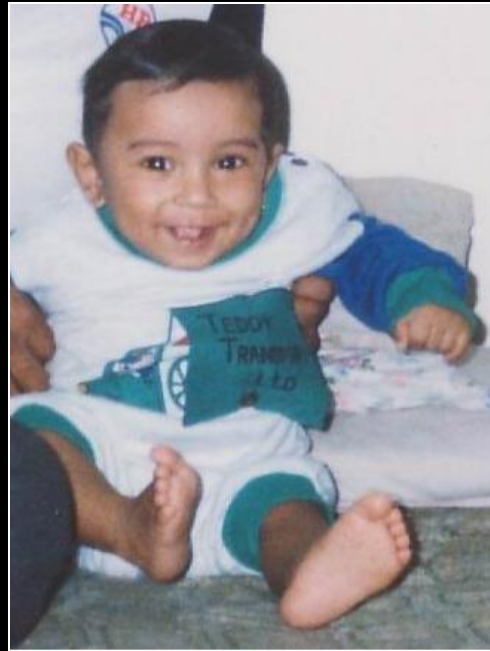

Negative
vertical
angulation


Point of entry on facial skin surface



COMPARE



AND CONTRAST !



COMPARISON

BISECTING THE ANGLE AND PARALLELING TECHNIQUE



BTA

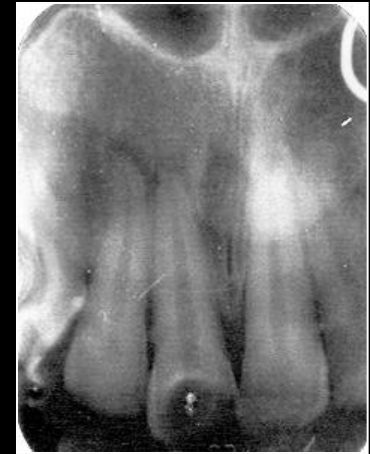

PT

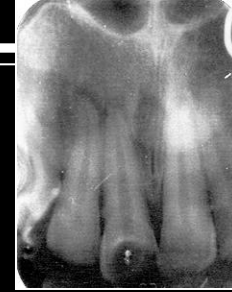COMPARISON

BISECTING THE ANGLE AND PARALLELING TECHNIQUE

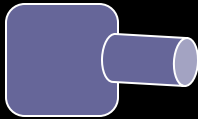
- Full tooth and periapical region seen
- Good resolution with appreciation of fine detail
- Most commonly used radiographic investigation in dental practice
- Does not need significantly costly equipment, both reasonably easy to perform by lay dentist.



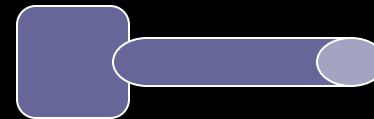
CONTRAST



BISECTING THE ANGLE V/S PARALLELING TECHNIQUE



SHORT CONE TECHNIQUE

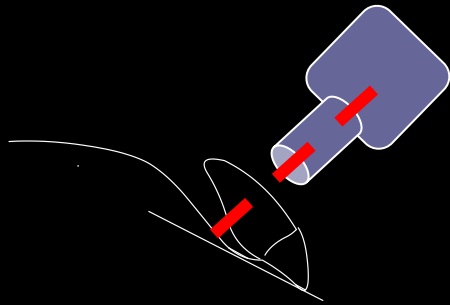


LONG CONE TECHNIQUE /
RIGHT ANGLE TECHNIQUE

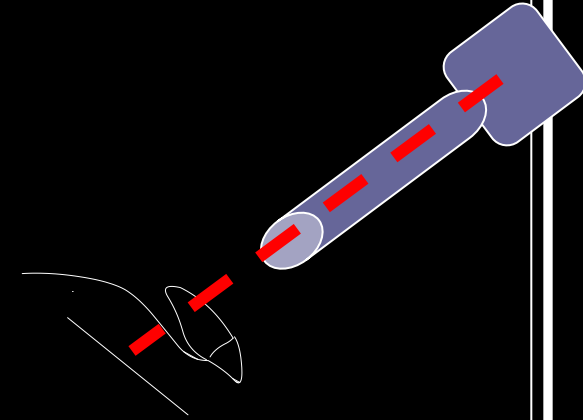
CONTRAST



BISECTING THE ANGLE V/S PARALLELING TECHNIQUE



SFD- 8 inches



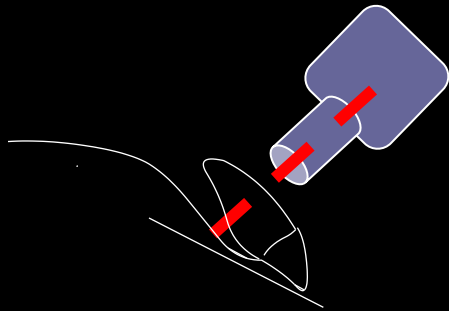
SFD- 16 inches

CONTRAST



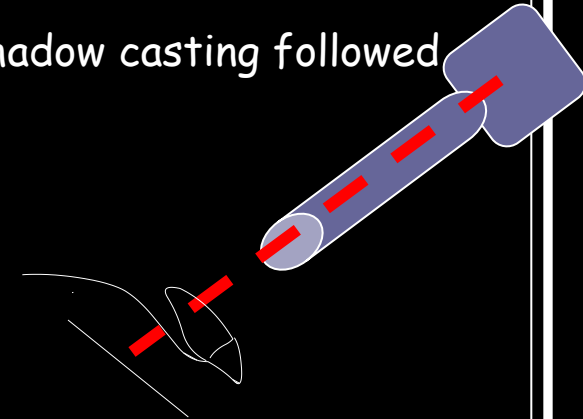
BISECTING THE ANGLE V/S PARALLELING TECHNIQUE

Principles of shadow casting followed



- Small object film distance

Principles of shadow casting followed



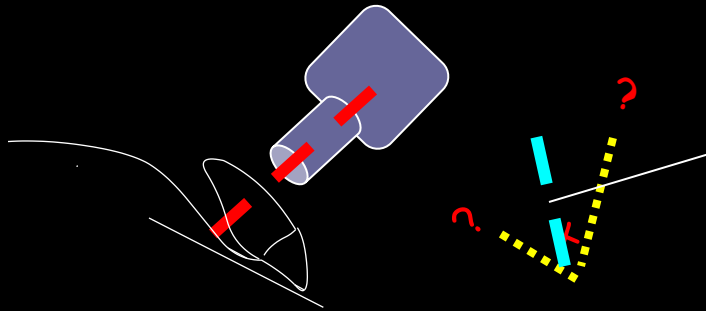
- Film // to object
- Large S-O distance
- C.R \perp both O and film

CONTRAST



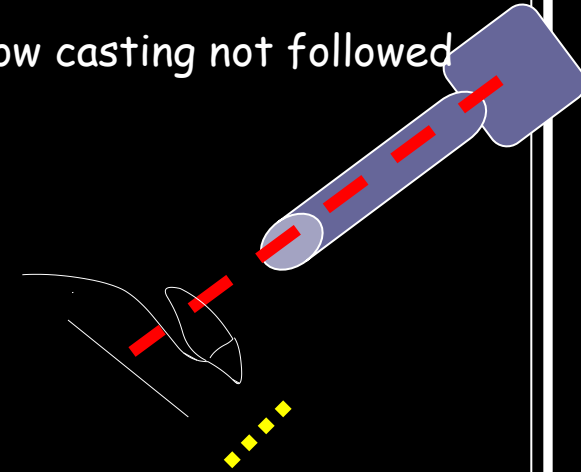
BISECTING THE ANGLE V/S PARALLELING TECHNIQUE

Principles of shadow casting not followed



- O-F //
- CR \perp both O & F

Principles of shadow casting not followed

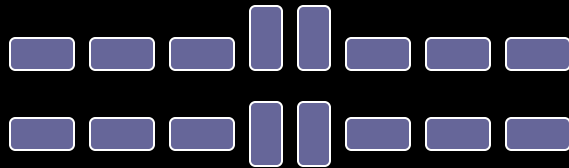


- O-F distance

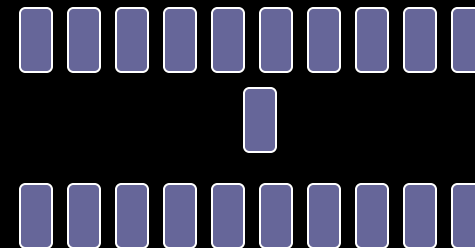
CONTRAST



BISECTING THE ANGLE V/S PARALLELING TECHNIQUE



16 films for full mouth exposure

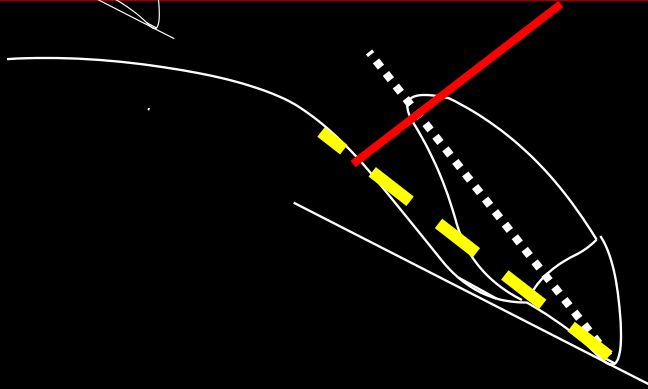


21 films for full mouth exposure

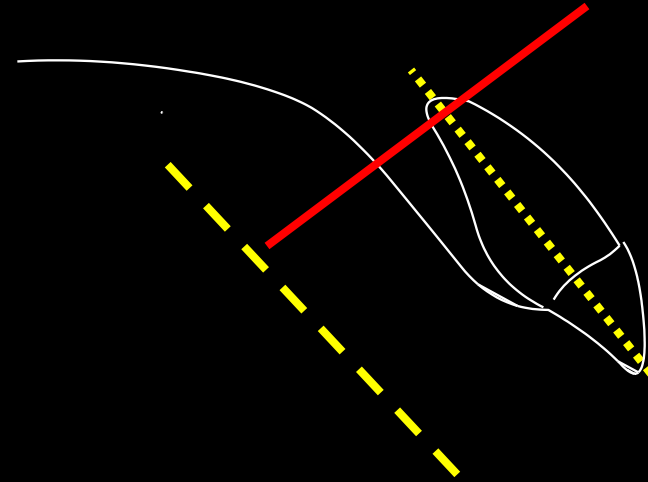
CONTRAST



BISECTING THE ANGLE V/S PARALLELING TECHNIQUE

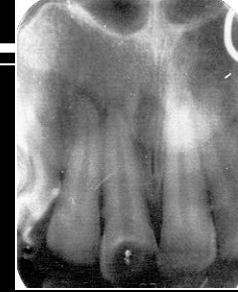

C.R. \perp to bisector



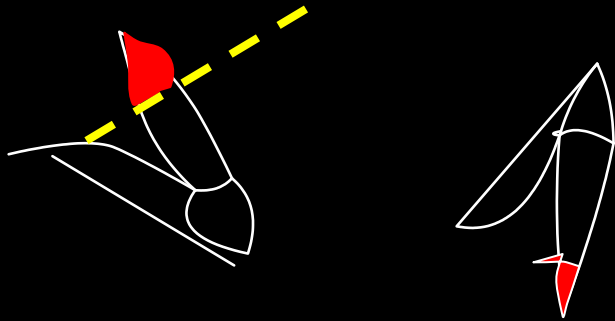
C.R. \perp to both film & tooth long axis

CONTRAST




BISECTING THE ANGLE V/S PARALLELING TECHNIQUE

Anatomical constraints



No Anatomical constraints



COMPARISON

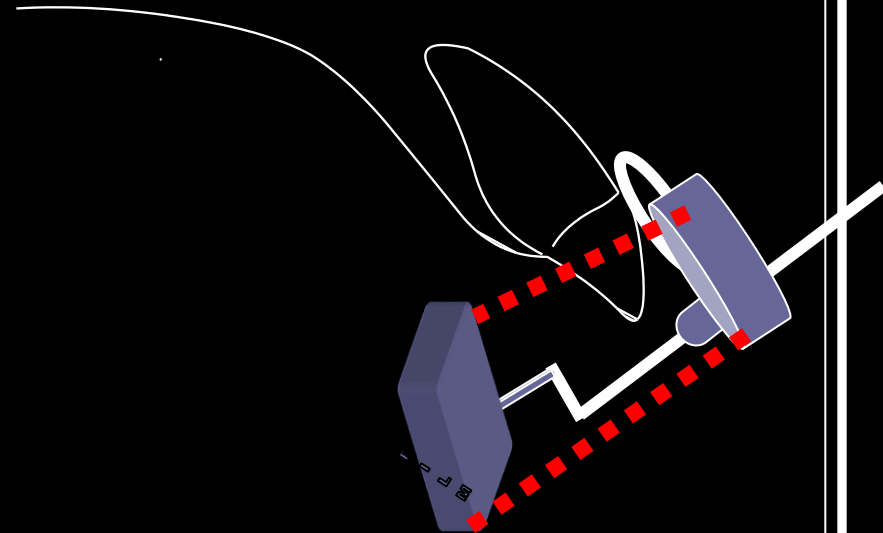
BISECTING THE ANGLE AND PARALLELING TECHNIQUE

Not mandatory, finger/thumb

Film holder mandatory




BTA



PT

COMPARISON

BISECTING THE ANGLE AND PARALLELING TECHNIQUE



BTA

More common



PT

Less common

COMPARISON

BISECTING THE ANGLE AND PARALLELING T



BTA

Lower KVp machine

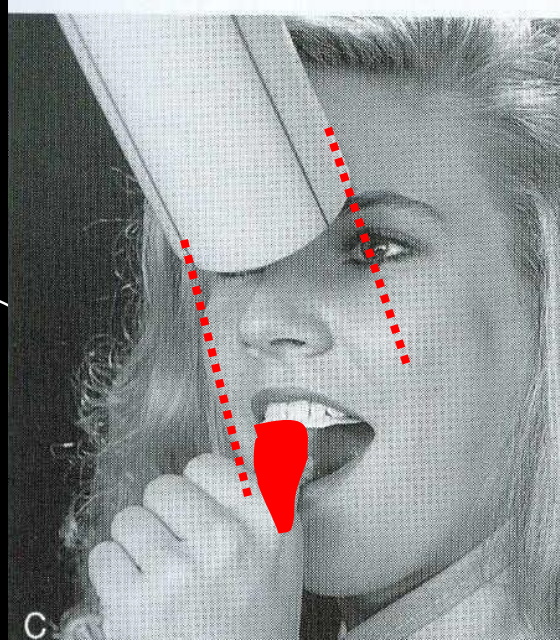


PT

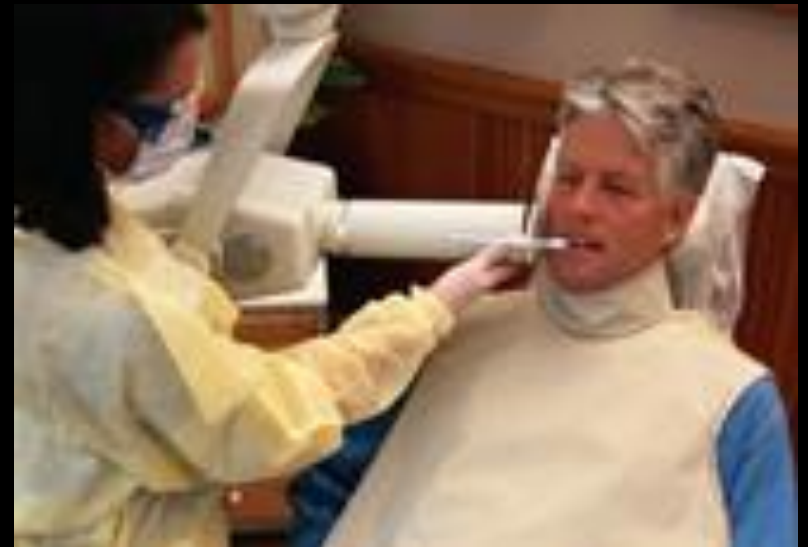Higher KVp machine

COMPARISON

BISECTING THE ANGLE AND PARALLELING TECHNIQUE



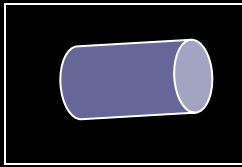
BTA



PT

COMPARISON

BISECTING THE ANGLE AND PARALLELING TECHNIQUE



BTA

Less office space



PT

More office space

COMPARISON

BISECTING THE ANGLE AND PARALLELING TECHNIQUE



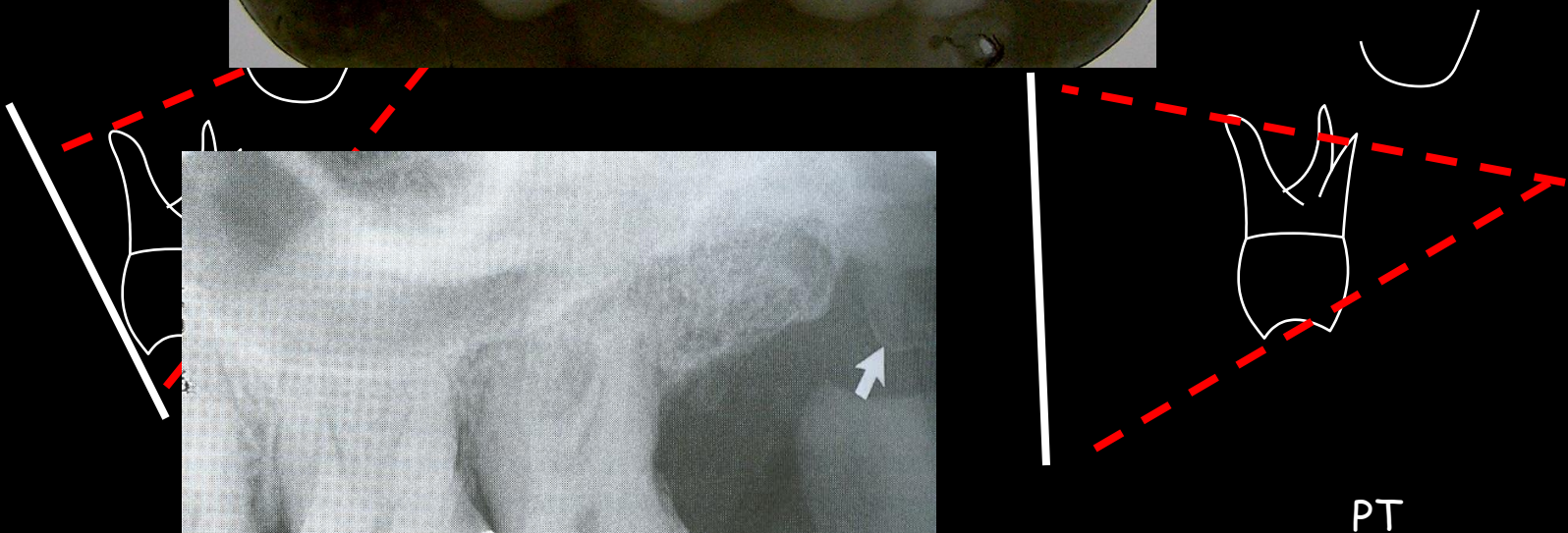
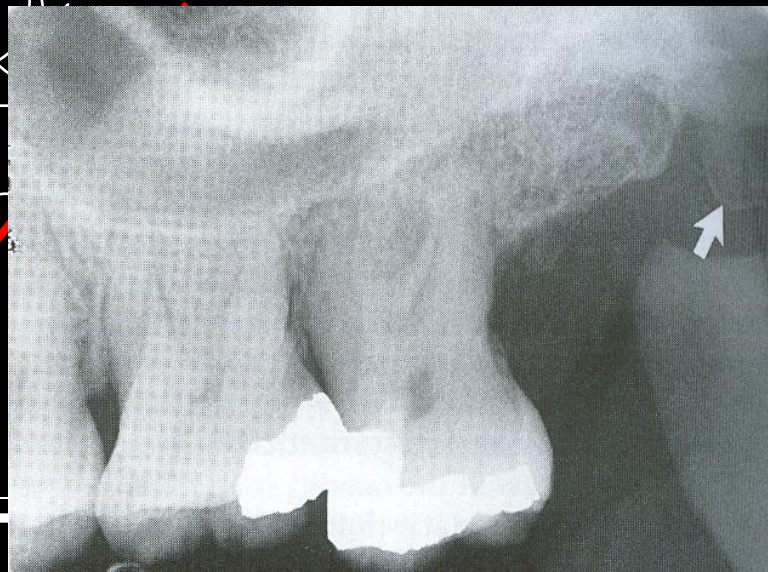
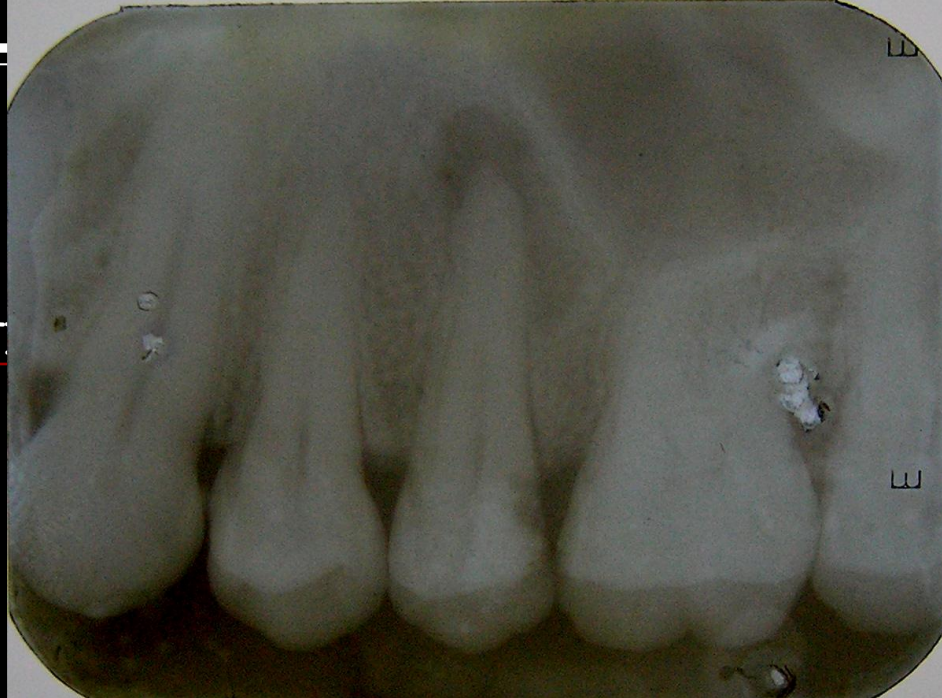BTA



PT

BISECT

NIQUE



PT

