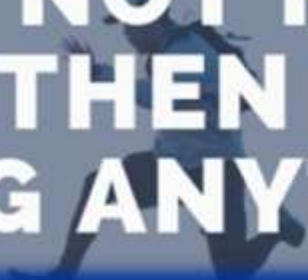

**"IF YOU'RE NOT MAKING  
MISTAKES, THEN YOU'RE  
NOT DOING ANYTHING"**



# Oral Mucous Membrane

Mucous Membrane:

Moist lining of the gastrointestinal tract, nasal passages and other body cavities that communicate with the exterior

In the oral cavity the lining is called as oral mucous membrane or oral mucosa

# Functions of the Oral Mucosa

- **1. Defence:** Barrier for entry of micro-organisms.  
Impermeable to bacterial toxins
- **2. Sensory:** Temperature (heat and cold), touch, pain, taste buds, thirst; reflexes such as swallowing, etching, gagging and salivating
- **3. Secretion:** Salivary secretion
- **4. Thermal regulation:** Important in dogs not in humans
- **5. Protection:** Protects deeper tissues from mechanical forces

# Classification of the Oral Mucosa

According to FUNCTION

```
graph TD; A[According to FUNCTION] --> B[1. Masticatory Mucosa:]; A --> C[2. Lining Mucosa:]; A --> D[3. Specialized Mucosa:];
```

1. Masticatory Mucosa:

2. Lining Mucosa:

3. Specialized Mucosa:

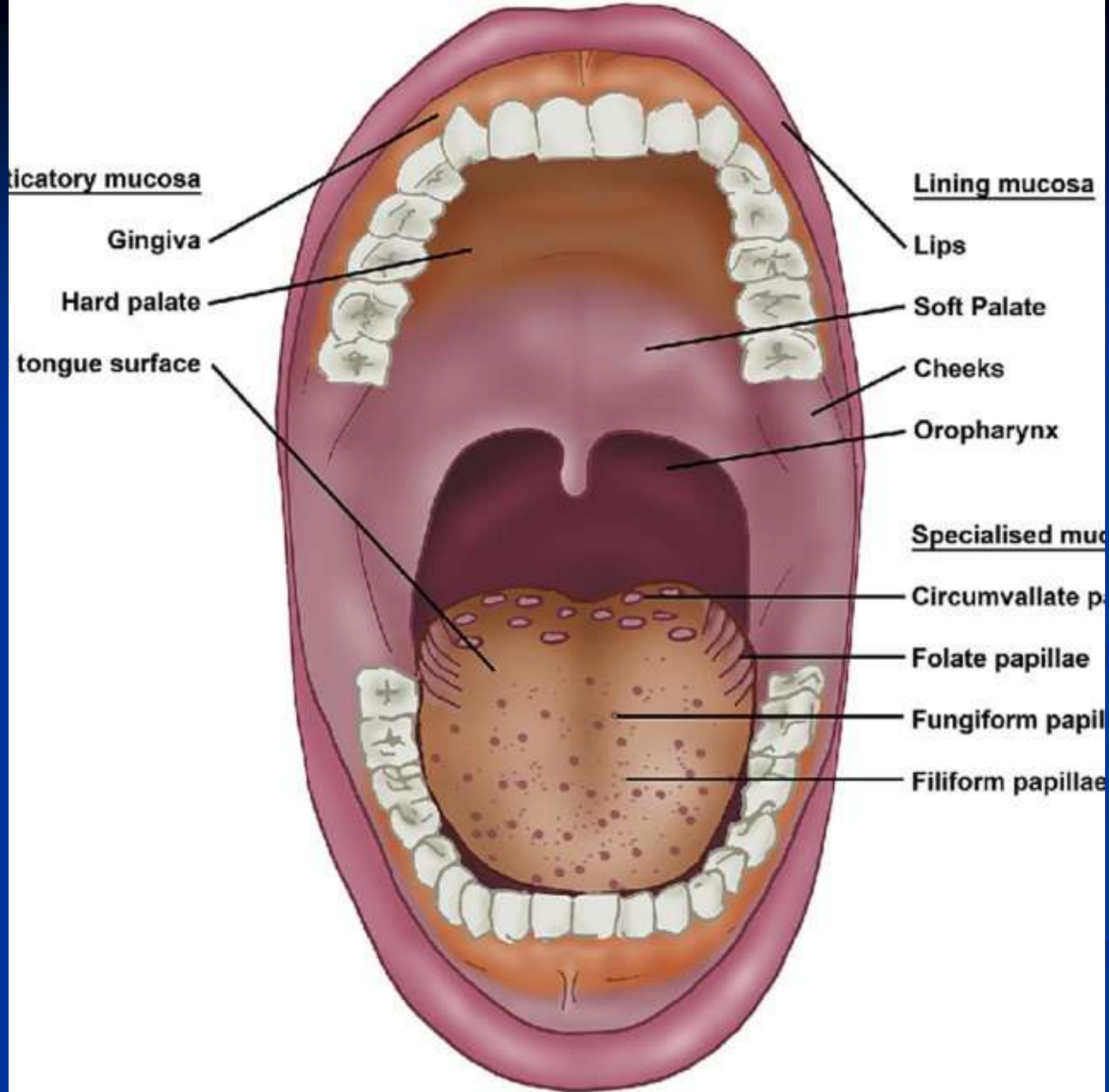
# Classification of the Oral Mucosa

according to HISTOLOGY

```
graph TD; A[according to HISTOLOGY] --> B[1. Keratinised]; A --> C[2. Non- Keratinised];
```

1. Keratinised

2. Non- Keratinised



# 1. Masticatory Mucosa

- 25% of total mucosa.
- **Gingiva** (free, attached and interdental)
- **Hard palate.**
- Primary mucosa to be in contact with food during mastication.
- MASTOCATORY MUCOSA IS USUALLY KERATINIZED.

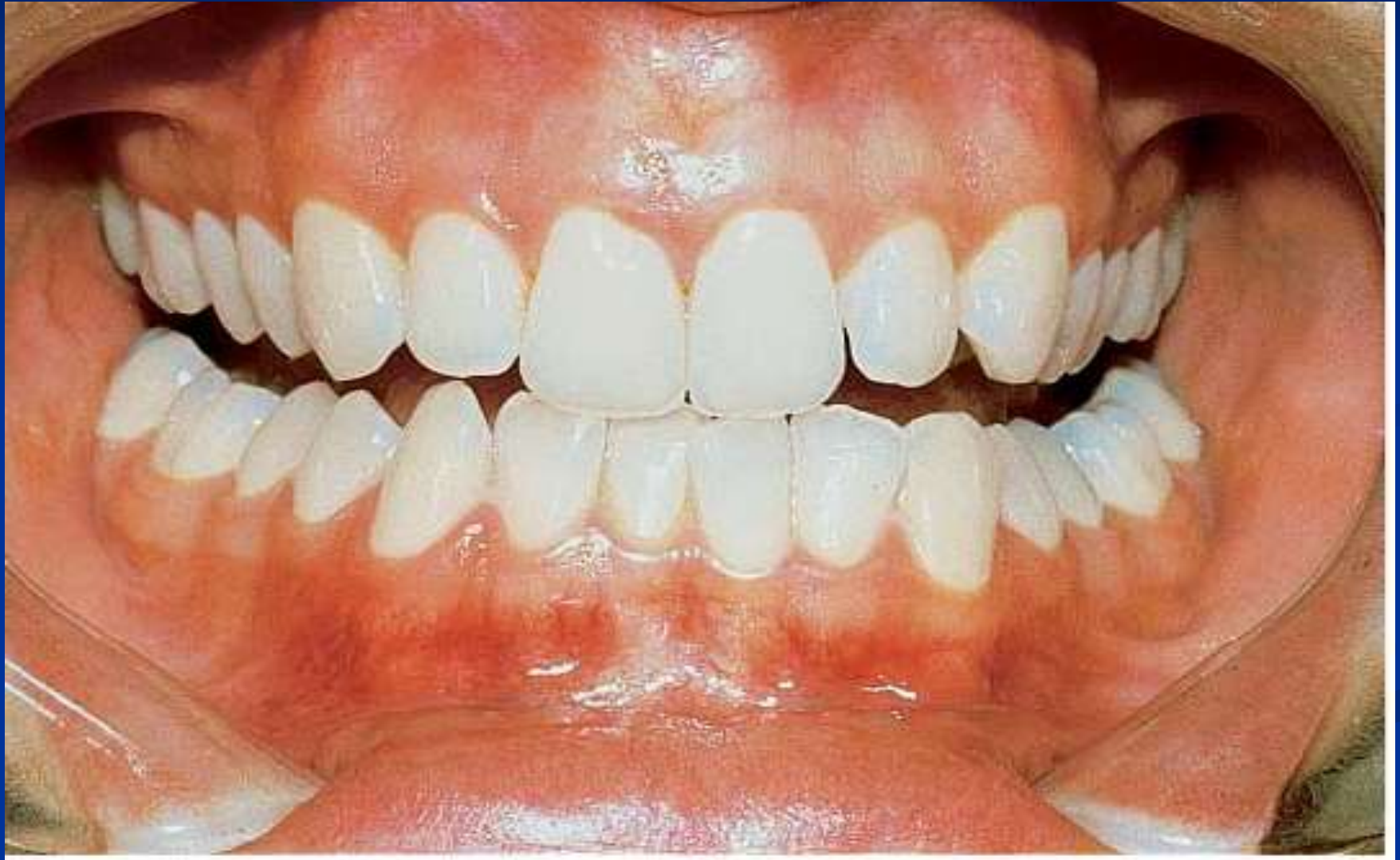## 2.Lining Mucosa:

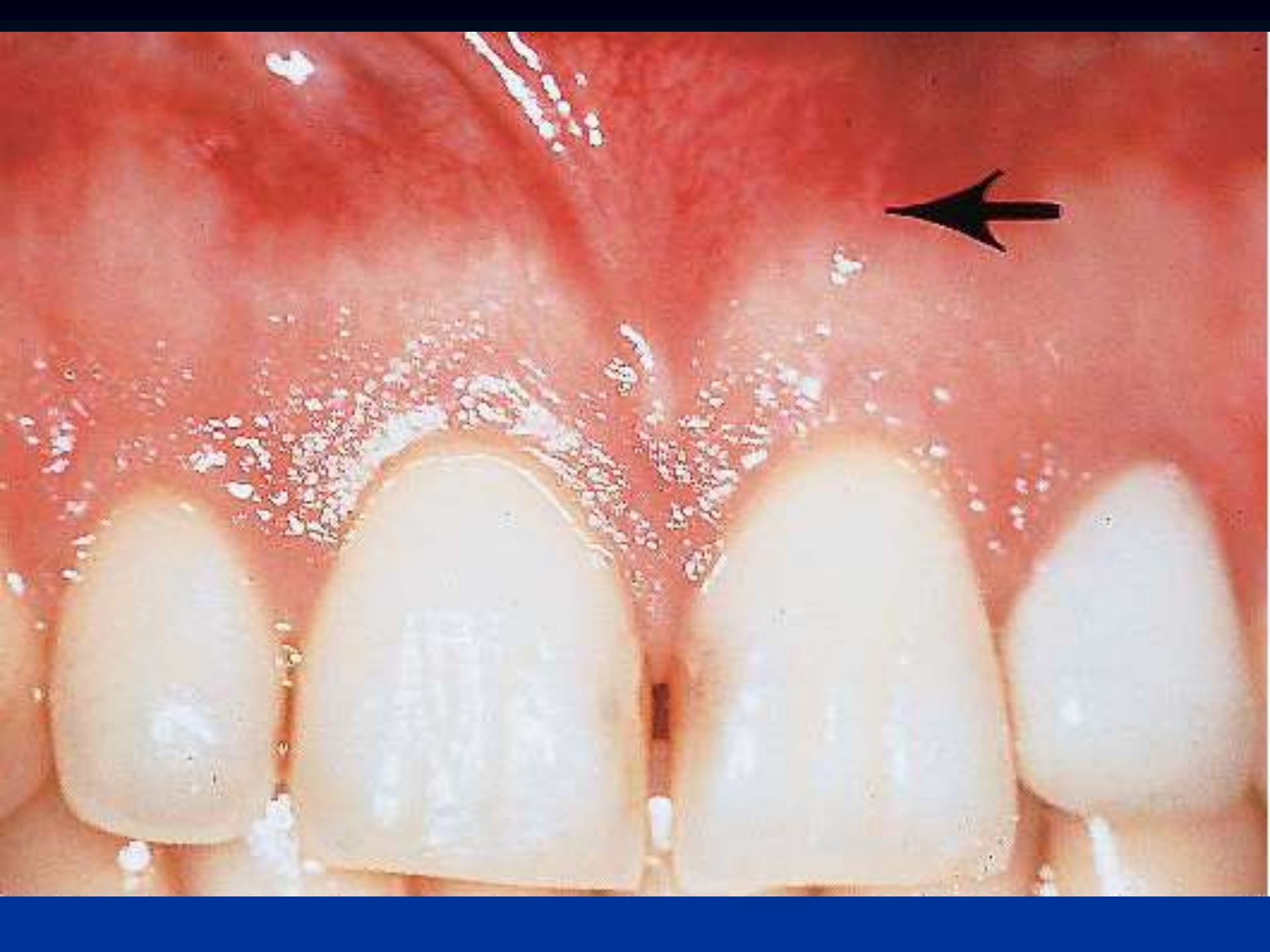- 60% of total mucosa.
- Covers the floor of mouth, ventral (underside) tongue, alveolar mucosa, cheeks, lips and soft palate.
- Does not function in mastication and therefore has minimal attrition.
- Non-keratinized; soft and pliable.

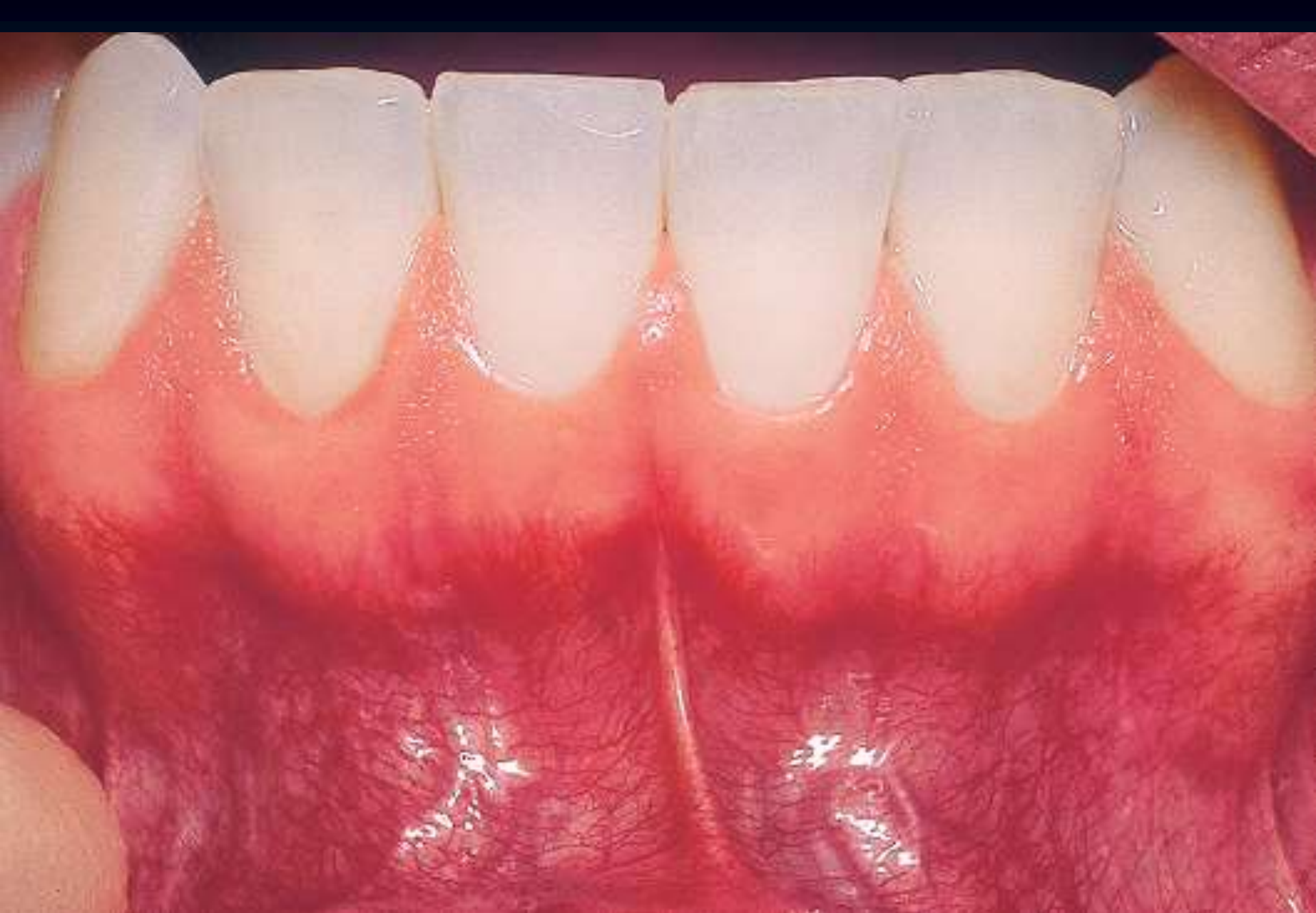# 3.Specialized Mucosa:

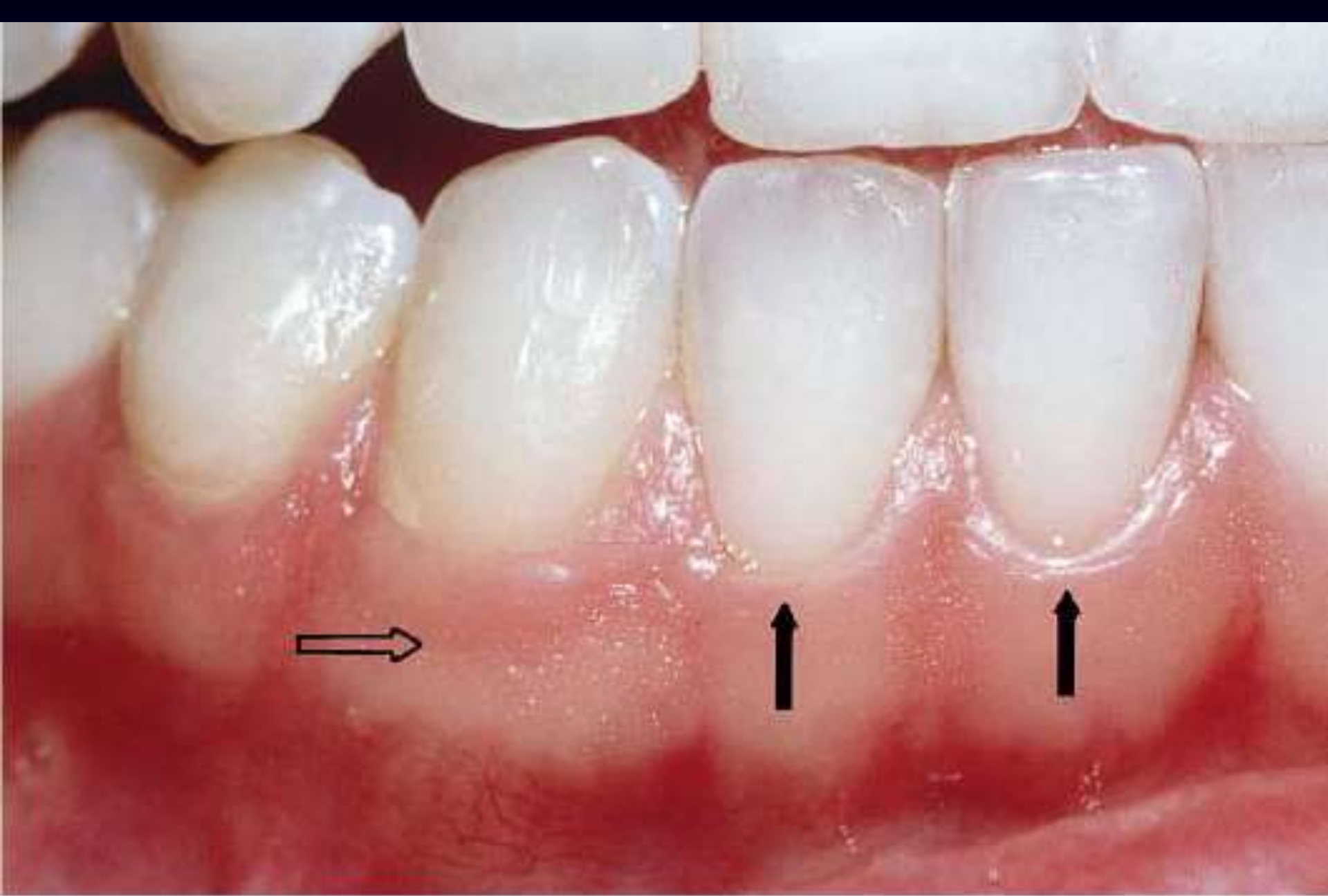
- 15% of total mucosa.
- Covers **Dorsal surface of tongue** and composed of cornified epithelial papillae and **Taste buds**.

# Masticatory Mucosa

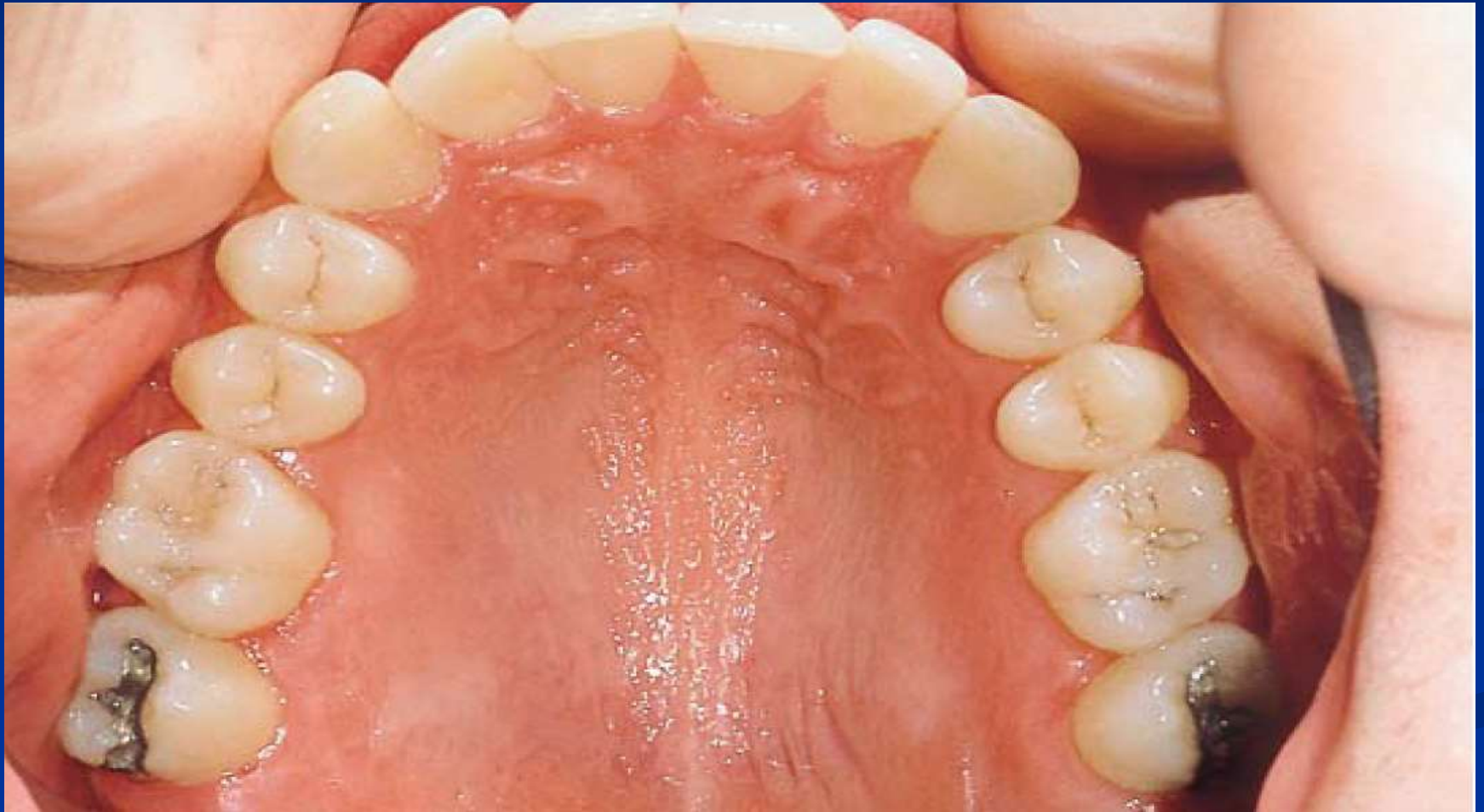




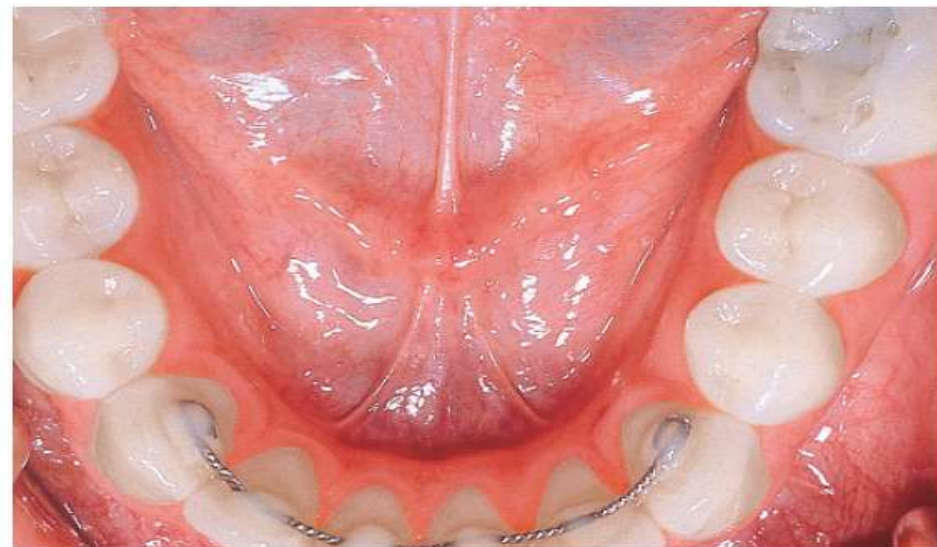
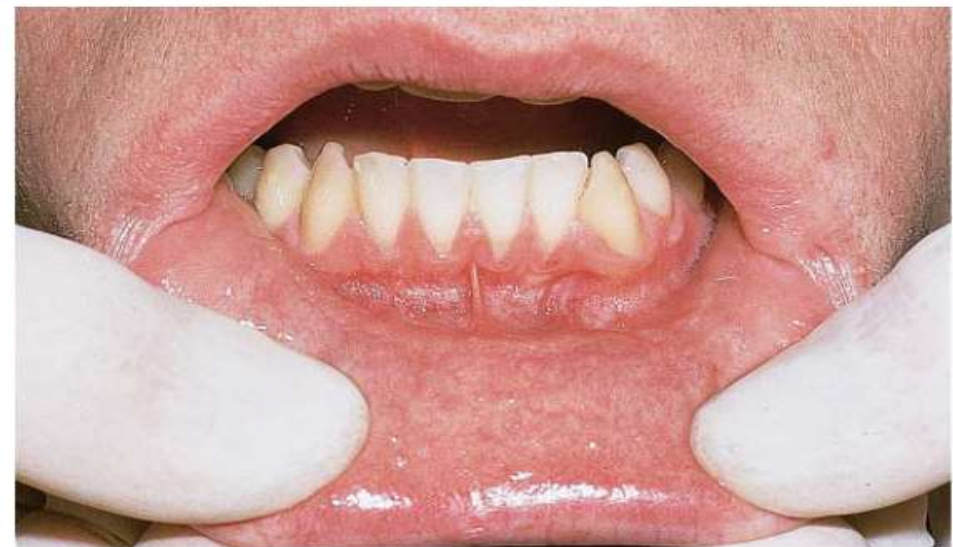
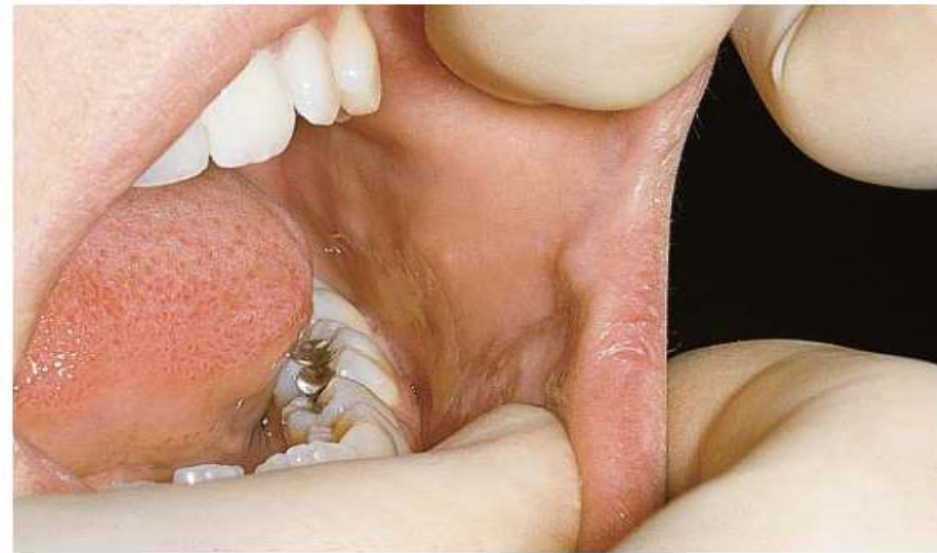
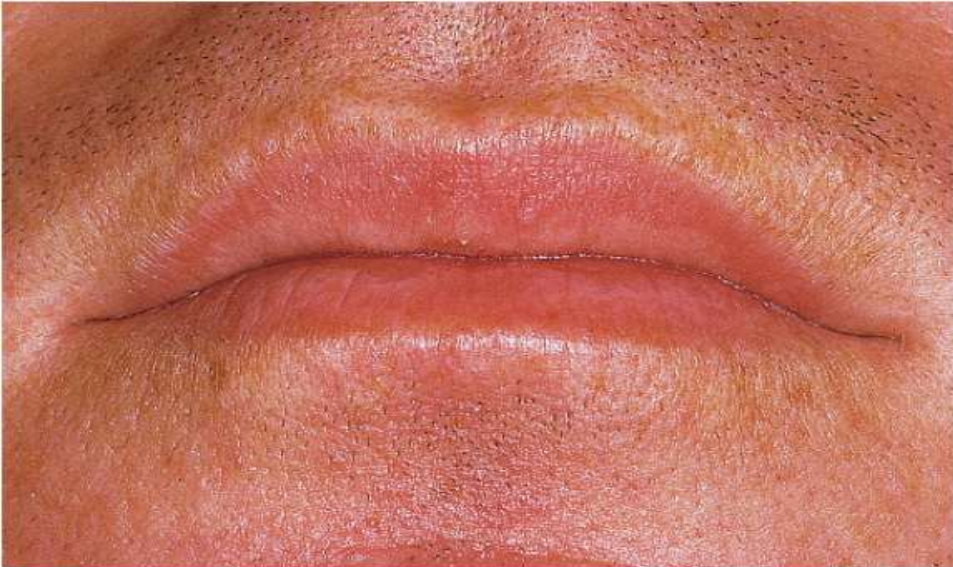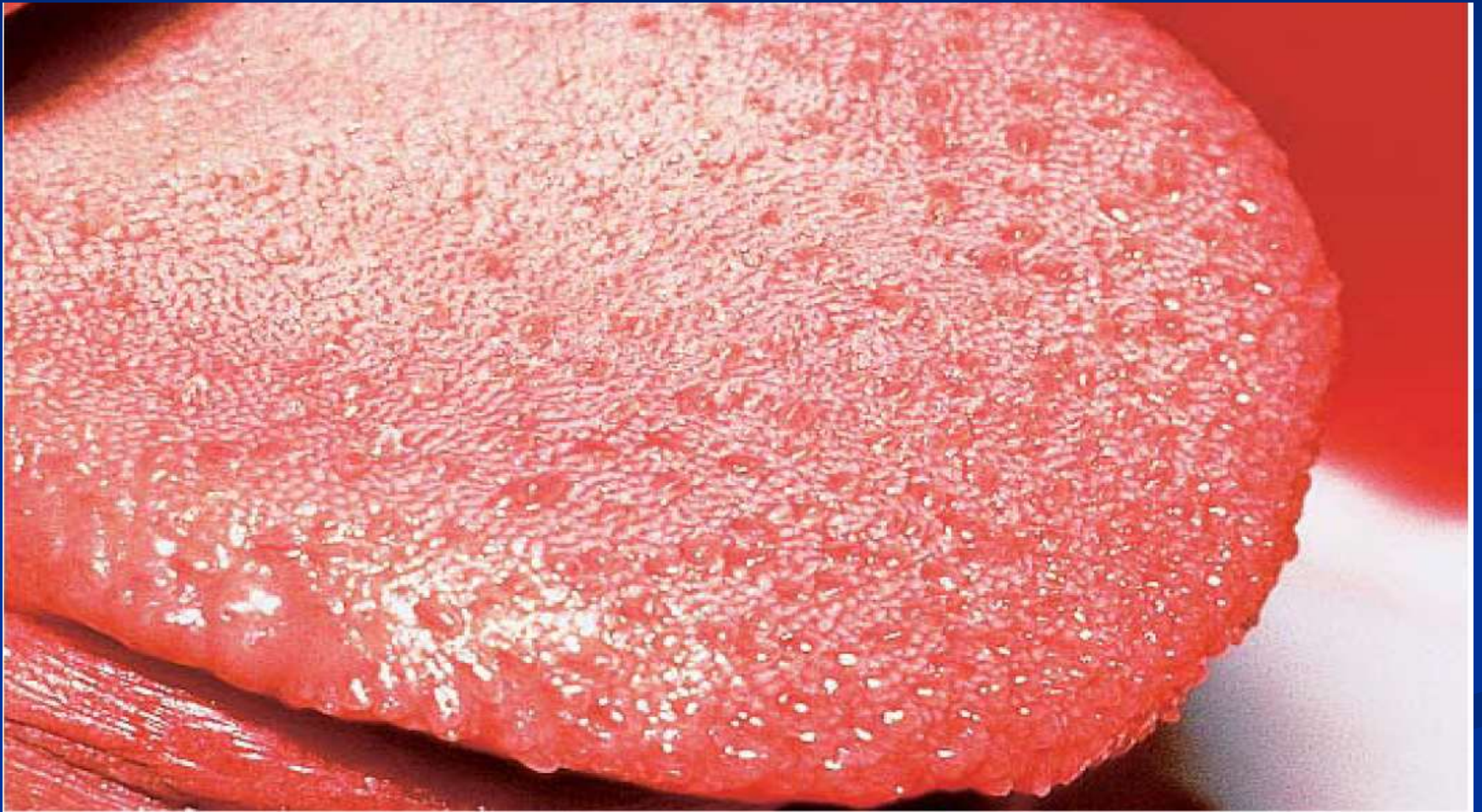# Masticatory Mucosa

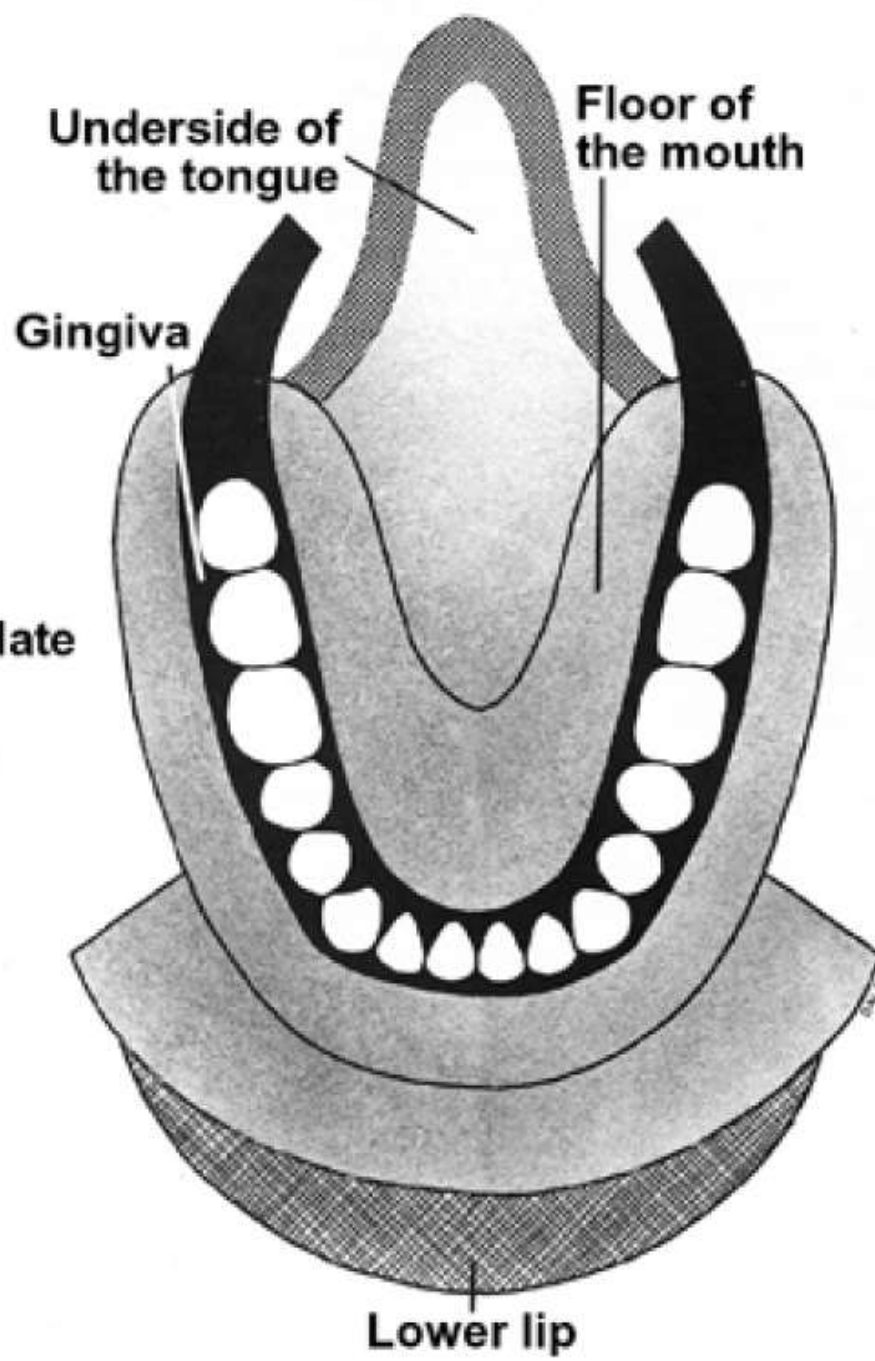
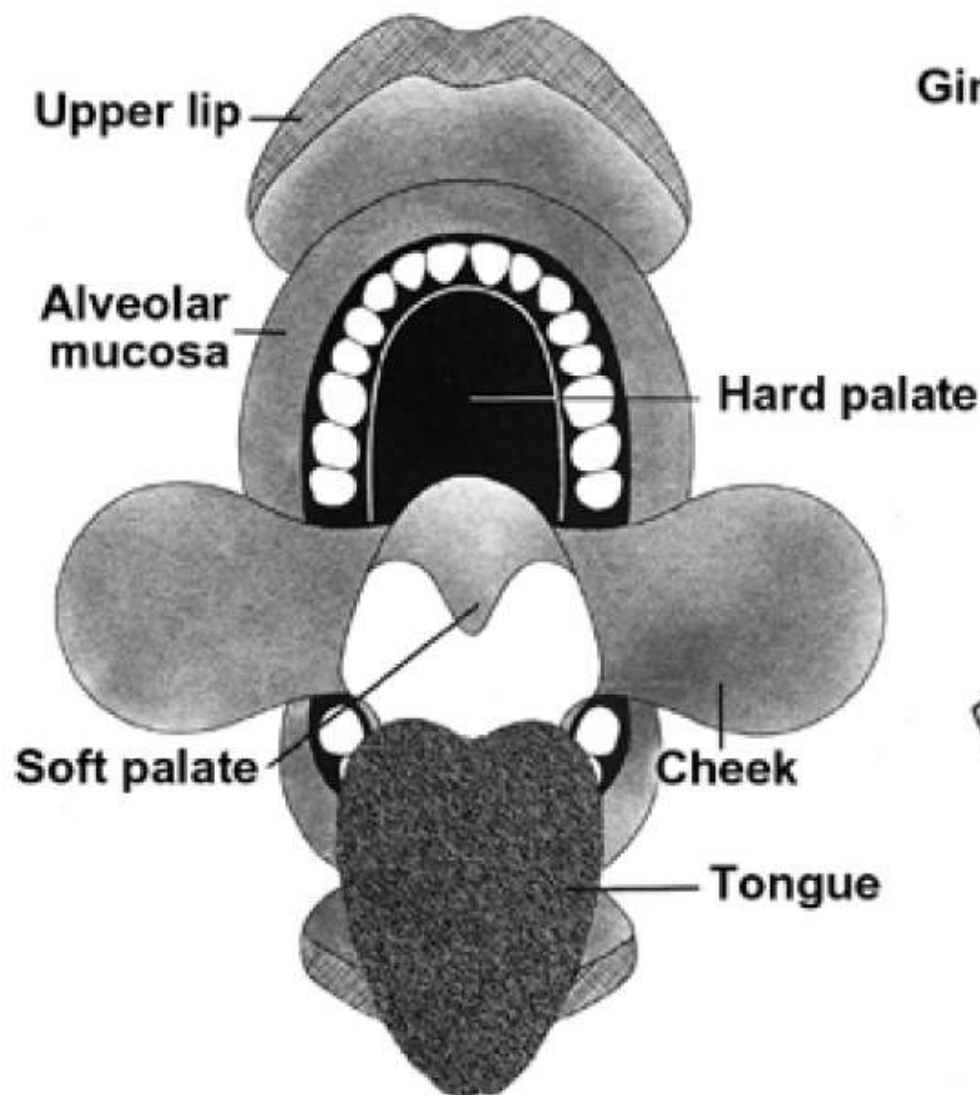


# Lining Mucosa



# Specialized Mucosa



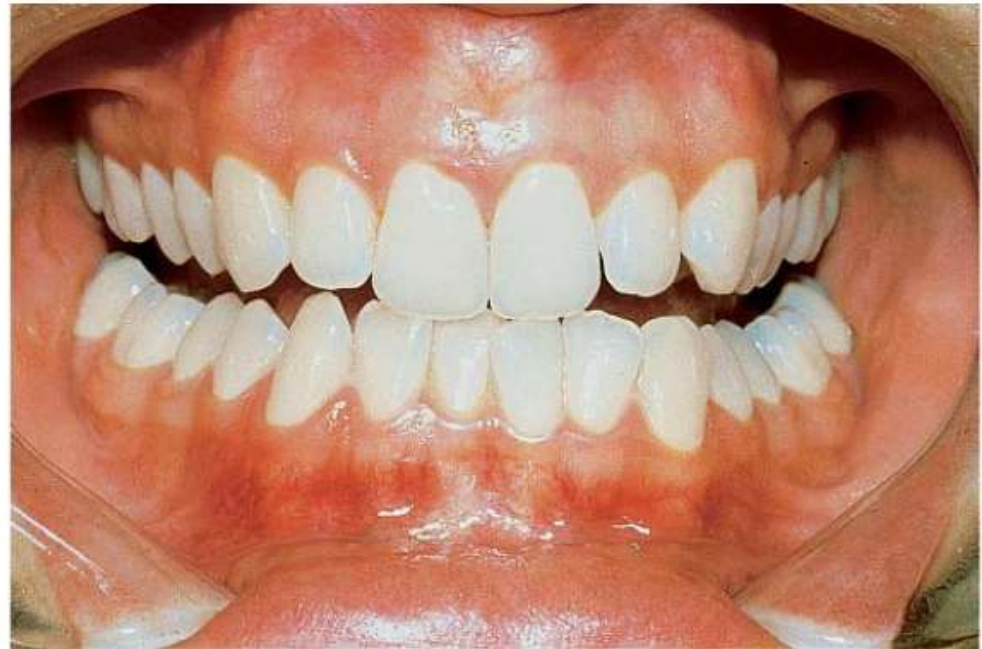
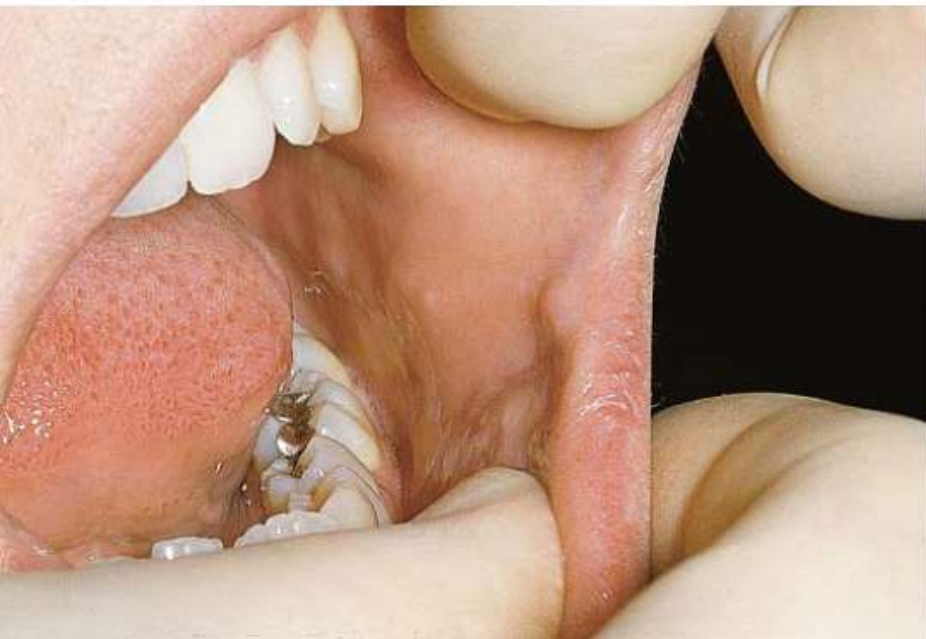
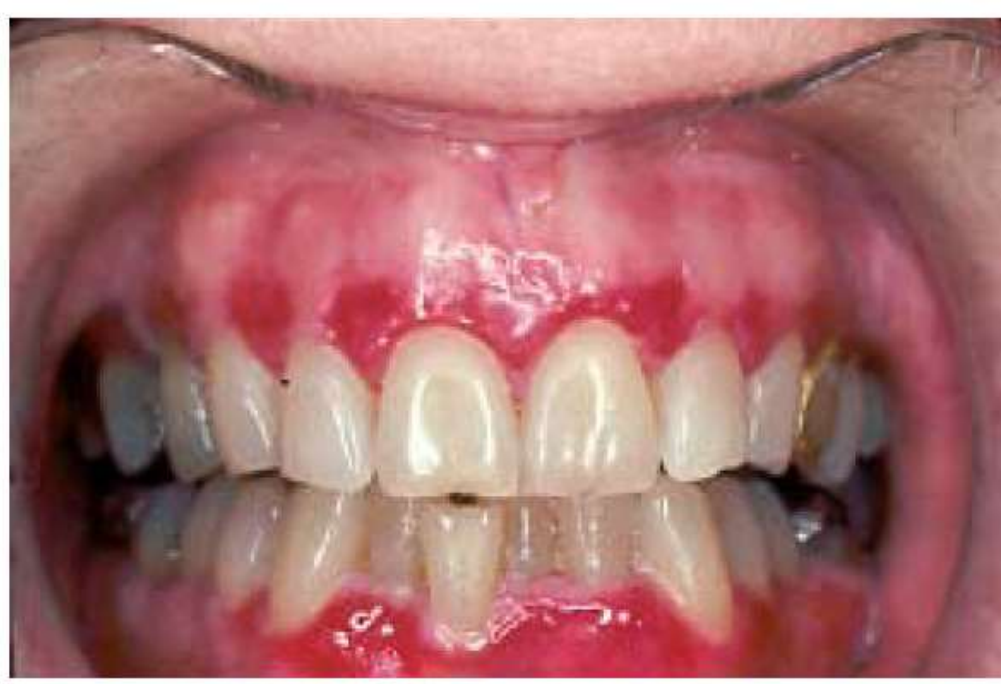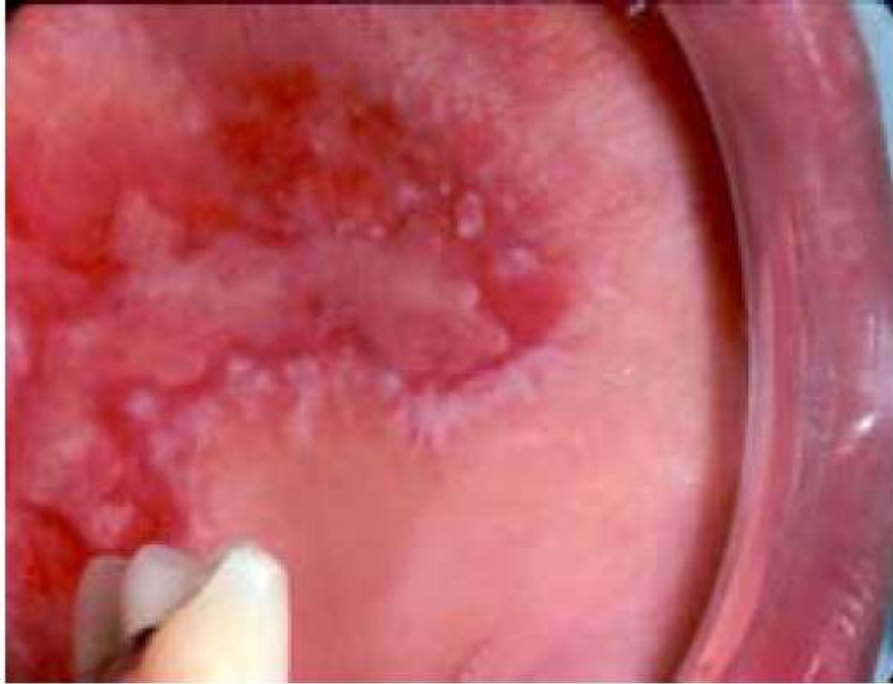# General Features of Oral Mucosa

1. Separated from the skin by **vermillion zone** of the lips which is more deeply colored than rest of the oral mucosa
2. **Factors affecting color of the oral mucosa:**
  - a. Concentration and state of dilation of the blood vessels in underlying connective tissue
  - b. Thickness of the epithelium.
  - c. Degree of keratinization.
  - d. Amount of melanin pigmentation

Clinically, color of oral mucosa is very important.

For example, inflamed oral tissues appear red rather than the normal **pale pink**



How is the oral  
mucosa  
different from  
skin?

1. Color

2. Moist surface

3. Absence of **adnexal skin structures** such as hair follicles, sweat glands and sebaceous glands (exception in Fordyce's disease)

4. Fordyce's disease: **Sebaceous glands** in oral cavity predominantly in upper lip, buccal mucosa and alveolar mucosa

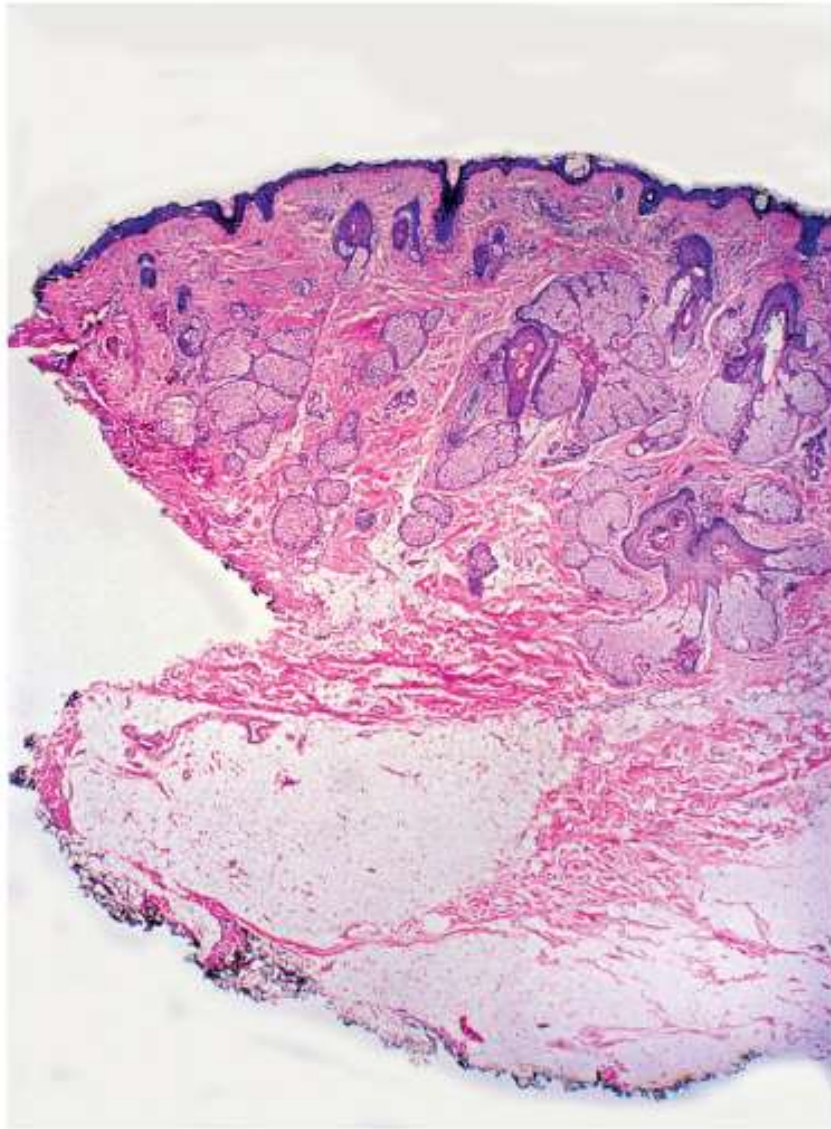
5. Presence of **minor salivary glands** in oral mucosa

6. **Texture of surface**: Oral mucosa is smoother than the skin (few exceptions like dorsal tongue –due to papillae; hard palate –rugae; gingiva –stippling)

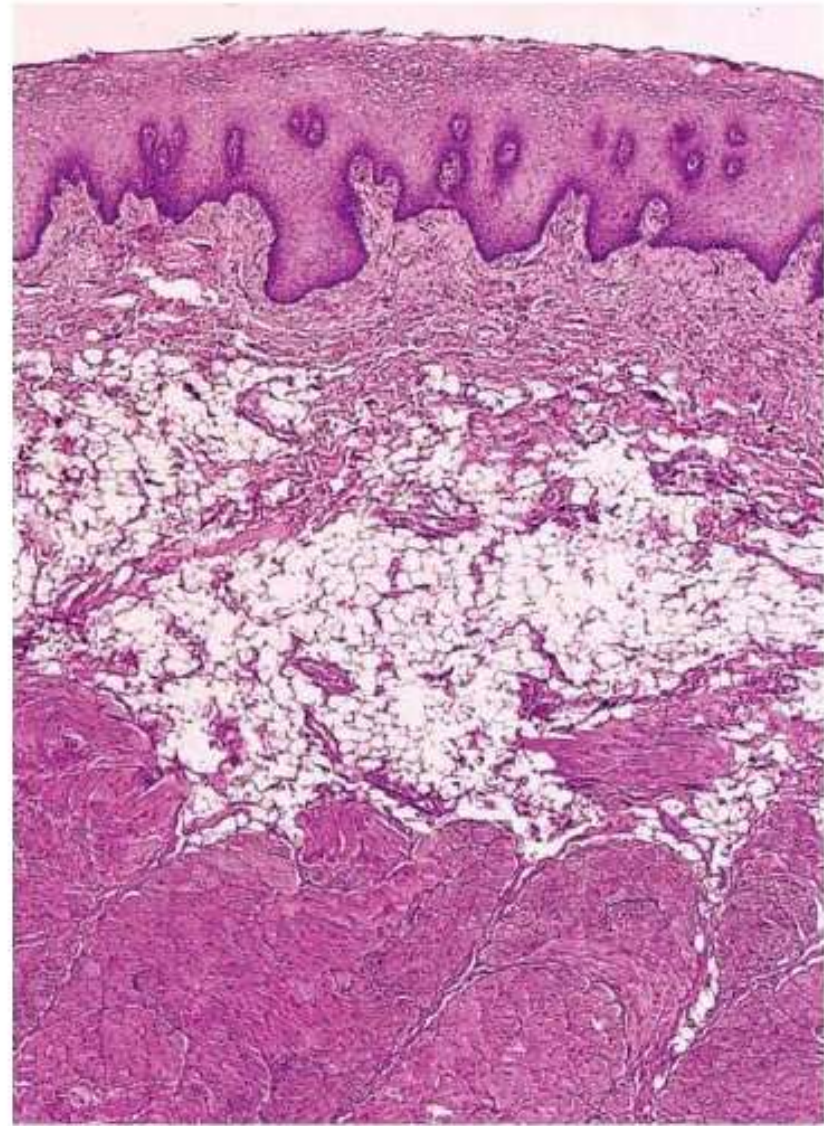
7. **Firmness:** Oral mucosa varies in its firmness.

For example buccal mucosa and lips are loose and pliable whereas the gingiva and hard palate are firm so critical clinically while giving injections

Skin

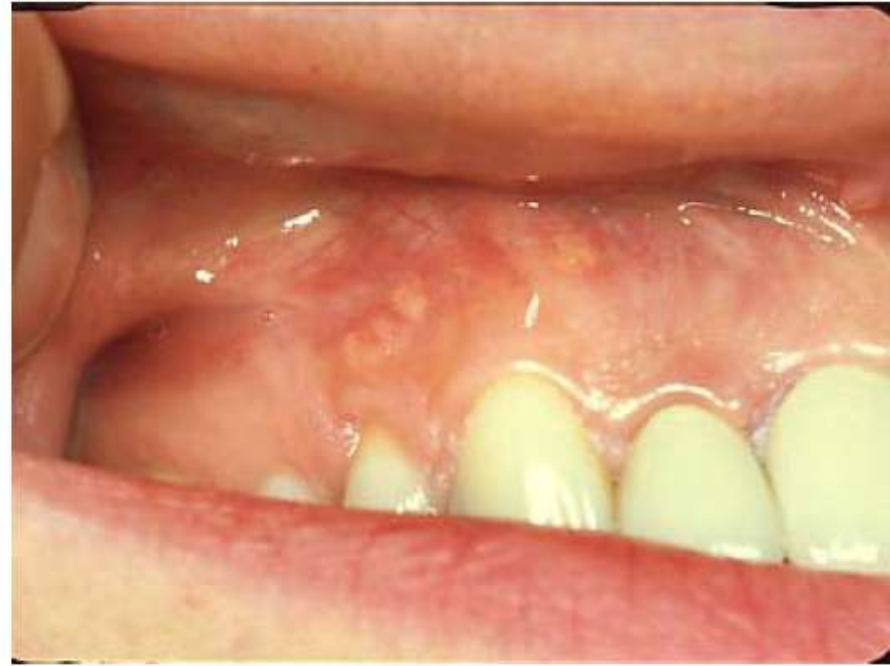
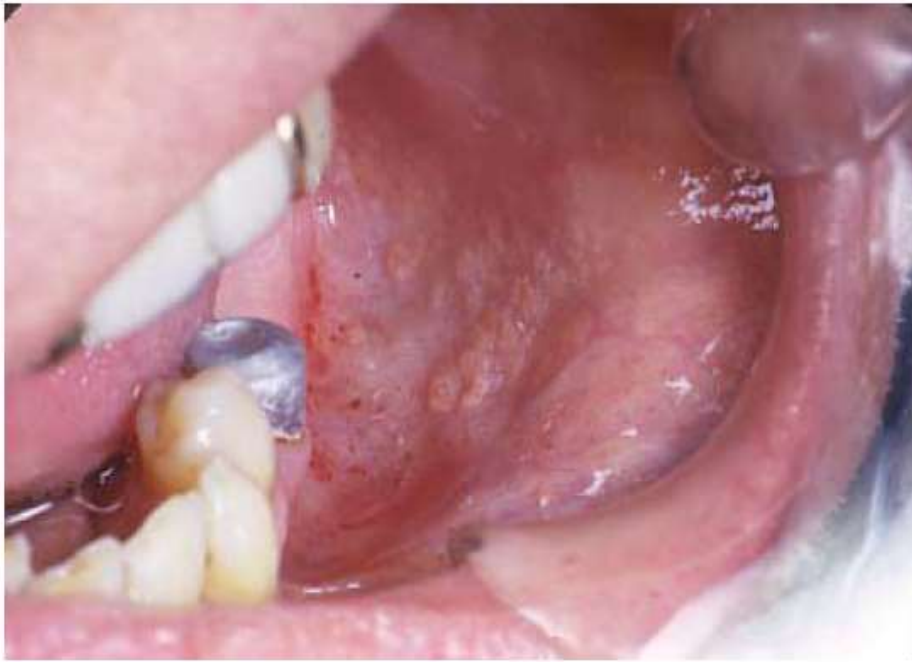
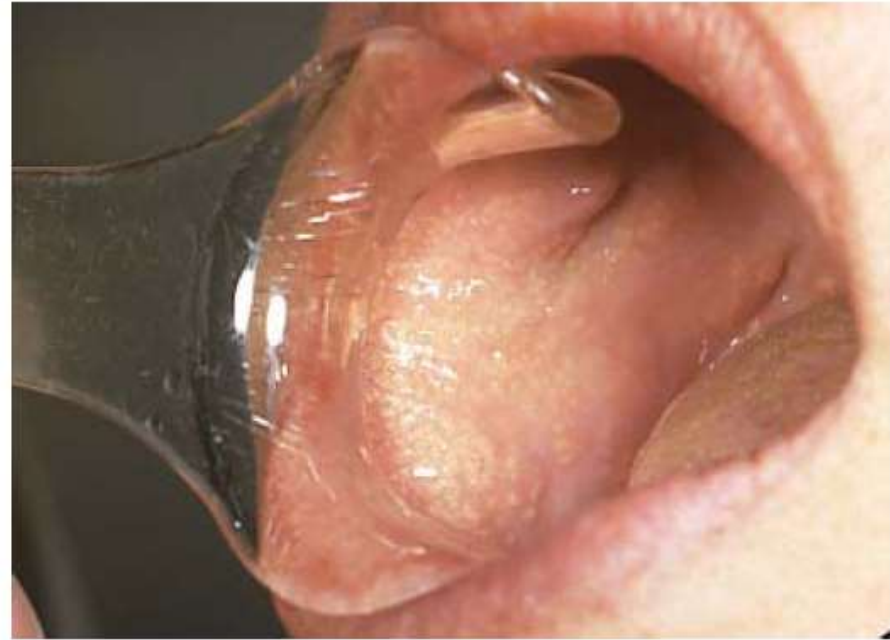Oral Mucosa-Cheek



# Fordyce's Disease

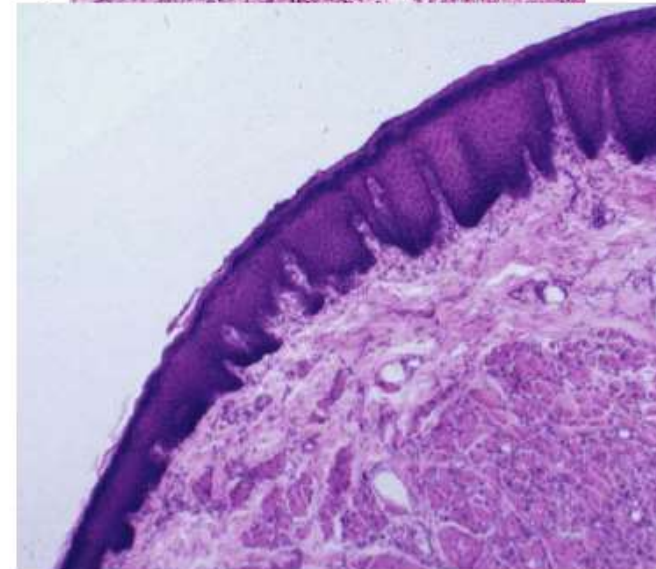
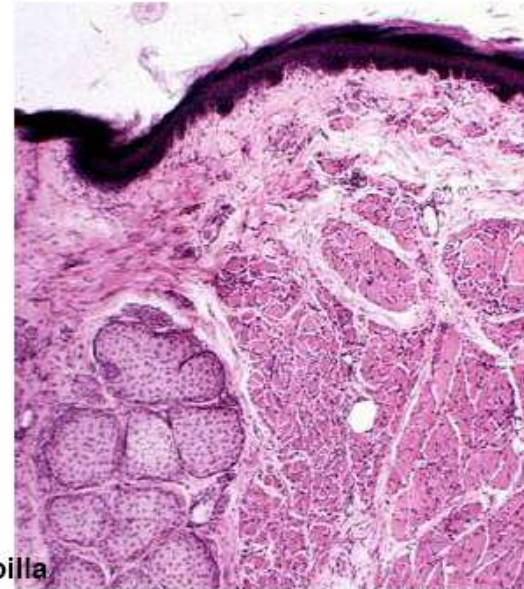
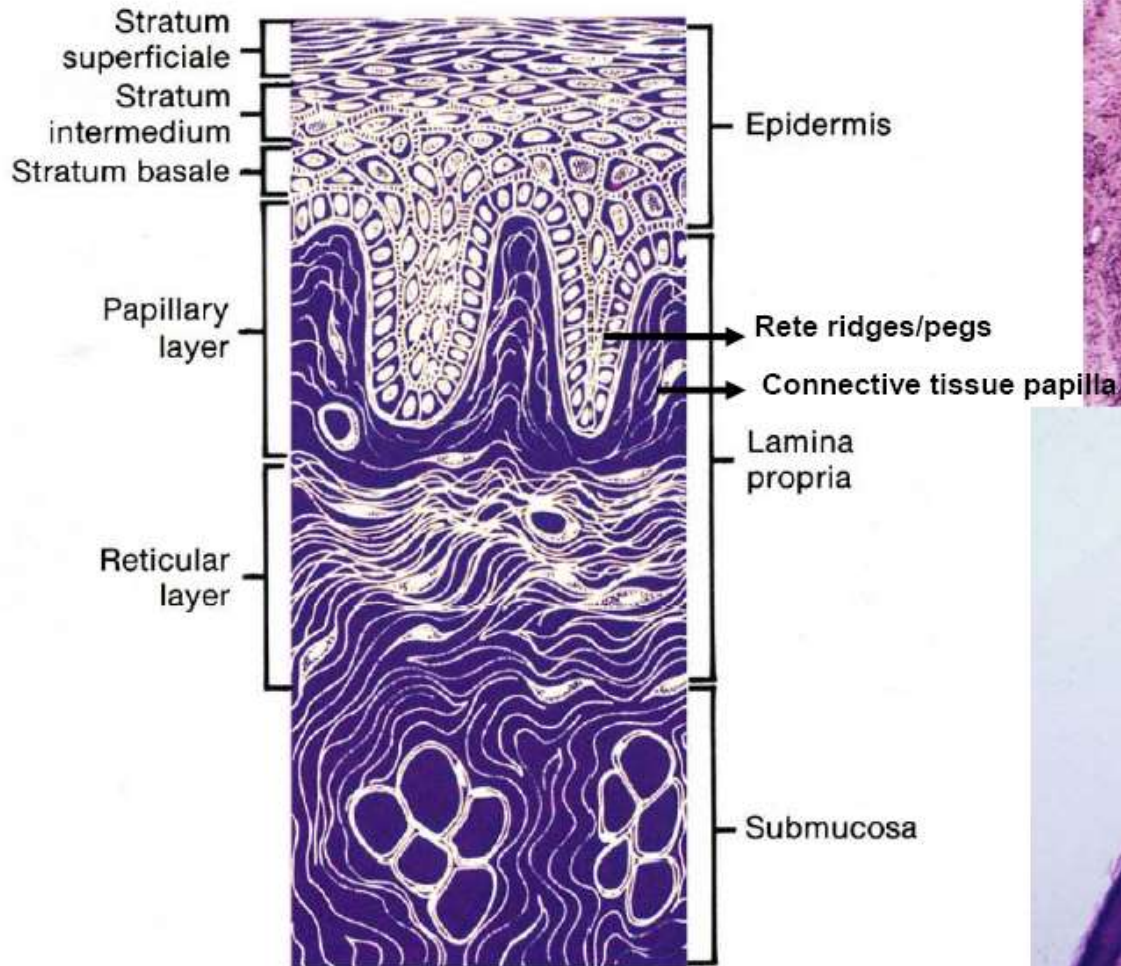
- Pale yellow spots
- Normal variation
- Lips, buccal mucosa, alveolar mucosa and tonsillar pillar

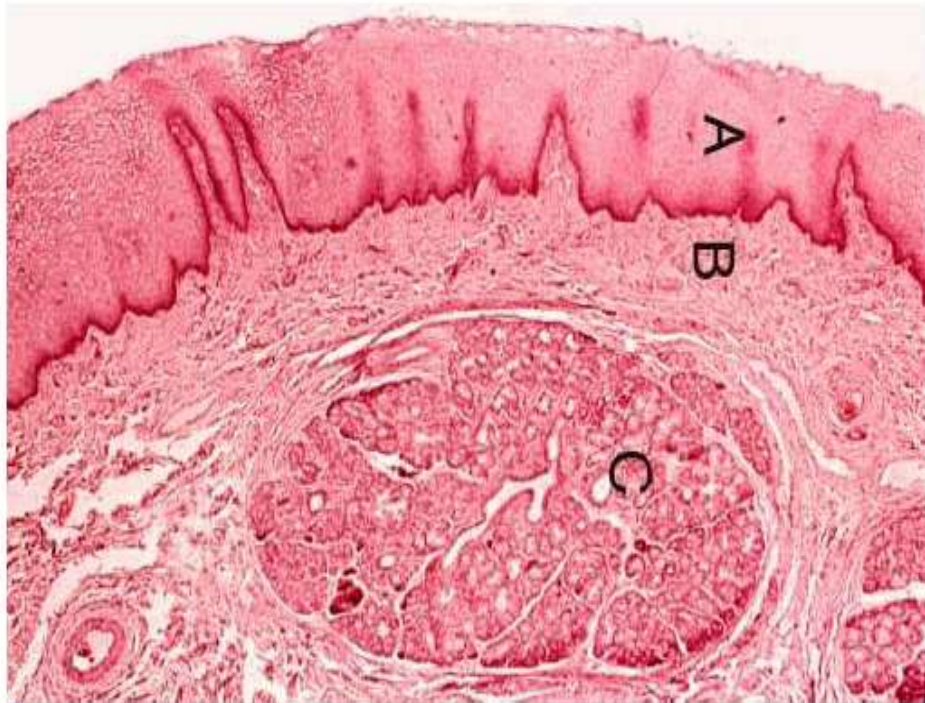


# Structure of Oral Mucosa

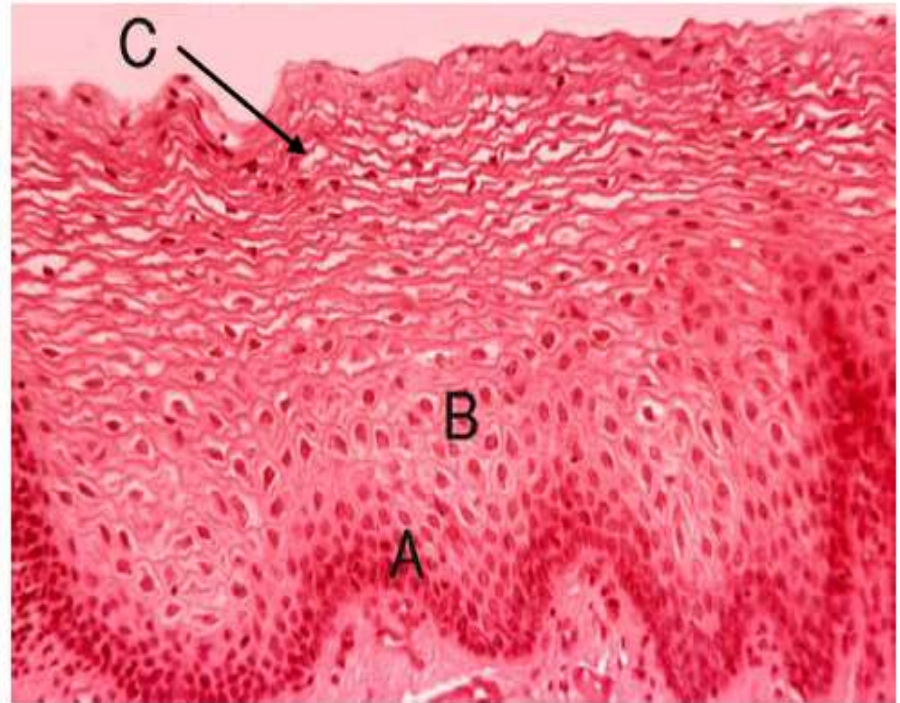
1. Overlying oral epithelium
2. Underlying connective tissue (lamina propria and submucosa)

In skin called epidermis and dermis





- A: Epithelium
- B: Connective tissue
- C: Salivary gland

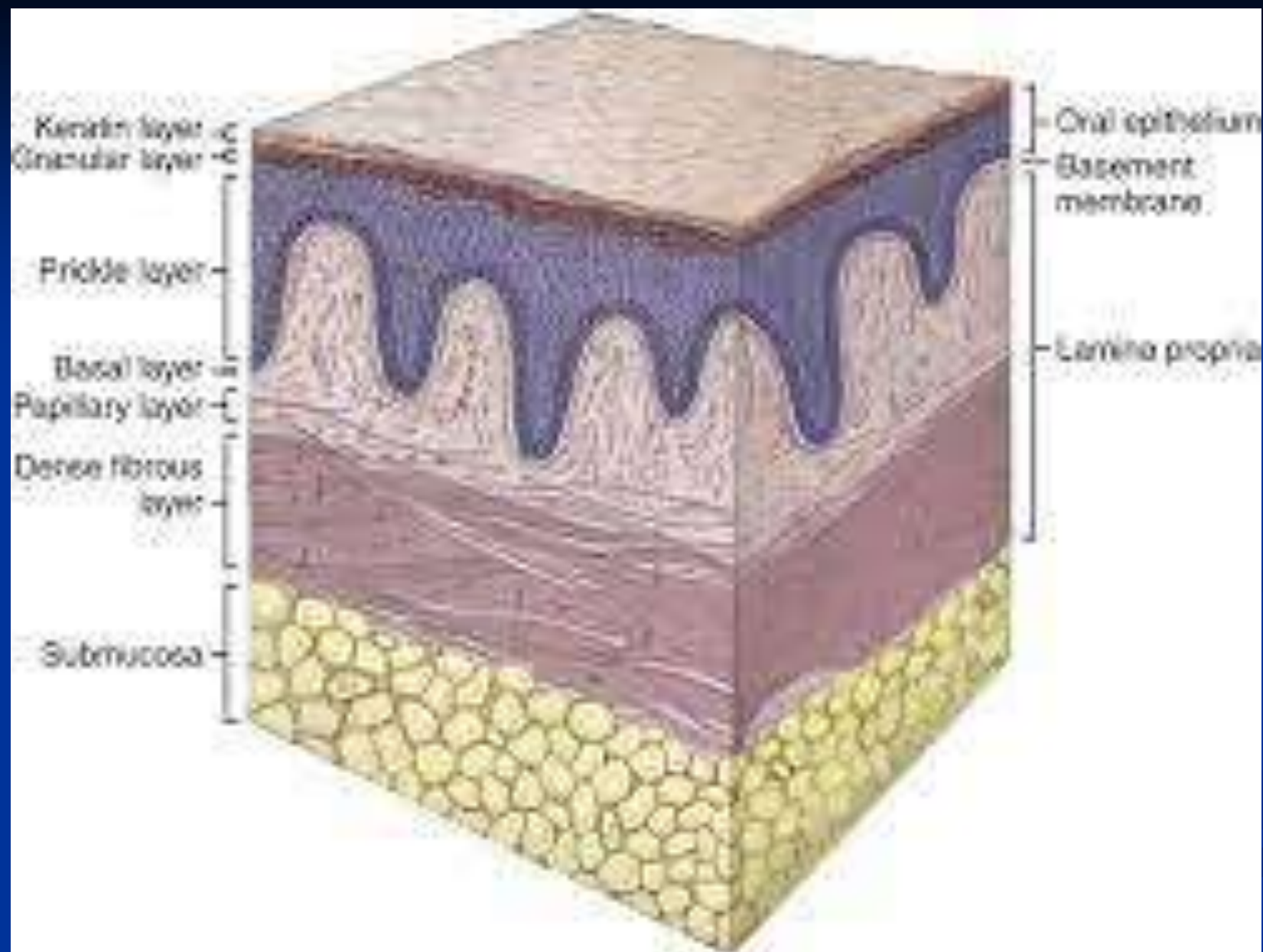


- A: Stratum basale
- B: Stratum spinosum
- C: Stratum superficiale

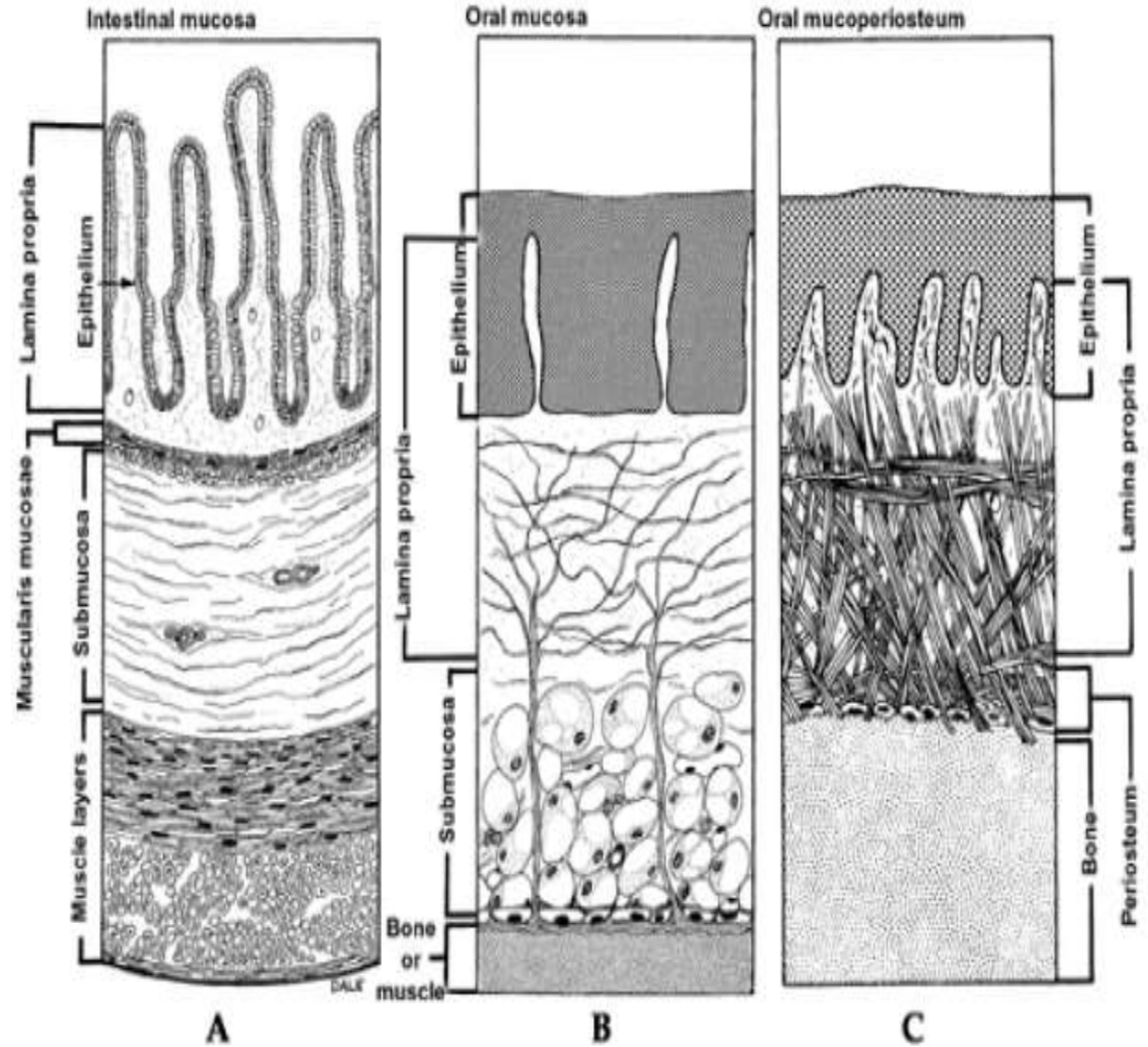
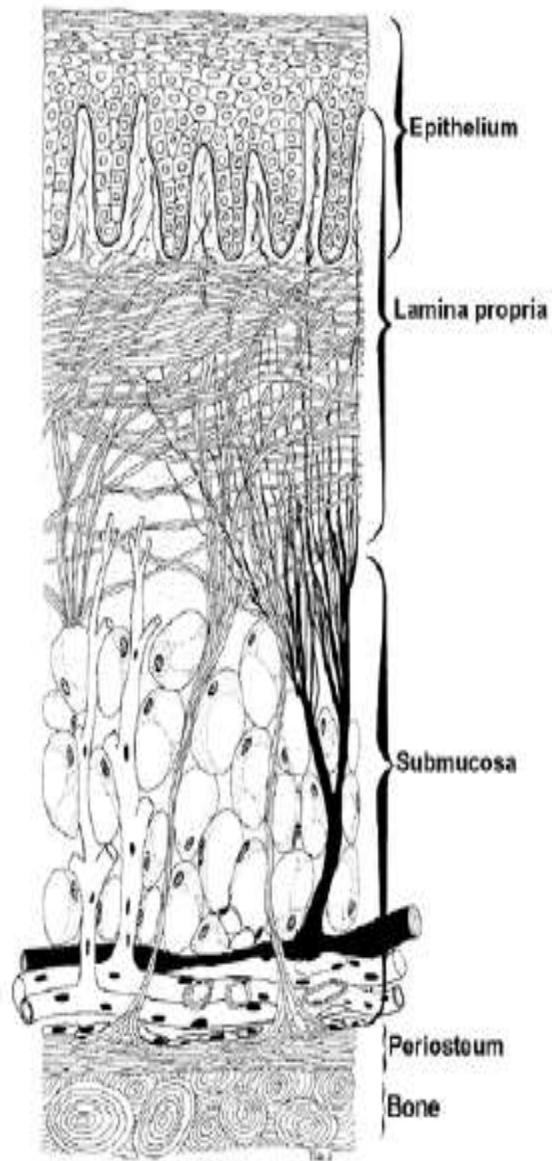
- The oral epithelium is **Keratinized Or Non-keratinized Stratified Squamous Epithelium**
- The interface between epithelium and connective tissue is comprised of a structureless layer called **basement membrane**
- This interface is irregular and is composed of downward projections of epithelium called **reteridges or retepegs**, and upward projection of connective tissue termed as **connective tissue papillae**

- Junction between oral epithelium and lamina propria is more obvious than that between lamina propria and submucosa
- No muscularis mucosae layer seen in oral mucosa
- Loose fat and glandular tissue with blood vessels and nerves seen underneath oral mucosa from underneath bone or muscle layer -this layer is termed **SUBMUCOSA** –provides flexibility

- In gingiva and hard palate, no submucosa is seen and the lamina propria is directly attached to the periosteum of the underlying bone which provides firm, inelastic attachment –this is called **ORAL MUCOPERIOSTEUM**

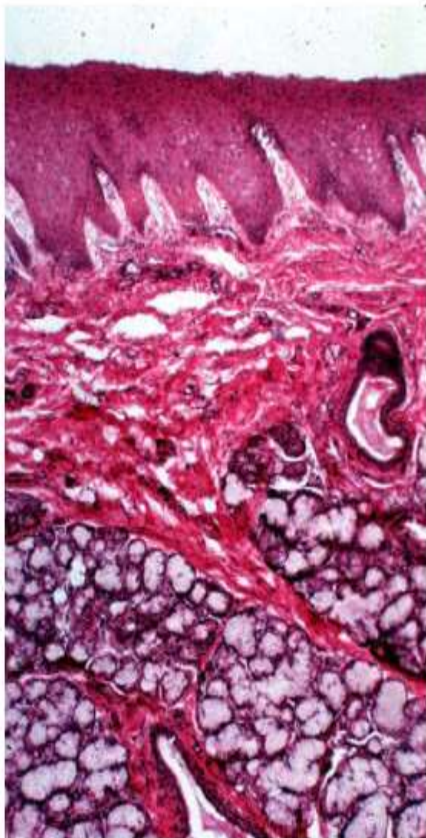


Oral Mucosa  
(and underlying tissues)

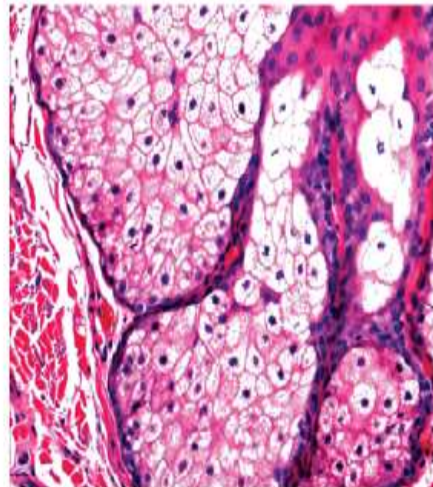
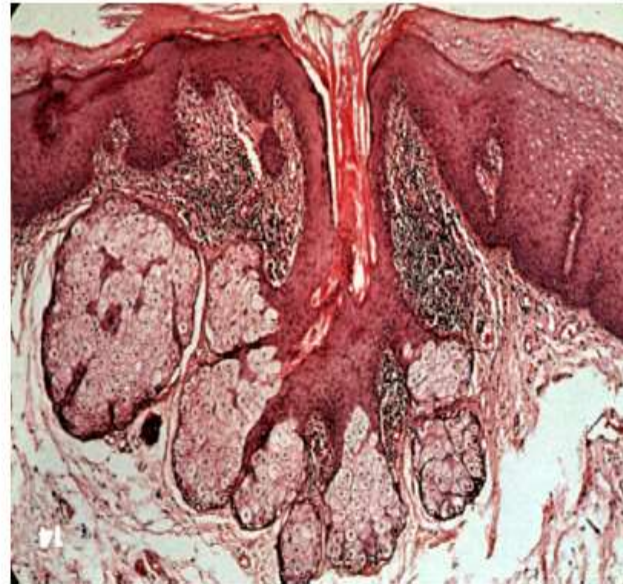


- Connective tissue in oral cavity is comprised of salivary glands, sebaceous glands (Fordyce's disease) and lymphoid tissue (tonsillar tissue)

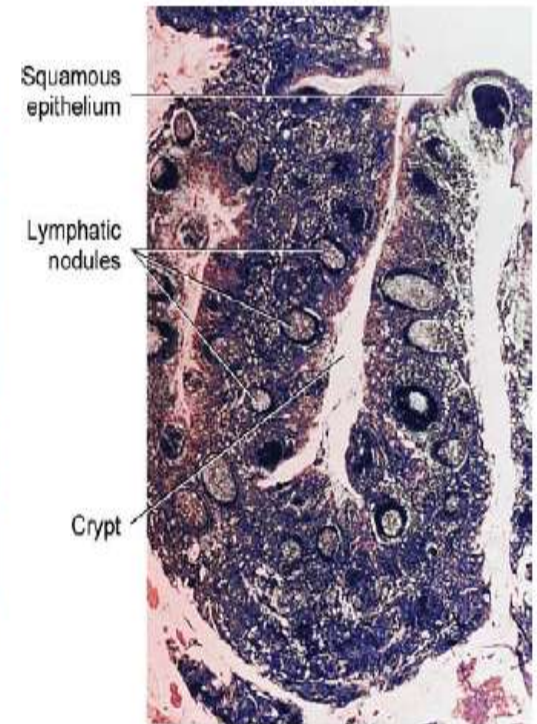
## Salivary glands



## Sebaceous glands



## Lymphoid tissue (tonsil)



Copyright © 2007 by Lippincott Williams & Wilkins, a Wolters Kluwer business.  
*Histology for Pathologists*, Third Edition by Stacey E. Mills.

[www.usc.edu/hsc/dental/opfs/QL/09tn.html](http://www.usc.edu/hsc/dental/opfs/QL/09tn.html)

High Power view of sebaceous glands

## Classification of oral mucosa

- Based upon primary function served
  1. Masticatory Mucosa (25%)
  2. Lining Mucosa (Covers 60% of total area)
  3. Specialised Mucosa (15%)
  
- Based upon keratinisation
  1. Keratinised
    - Orthokeratinized
    - Parakeratinized
  2. Non-keratinised.

# Masticatory Mucosa/ Keratinized Epithelium

Mucosa is thicker than nonkeratinized because of the keratin layer

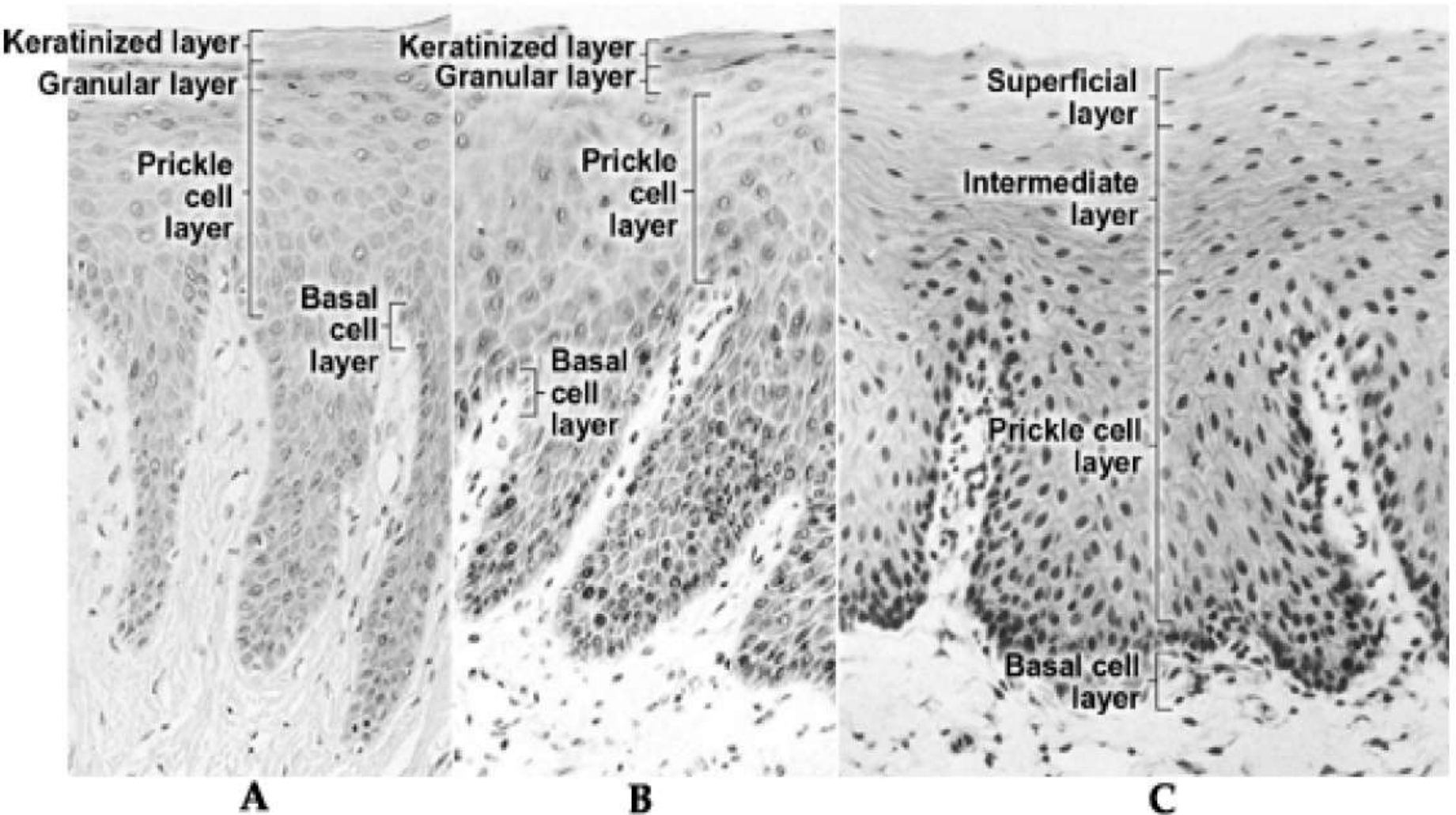
- **Stratum basale**-Same as nonkeratinized epithelium
- **Stratum spinosum**-Same as nonkeratinized epithelium
- **Stratum granulosum**: Cells contain keratohyaline granules
- **Stratum corneum** :Contains thin, flat and non nucleated cells which are filled with keratin. In contrast to the hard keratin seen in nails and hair, keratin overlying normal masticatory oral mucosa is soft. Keratin is tough, nonliving material that is resistant to friction and impervious to bacterial invasion. Same as nonkeratinized epithelium

# Types of Oral Epithelium

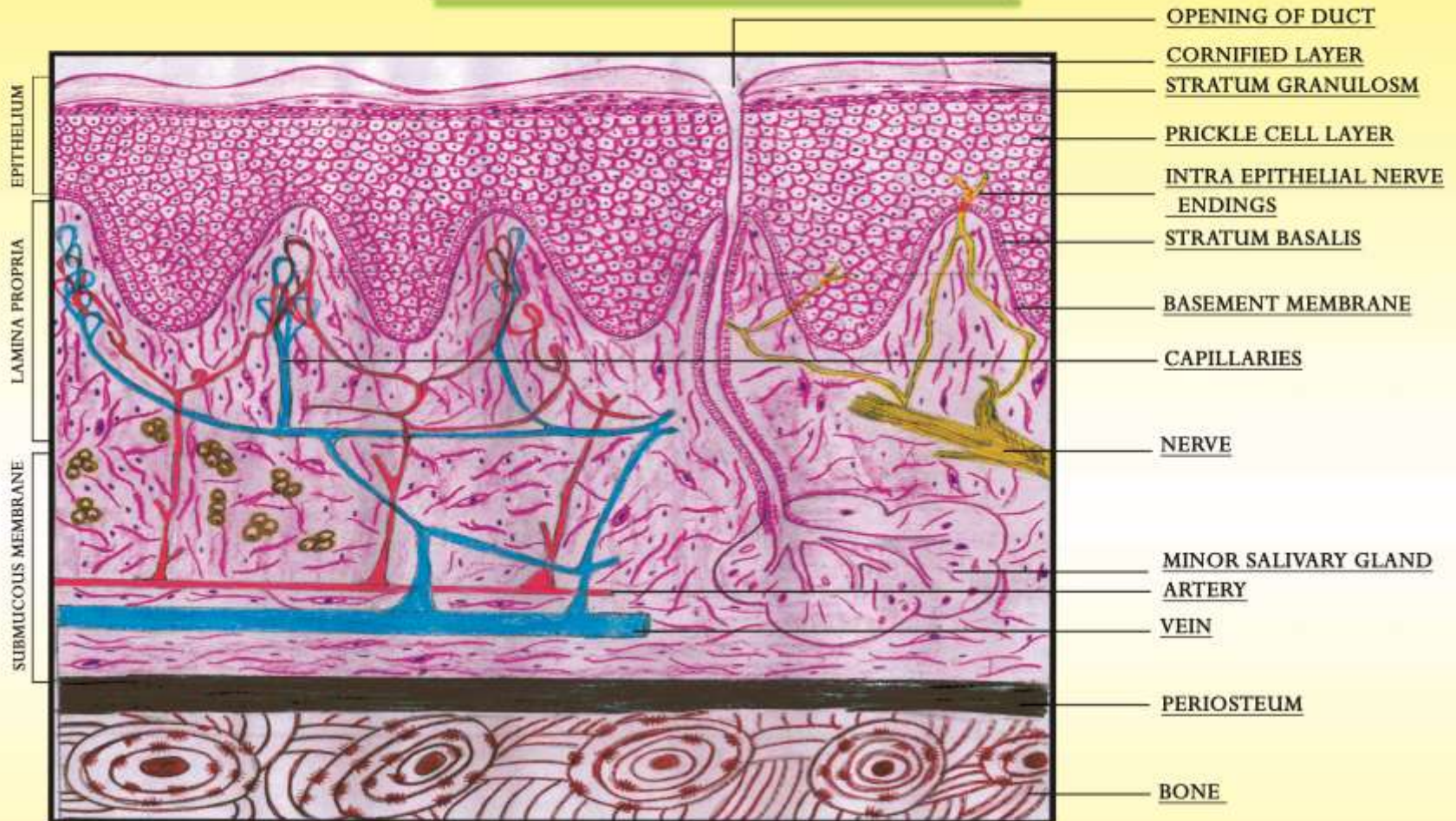
Orthokeratinized stratified squamous epithelium

Parakeratinized stratified squamous epithelium

Nonkeratinized stratified squamous epithelium



# Oral Mucosa



Epithelium :Stratified squamous keratinised epithelium

Basement Membrane :Is the interface between the connective tissue and the epithelium

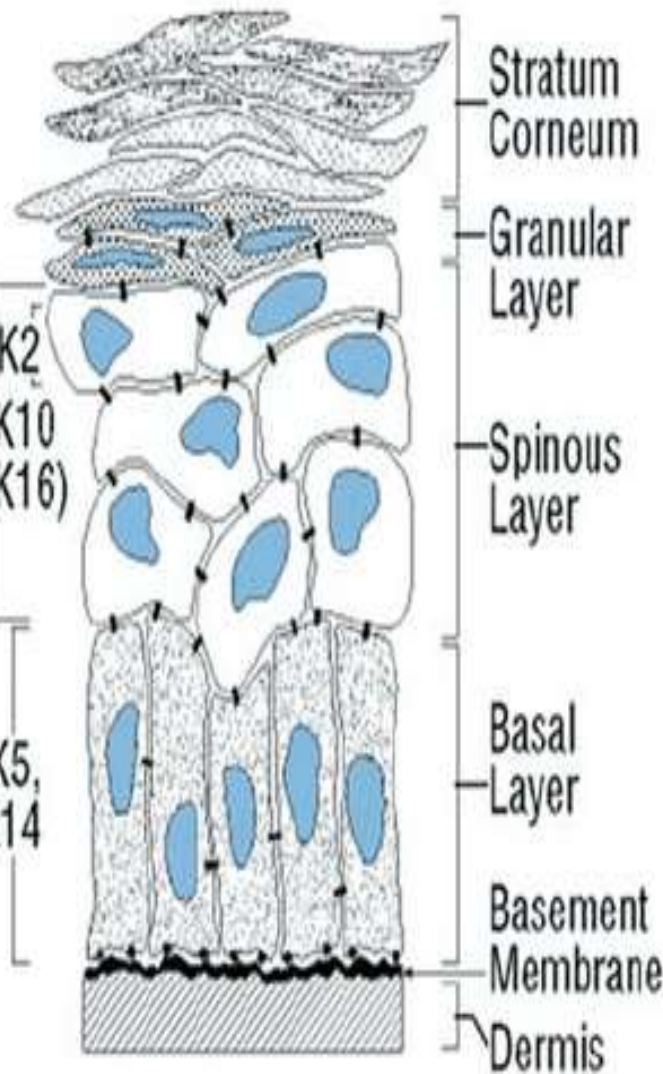
Lamina Propria :Is a connective tissue of variable thickness that support the epithelium  
It is divided into two parts- Papillary and Reticular

Submucosa :It attaches the mucous membrane to the underlying structure

Submitted By : Aardra Ann joe, Absal Abdul Azeez, Antony Juju Vincent, Aswathy C.S, Aswathy V.Mohan.

(II<sup>nd</sup>BDS 2007-08Batch)

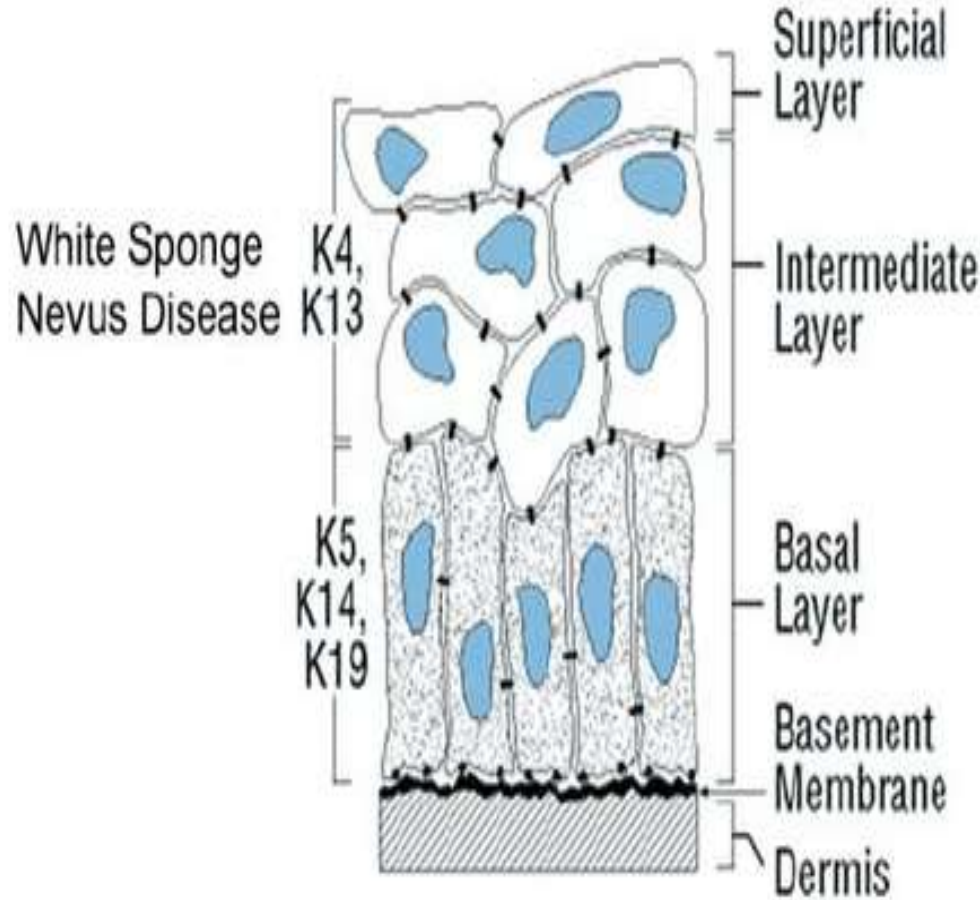
# Epidermis, Oral Keratinized



IBS  
EHK  
PC-1

EB simplex

# Oral Non-Keratinized (Buccal)

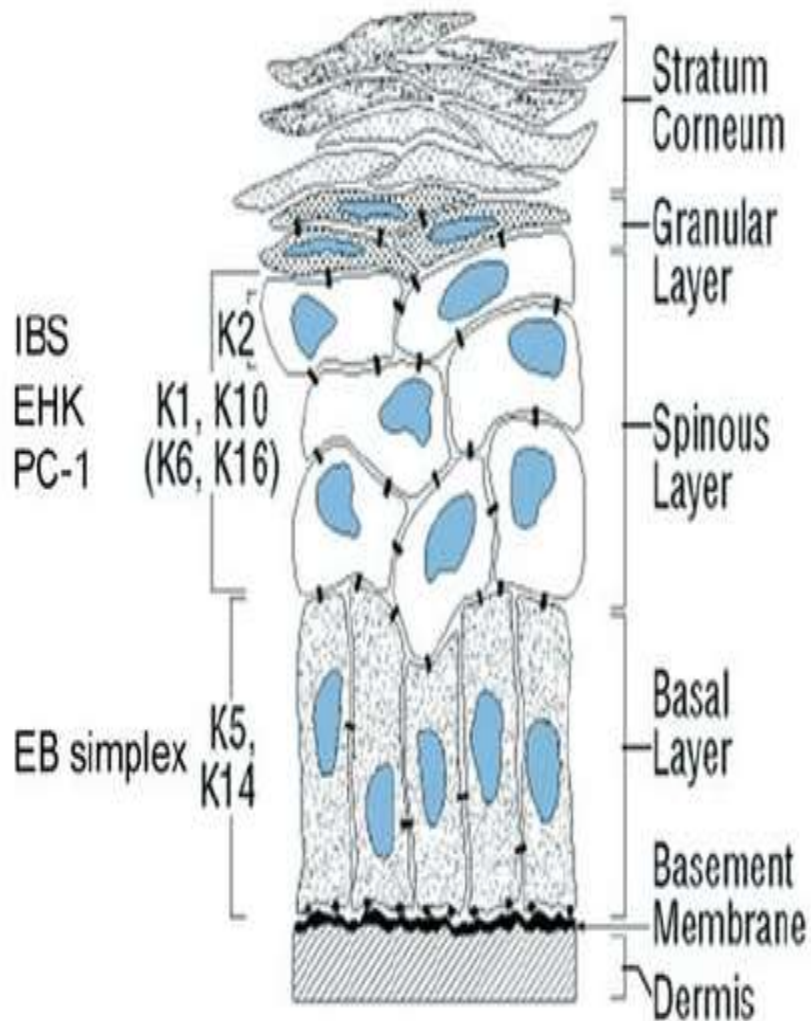


White Sponge  
Nevus Disease

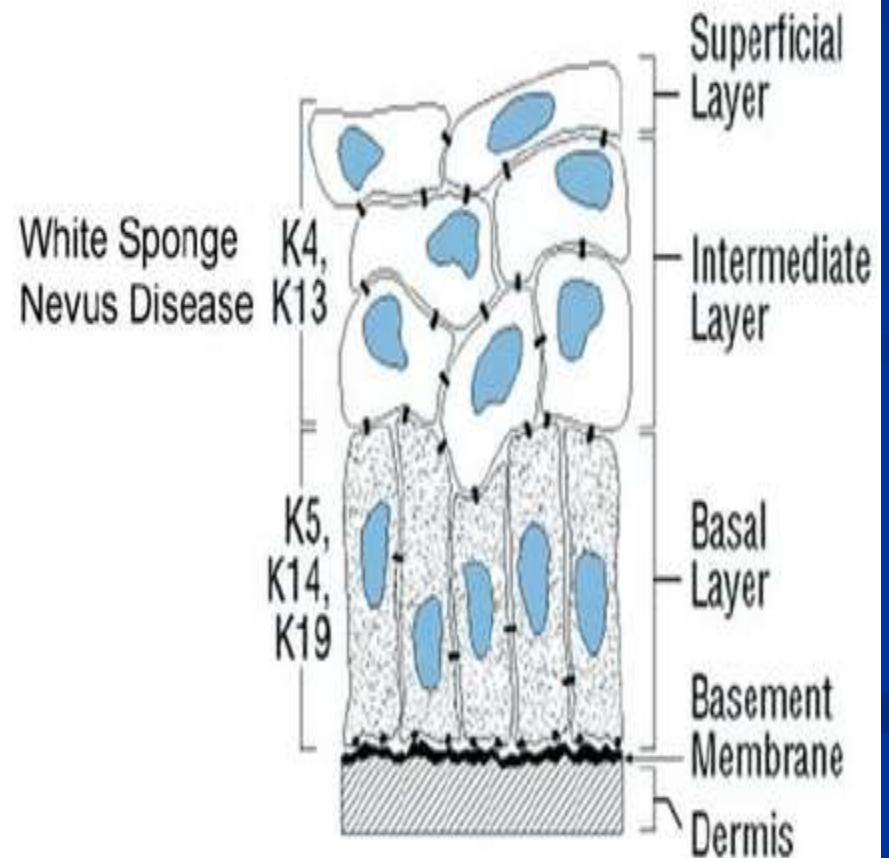
# Components of Oral Epithelium

- **Lining Mucosa:**
- **Stratum Basale:** Basal cell layer comprised of cuboidal cells. Progenitor cells that divide and provide new cells by mitotic division that migrate to the surface to replace cells that are shed.
- **Stratum Spinosum (or intermedium):** Cells are oval and represent bulk of the epithelium.
- **Stratum Superficiale:** Cells are flat and contain small oval nuclei that are continuously shed.

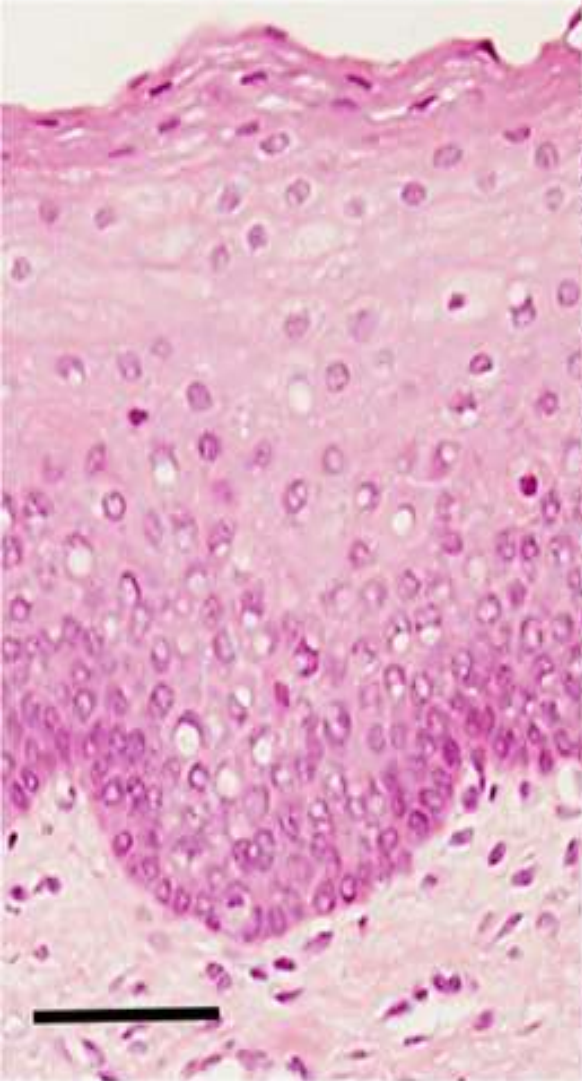
## Epidermis, Oral Keratinized



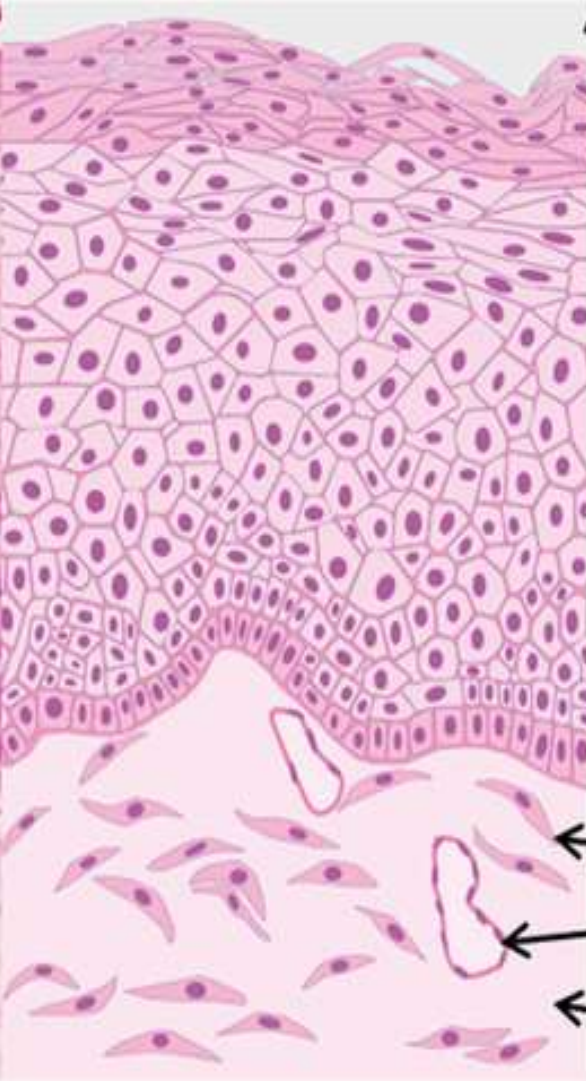
## Oral Non-Keratinized (Buccal)



# Histology



# Schematic



Mucus

Superficial, nucleated  
non-keratinized  
differentiated epithelium

Stratum spinosum

Stratum basale

Oral fibroblast

Blood vessel

Connective tissue

Stratified squamous  
epithelium

Lamina propria

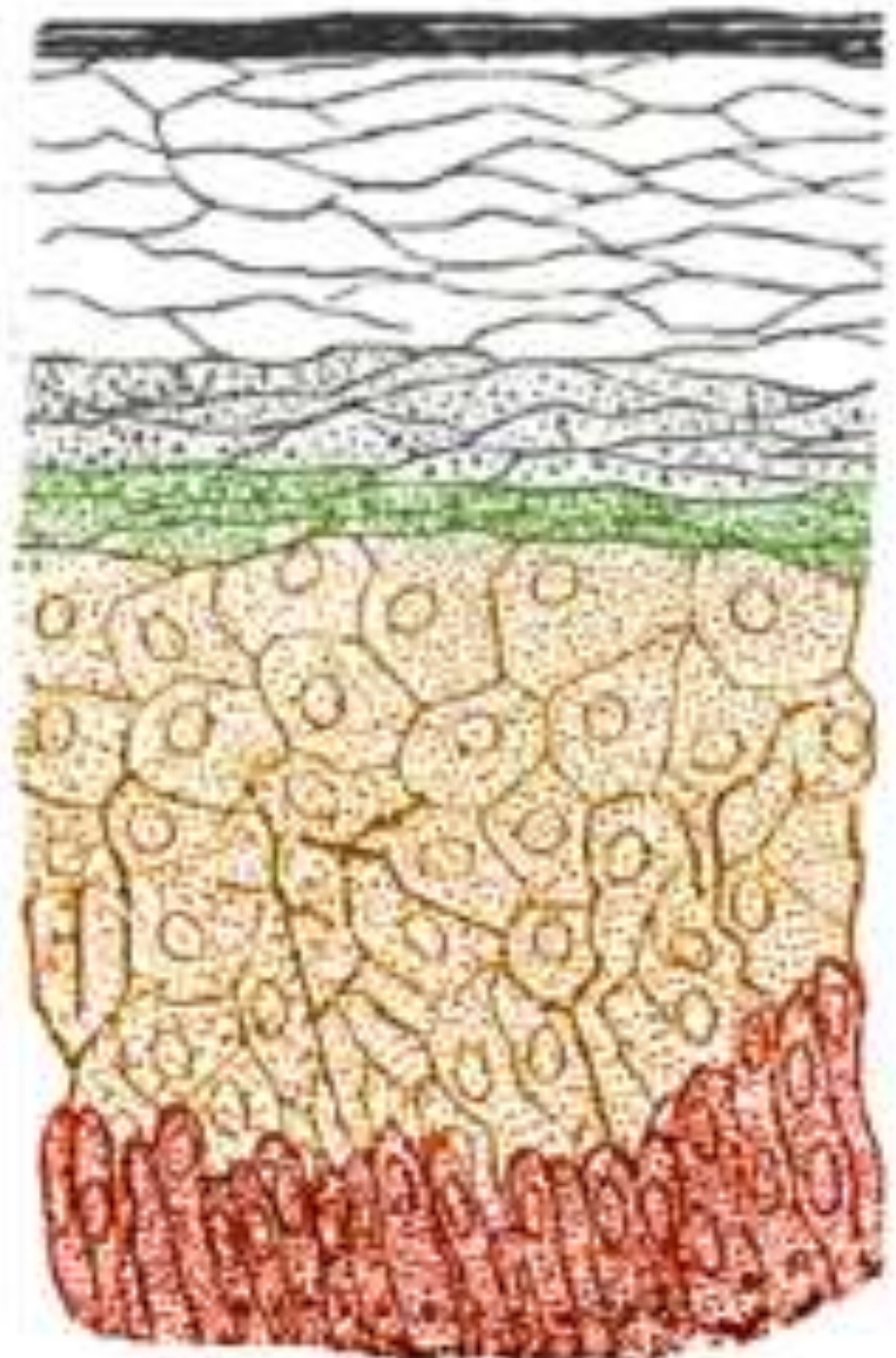
Stratum corneum

Stratum lucidum

Stratum granulosum

Stratum spinosum

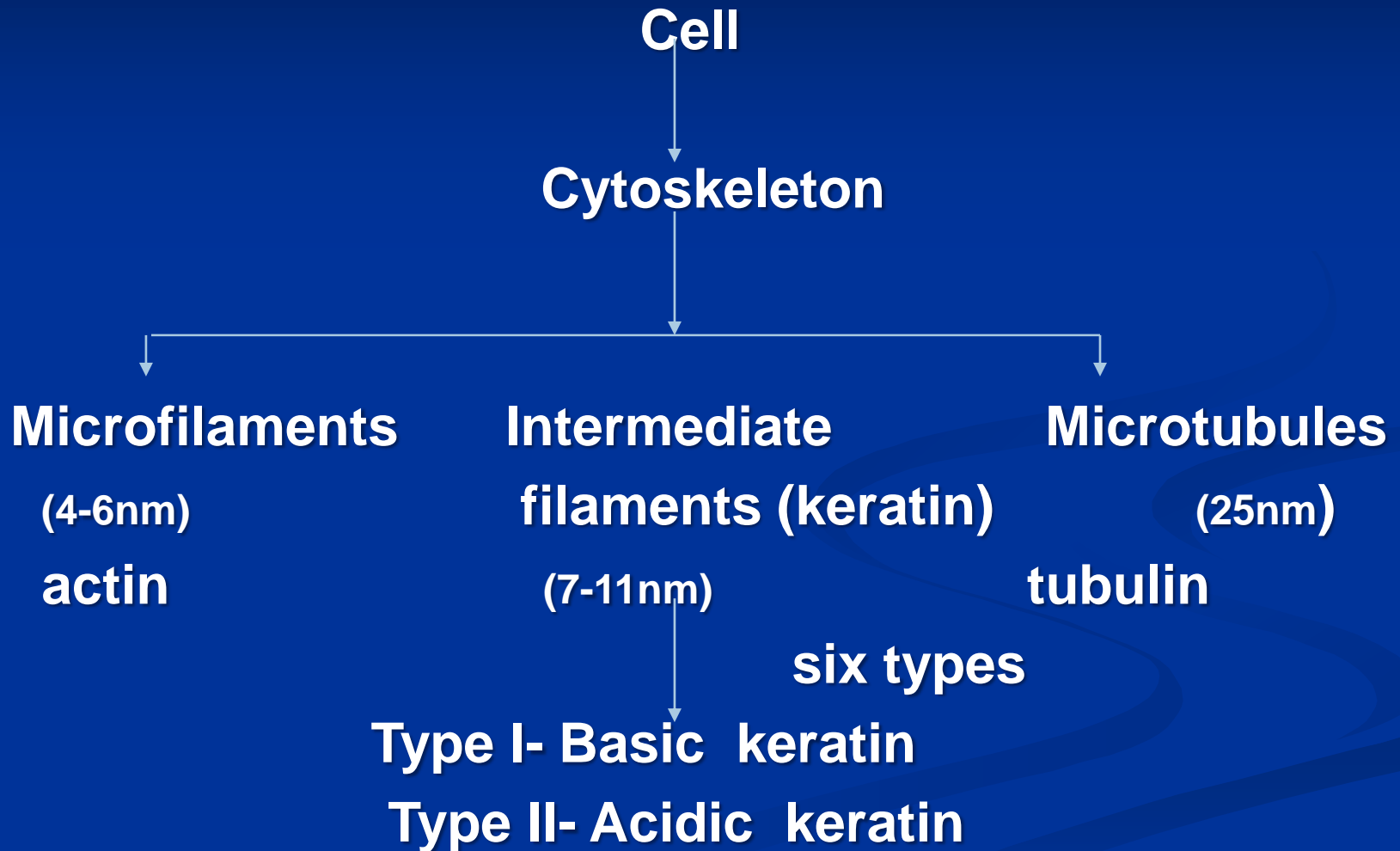
Stratum basale



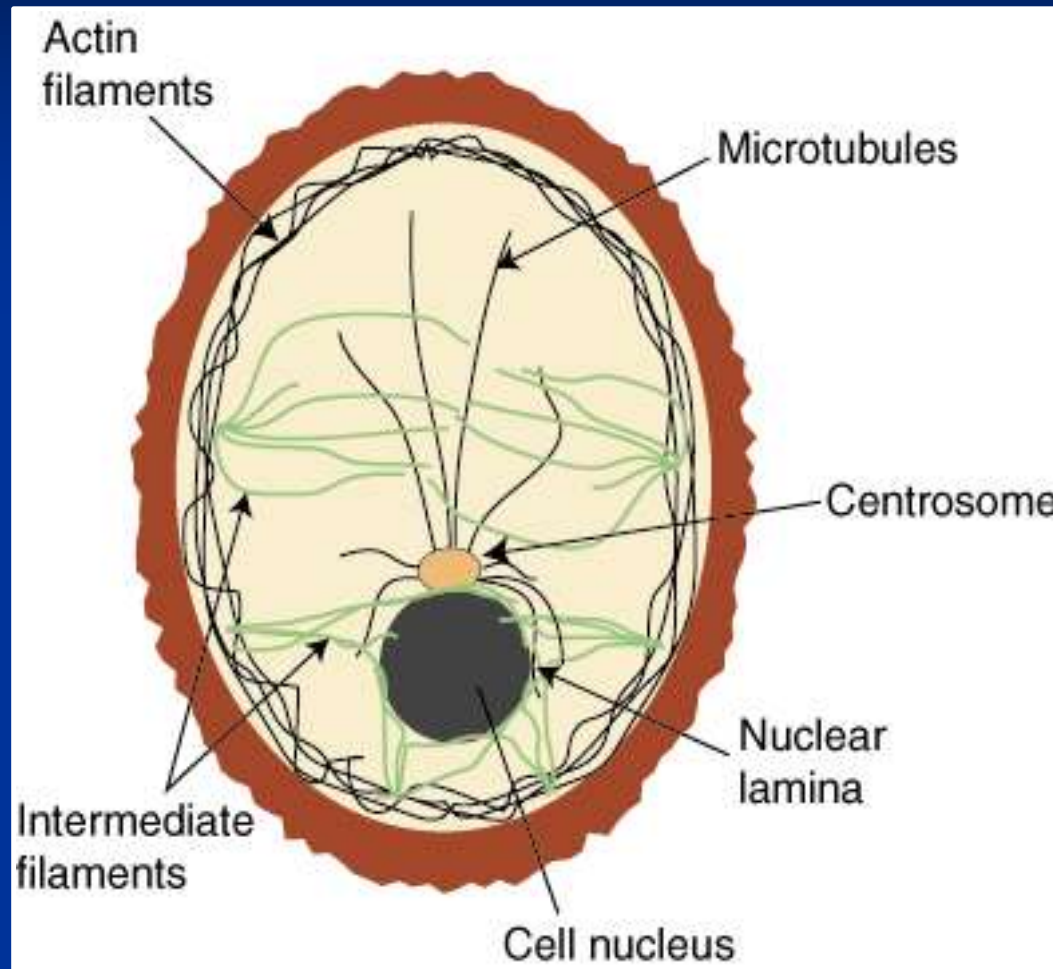
# Cytokratinen

- Cytokeratins form the Cytoskeleton of all epithelial cells, along with microfilaments and microfibrils.
- Serve to provide mechanical linkages and distribute the forces over wide area.
- Function as **stress bearing structures** within epithelium and are important in maintaining cell shape.

# Structural elements of cell



# Cytoskeleton



## Type I Cytokeratins

- Basic group
- Cytokeratins: 1-8
- Mol wt: 52-67 KDa
- **LARGER** cytokeratins

## Type II Cytokeratins

- Acidic group
- Cytokeratins: 9-20
- Mol wt: 40-56.5 KDa
- **SMALLER** cytokeratins

**TYPE II**

**TYPE I**

10



1,2

12



3

13



4

14, 15



5

16,17



6,7

18

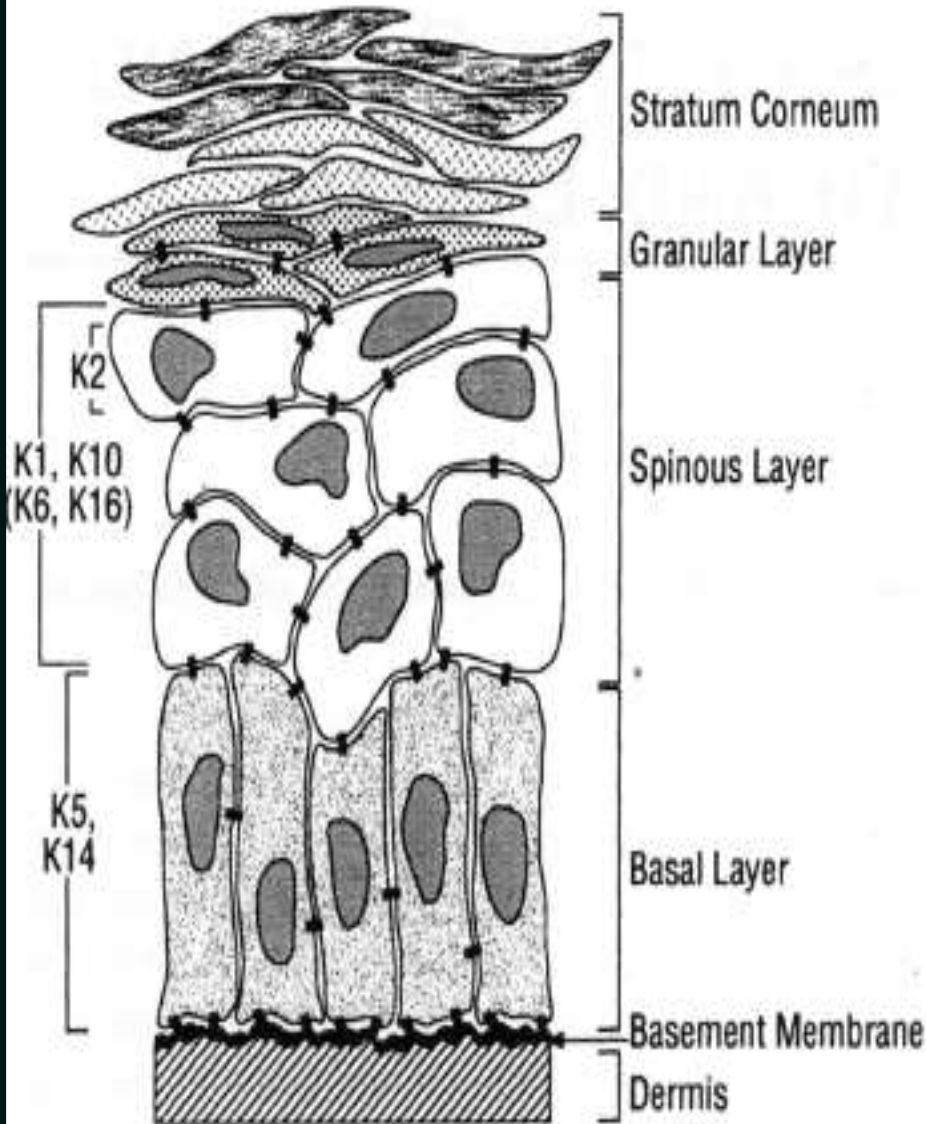


8

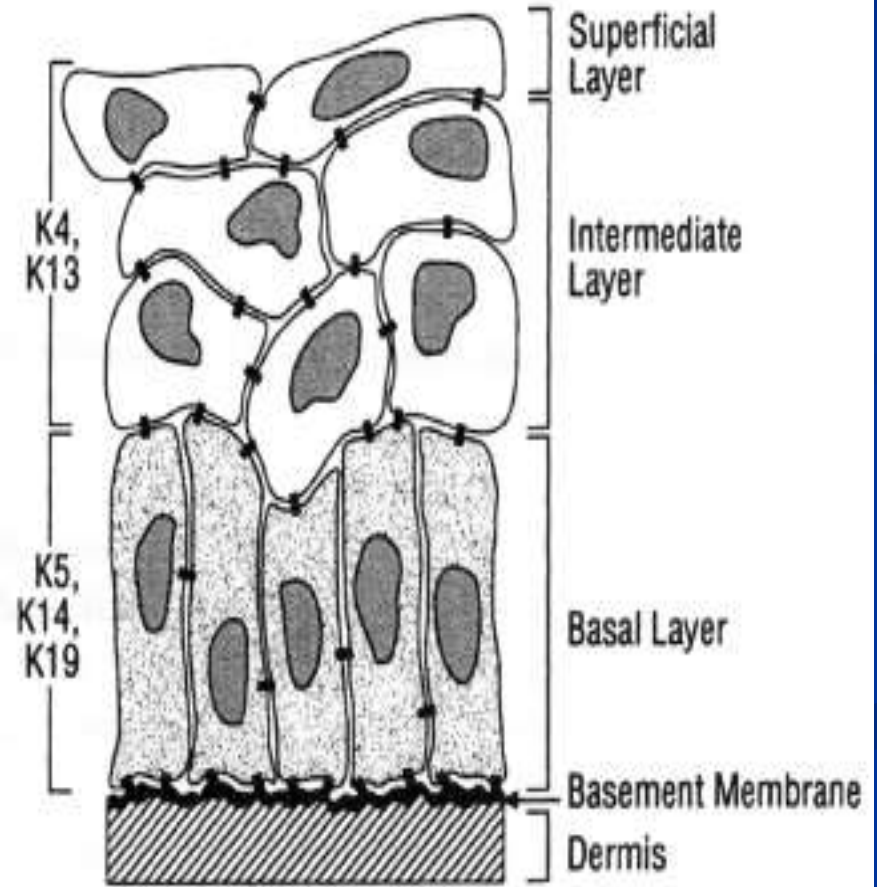
19

Only unpaired cytokeratin

### A Epidermis, Oral Keratinized



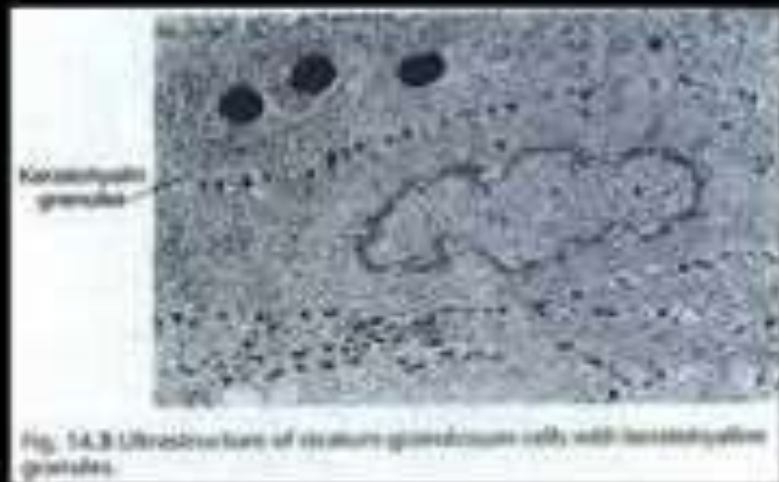### B Oral Non-Keratinized (Buccal)



- Masticatory Mucosa--- CK1, CK10
- Lining Mucosa--- CK4, CK13
  
- Ventral surface of Tongue- CK5,6,14
- Soft Palate- CK7,8,18

# Keratinosome or Odland bodies or membrane containing granules

- Modified lysosomes
- 0.25 $\mu$ m in length.
- Rich in phospholipids.

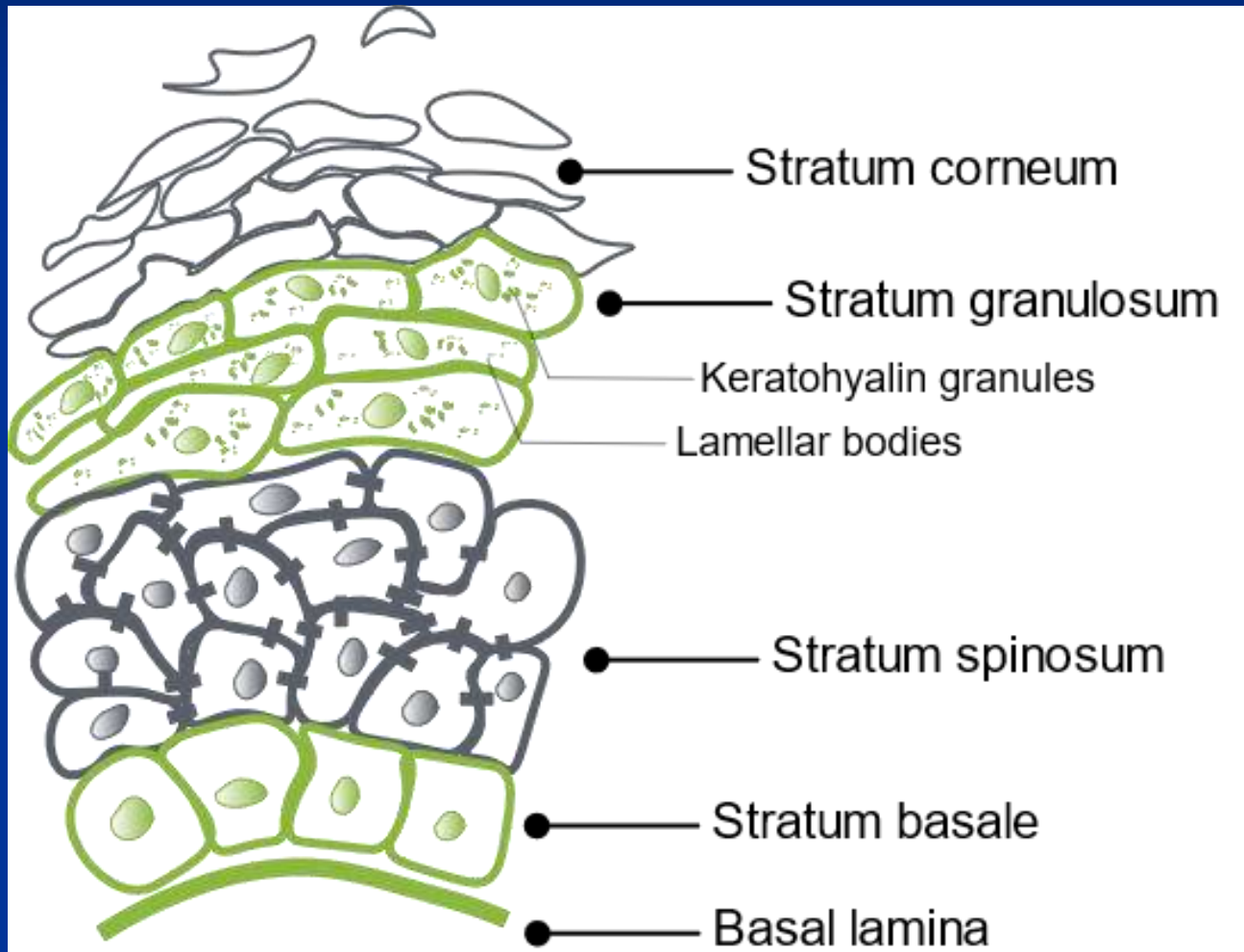


- Structure - layers of parallel lamellae, probably originating from golgi apparatus.
- Lamellar granules discharge their contents - permeability barrier.

# ODLAND BODIES/ KERATINOSOMES

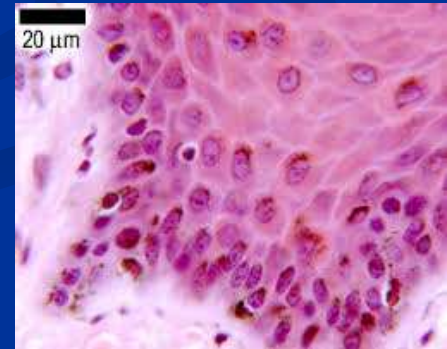
- Lamellar granules secrete their contents into the intercellular spaces forming an intercellular lamellar structure.
- This contributes to the permeability barrier.
- This barrier forms at the junction of granular and cornium layer.

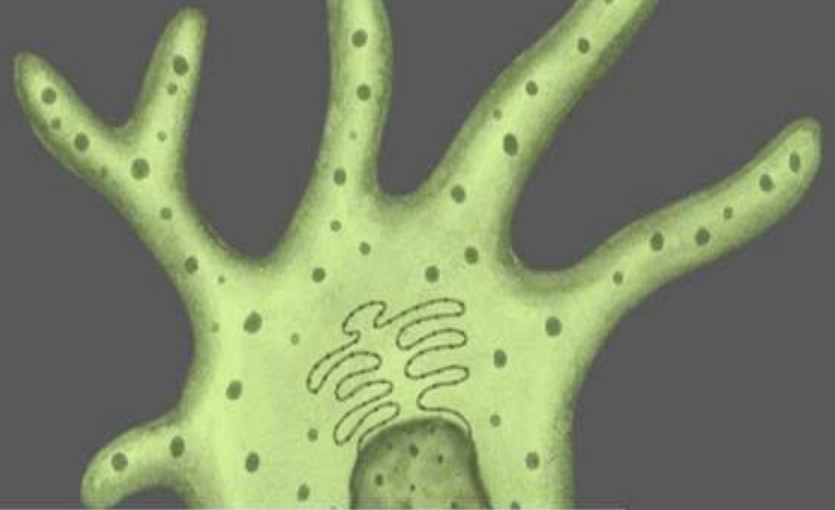
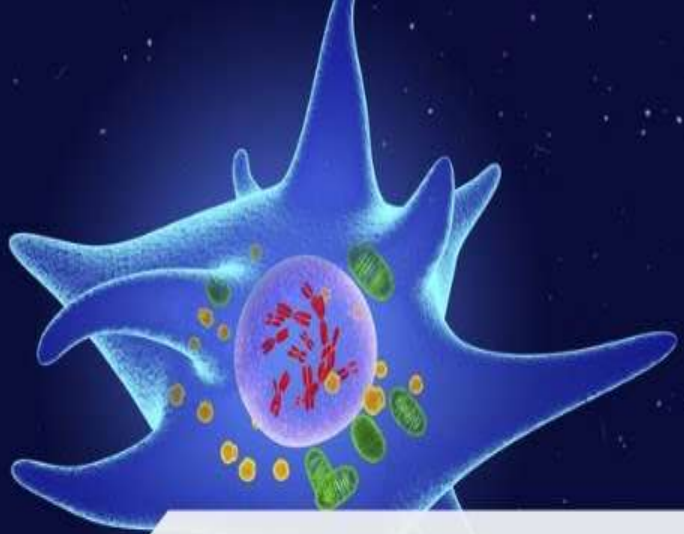
# Odland bodies



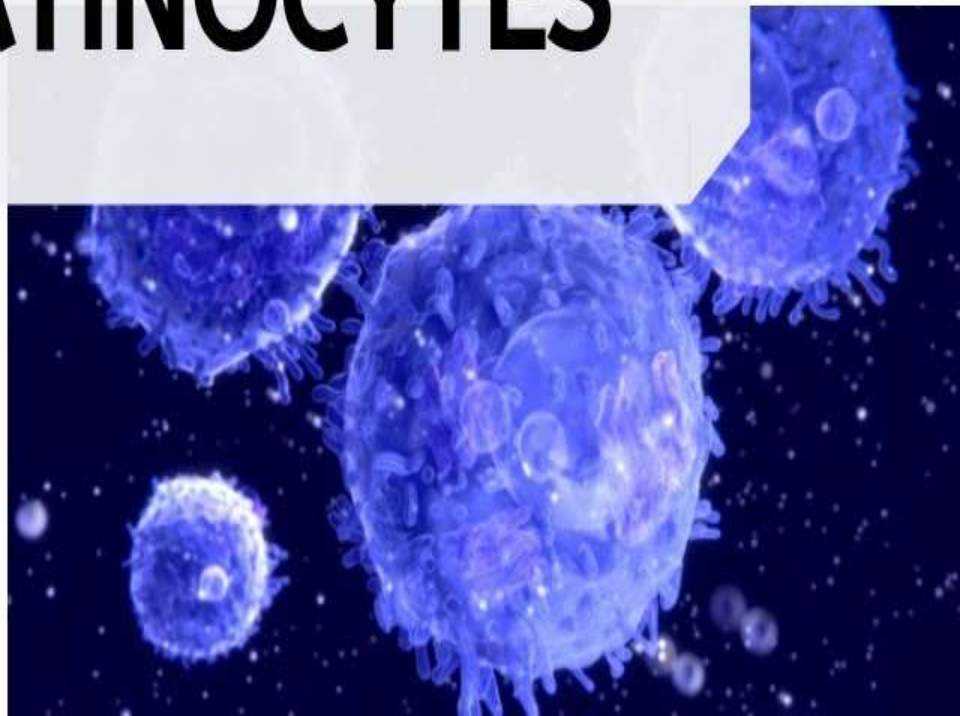
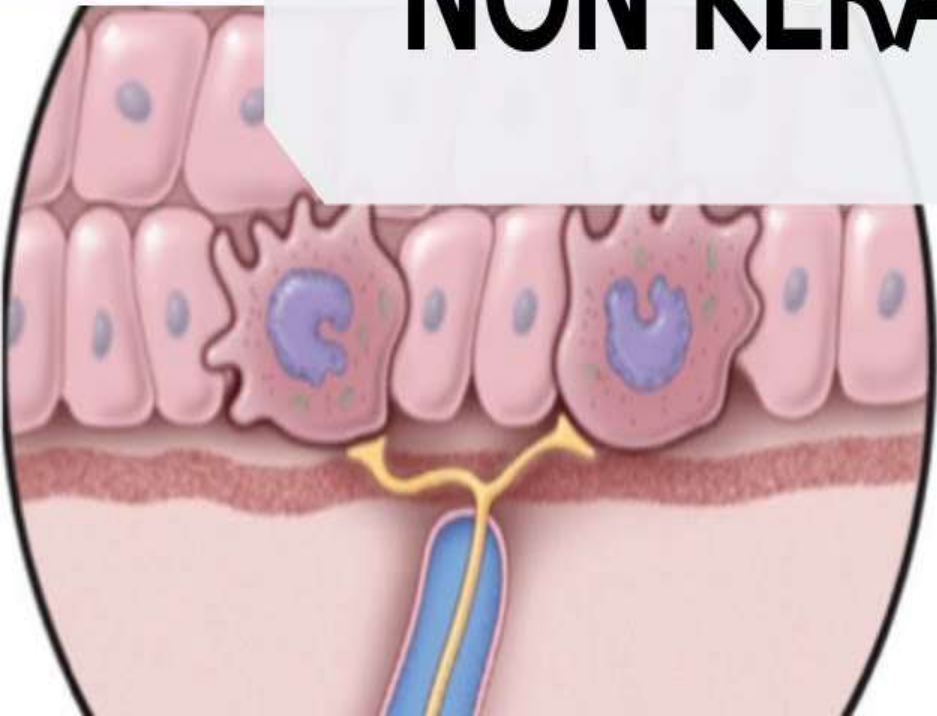
# Non-keratinocytes.

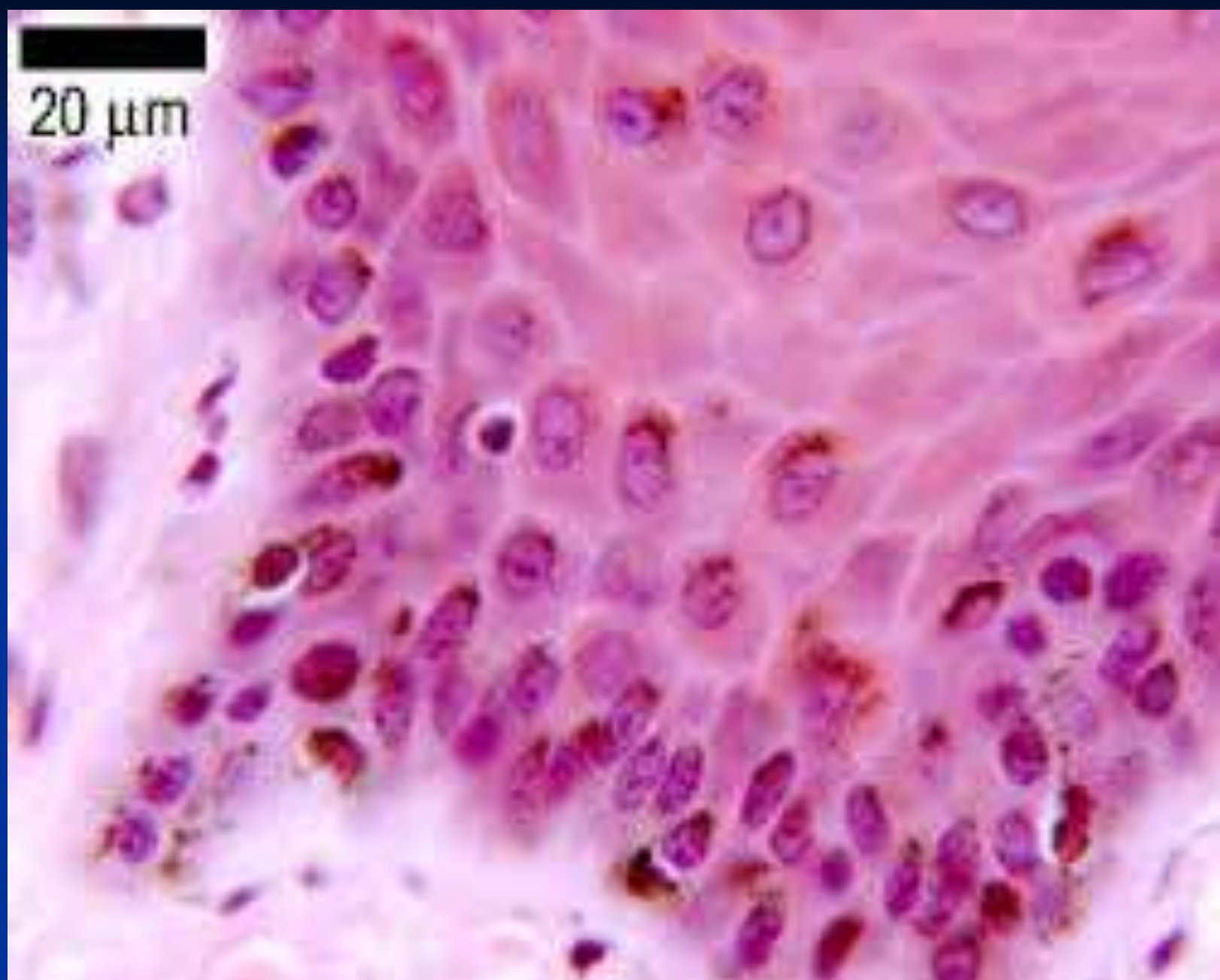- Oral epithelium in many areas contain cells that differ in appearance from other epithelial cells.
- Lack desmosomal attachment to adjacent cells Hence During histologic processing, Cytoplasm shrinks around the nucleus To produce----- **Clear cell**
- None of these cells contain the large numbers of tonofilaments and Desmosomes seen in epithelial keratinocytes and none participates in the process of maturation seen in epithelial.
- They are called as --- Non keratinocytes





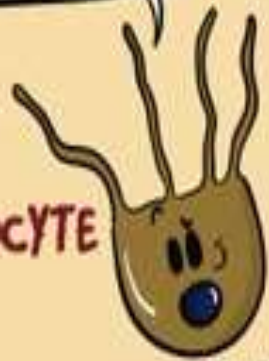# NON KERATINOCYTES





# NON-KERATINOCYTES

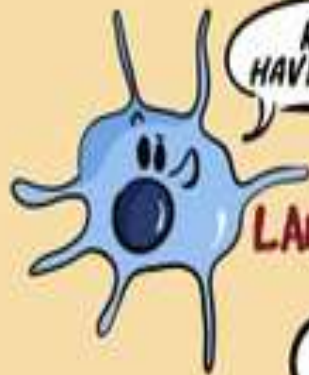
DESMOSOMES?? NEVER HEARD OF 'EM!!



MELANOCYTE

© HACKDENTISTRY 2018

NAAH..WE DON'T HAVE CYTOKERATINS!!



LANGERHANS CELL

WE DON'T UNDERGO MATURATION..



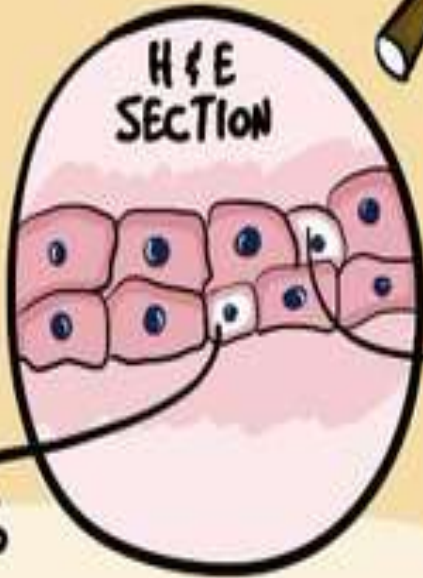
MERKEL CELL

WE ARE FEW IN NUMBER!



INFLAMMATORY CELL (MOSTLY LYMPHOCYTES)

HMM..CLEAR CELLS..

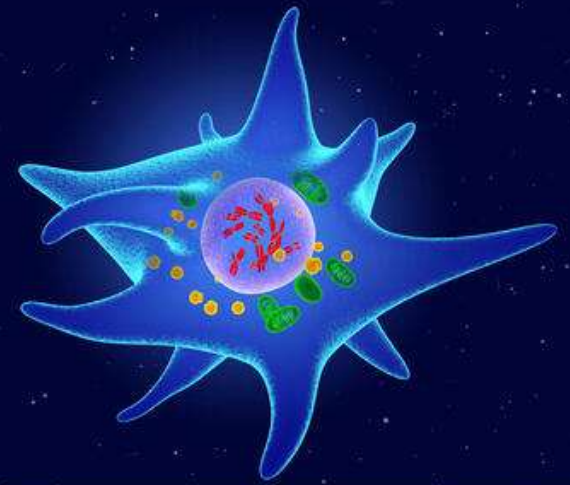


H & E SECTION

CYTOPLASM AROUND NUCLEUS SHRINKS

"HALO" AROUND NUCLEUS

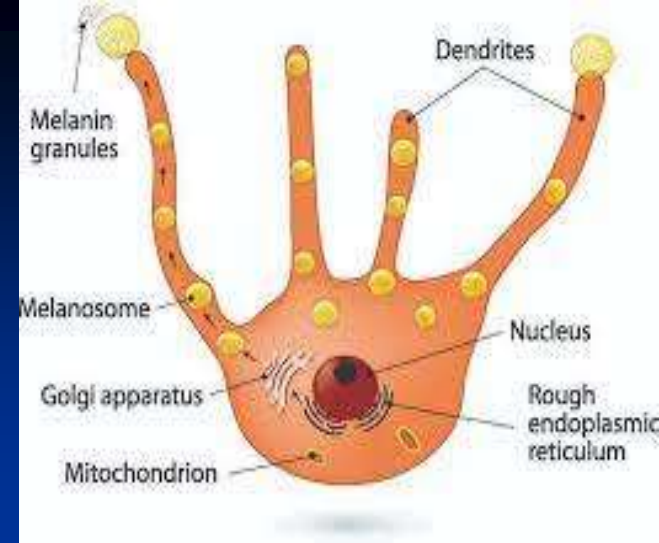
# Langerhan's cells:



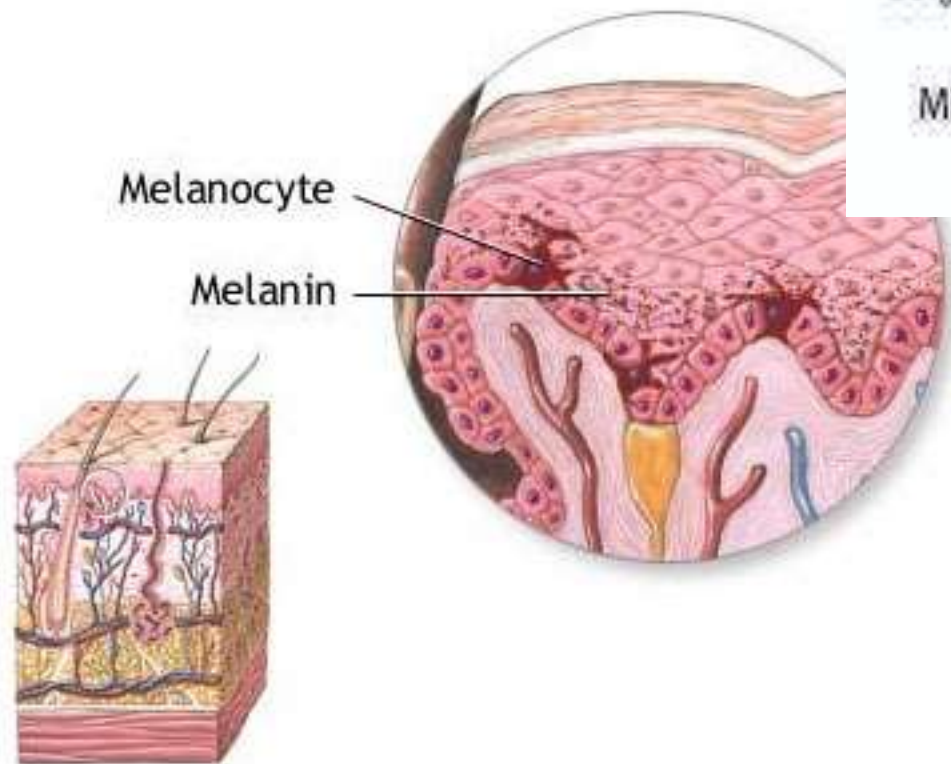
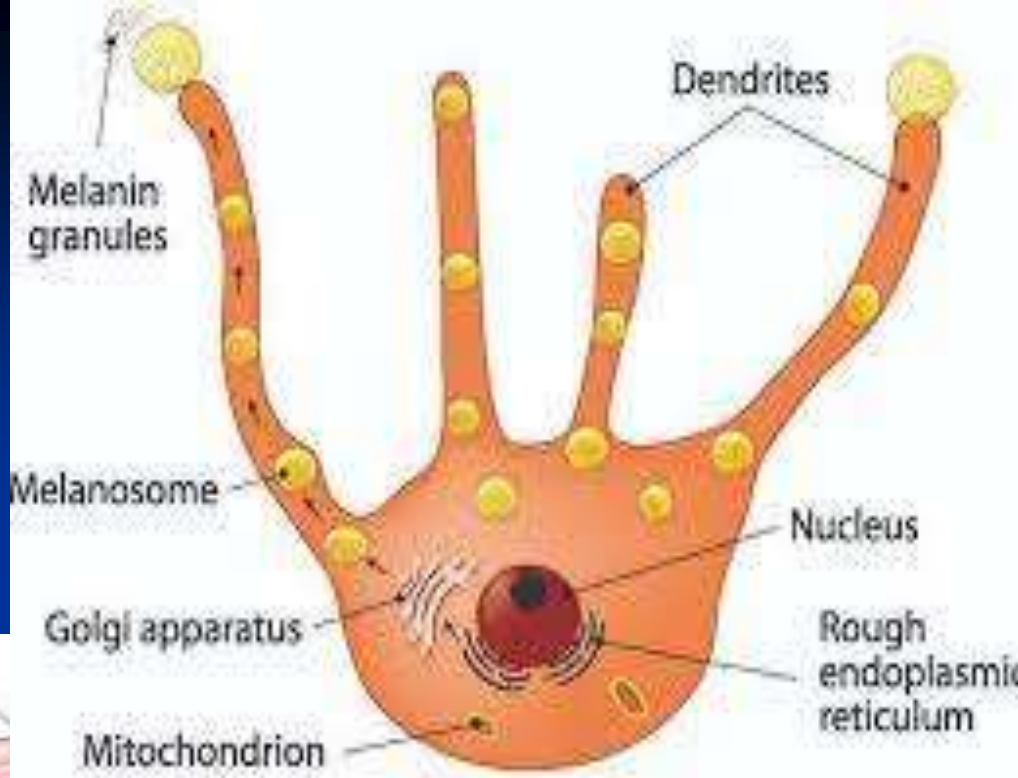
alamy - JGN6JG

- Location: Supra basal.
- Function: Antigen trapping and processing
- Description: Dendritic cell
- ~ Lack desmosomal attachments
- ~ Characterized ultra structurally by a small rod or flask shaped granules sometimes called —  
**Birbeck granules.**
- They may be capable of limited division with in the epithelium.

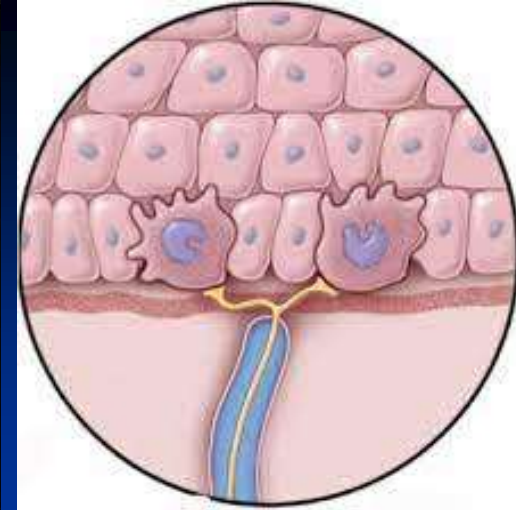
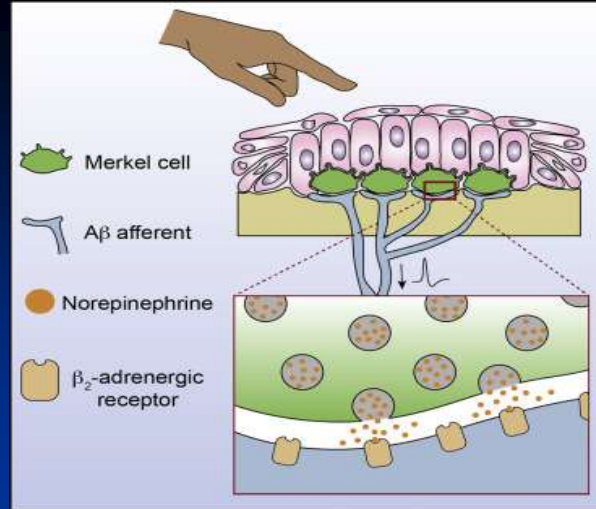
# Melanocytes:



- Origin: Neural crest cytoderm.
- Function: Produce Melanin — Pigment.
- Description: They are present predominantly at Basal layer of epithelium.
- ~ They lack desmosomes and tonofilaments but have Long dendritic processes that extend between keratinocytes.
- ~ **Melanin** — synthesized within the Melanocytes as small structures called — **Melanosomes**. Injected Into cytoplasm of adjacent keratinocytes by the dendritic processes of Melanocytes.



# Merkel Cell:



- Location: Basal layer.
- Function: **Tactile sensory cell.**
- Description: Unlike Melanocytes and Langerhan's cells it is not dendritic.
- It does not contain tonofilaments and presence of occasional desmosomes linking to adjacent cells—hence not always clear cell.

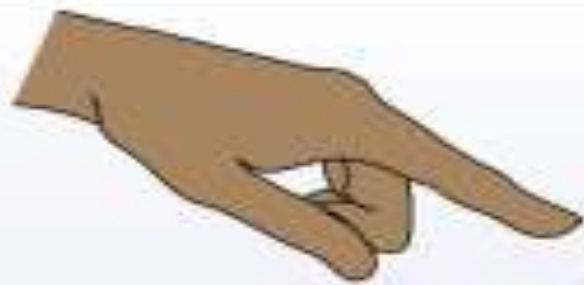- It has nerve tissue immediately adjacent.
- It is presumed to be “Specialised neural pressure-sensitive receptor cell”
- Responds to touch sensation.

- *Characteristic features:*


- Small membrane bound vesicles in the cytoplasm


Sometimes situated adjacent to nerve fiber associated with the cell


- These granules many liberate **Transmitter substance**
- Across synapse like function between Merkel cell and Nerve fiber--- trigger an impulse
- These cells may arise from division of an epithelial cell (Keratinocyte).

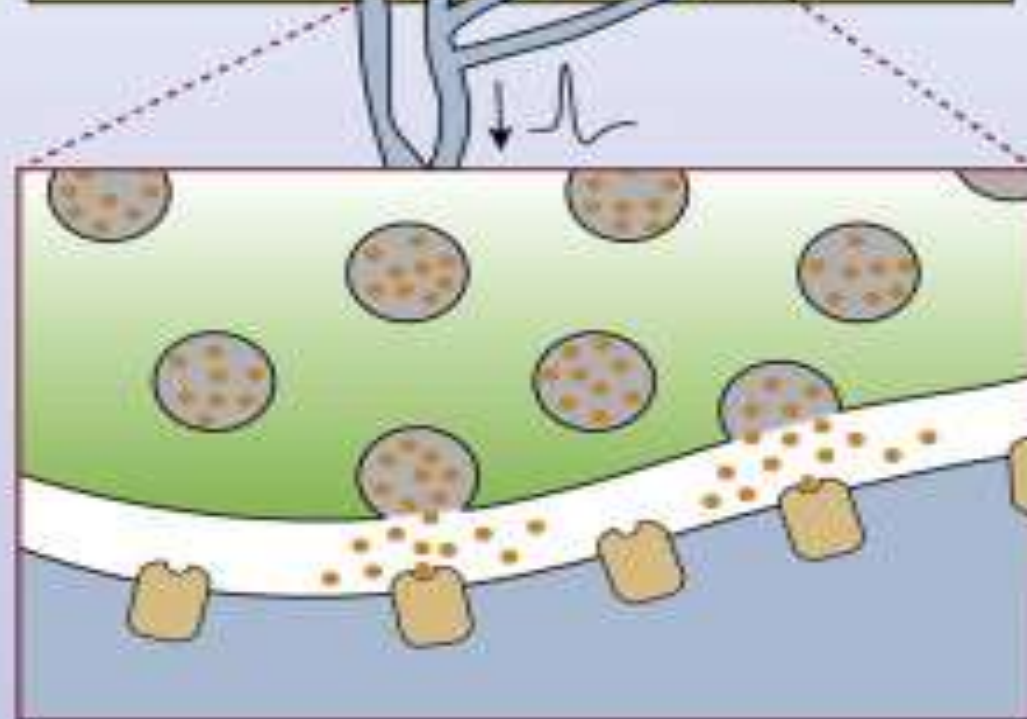
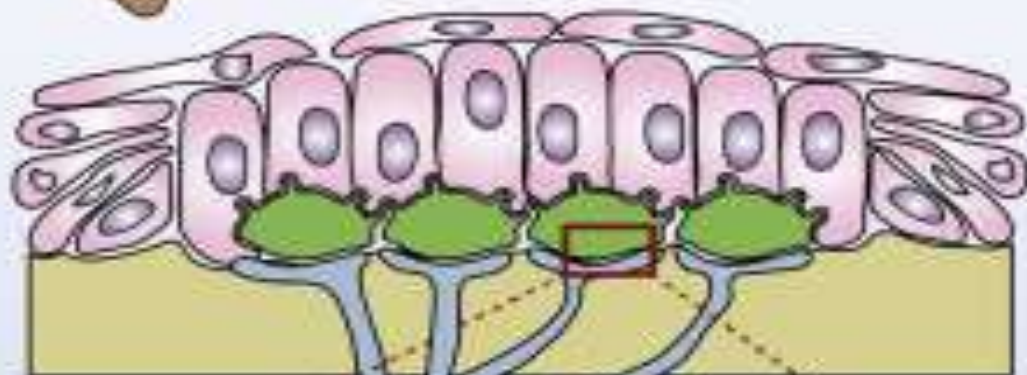


 Merkel cell

 A $\beta$  afferent

 Norepinephrine

  $\beta_2$ -adrenergic receptor



# Inflammatory cells:

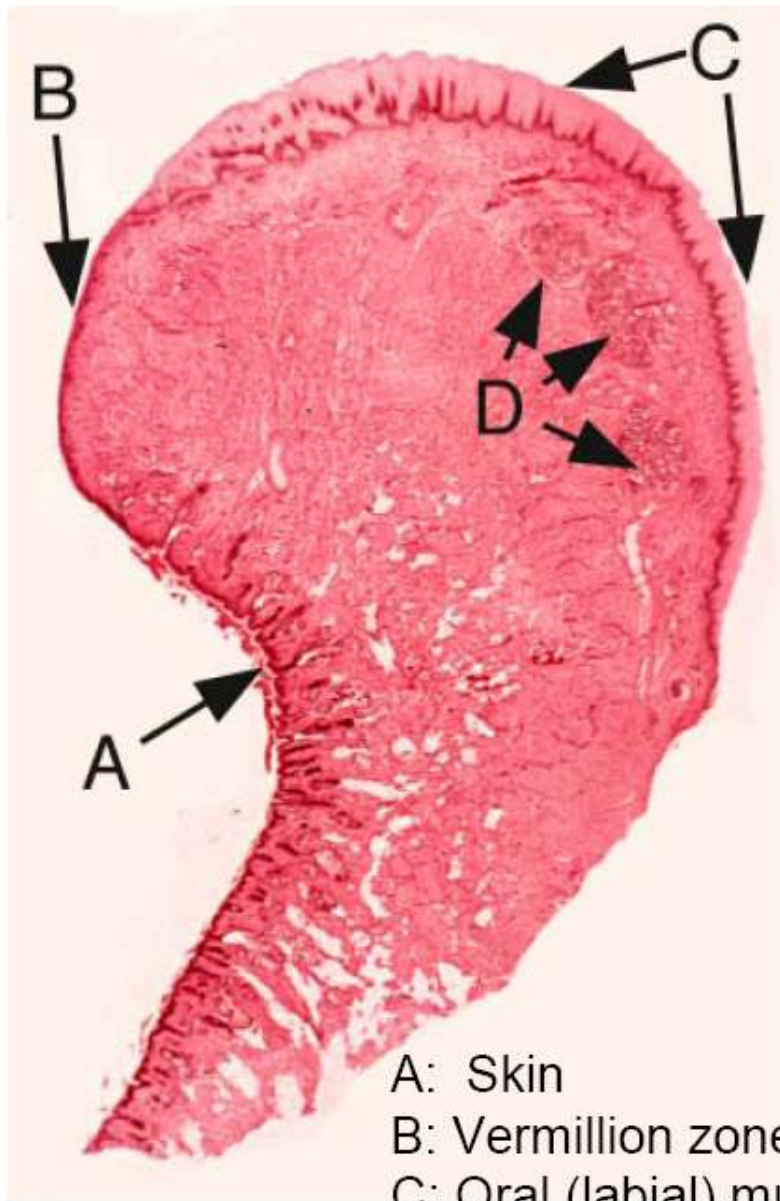
- Function: Associated with inflammatory process in Oral Mucosa.
- Description: Sections of normal Oral inflammatory cells often in the nucleated cell layers.
- ~ These cell — transient & do not reproduce themselves in the Epithelium
- ~ The cell most frequently seen is
- ~ **Lymphocyte occasionally PNM and mast cells** can also be seen
- ~ Lymphocytes — often associated with Langerlan's cells

# Histology of Lip

- **Skin:** keratinized stratified squamous epithelium with adnexal skin structures
- **Oral Mucosa:** Moist-surface, covered by nonkeratinized stratified squamous epithelium associated with small round seromucous glands of the lamina propria. In the submucosa fibers of orbicularis oris muscle is noted.
- **Vermillion zone:** Very thin keratinized epithelium that contains no adnexal skin structures (can contain sebaceous glands)

- The Transitional zone between the Skin of the Lip and the Mucous Membrane of Lip is the **RED ZONE/ VERMILLION ZONE.**
- The line that separates the skin from the Vermillion zone- **VERMILLION BORDER**

- The skin on outer surface of Lip- moderately Thick keratinized epithelium with thick str. Corneum.
- CT Papillae few and short.
- Transitional Zone- midly keratinized epi with long CT papillae.
- Deep in to epi---- large capillary loops

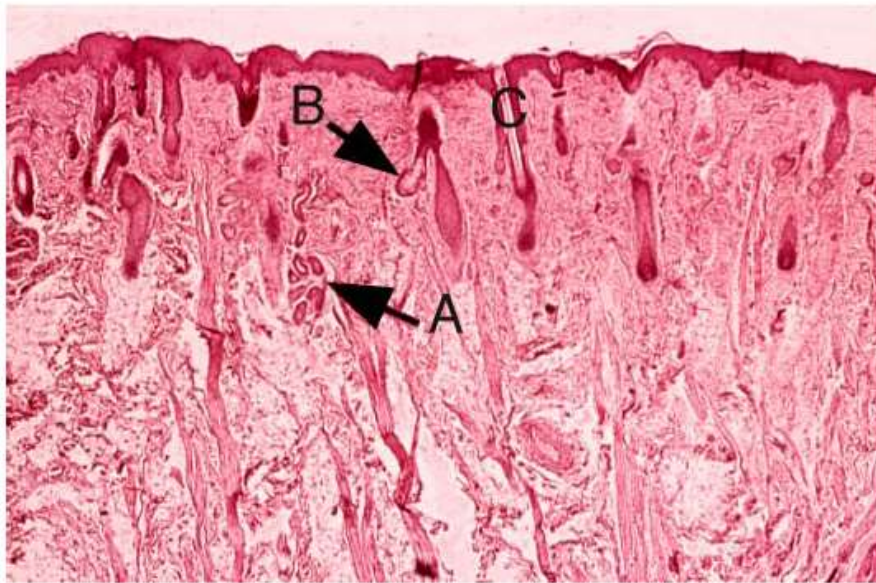


- A: Skin
- B: Vermillion zone
- C: Oral (labial) mucosa
- D: Minor salivary glands

# What gives the vermillion zone the red color?

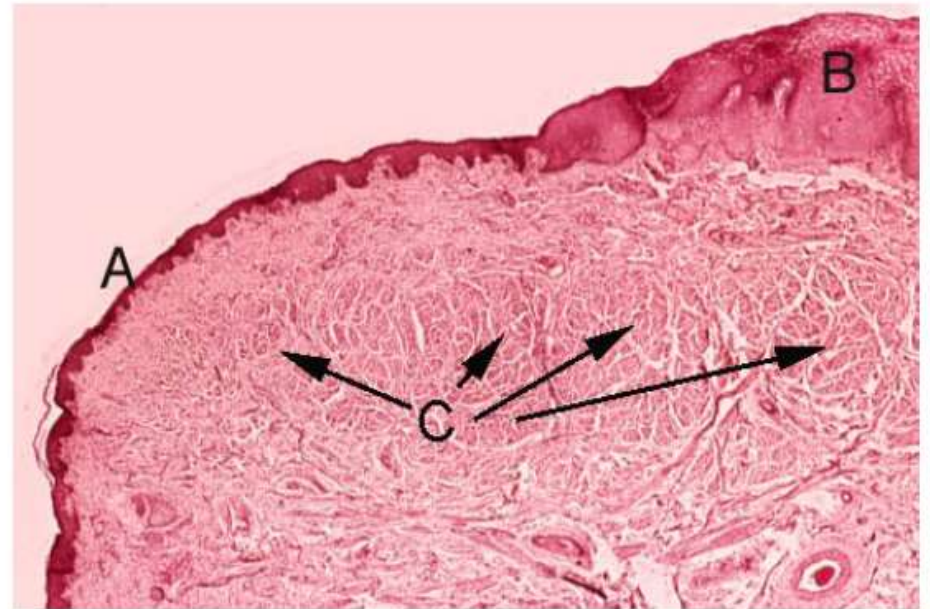
- 1. Epithelium is thin
- 2. Epithelium contains eleidin, which is transparent
- 3. Blood vessels are present near the surface

## Skin of the Lip



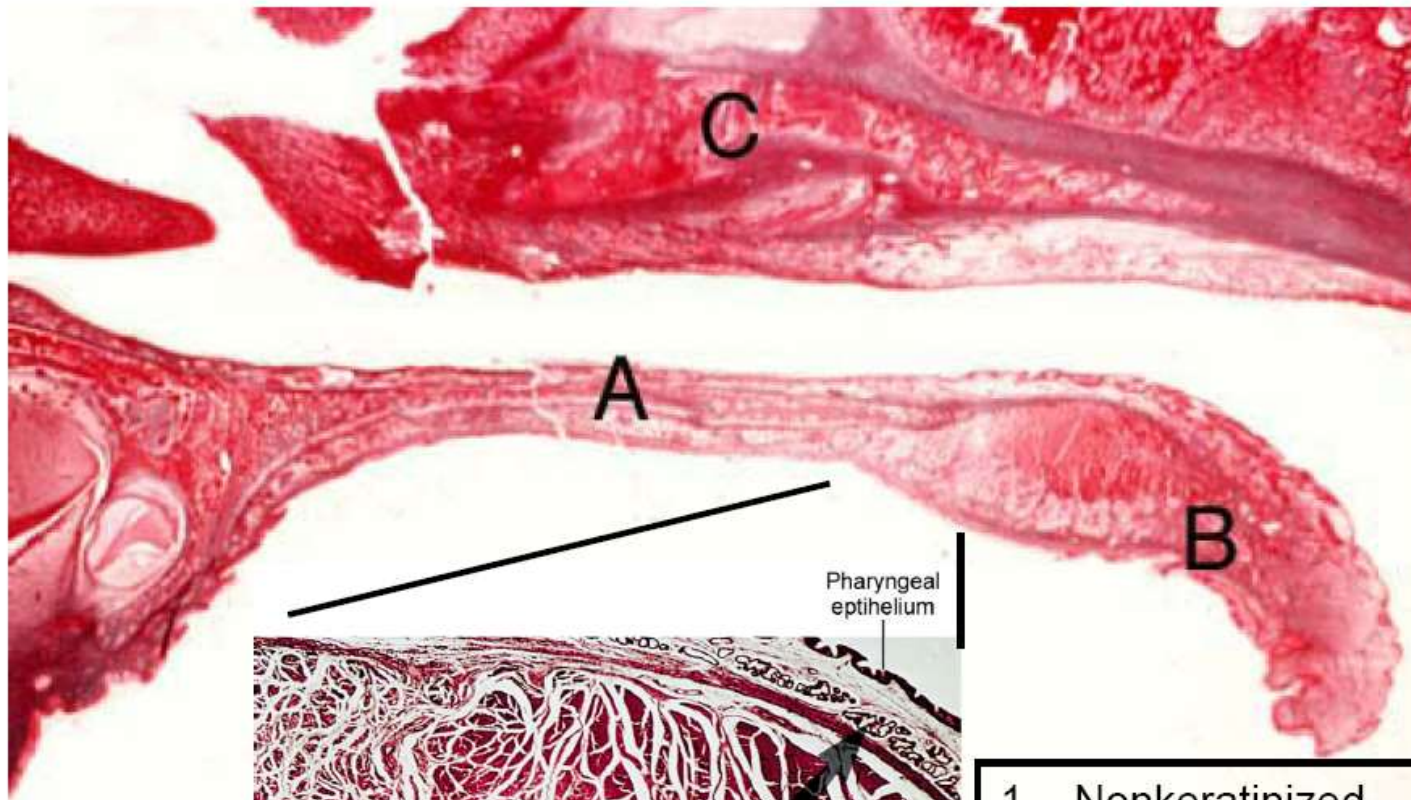
- A: Sweat glands
- B: Sebaceous glands
- C: Hair follicles

## Vermillion Zone and Labial Mucosa

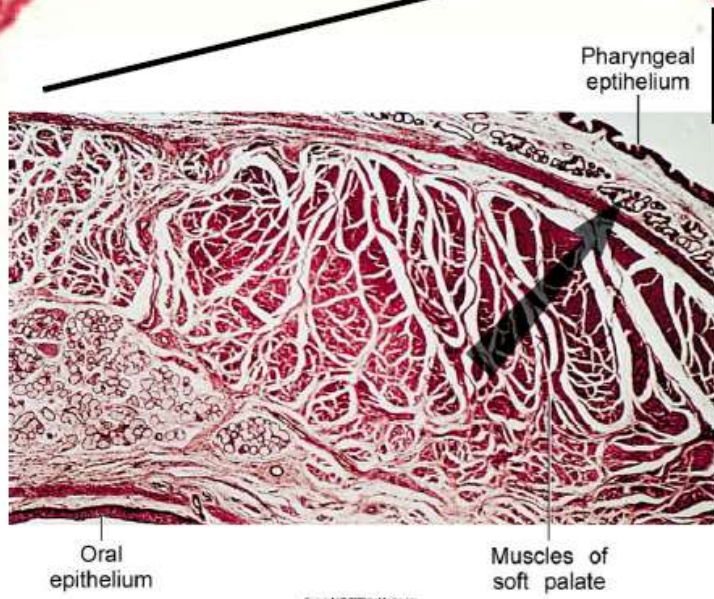


- A: Vermillion zone
- B: Labial mucosa
- C: Orbicularis oris muscle

Soft palate



**A: Hard Palate**  
**B; Soft palate**  
**C: Nasal cavity**

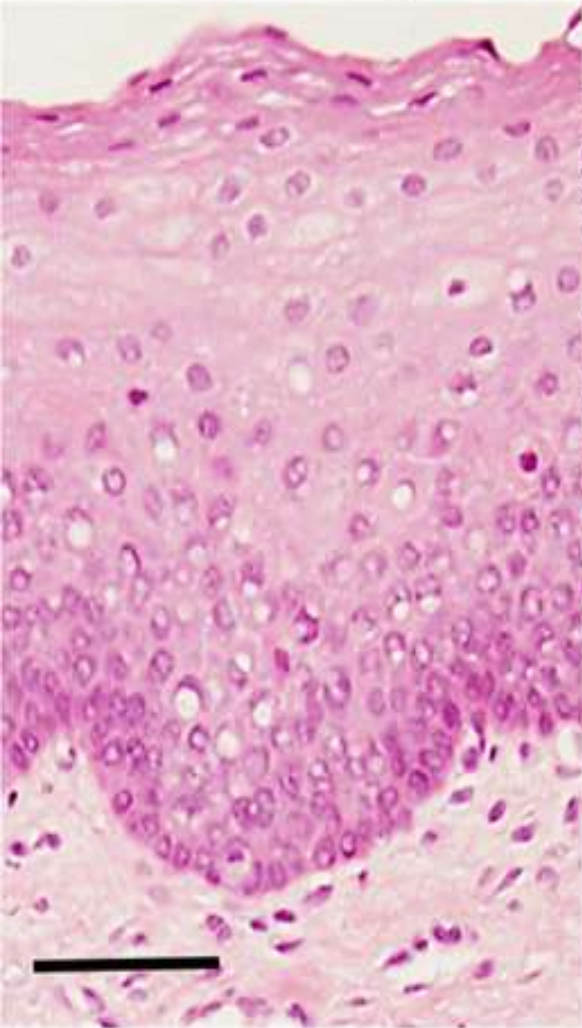


Copyright © 2009 by Mosby, Inc.

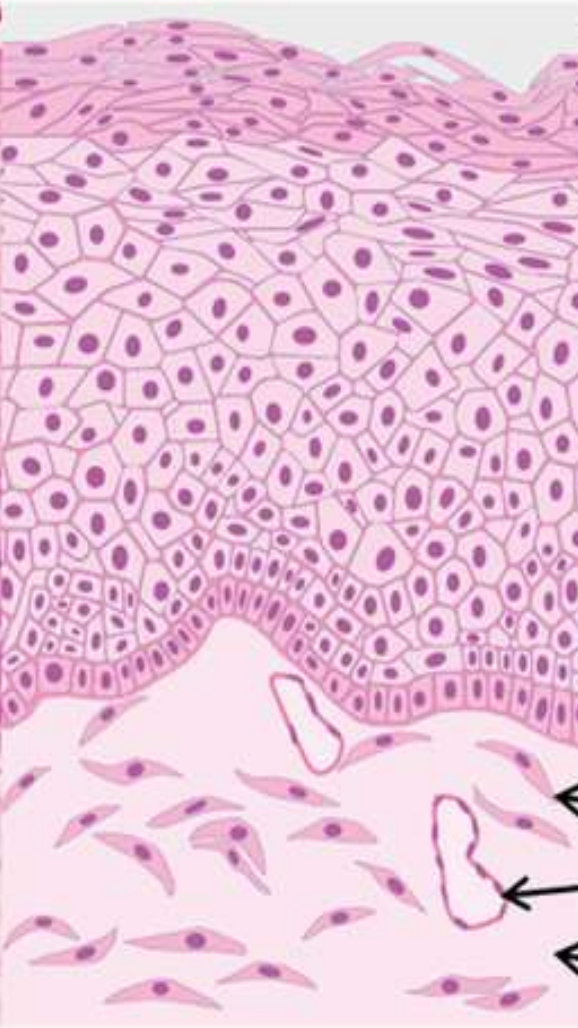1. Nonkeratinized
2. Highly vascularized so more pink than hard palate
2. Lamina propria and submucosa present (unlike hard palate when only lamina propria is noted – mucoperiosteum)
3. Submucosa contains salivary glands and muscle soft palate

# Cheeks (Buccal Mucosa)

Histology



Schematic



Mucus

Superficial, nucleated  
non-keratinized  
differentiated epithelium

Stratum spinosum

Stratum basale

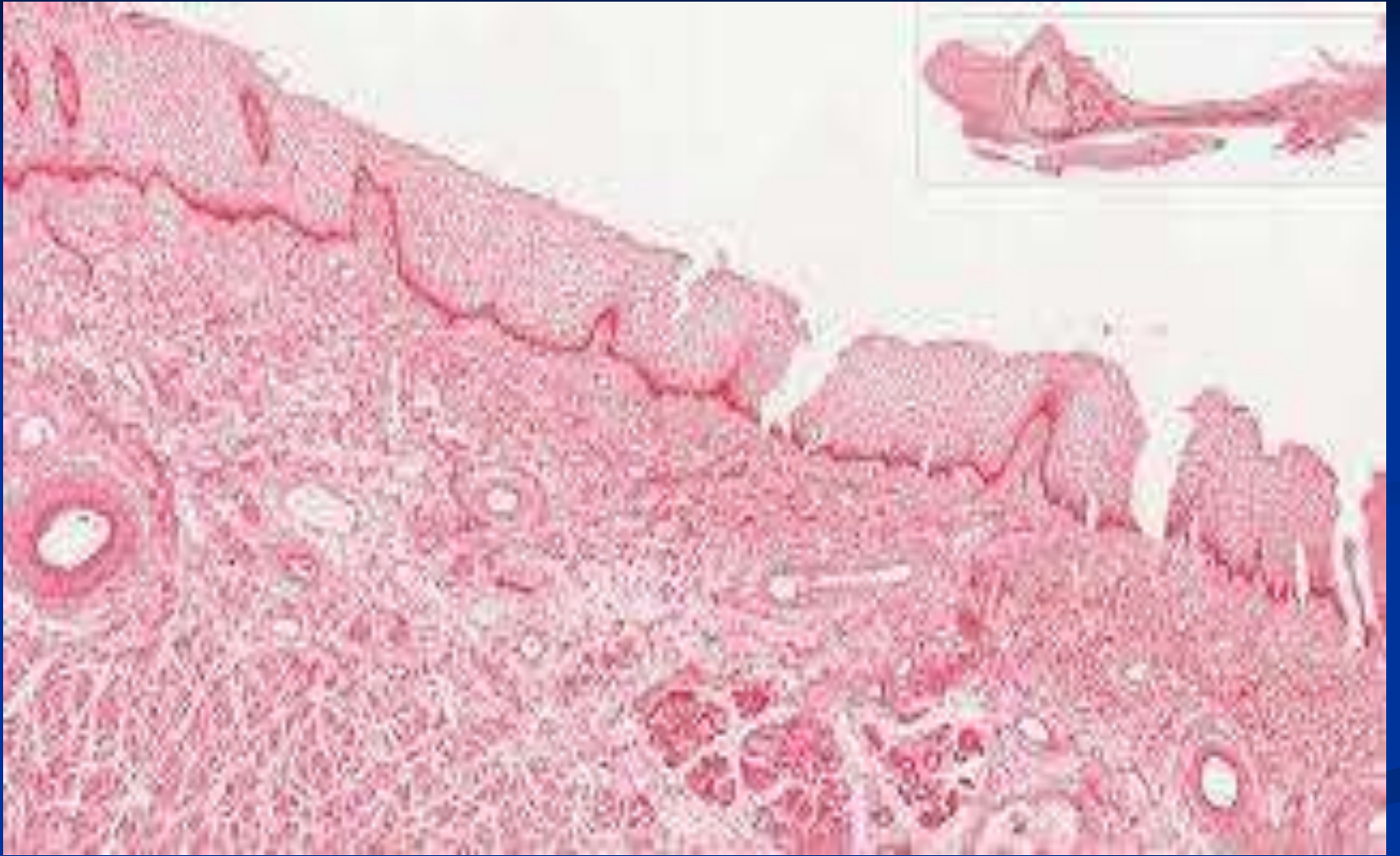Oral fibroblast

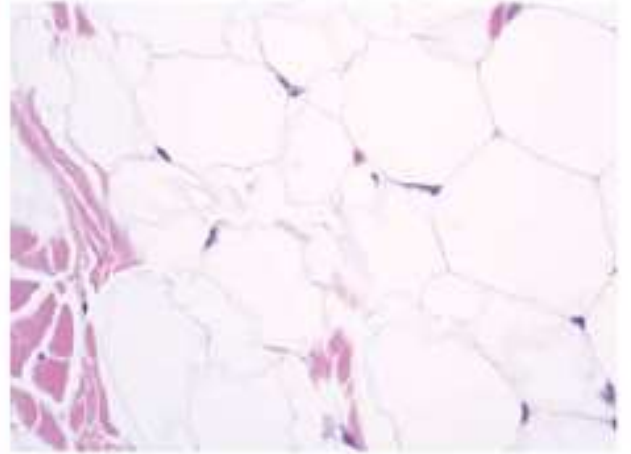
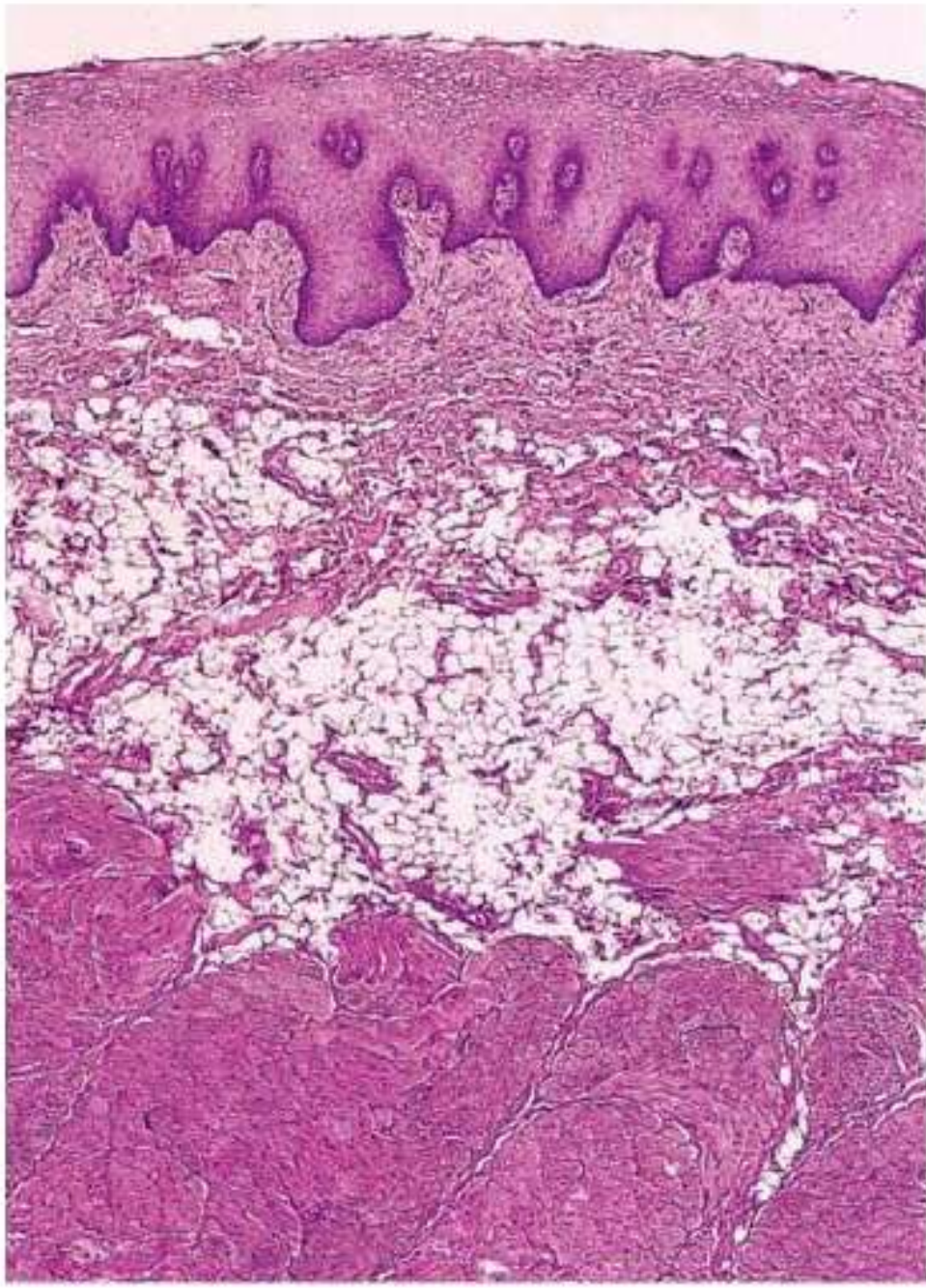
Blood vessel

Connective tissue

Stratified squamous  
epithelium

Lamina propria





# Cheeks (Buccal Mucosa)

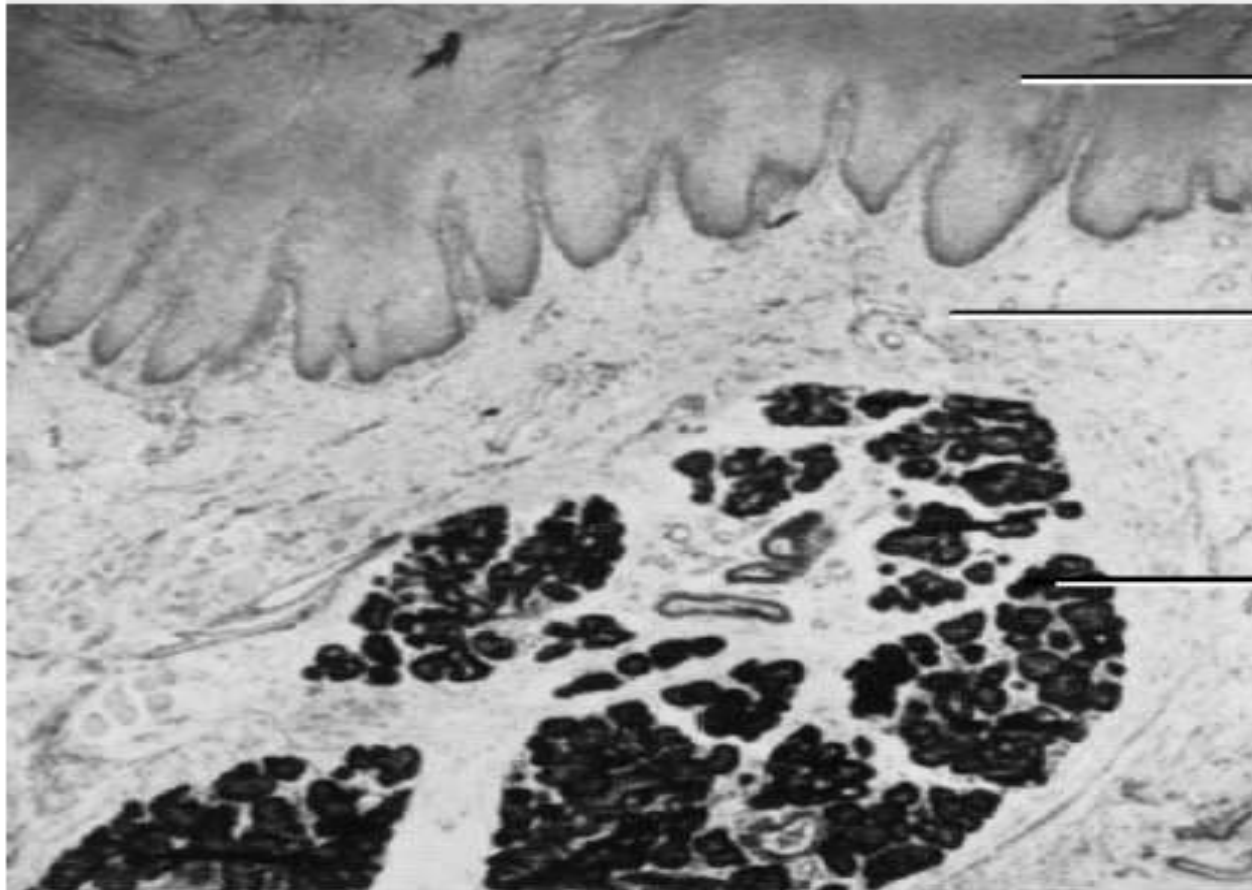
- Similar to lips and soft palate
- Non-keratinized stratified squamous epithelium, lamina propria and submucosa
- Submucosa of cheeks contain fat cells along with lobules of minor salivary glands and muscle fibers

- The **strands of dense connective tissue** limit the mobility mucous membrane, holding it to the musculature and preventing the elevation between folds.
- This prevents mucous membrane of lips and cheeks from lodging between biting surfaces of teeth.

# Ventral surface of tongue

- Nonkeratinized stratified squamous epithelium, lamina propria and submucosa
- Thin epi loosely attached to underlying structures– free mobility of tongue
- Extremely dense muscle fibers
- interlacing connective tissue fibers in submucosa

# Floor of mouth



Epithelium of  
floor of mouth

Connective tissue  
fibers

Salivary gland  
(minor)

Nonkeratinized stratified squamous epithelium, lamina propria and submucosa

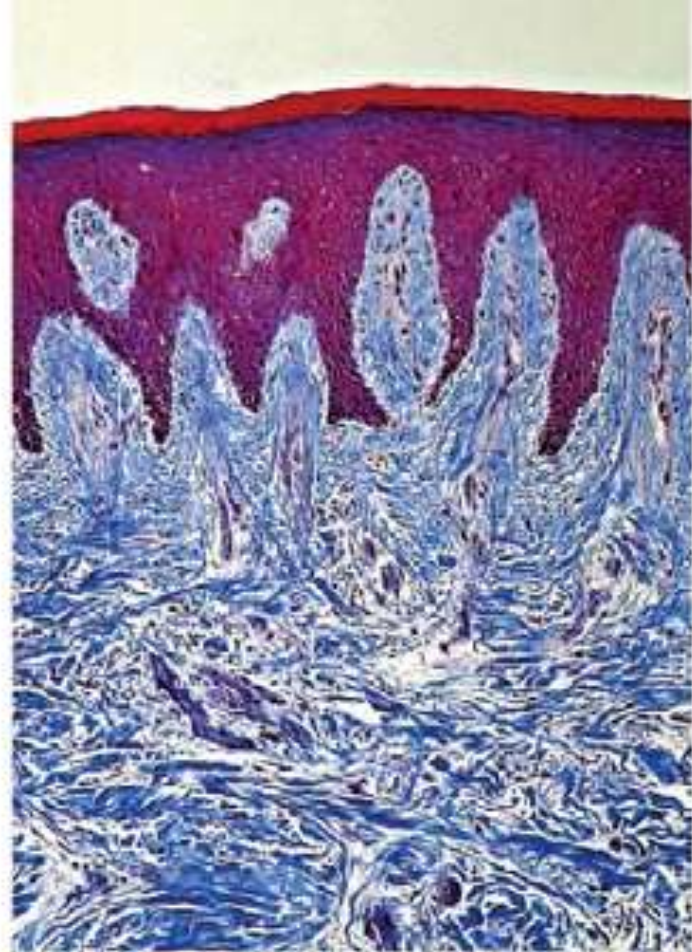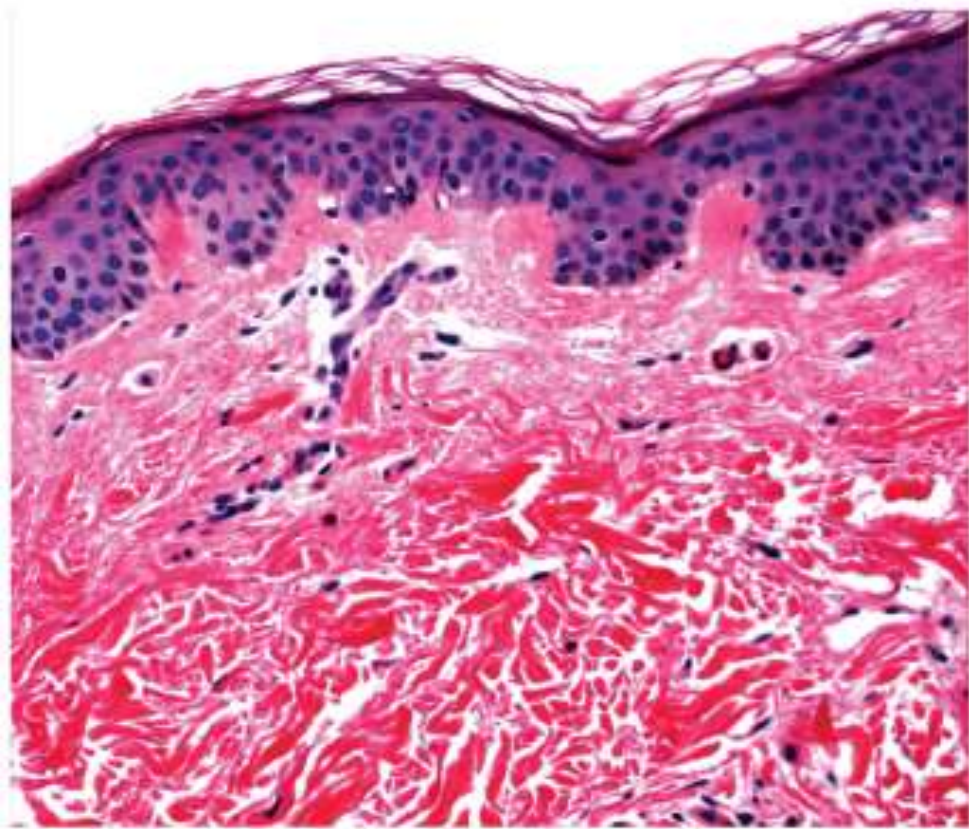
Epithelium is loosely attached to lamina propria

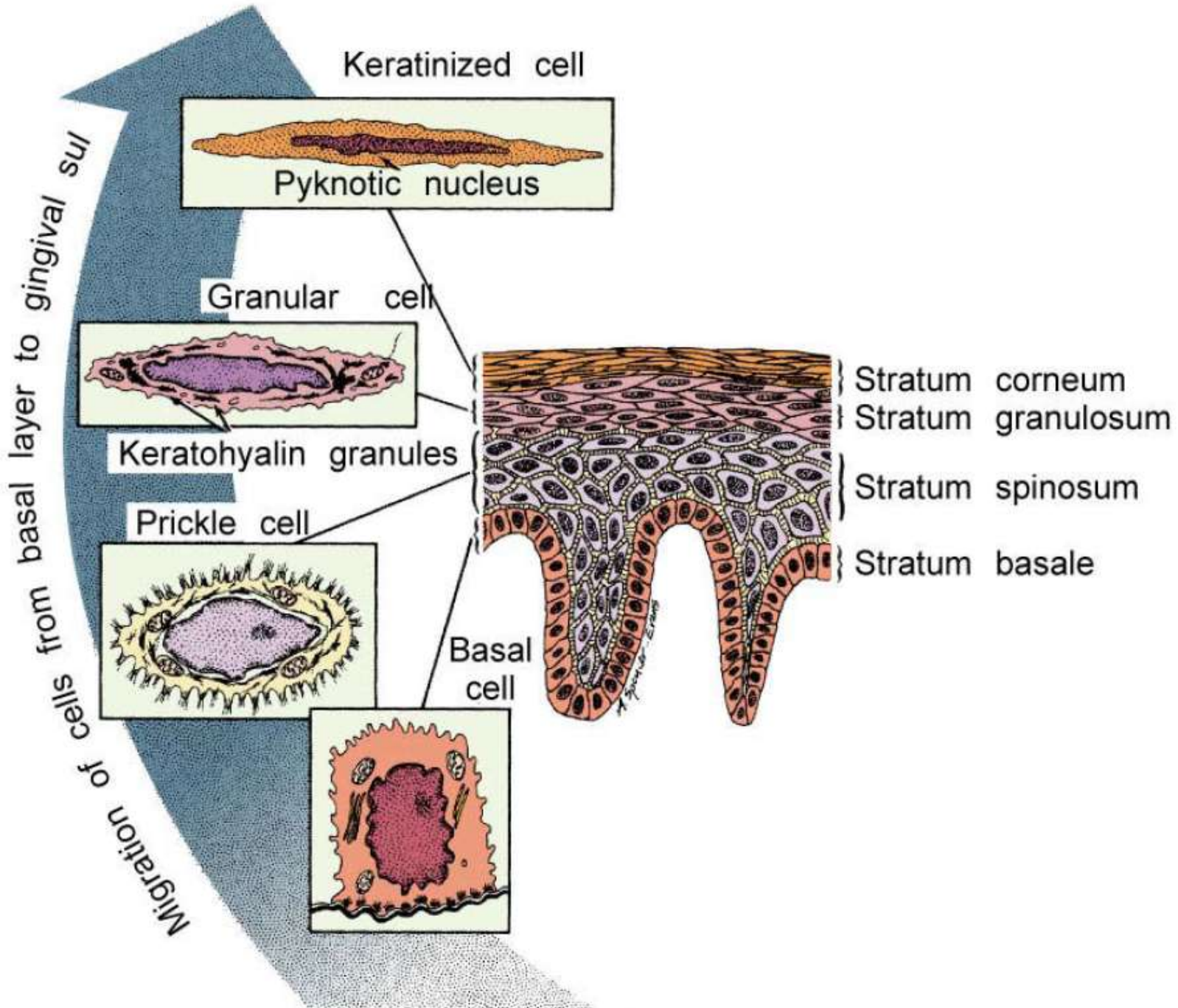
No muscle



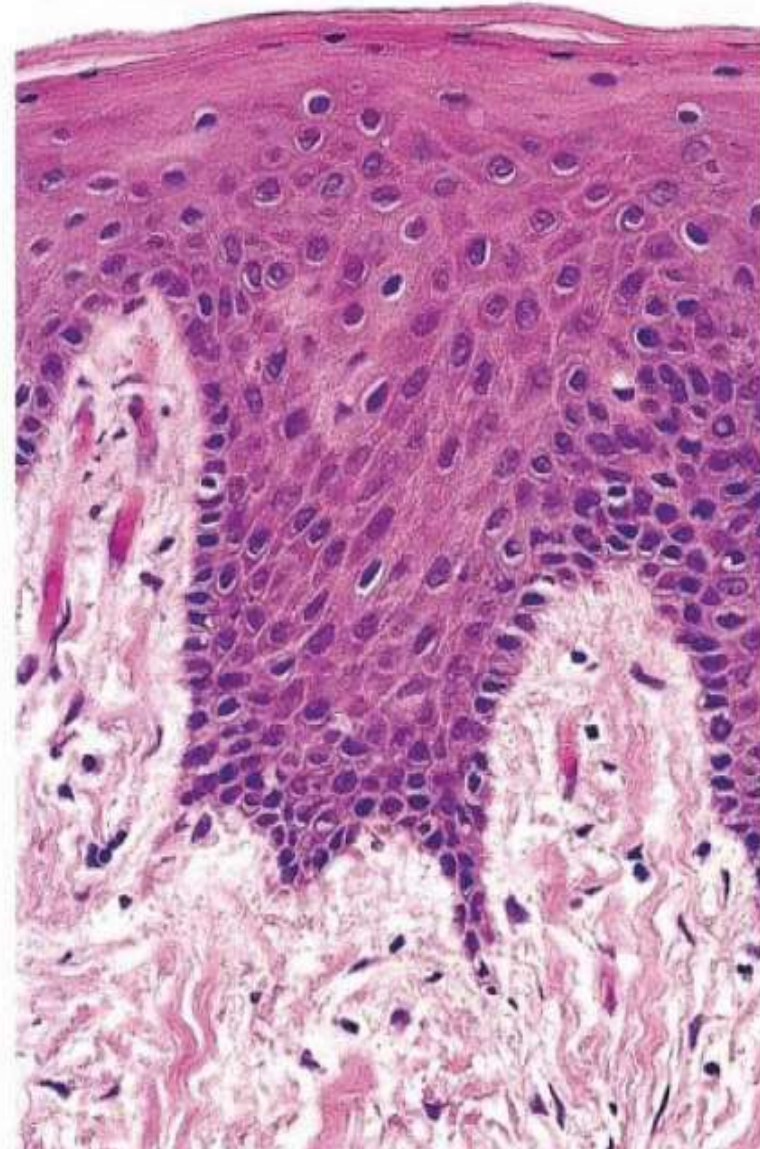
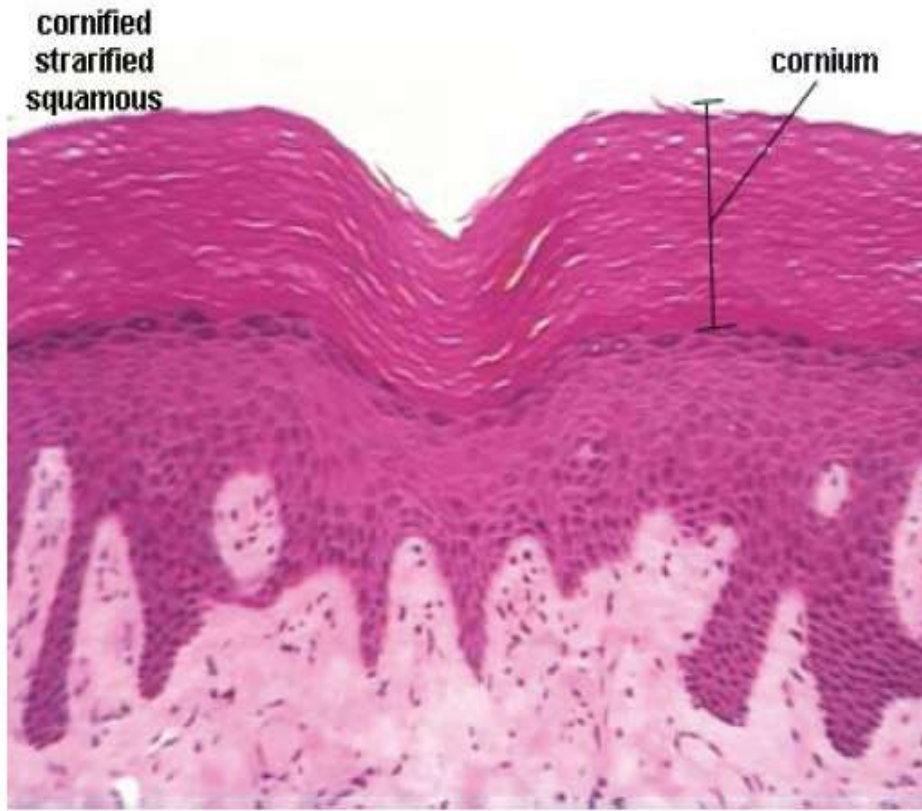
# Masticatory Mucosa

- Epithelium that covers gingiva and hard palate
- Mucosa is thicker than nonkeratinized because of the keratin layer
- **Stratum basale**-Same as nonkeratinized epithelium
- **Stratum spinosum**-Same as nonkeratinized epithelium
- **Stratum granulosum**: Cells contain keratohyaline granules
- **Stratum corneum** :Contains thin, flat and non nucleated cells which are filled with keratin. In contrast to the hard keratin seen in nails and hair, keratin overlying normal masticatory oral mucosa is soft. Keratin is tough, nonliving material that is resistant to friction and impervious to bacterial invasion. Same as nonkeratinized epithelium



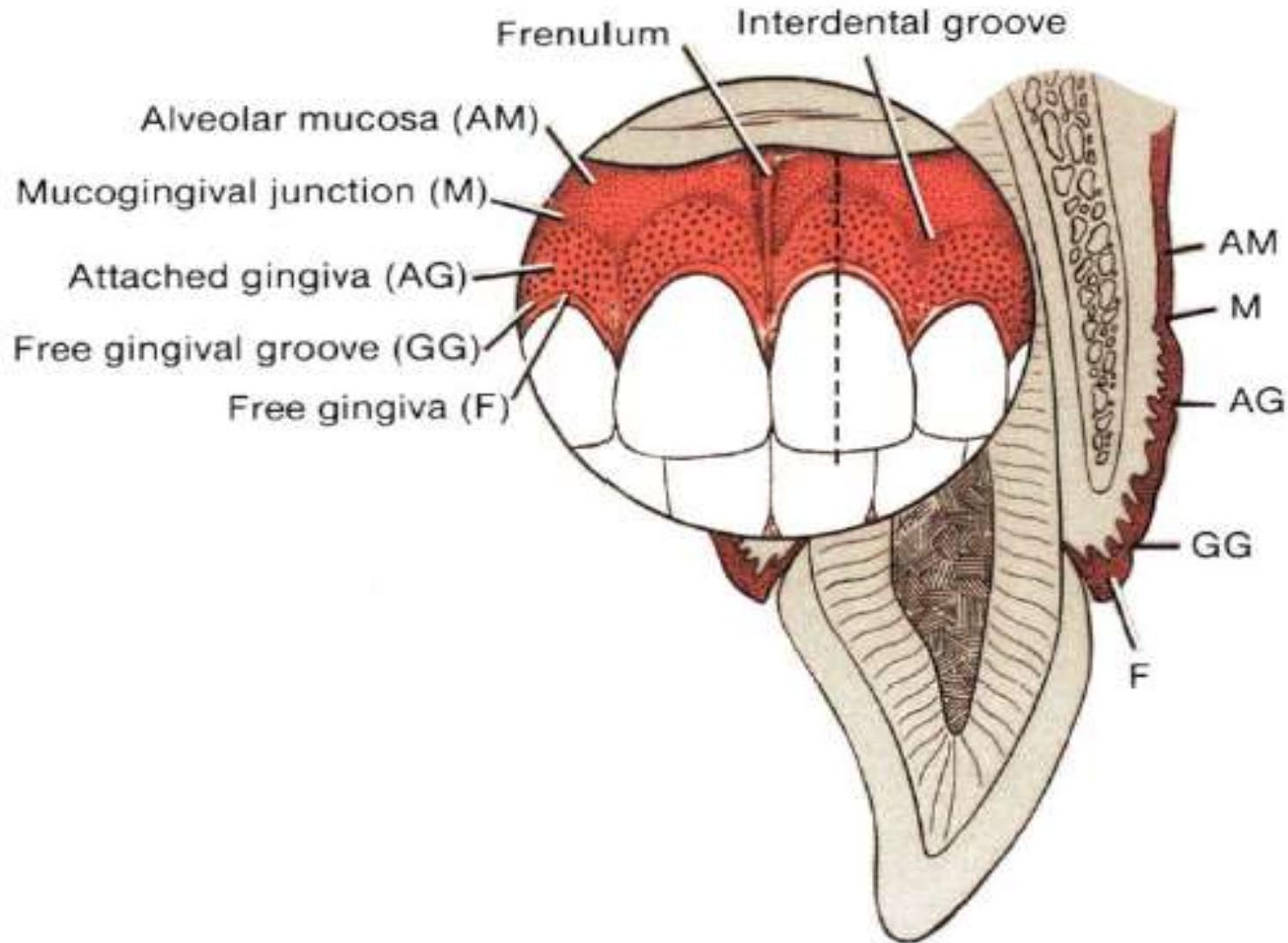


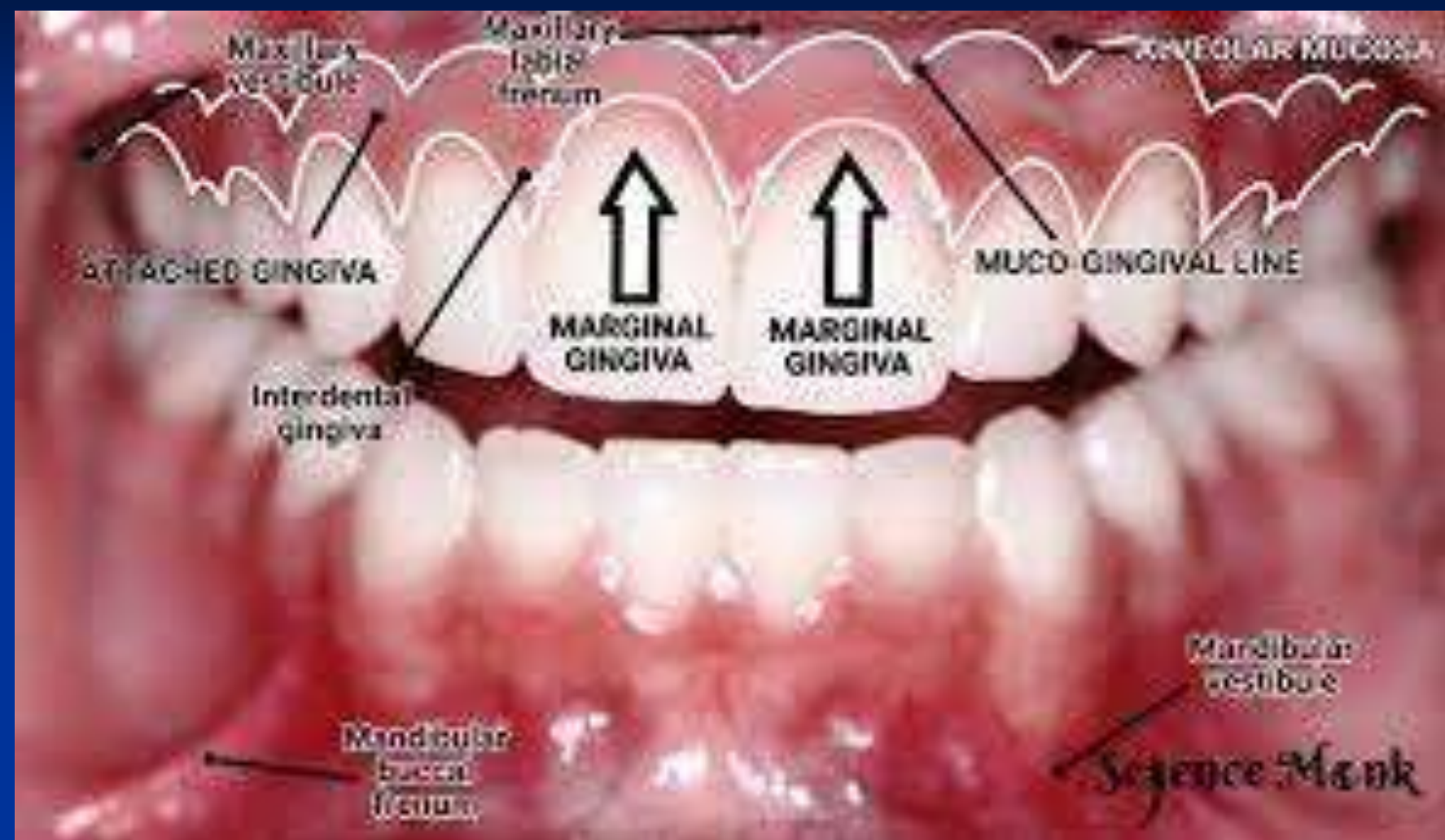# Types of Keratinized Epithelium

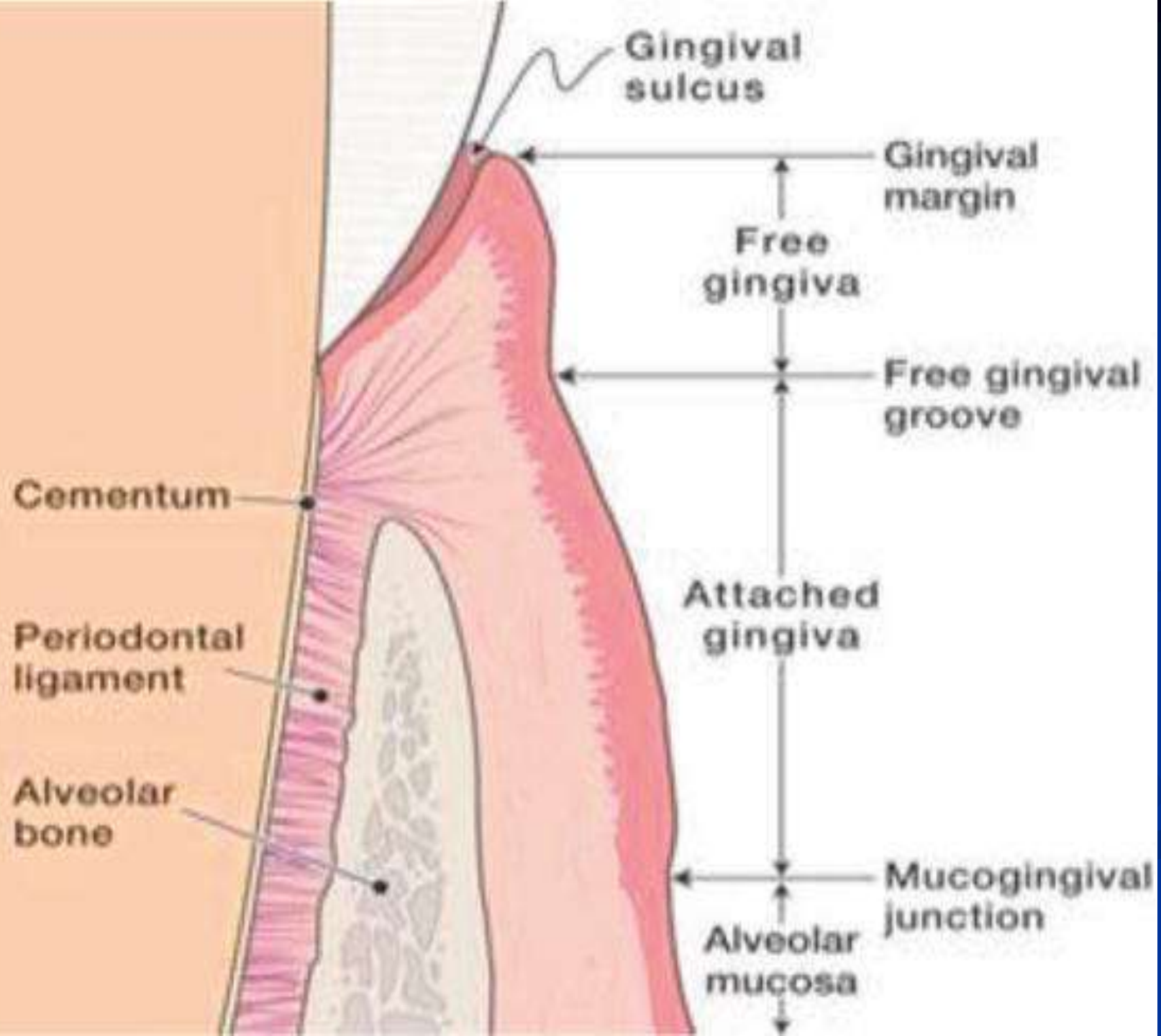


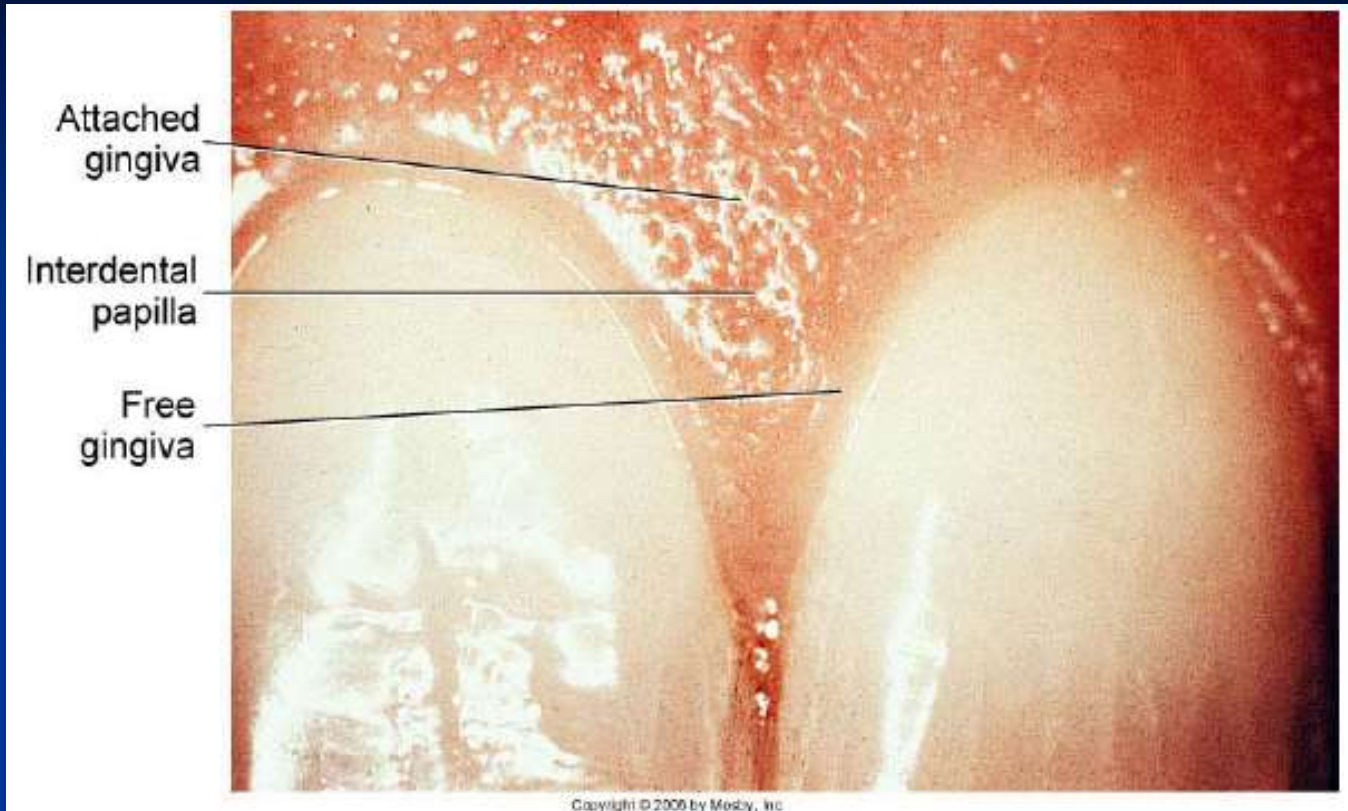
- **Epithelium**-- The superficial cells are dead but retain the nucleus in parakeratinized epithelium but the nuclei are lost in orthokeratinized epithelium
- The rete pegs are long and slender in keratinized epithelium
- Mucoperiosteum

# Gingiva and Epithelial Attachment





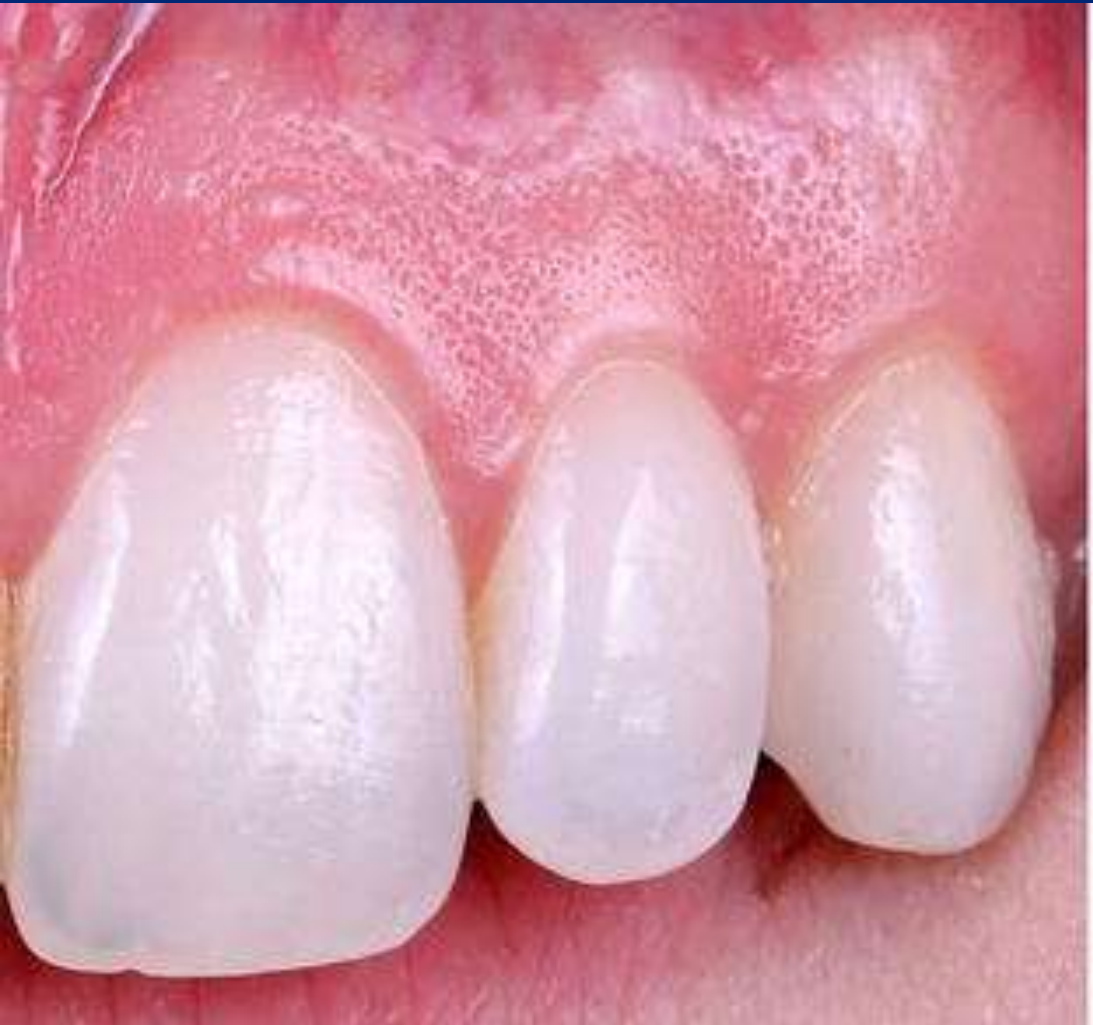



## Free or marginal gingiva

Attached gingiva attaches with the neck of the tooth by means of junctional epithelium

# STIPPLING



- Functional adaptation to mechanical forces
- Healthy gingiva

# Histology of Gingiva

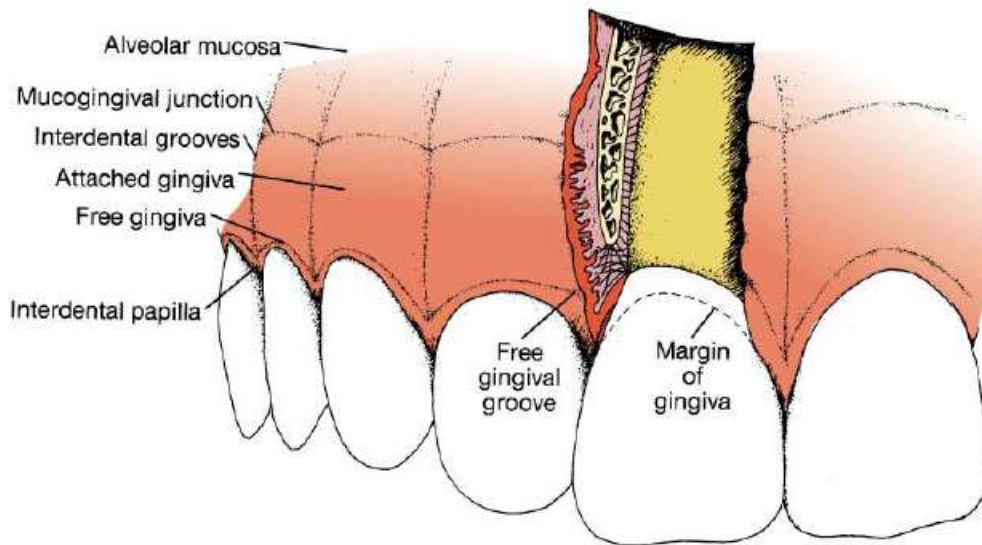
- Thick (250  $\mu\text{m}$ ), either orthokeratinized or parakeratinized stratified squamous epithelium with a stippled surface
- In healthy attached gingiva “**stippling**” is seen which appears as small pits in the epithelium and are due to deep rete pegs.
- The lamina propria is composed of long narrow papillae which are not highly vascular.
- No distinct submucosa is noted as the overlying mucosa is directly attached to the underlying periosteum and cementum by collagen fibers

- **Free Gingiva:**

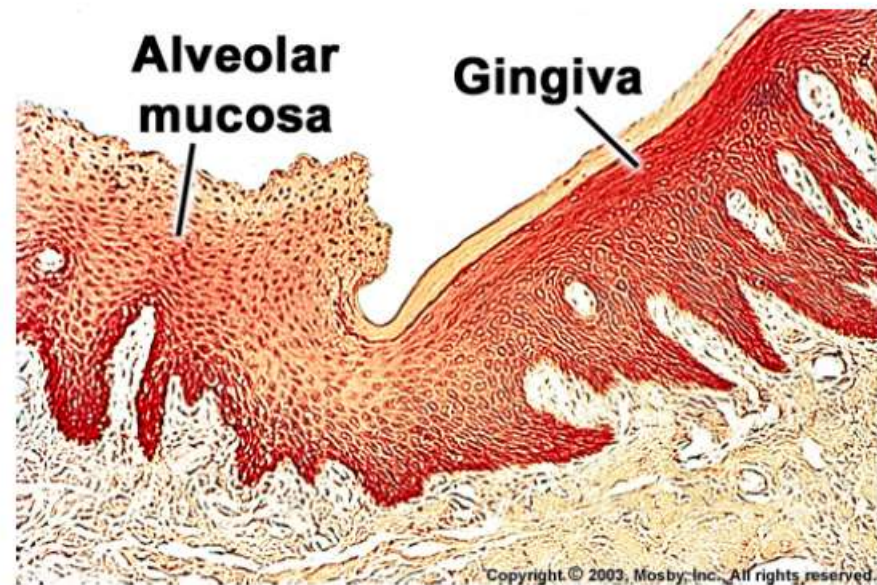
Keratinized; NOT STIPPLED; bound on inner margin by the gingival sulcus, which separates it from the tooth; bound on its outer margin by the oral cavity; and apically by the free gingival groove.

- **Attached Gingiva:**

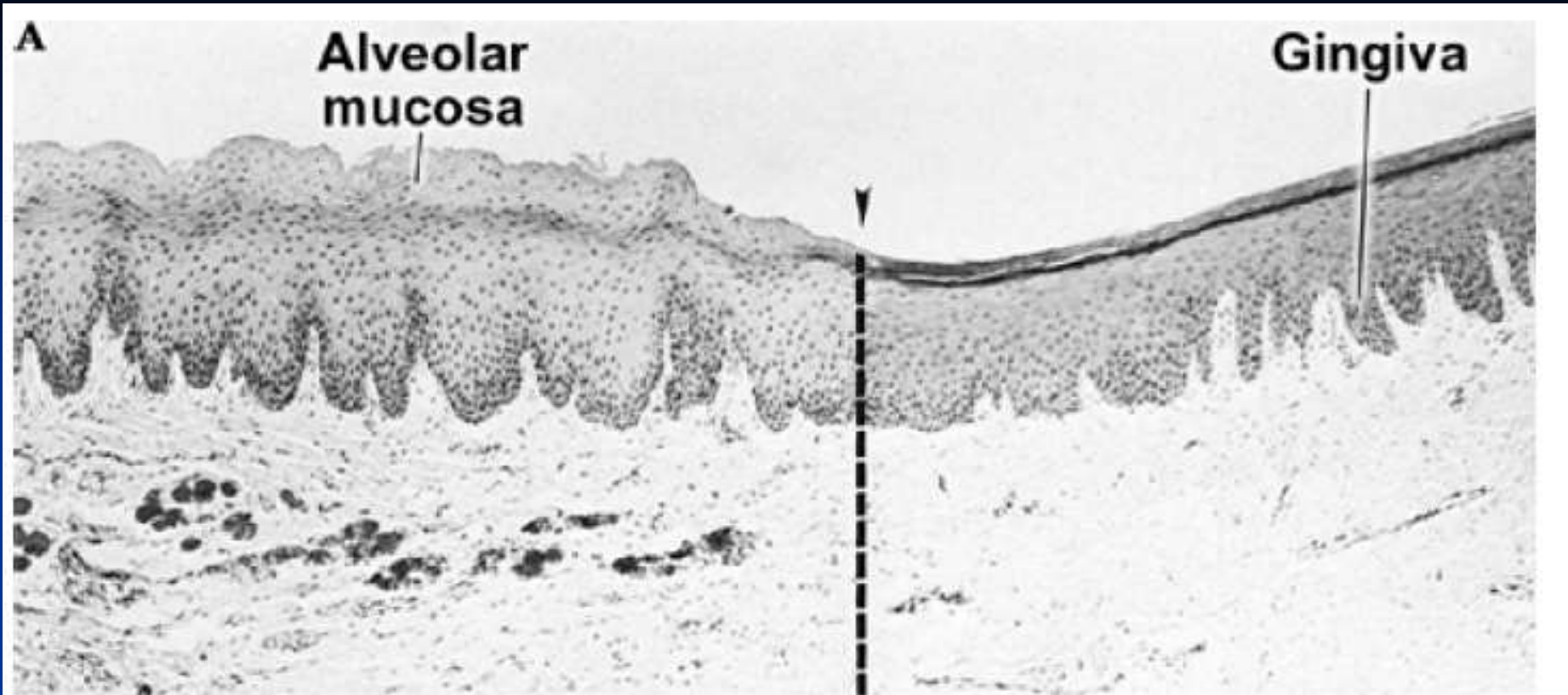
Keratinized; STIPPLED; separated from the alveolar mucosa by the mucogingival junction (groove). Attached to the tooth by junctional epithelium.




Copyright © 2006 by Mosby, Inc.



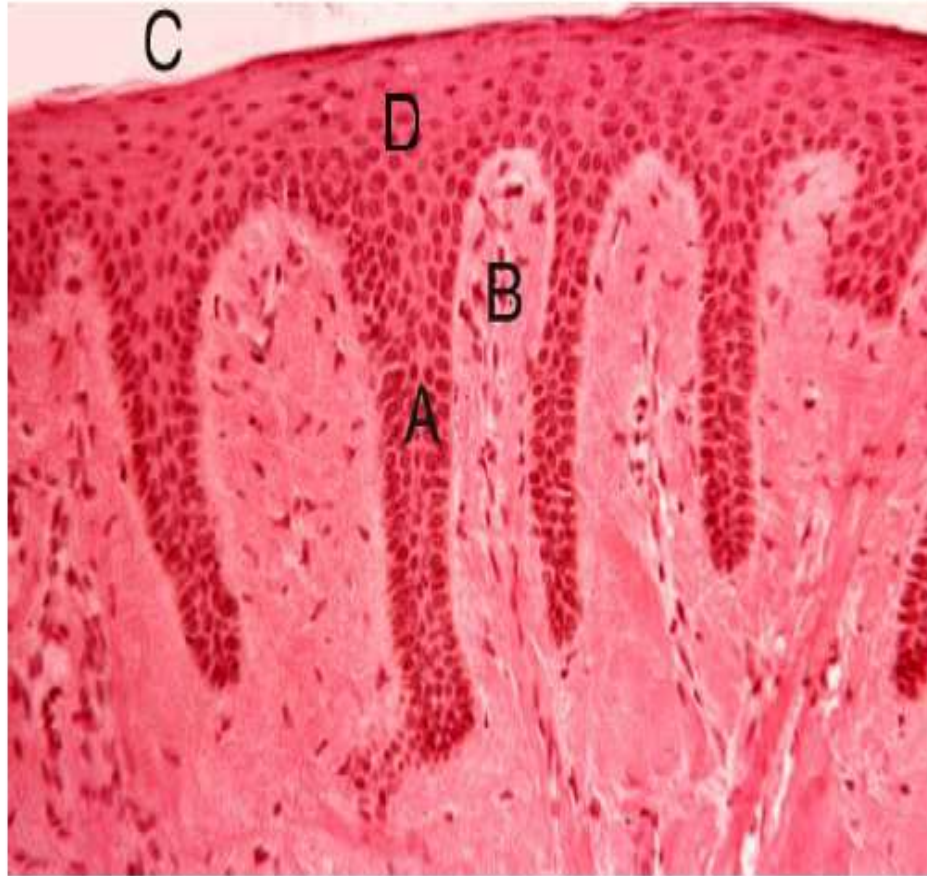
Copyright © 2003, Mosby, Inc. All rights reserved.



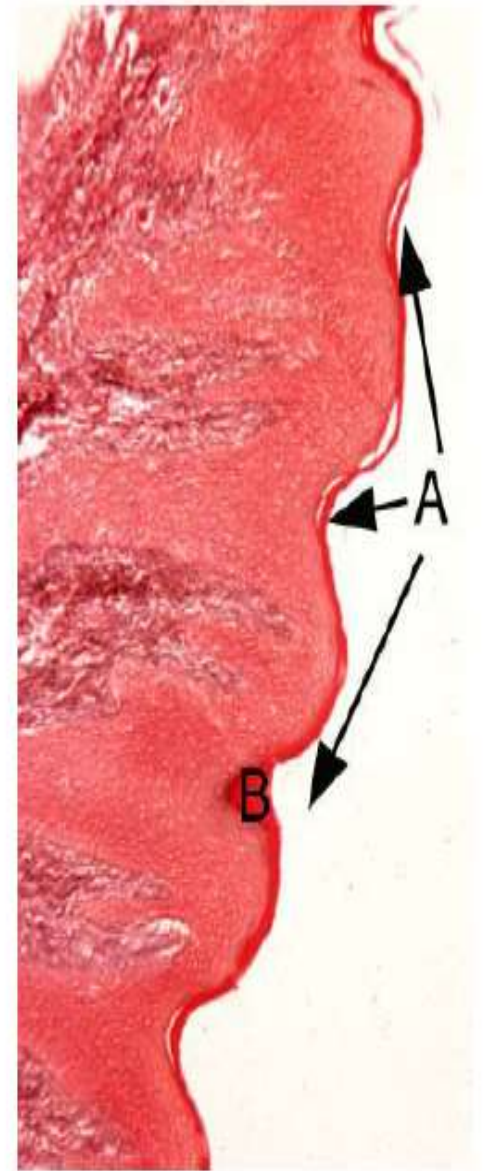
note the difference in keratinization, thickness of epithelium and ridge pattern.



stained with an elastic stain, note the presence of elastic fibers in lamina propria in alveolar mucosa. Not much difference in the epithelium is seen between the two types of mucosa.



- A: Rete pegs
- B: Conective tissue papilla
- C: Parakeratin
- D: Spinous layer

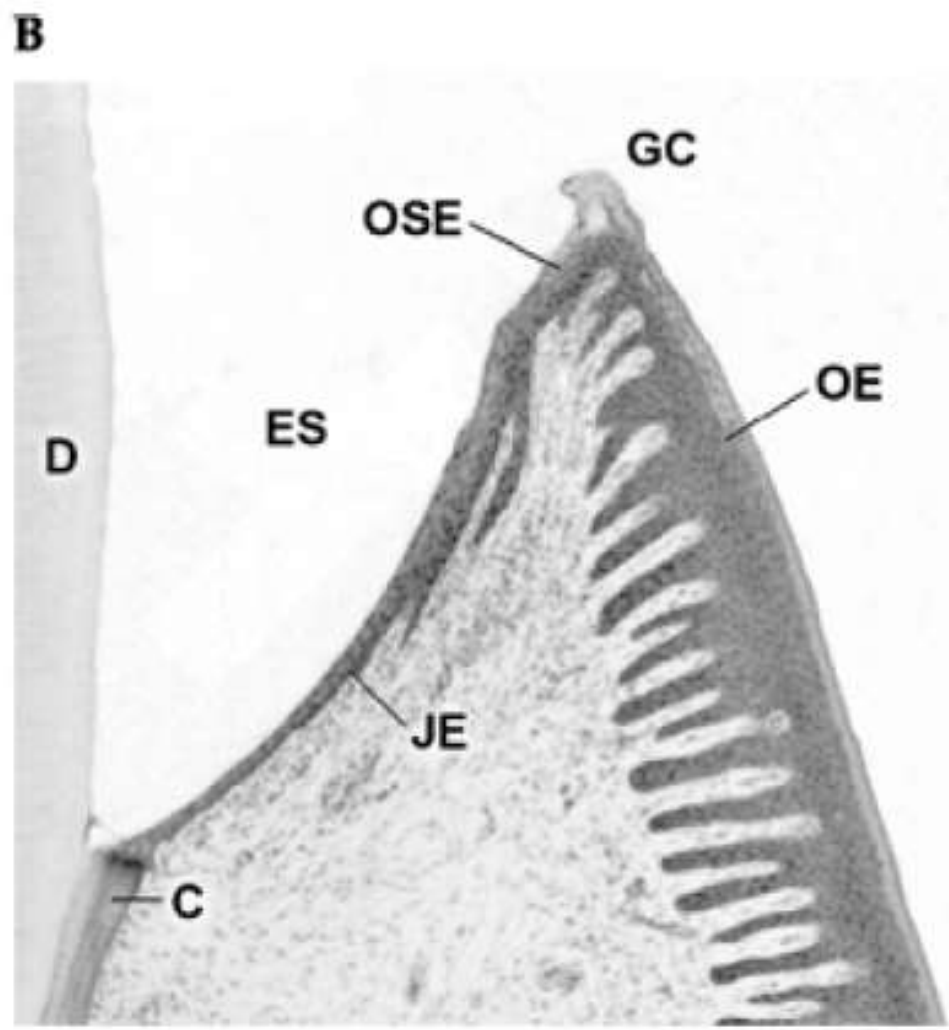
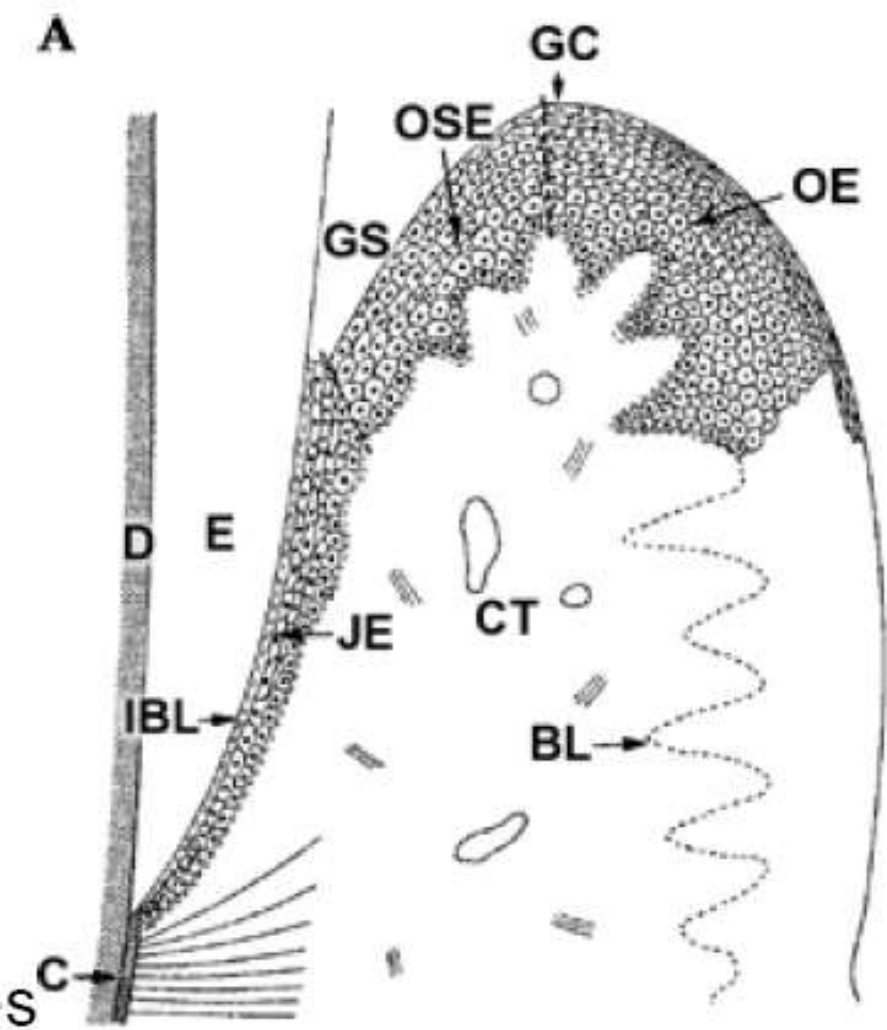


- In healthy attached gingiva “**stippling**” is seen which appears as small pits in the epithelium and are due to deep retepegs.
- The lamina propria is composed of long narrow papillae which are not highly vascular.
- No distinct submucosa is noted as the overlying mucosa is directly attached to the underlying periosteum and cementum by collagen fibers

# Dentogingival Junction and Junctional Epithelium

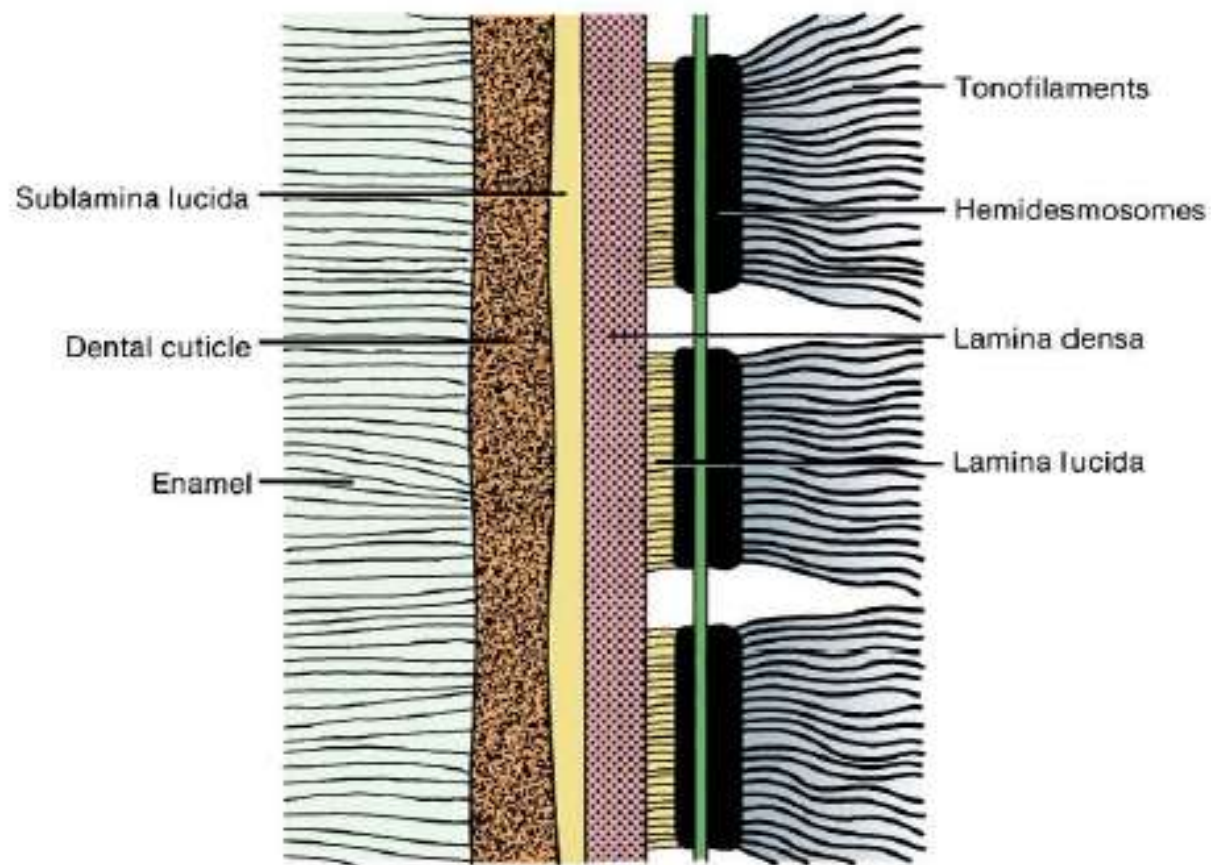
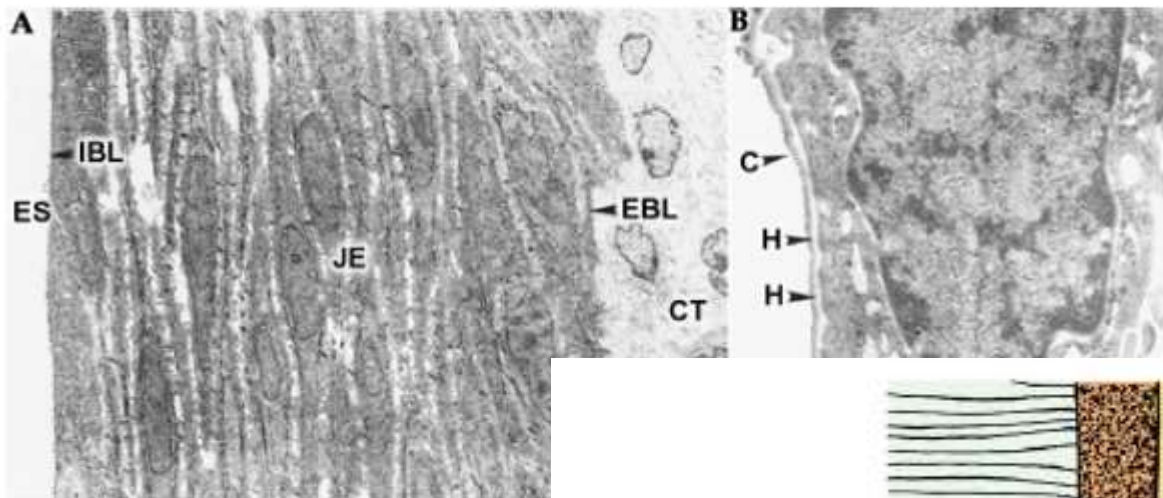
- Dentogingival junction is the region where the oral mucosa meets the surface of the tooth
- Very important because it is a weak area in the oral mucosa which is otherwise continuous
- Bacteria on the surface of the tooth produce toxins that can incite inflammation and damage if it enters into the mucosal tissues
- Gingival sulcus in healthy individuals is  $\sim 0.5$  to 3 mm (mild inflammation is present-1.8 mm average)

- Depth greater than 3mm is considered pathologic; and the sulcus represents periodontal pocket
- Floor of the sulcus and the epithelium cervical to it is called **junctional epithelium** which is in contact with the tooth surface (enamel and some times cementum)
- Wall of the gingival sulcus is lined by **NON-KERATINIZED** stratified squamous epithelium that is derived from and continuous with the rest of the oral mucosa –oral sulcular epithelium



# Junctional Epithelium

- The epithelium that is attached to the tooth (enamel or sometimes cementum) surface continuous with sulcular epithelium
- Derived from reduced enamel epithelium of the tooth germ
- Junctional epithelium consists of flat cells aligned parallel to the tooth surface increasing in thickness from the apex to the crown
- Attached to enamel by internal basal lamina and to the connective tissue by external basal lamina.
- Hemidesmosomes are present in both basal laminas.



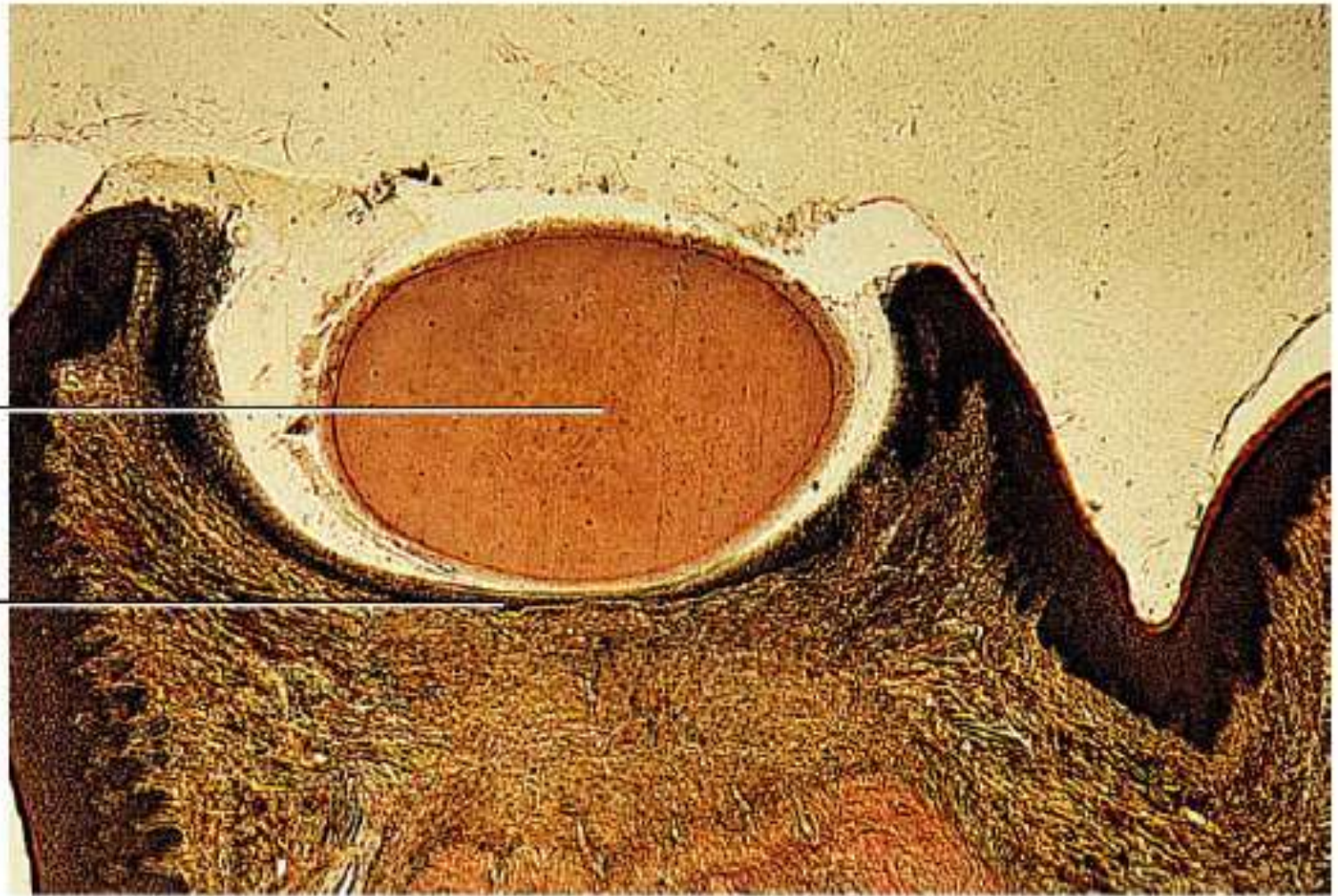
Copyright © 2006 by Mosby, Inc.

# Epithelial cell turnover in gingiva

- Similar to all other epithelia, the deeper cells adjacent to the connective tissue undergo cell division to replenish those lost at the surface
- High rate of cell division
- Migrate about 2 to 3 cell layers from the tooth surface and then join a main migratory route in a coronal direction, parallel to tooth surface, to be desquamated into the gingival sulcus.
- Key point: Junctional epithelium readily regenerates from the sulcular epithelium or oral epithelium if it is damaged or surgically excised
- Connective tissue normally contains plenty of neutrophils which is different than the normal oral mucosa

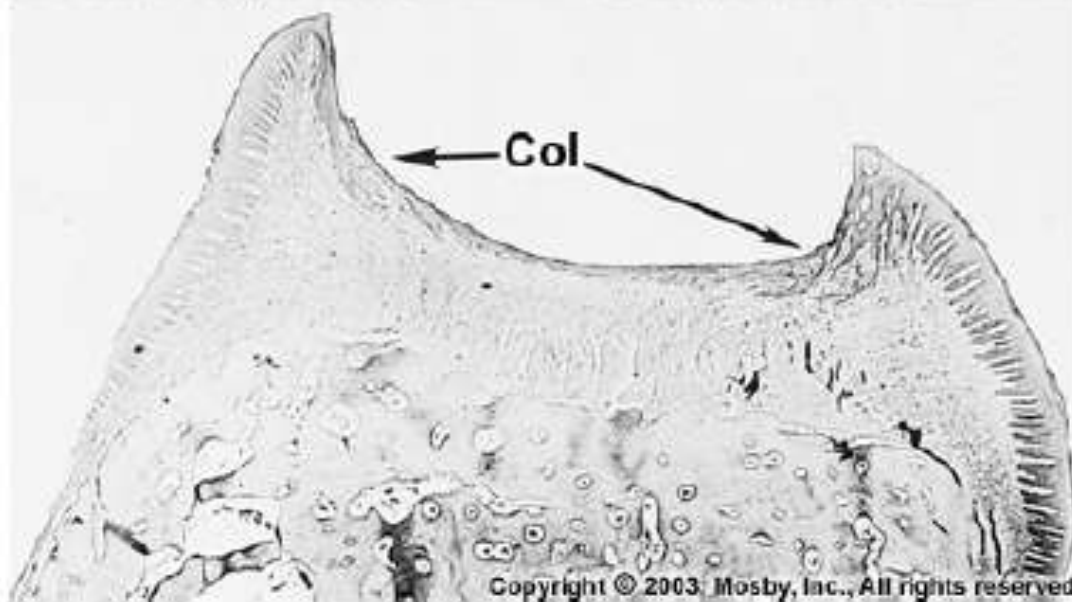
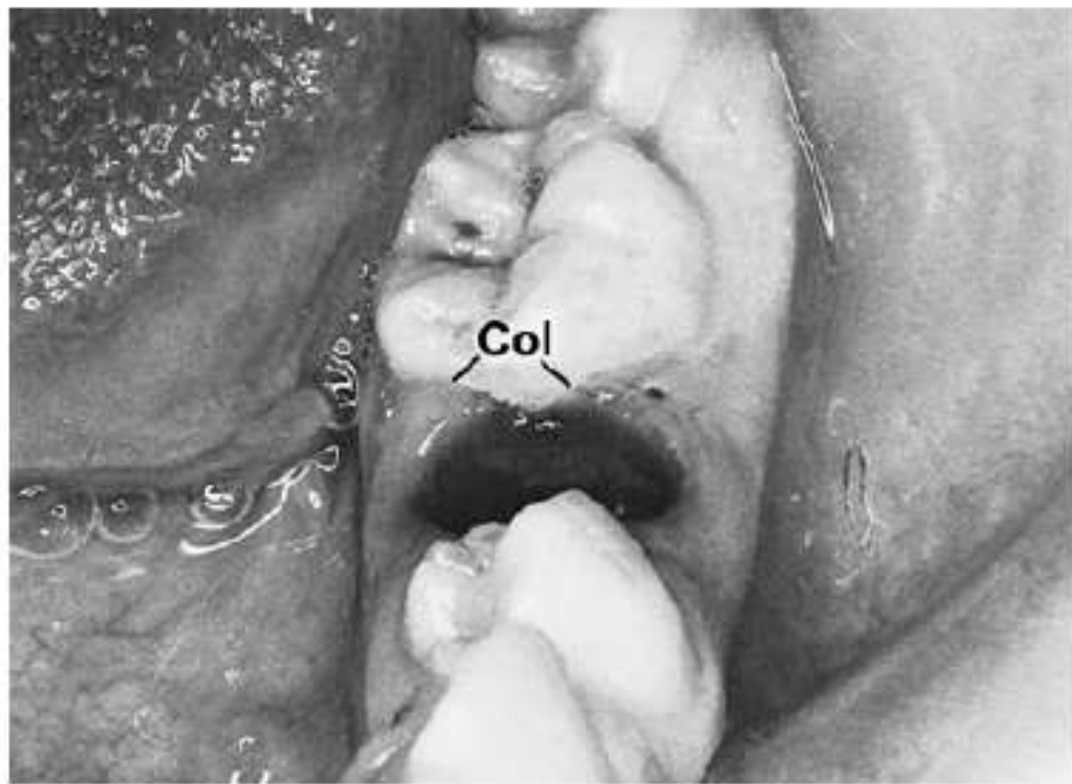
# Col

- Col (or depression): This is how the gingiva looks in the **interdental area**. Similar to an outline of a depression or col with buccal and lingual peaks. Col epithelium is identical to junctional epithelium and has the same origin (from dental epithelium) and is also replaced continually by cell division.
- Not sure if there is any significance that the col is more vulnerable to inflammation, but the incidence of gingivitis is greater interdentally.



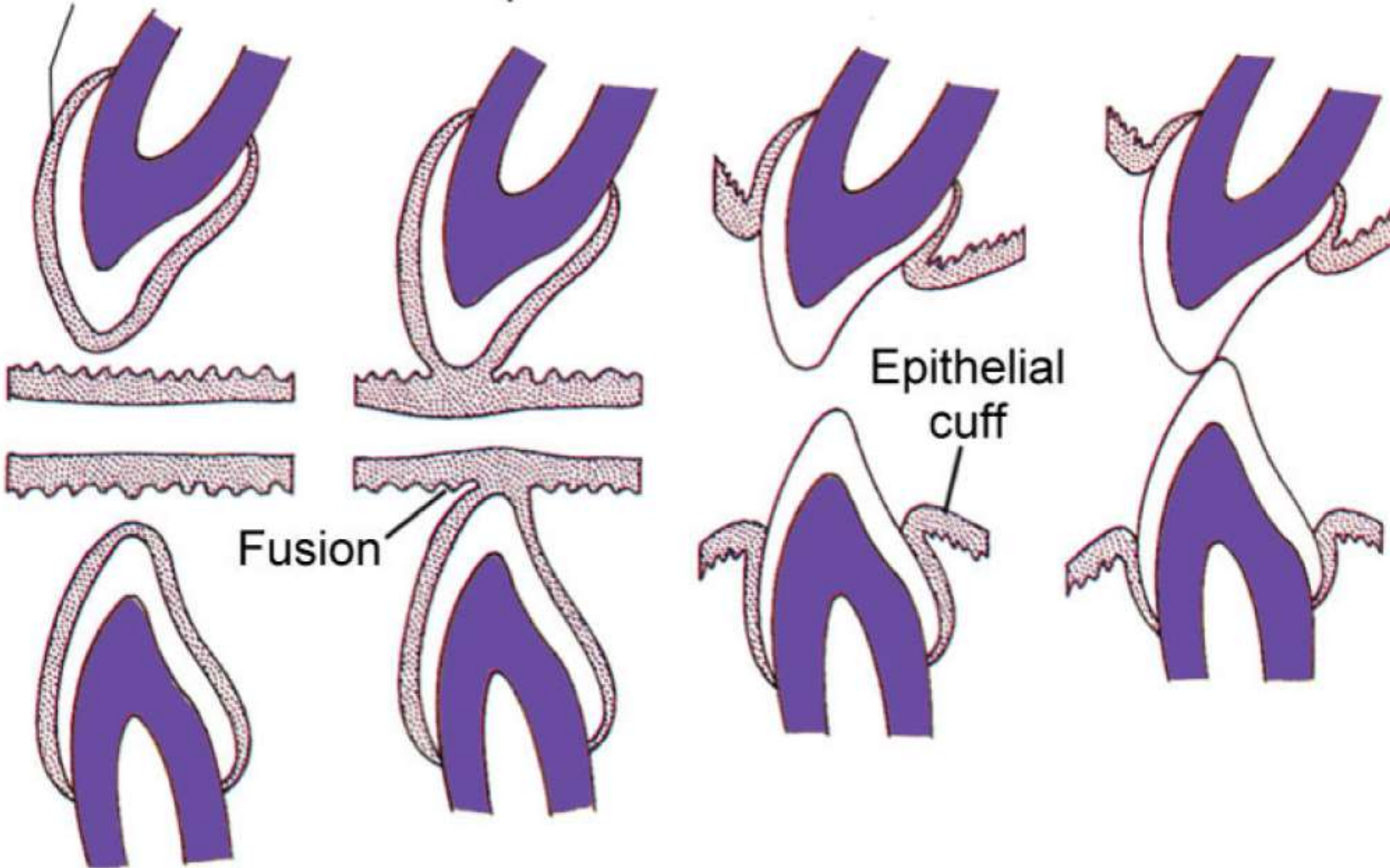
Dentin

Gingival  
lining of  
the col



# How does Gingiva develop?

Reduced enamel epithelium

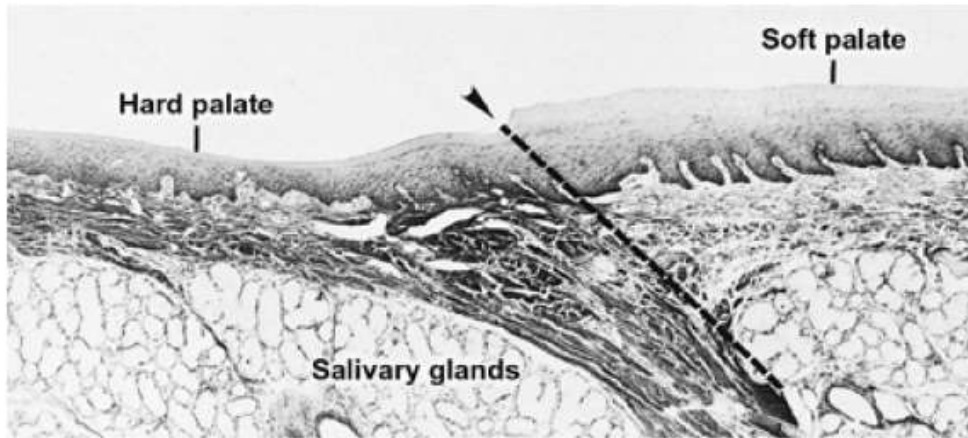


# A quick note on.....

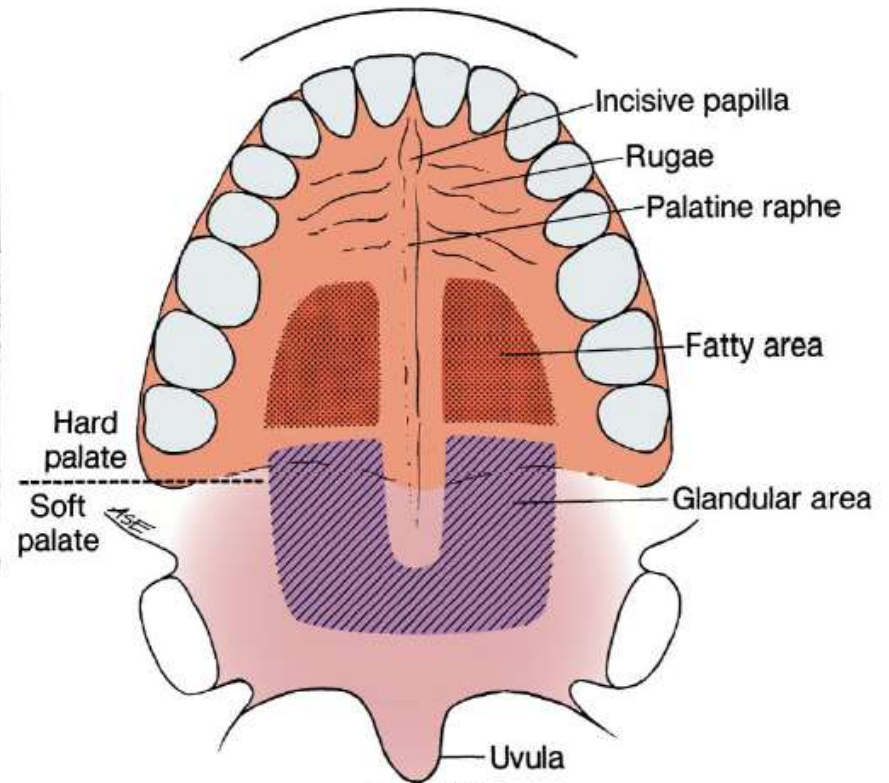
- **Blood supply to the gingiva:** Derived from periosteal vessels in the periosteum of the alveolar process
- **Blood supply to the dentogingival junction:** Continuation of inter alveolar arteries
- **Nerve supply to the gingiva:** terminal branches of periodontal nerve fibers and by branches of the infraorbital and palatine, or lingual, mental, and buccal nerves

# Histology of Hard Palate

- Thick orthokeratinized (or parakeratinized in areas) epithelium showing ridges (rugae)
- Lamina propria shows long papillae with thick dense connective tissue
- Submucosa is mucoperiosteum with dense collagenous connective tissue attaching directly to periosteum. Contains fat and salivary glands



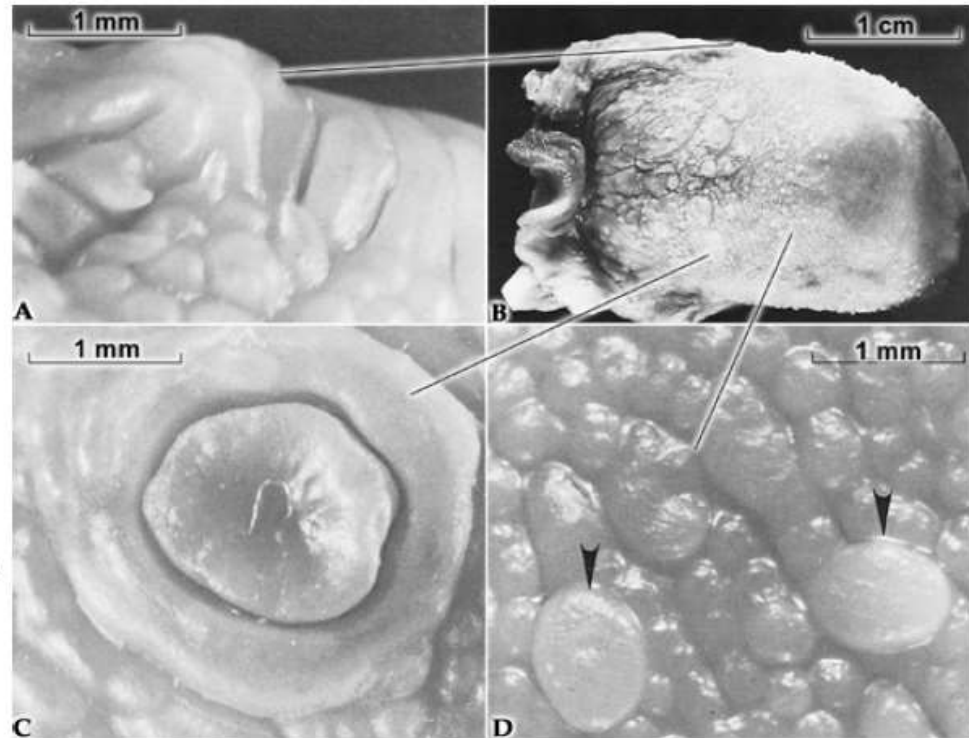
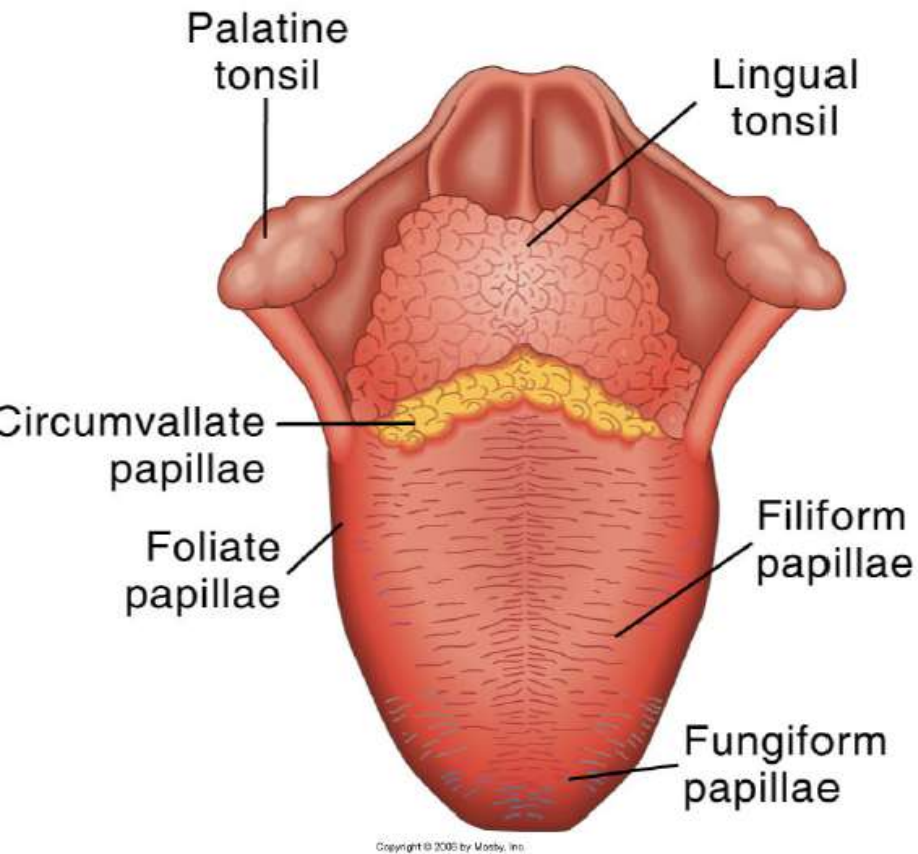
Copyright © 2003, Mosby, Inc.,



Copyright © 2003 by Mosby, Inc.

# Specialized Mucosa -Dorsal Tongue

## Types of papilla: 4 types



Copyright © 2003, Mosby, Inc., All rights reserved.

- A: Foliate
- C: Circumvallate
- D: Filiform

# NERVE SUPPLY OF TONGUE

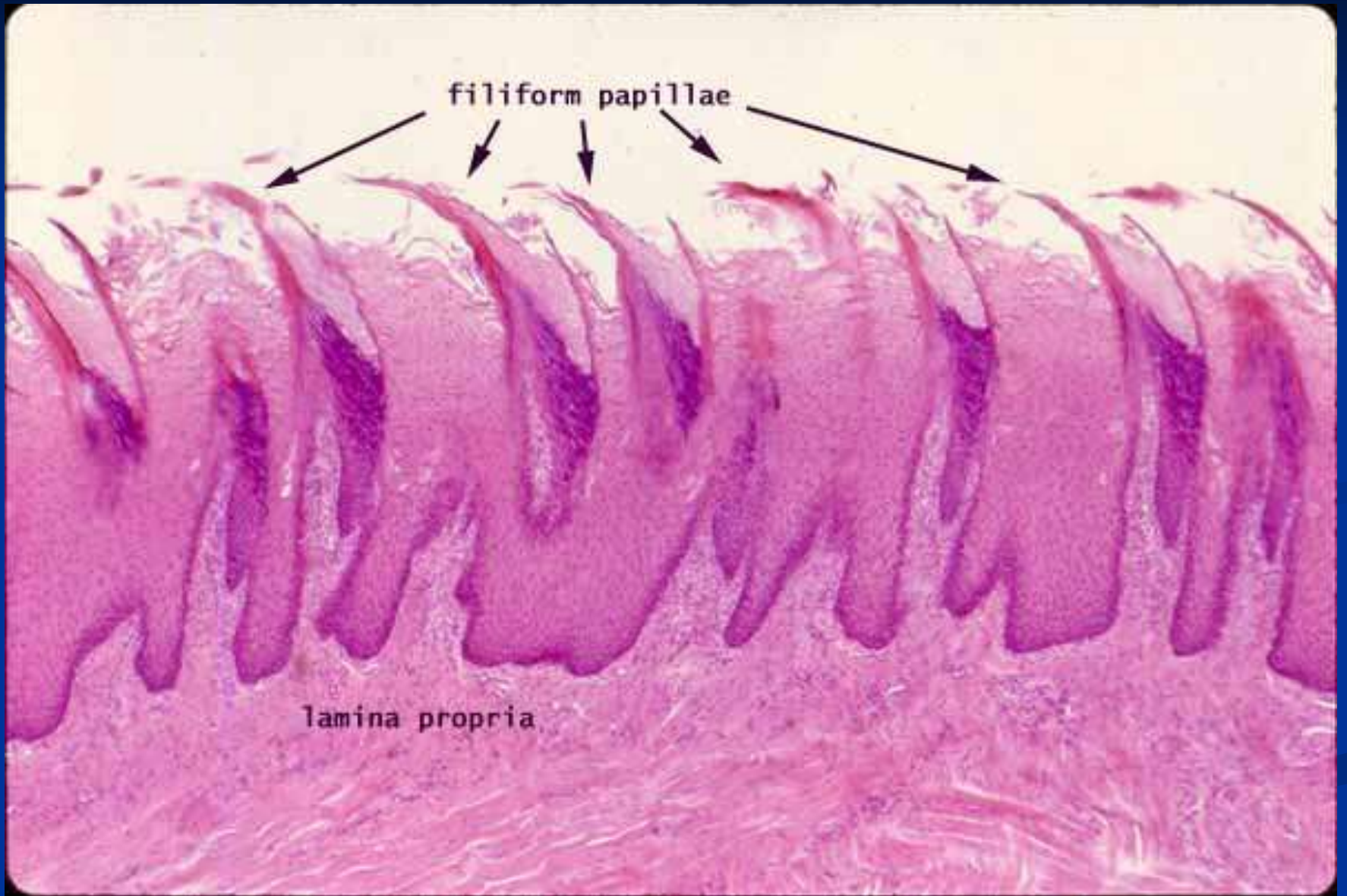
- ANTERIOR 2/3<sup>RD</sup>--- TRIGEMINAL NERVE
- POST 1/3<sup>RD</sup>--- GLOSSOPHARYNGEAL NERVE
- MUSCLES OF NERVE--- HYPOGLOSSAL NERVE EXCEPT,
- PALATOGLOSSUS MUSCLE--- VAGUS NERVE

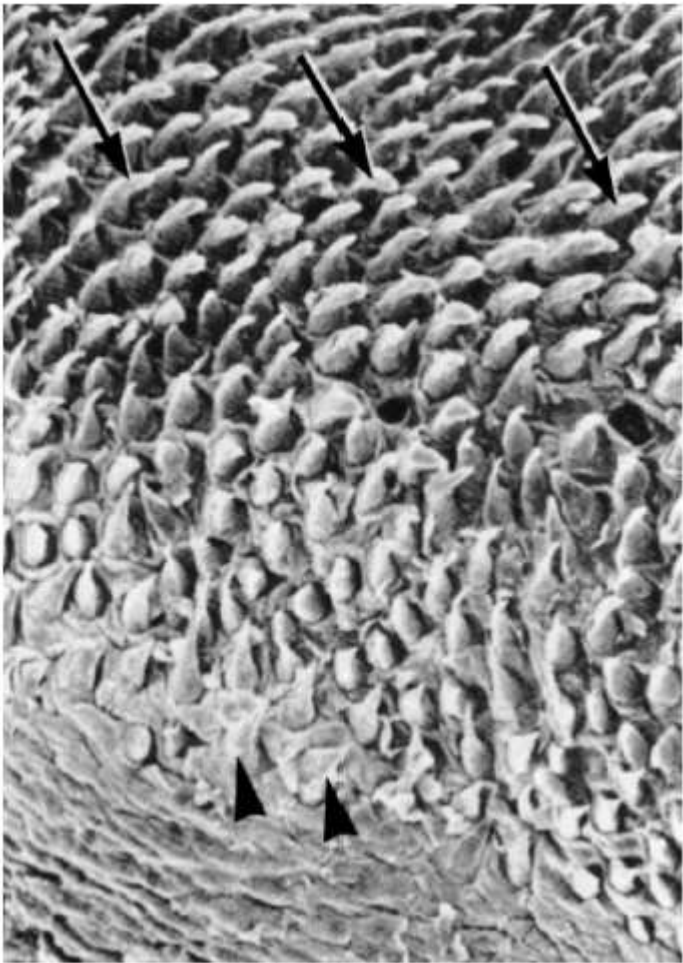# Filiform papilla:

- Makes up majority of the papillae and covers the anterior part of the tongue.
- VELVET Appearance to tongue
- They appear as slender, threadlike **keratinized** projections (~ 2 to 3 mm) of the surface epithelial cells.
- These papillae facilitate mastication (by compressing and breaking food when tongue is apposed to the hard palate) and movement of the food on the surface of the tongue.
- The papillae is directed towards the throat and assist in movement of food towards that direction.
- **NO TASTE BUDS.**

filiform papillae

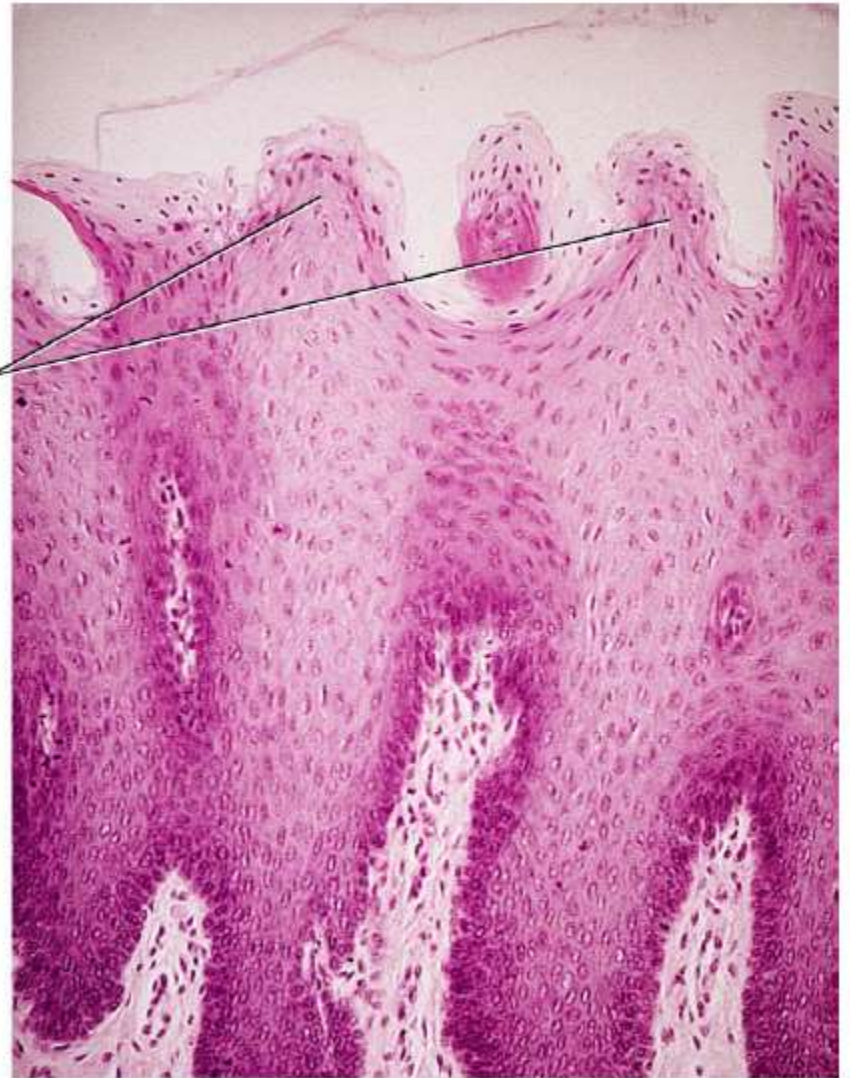lamina propria





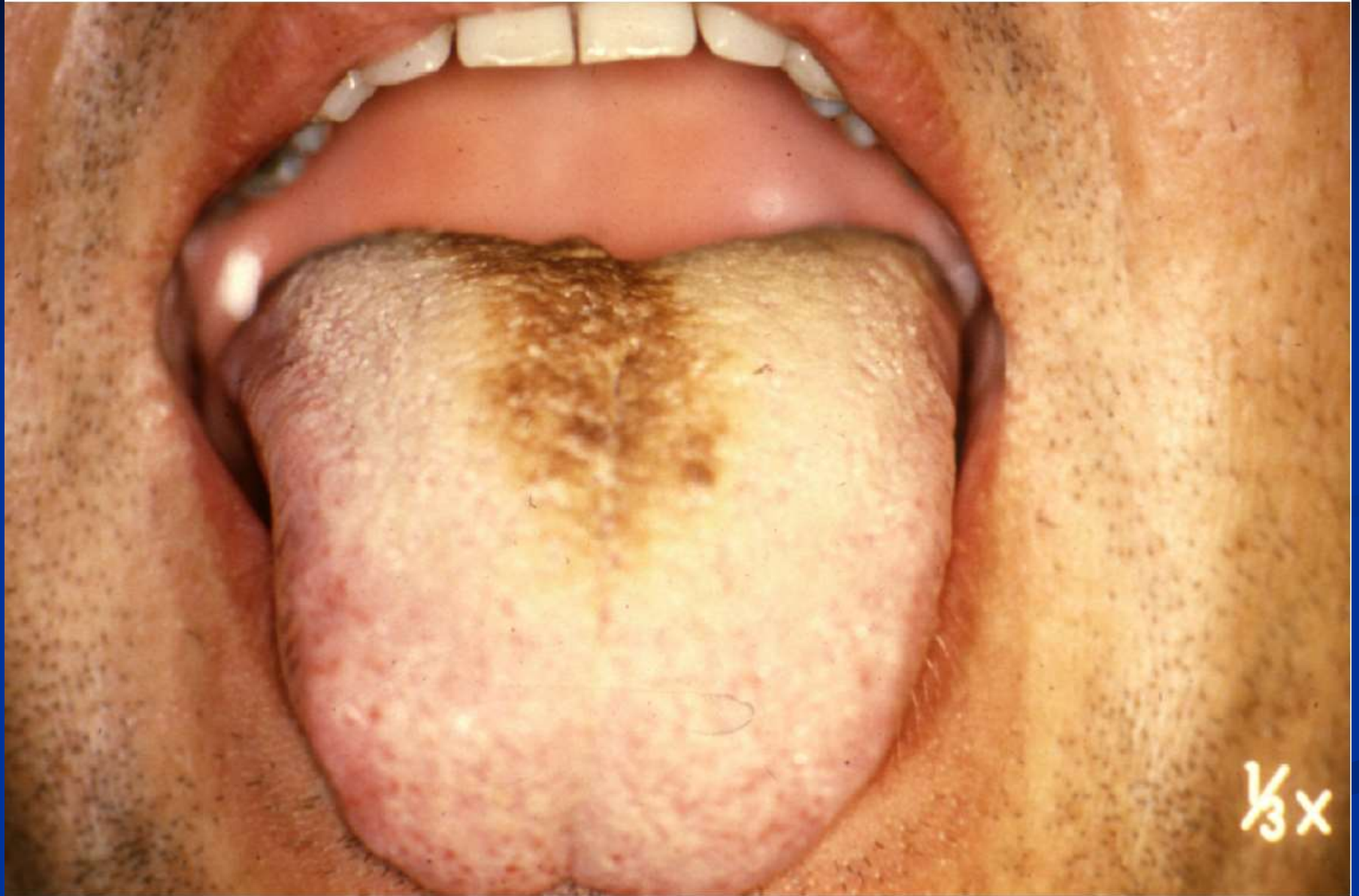Copyright © 2006 by Mosby, Inc.

Filiform papillae



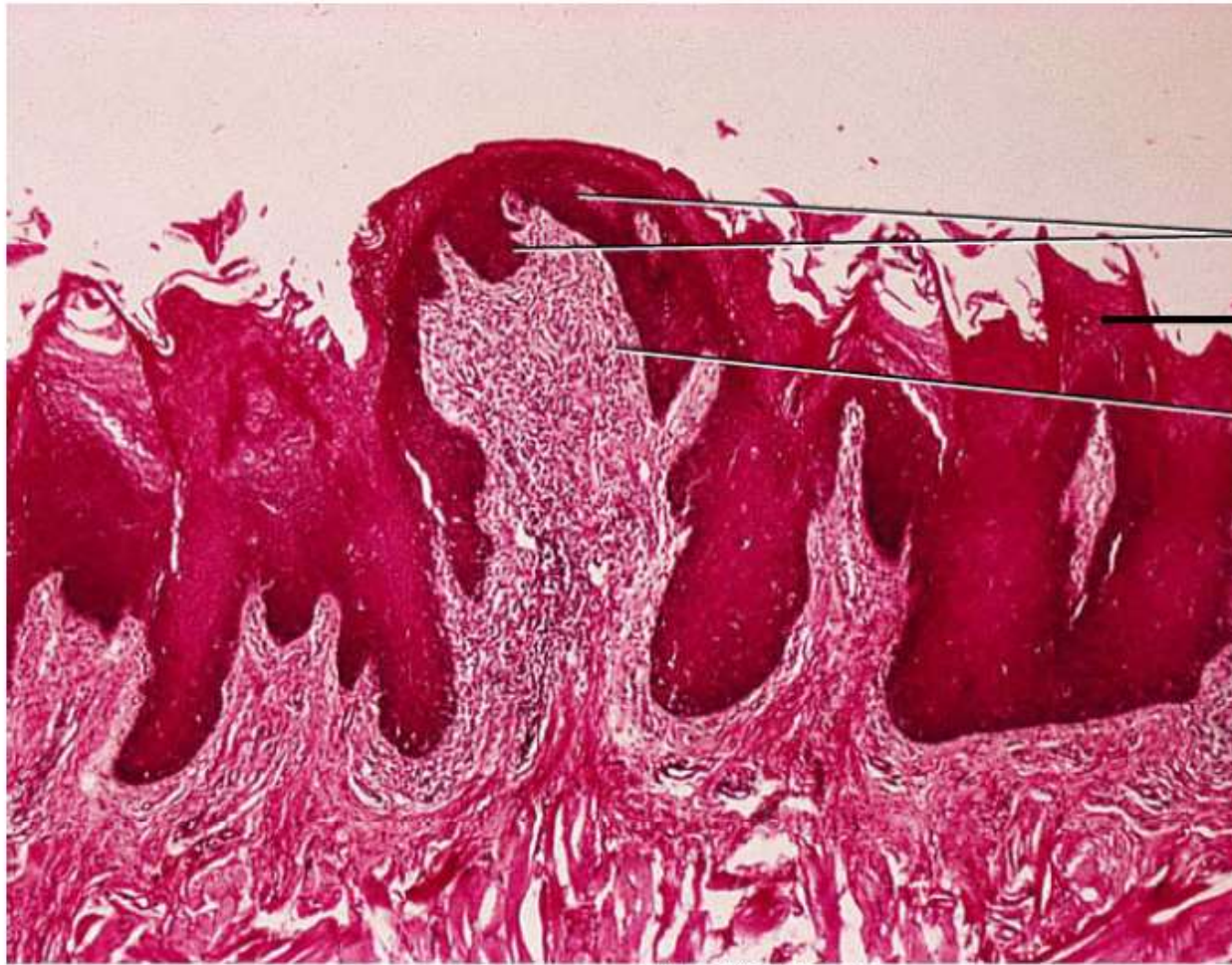Copyright © 2006 by Mosby, Inc.

Hairy Tongue



# Fungiform papilla

- These are interspersed between the filiform papilla.
- More numerous near the tip of the tongue.
- Smooth, round structures that appeared because of their highly vascular connective tissue core
- seen through a thin, nonkeratinized stratified squamous epithelium.
- Taste buds are usually seen within the epithelium.



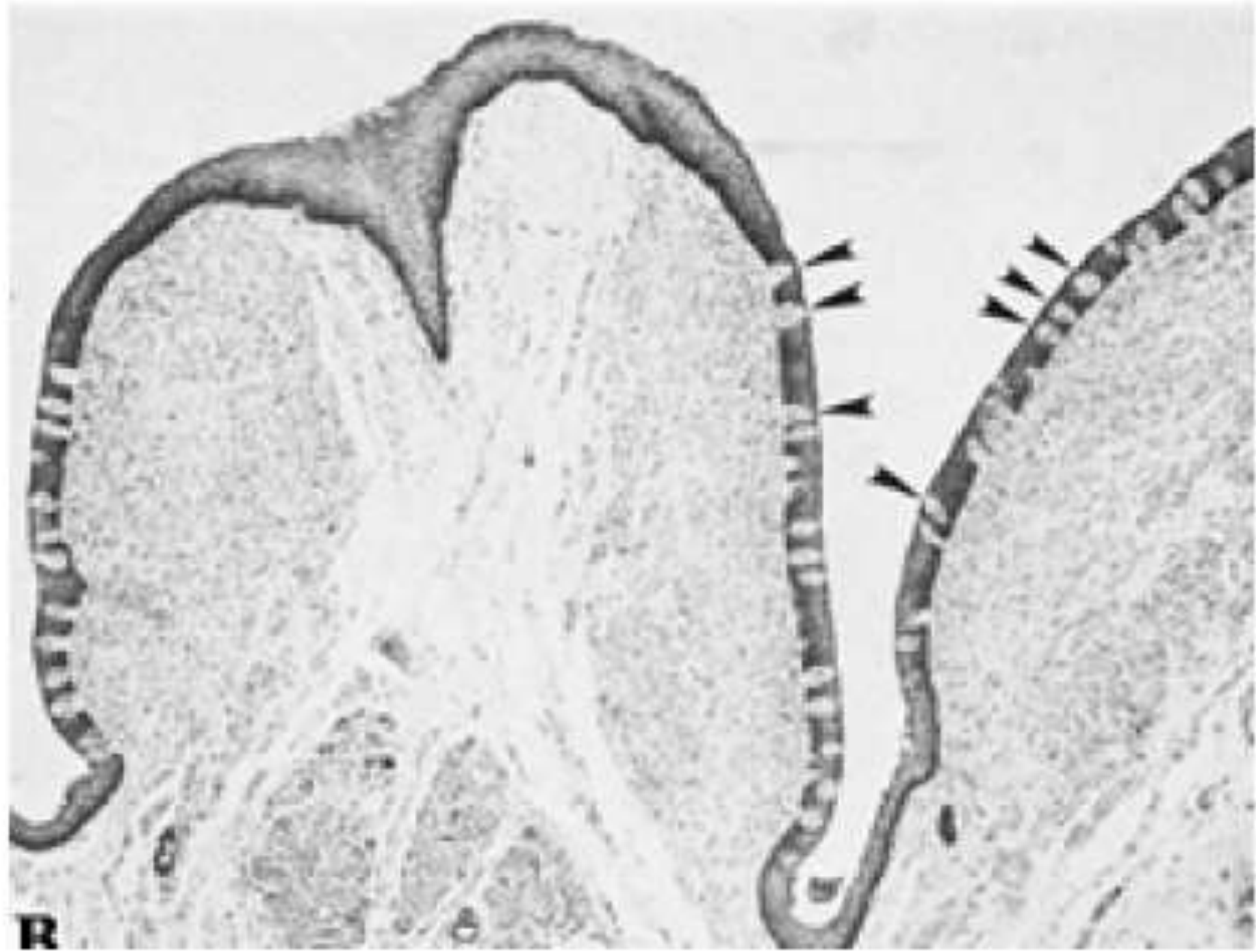
Taste bud

Filiform papilla

Fungiform papilla

# Foliate Papilla

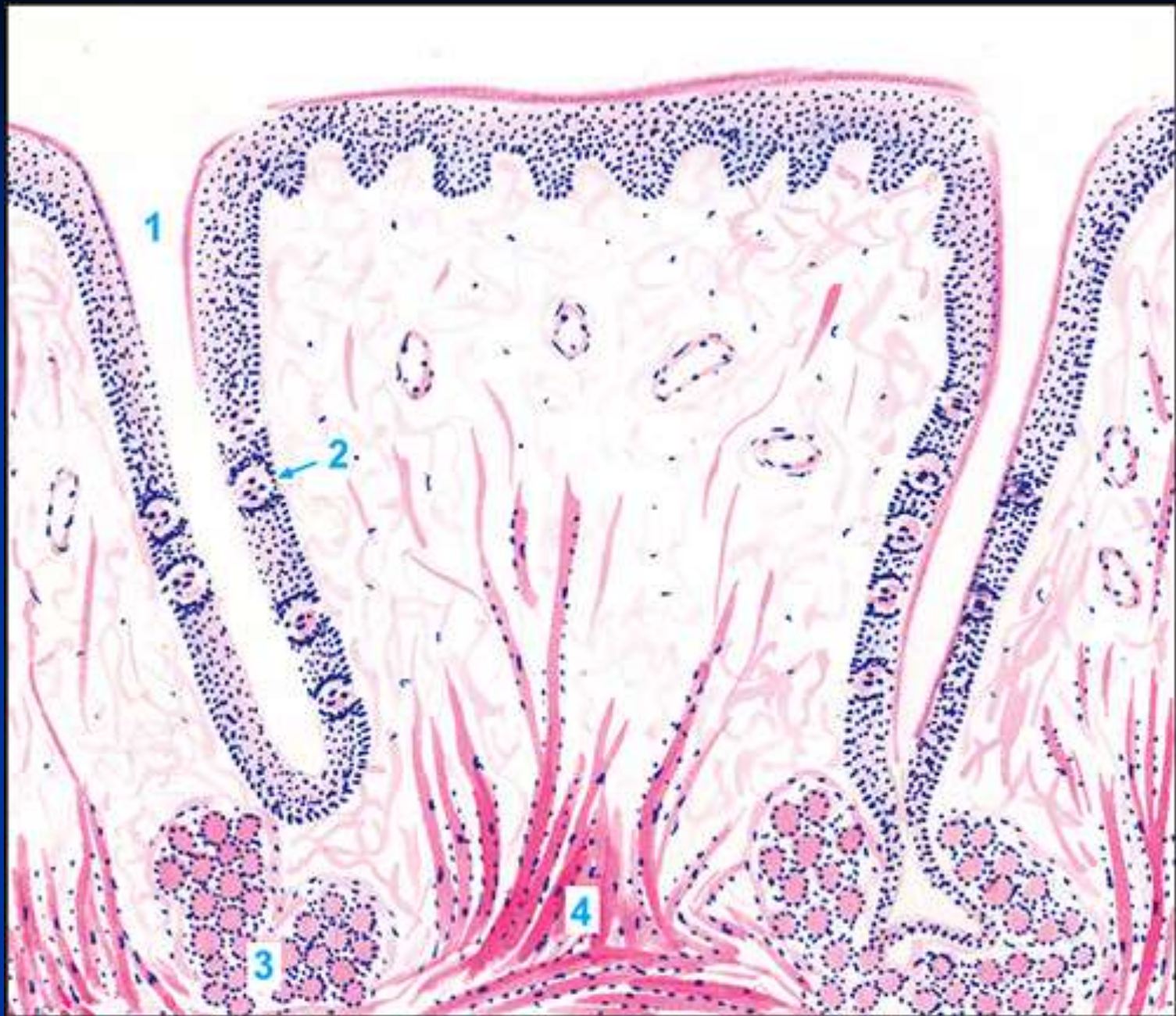- (Leaf-like). Present on the lateral margins of the posterior tongue.
- Consist of 4 to 11 parallel ridges that alternate with deep grooves in the mucosa,
- A few taste buds are present in the epithelium.
- They contain serous glands underlying the taste buds which cleanse the grooves.

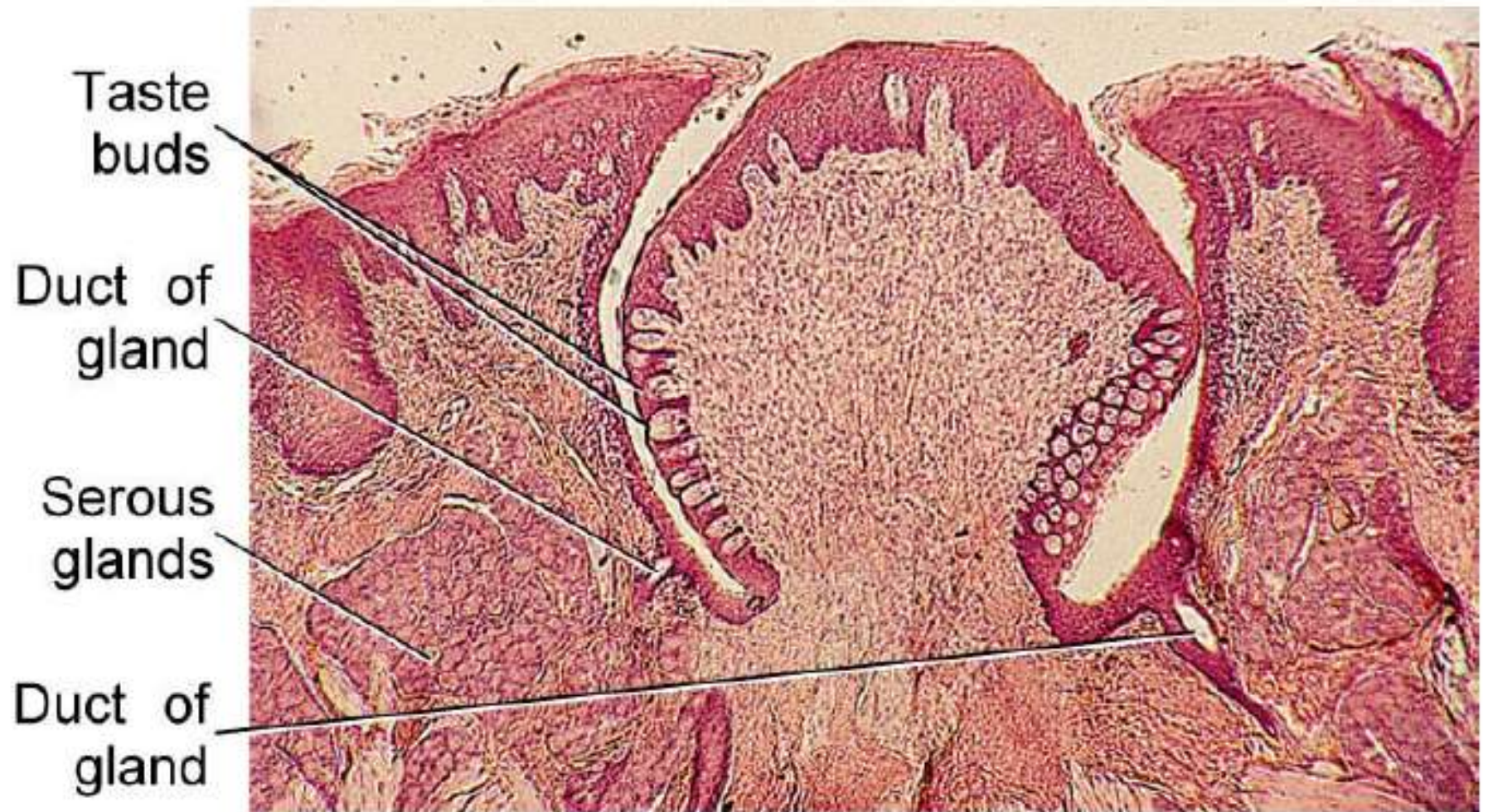

R

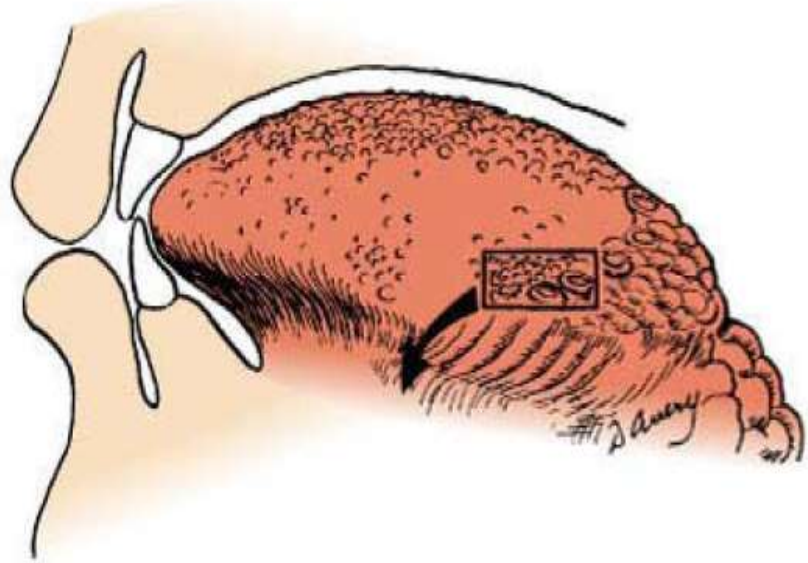
# Circumvallate papilla

- (Walled papilla). 10 to 14 in number these are seen along the V-shaped sulcus between the base and the body of the tongue.
- Large, ~ 3 mm in diameter with a deep surrounding groove.
- Ducts of **Von Ebner glands** (serous salivary glands) open into the grooves.
- Taste buds are seen lining the walls of the papillae.

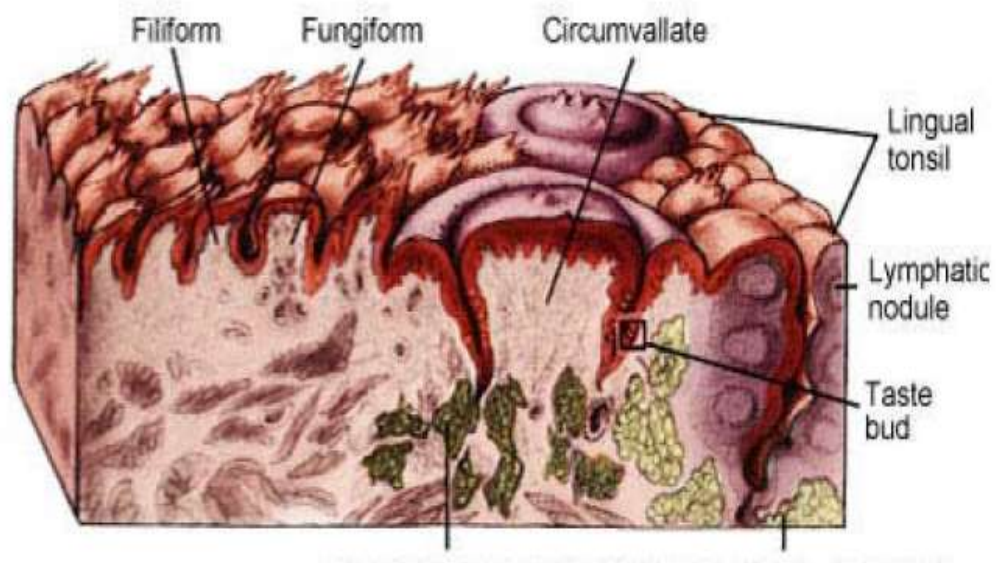




Copyright © 2006 by Mosby, Inc.



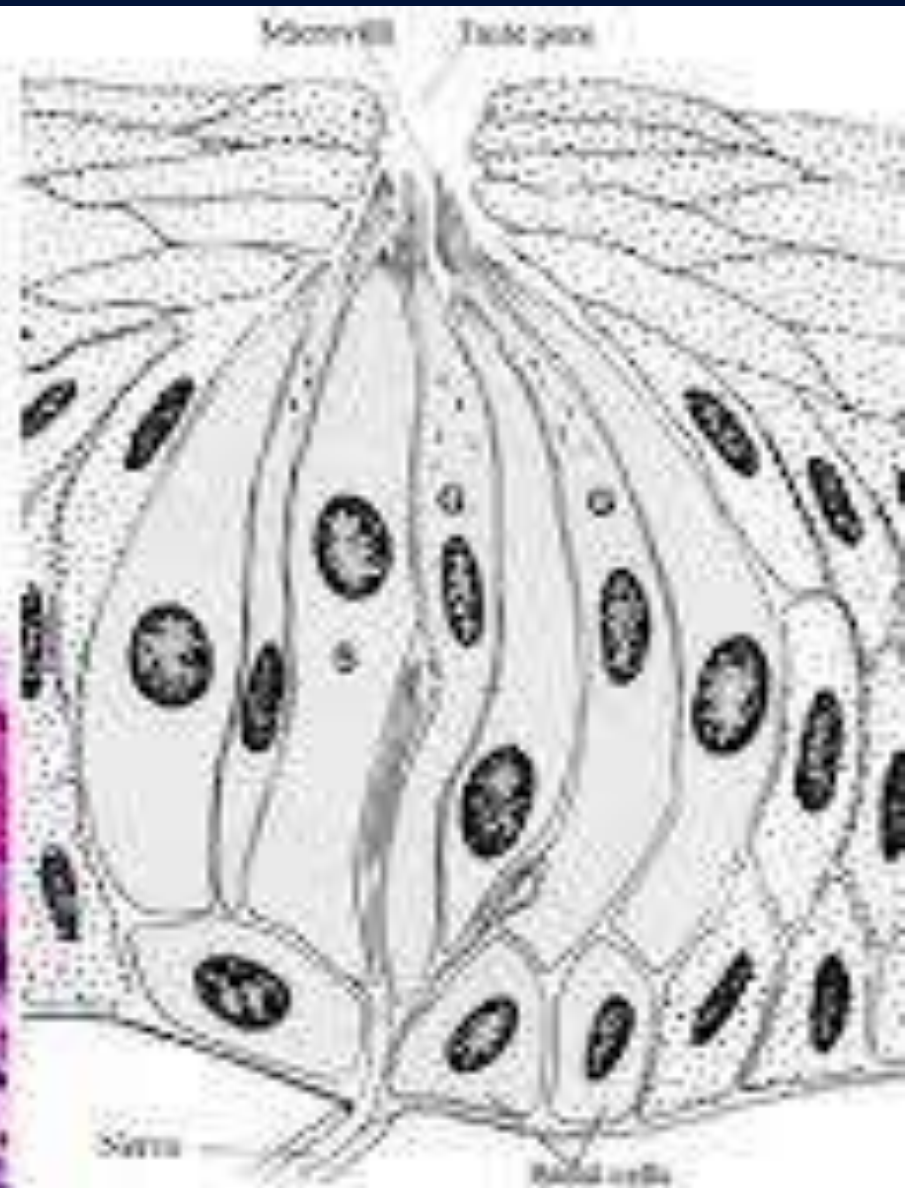
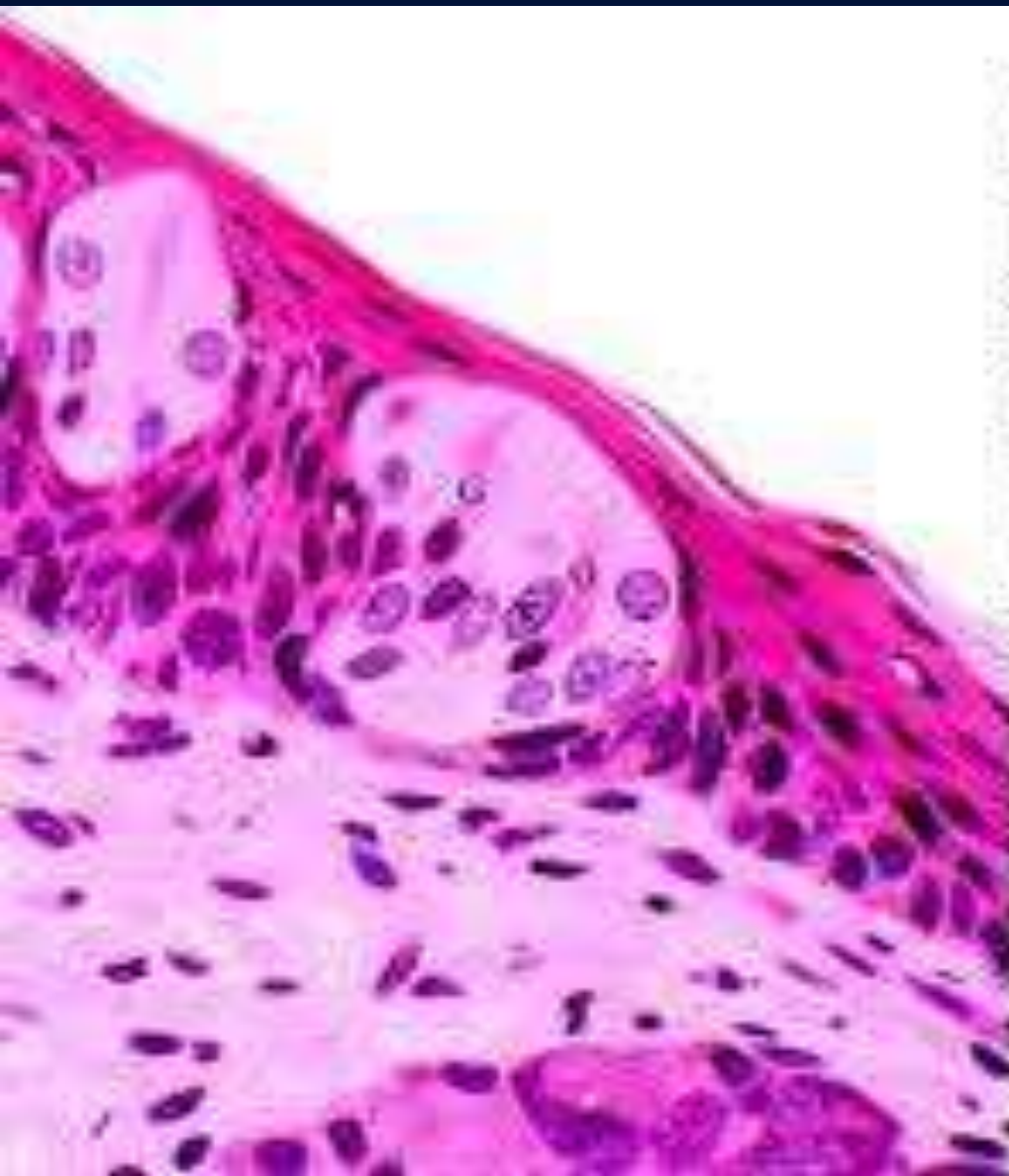A

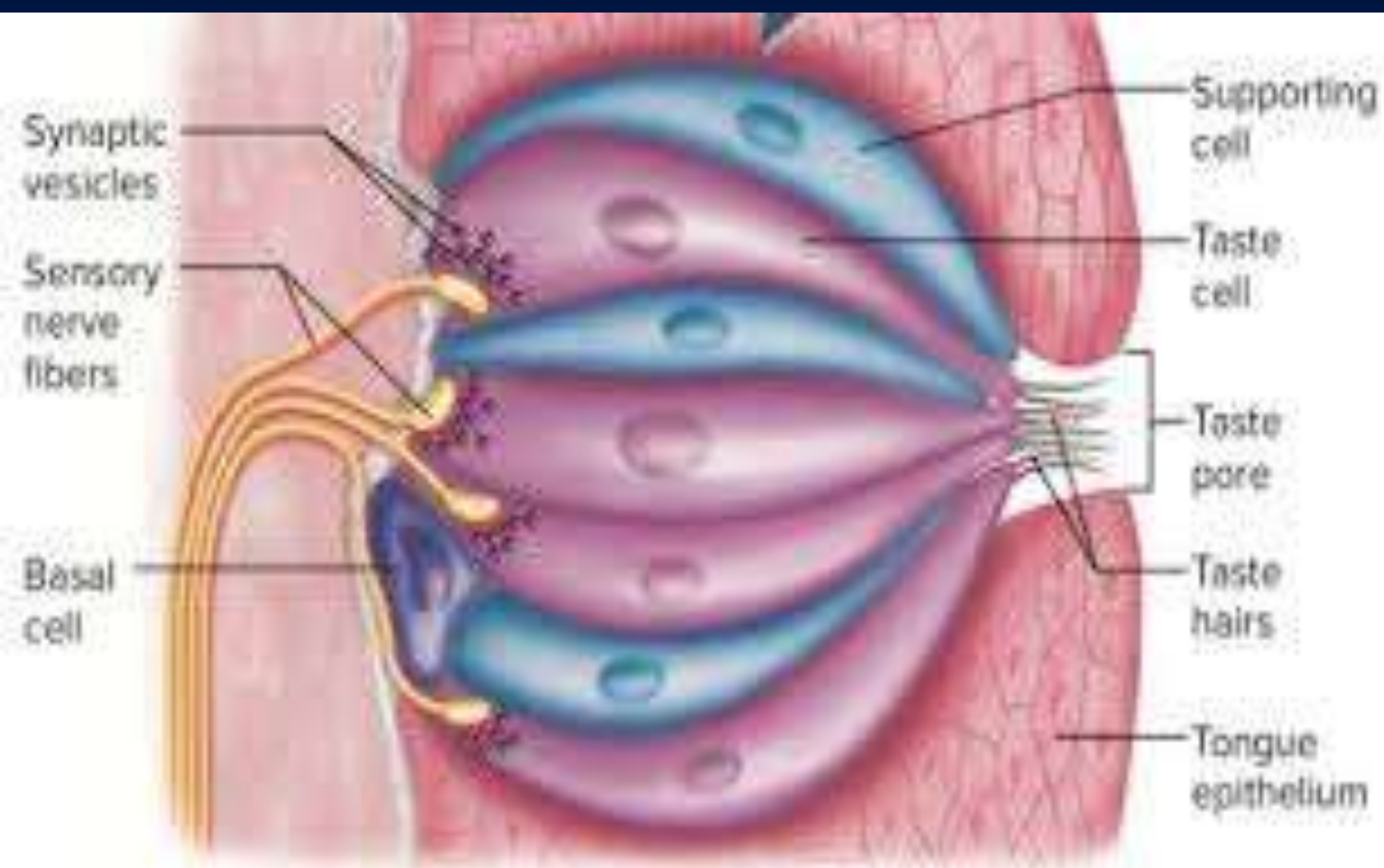


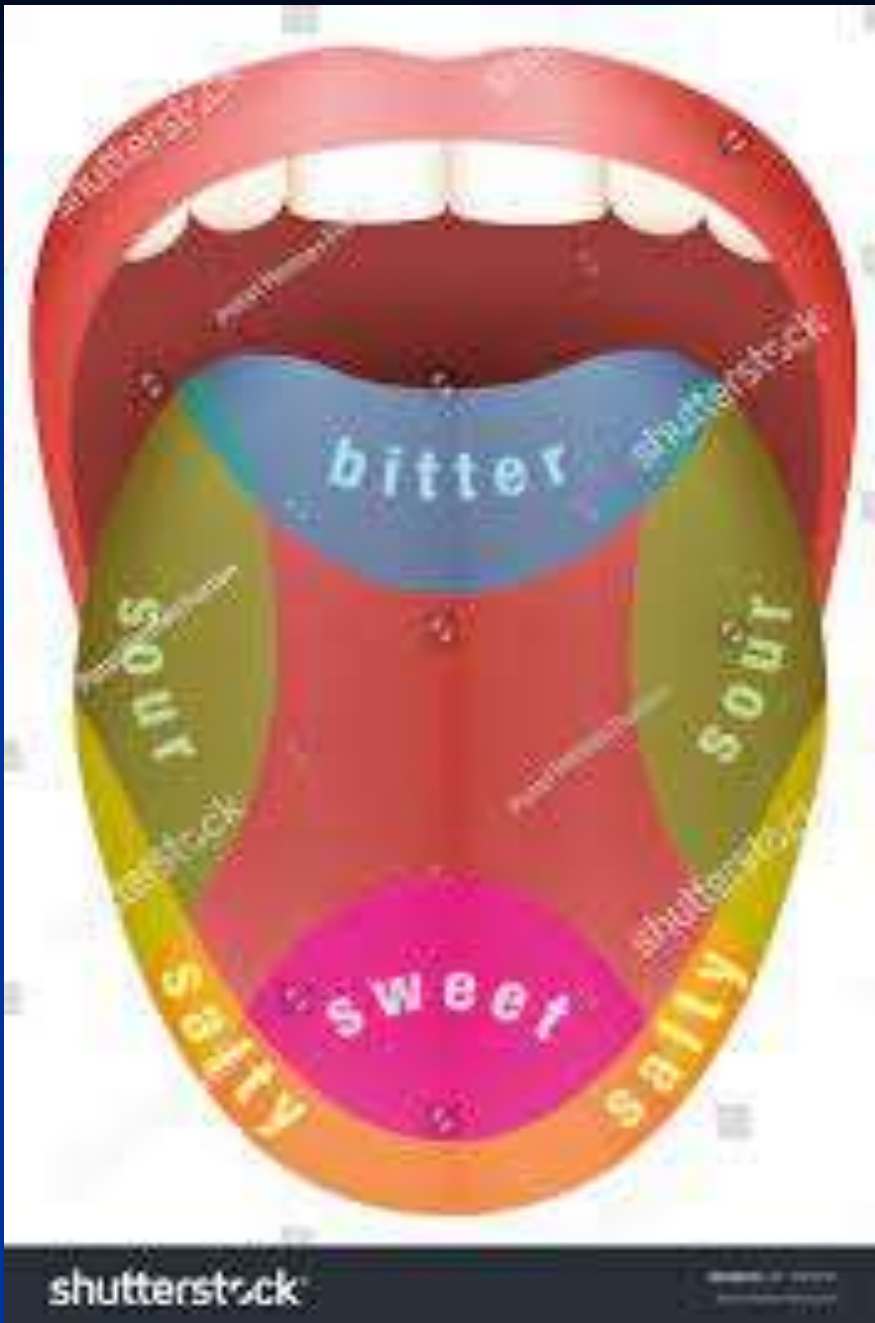
B

# TASTE BUDS

- Small ovoid or Barrel shaped intra-epithelial organ
- 80um high and 40um thick
- Extend from basal lamina till surface
- Seen in:
  - A. Circumvallate papillae
  - B. Folds of foliate papillae
  - C. Post part of epiglottis
  - D. Fungiform papillae







- SWEET- TIP
- SALTY- LATERAL BORDER
- BITTER- POSTERIOR MIDLINE
- SOUR- POSTERIOR LATERAL

# Structure of Mucosa in different regions

Region	Covering epithelium	Lamina propria	submucosa
<b>Lining mucosa</b>			
Labial & buccal mucosa	Very thick-nonkeratinized	Long slender papillae; dense fibrous CT, rich vascular supply	Muscle forming firm attachment .Fat, minor salivary glands, sometimes sebaceous glands
Floor of mouth	Very thin-nonkeratinized	Short papillae, extensive vascularity	Loose CT, containg fat and minor salivary glands
Soft palate	Thin-nonkeratinized Taste buds	Thick with numerous short papillae, elastin fibers, highly vascular	Diffuse tissue containing numerous minor salivary glands

# Structure of Mucosa in different regions

Region	Covering epithelium	Lamina propria	submucosa
<b>Lining mucosa</b>			
Lips vermilion zone	Thin orthokeratinized	Numerous narrow papillae	Mucosa firmly attached to muscle, some sebaceous glands, minor salivary glands and fat
Ventral surface of the tongue	Thin nonkeratinized	Thin with numerous short papillae, few minor salivary glands	Thin and irregular, may contain fat and small vessels ;tongue musculature

# Structure of Mucosa in different regions

Region	Covering epithelium	Lamina propria	submucosa
<b>Masticatory mucosa</b>			
Gngiva	Thick parakeratinized/ orthokeratinized	Long nrrarrow papillae(fork like) not highly vascular	No distinct layer- mucoperiosteum
Hard palate	Othokeratinized	Longe thick papailles, dense collagenous tissue	Mucoperiosteum, antlatelalar –fat, Posterolateral-minor salivary glands