



GOOD MORNING

TEMPEROMANDIBULAR JOINT

Contents

- ❖ Introduction to joint
- ❖ Classification of joints
- ❖ Introduction to TMJ
- ❖ Development
- ❖ Anatomy
- ❖ Biomechanics of the TMJ
- ❖ Temporomandibular disorders
- ❖ Conclusion
- ❖ References

INTRODUCTION TO JOINT

- Joint is a junction between two or more bones or cartilages.
- It permits movements, however immovable joints are meant primarily for growth, and may permit moulding during childbirth.
- Joints are more in child than adult because as the growth proceeds some of the bones fuse together e.g.-ilium ischium and pubis to form pelvic bone...

CLASSIFICATION OF JOINTS

Based on structural characteristics

1. fibrous joint

- Sutures
- Syndesmosis
- Gomphosis

2. Cartilagenous joint

- Synchondrosis
- symphysis

3. Synovial joint

- Ball & socket
- Saddle
- Condylar
- Ellipsoid
- Hinge
- Pivot
- plane

❖ Based on functional characteristics

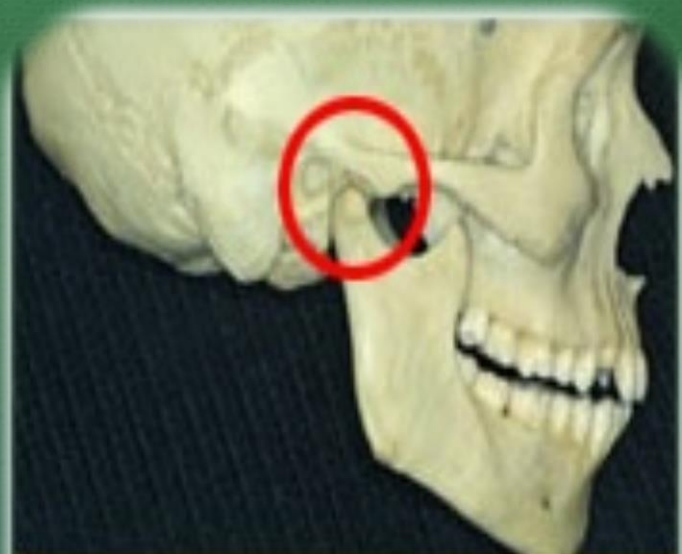- Synarthrosis: immovable , like fibrous joint
- Amphiarthroses: slightly movable, Cartilagenous joints
- Diarthrosis: freely movable, synovial joints

❖ Based on regional characteristics

- Skull type : immovable
- Vertebral type : slightly movable
- Limb type : freely movable

INTRODUCTION TO TMJ

- ❖ Synovial
- ❖ Diarthroidal
- ❖ Ginglymoid
- ❖ Compound joint
- ❖ Also called as



Temporomandibular Joint

'Craniomandibular Articulation'

- ❖ The mammalian craniomandibular articulation is a comparatively modern evolutionary feature; being as recent as 70×10^6 years old.
- ❖ Prior to this, vertebrates had various types of jaw articulations, simplest with Meckel's cartilage articulating indirectly with the otic capsule, which are now in the middle ear.

DEVELOPMENT

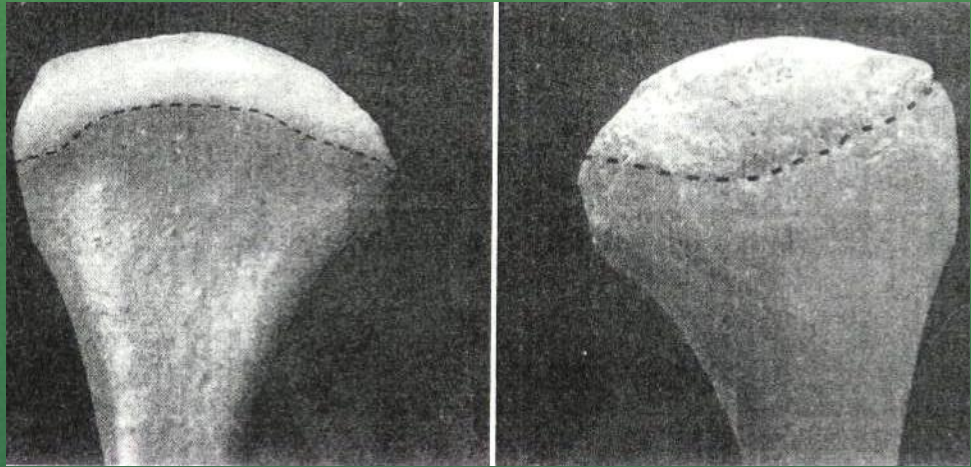
- ❖ TMJ begins to develop by 10th week of gestation period from two separate blastemas (mesenchymal condensation)-
 - i) for the Temporal bone component.
 - ii) for the Condyle.
- ❖ The Temporal & Condylar mesenchymal cells differentiate into Osteoblasts, which lay down the membrane Bone.
- ❖ Soft x-ray analysis of TMJ region from 12 to 32 weeks of gestation period reveals high degree of calcification in condylar head.

- ❖ Superior to condylar blastema, a band of mesenchymal cells develops that differentiate into the Disc.
- ❖ In the center of the condyle a Cartilage develops the Secondary Cartilage which remains in the condyle upto 27 year of age.
- ❖ Secondary cartilage contributes to Subendochondral bone growth, which causes enlargement of the condyle in adulthood as a part of adaptive changes in response to overloading.

❖ The developing disc continues anteriorly with the developing Lateral Pterygoid muscle & posteriorly by a ligament with the superior end of the Meckel's cartilage.

ANATOMY

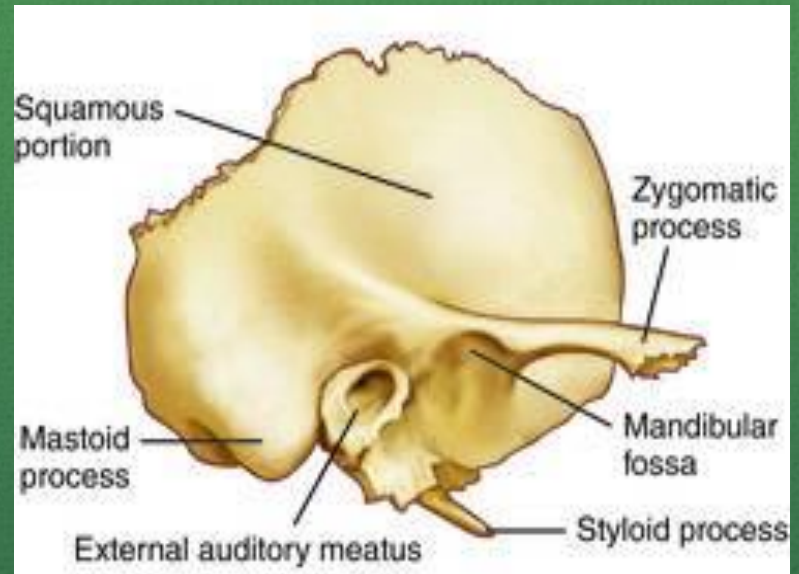
- ❖ Technically, it is compound joint which by definition requires the presence of at least 3 bones.
- ❖ Although composed of only two bones the mandible and the temporal, this requirement can be satisfied by considering the articular disc as a non-ossified 3rd bone.



Condyle

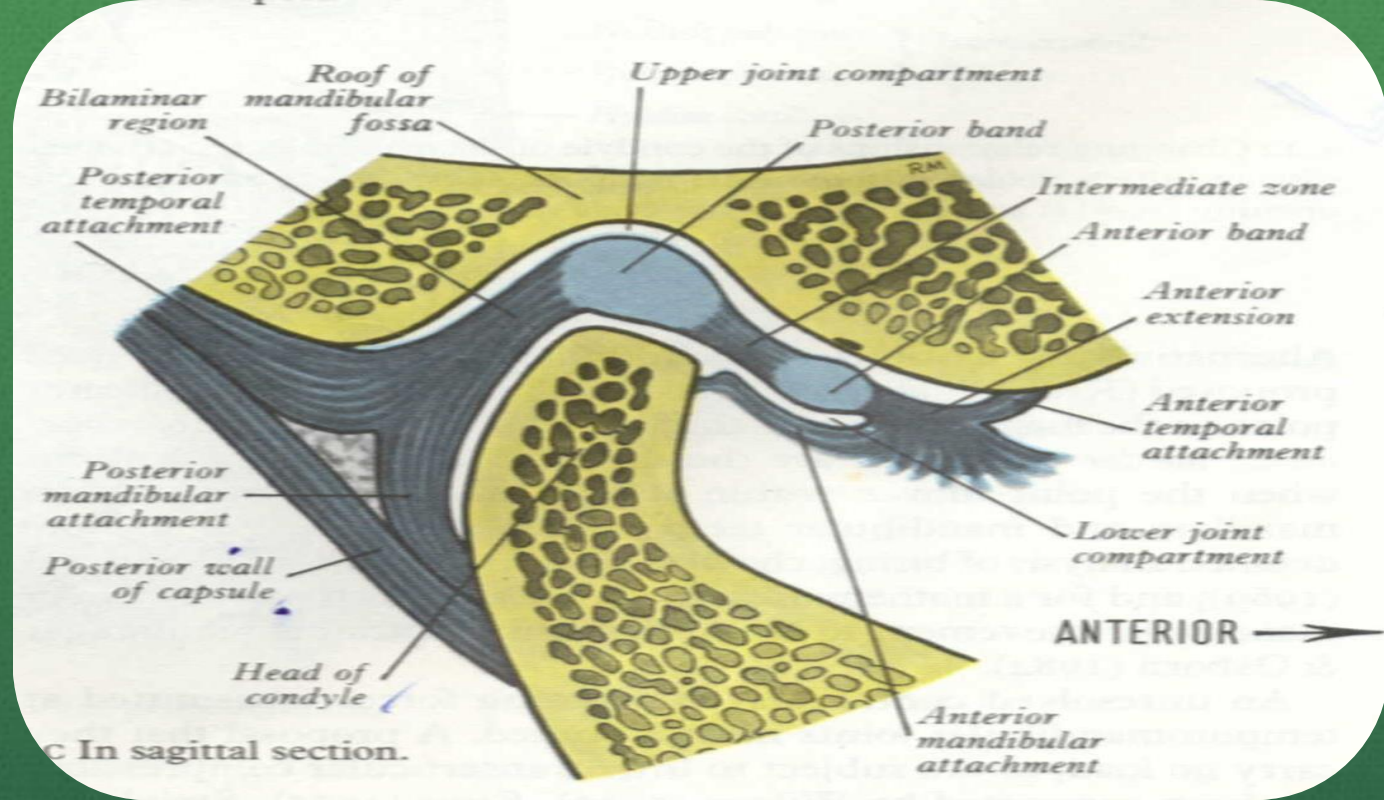
- ❖ The portion of the mandible that articulates with the cranium around which movements occurs.
- ❖ **Anterior view:** It has medial and lateral projection called poles.
- ❖ Medial pole is generally more prominent than the lateral.

Temporal bone



- ❖ The squamous portion of the temporal bone is made-up of the concave mandibular fossa also called articular / glenoid fossa.
- ❖ Immediately anterior to the fossa is a convex bony prominence called articular eminence.

- ❖ The steepness or degree of convexity of articular eminence dictates the pathway of the condyle when the mandible is positioned anteriorly.
- ❖ The posterior roof of the mandibular fossa is quite thin (therefore doesn't sustain heavy forces).
- ❖ The articular eminence consist of thick dense bone and can more likely tolerate such forces.



Articular disc

- ❖ Composed of dense fibrous connective tissue devoid of any blood vessels, nerve fibers.
- ❖ Divided into three regions according to thickness. The central area is thinnest (intermediate zone), Posterior border is generally slightly thicker than anterior border.

- ❖ In the normal joint the articular surface of the condyle located in intermediate zone.
- ❖ From anterior view disc is generally thicker medially than laterally.
- ❖ During movement, the disc is flexible and can adapt to the functional demands of the articular surfaces.
- ❖ The disc maintains its morphology unless destructive forces are transferred.

- ❖ If these changes occur the morphology of the disc can be irreversibly altered and a pathologic condition ensues.
- ❖ The contour of the disc with the thick bands helps in preventing displacement of the disc from the condyle during translation.
- ❖ **Function :** divides the joint cavity into two distinct cavities each with a different function; the articular disc creates a double joint one above the other.

❖ Lower joint

❖ Upper joint

- ❖ During functional movement of the mandible, stability within the TMJ is achieved by maintaining the thin intermediate zone of the disc between the condyle and the eminence.
- ❖ The disc also serves as a shock absorber to counteract the many forces acting on the joint during both functional and parafunctional activity (i.e. when the teeth are clenched).

Synovial membrane

- ❖ Surrounding the TMJ, there is a thin fibrous connective tissue capsule that defines the anatomic and functional boundaries of the TMJ.
- ❖ The capsule is attached superiorly to the temporal bone and inferiorly to the neck of the condyle.
- ❖ A synovial membrane that secretes synovial fluid into the joint cavities lines the inner surface of the capsule.

- ❖ It *does not* cover the articular surfaces of the joint or the disc except for its posterior bilaminar region
- ❖ On its lateral wall, the capsule is reinforced by the temporomandibular ligament

Functions of synovial fluid



Lubrication

metabolic
requirements

TMJ ligaments

- ❖ Made up of collagenous connective tissue.
- ❖ Act as passive restraining devices to limit and restrict joint movements.
- ❖ These are....

Functional ligaments

1. Collateral (discal) ligament
2. Temporomandibular ligament

3. Capsular ligament

Accessory ligaments

1. Sphenomandibular ligaments
2. Stylomandibular ligaments



Collateral (discal) ligament

- ❖ Attach the medial and lateral borders of the articular disc to the poles of the condyle, divides the joint mediolaterally into the superior and inferior compartments.

Functions

- ❖ Restrict the movement in the lower joint to hinge or rotary action when viewed in a sagittal plane.
- ❖ Discal ligaments cause the disc to move passively with the condyle in an anterior and posterior direction during condylar translation.
- ❖ They have a vascular supply and are innervated which provides information regarding joint position and movements.

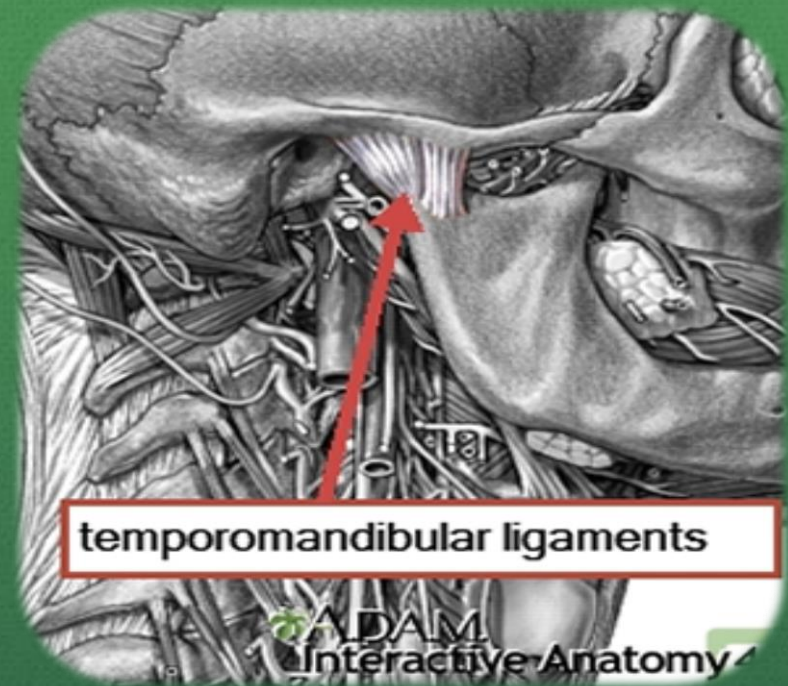
Capsular ligaments



- ❖ Surrounds the entire TMJ.
- ❖ Fibers attached superiorly to the temporal bone along the borders of the articular surfaces i.e. mandibular fossa, articular eminence and inferiorly attaches to the neck of the condyle.

Function

- ❖ Resist any medial, lateral or inferior forces that tend to separate or dislocate the articular surfaces.
- ❖ Retain the synovial fluid by encompassing the entire joint.
- ❖ Well innervated and provides proprioceptive feed back regarding joint position and movements.



Temporomandibular ligament

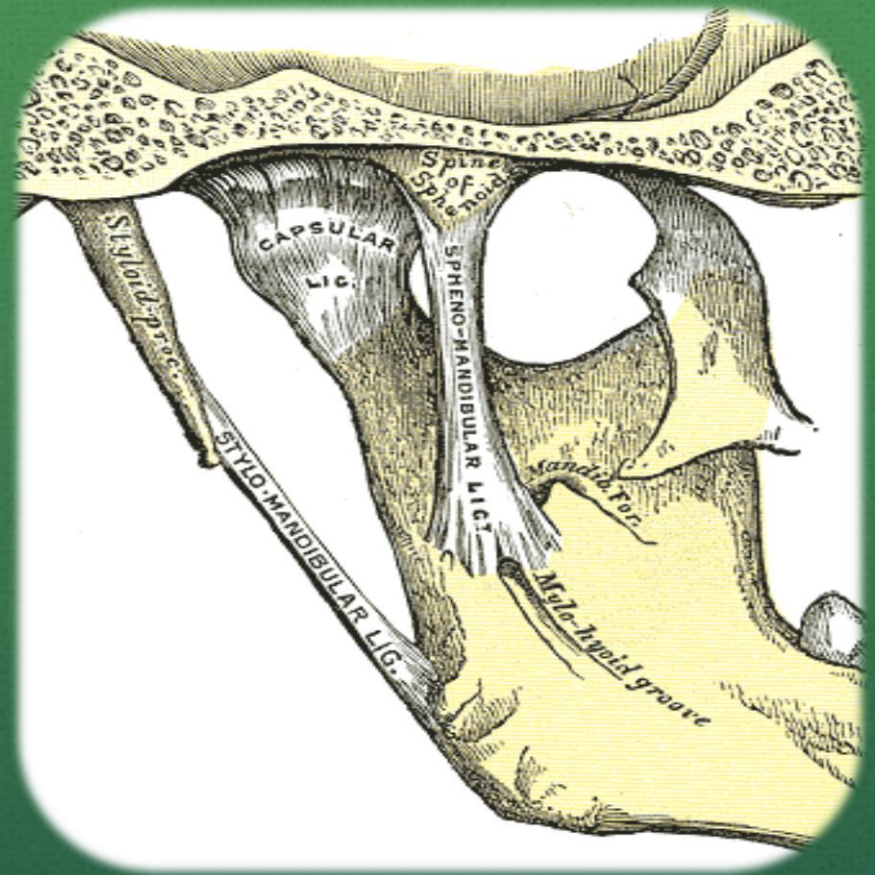
- ❖ Composed of 2 parts, an outer oblique portion and an inner horizontal portions
- ❖ The outer portion extends from the outer surface of the articular tubercle and zygomatic process posteroinferiorly to the outer surface of the condylar neck.

- ❖ The inner horizontal portion extends from the outer surface of the articular tubercle and zygomatic process posteriorly and horizontally to the lateral pole of the condyle and posterior part of the articular disc.

Functions

- ❖ Outer oblique portion - resists excessive dropping of the condyle and therefore acts to limit the extent of mouth opening.
- ❖ It limits rotational opening movement of the mandible.

- ❖ The inner portion limits posterior movement of the condyle and disc.
- ❖ Also protects the lateral pterygoid muscle from overlengthening or extrusion.

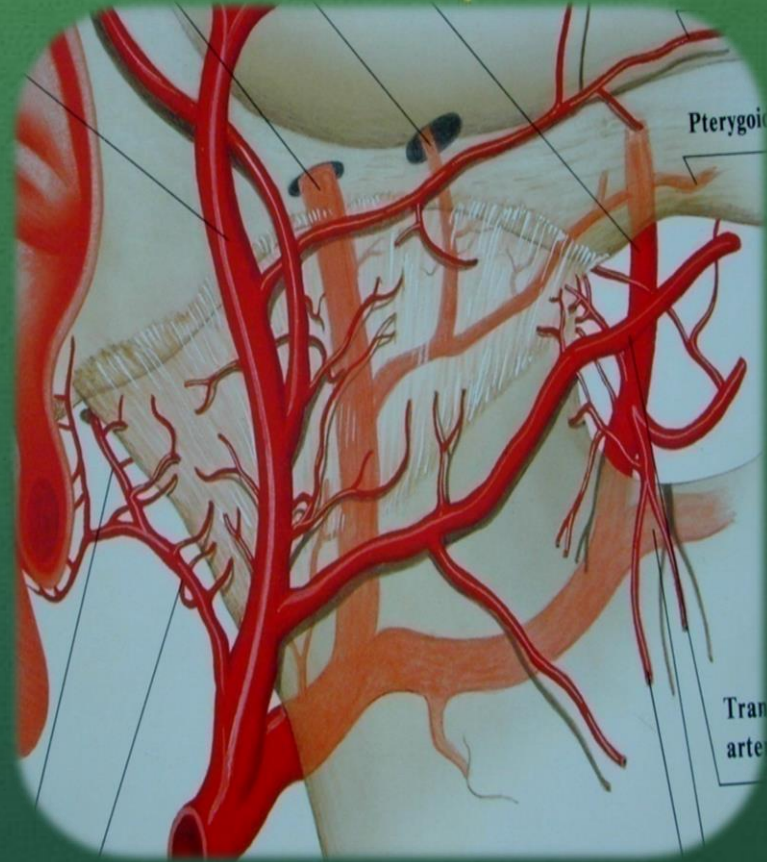


Accessory ligament

- ❖ They become tight when the mandible is protruded and thus limits the excessive protrusive movements of the mandible.

Vascular supply

- ❖ Superficial temporal artery from the posterior.
- ❖ Middle meningeal artery from the anterior.
- ❖ Internal maxillary artery from the inferior.
- ❖ Other arteries are deep auricular, Anterior tympanic, Ascending pharyngeal.



Nerve supply

❖ Most of the innervation is by the **auriculotemporal nerve** as it leaves the mandibular nerve behind the joint and ascends laterally and superior to wrap around the posterior region of the joint.

❖ **deep temporal and masseteric nerve**

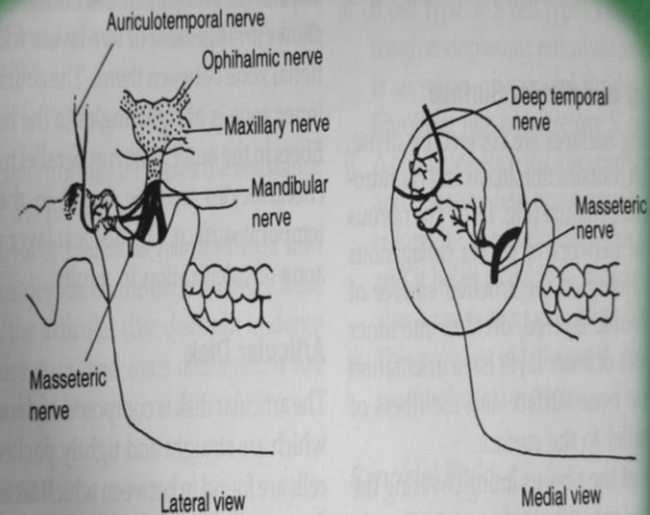


Fig. 13.4: Nerve supply to temporomandibular joint

Lymphatic Drainage

- ❖ Anterior surface drains into PAROTID lymph nodes.
- ❖ Posterior and medial surface drain into SUBMANDIBULAR lymph nodes.
- ❖ Lateral surface drains into PREAURICULAR and PAROTID lymph nodes.

Biomechanics of the TMJ

- ❖ Within the TMJ 2 types of movements can be isolated
 - 1) Rotational or hinge movement between the disc and condyle in the lower compartment.
 - 2) Sliding movement or translation in the upper compartment between the superior surface of the disc and the articular eminence.

What are TMDs?

- ❖ TMD is a collective term describing problems that affect masticatory muscles and TMJ and associating structures or both...term was coined by Bell.
- ❖ Conditions producing abnormal, incomplete or impaired function of the TMJ.(GPT-8)
- ❖ Other terms
 - costen syndrome, temporomandibular joint dysfunction, functional temporomandibular joint disturbance, occlusomandibular disturbance

CLASSIFICATION

- I. Temporomandibular joint disorders
 1. Deviation in form
 - Articular surface defects
 - Disc thinning and perforations
 2. Disc displacement with or without reduction
 3. Displacement of disc condyle complex
 - subluxation
 - Dislocation
 4. Inflammatory conditions
 - Capsulitis and synovitis
 - Retrodiscitis

5. Degenerative diseases

- Osteoarthritis
- Polyarthrititis
- Ankylosis - fibrous and bony

II. Masticatory muscle disorders

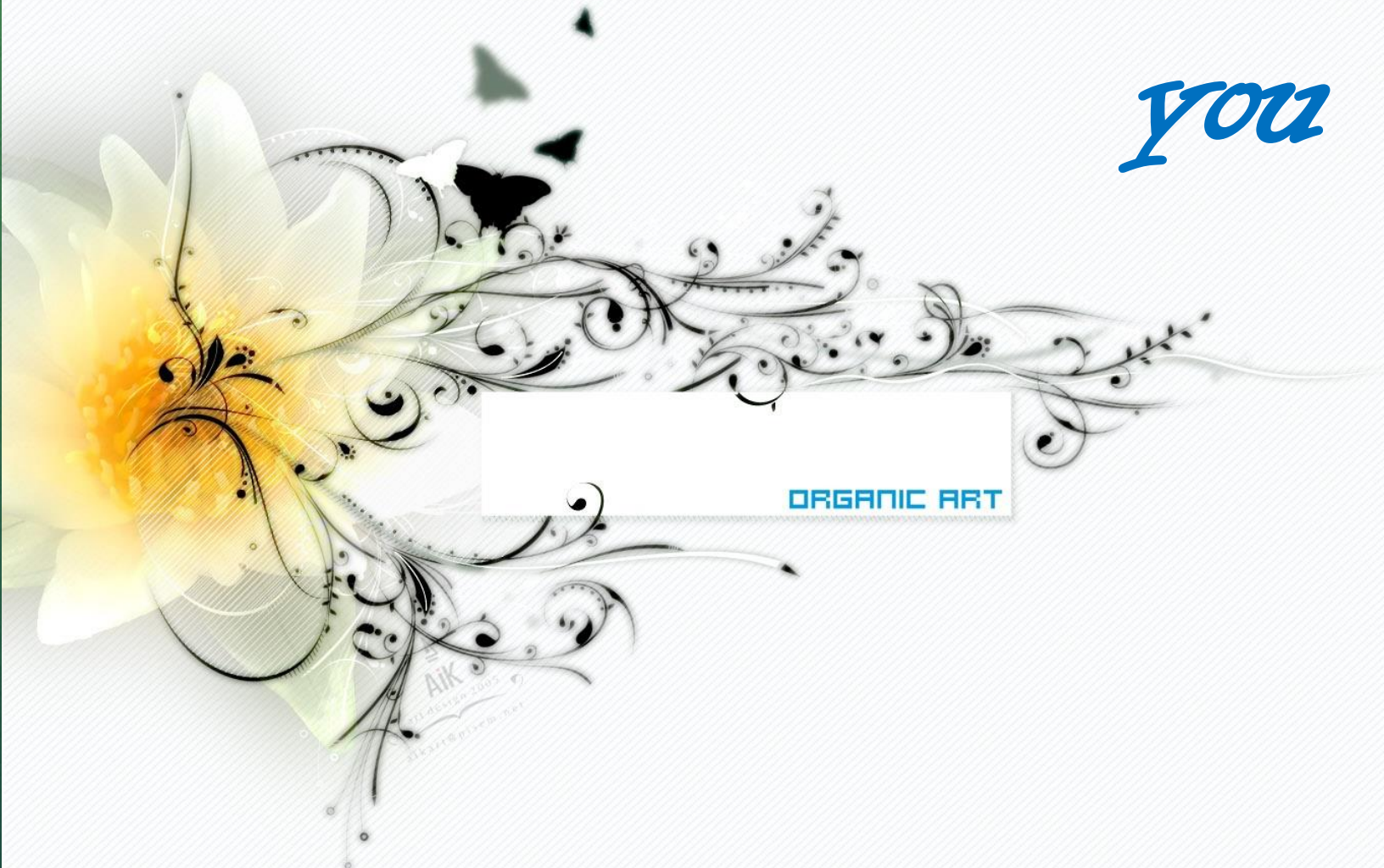- Acute
 - Myositis
 - Reflex muscle splinting
 - Muscle spasm
- Chronic
 - Myofascial pain
 - Muscle contracture
 - Hypertrophy
 - Myalgia secondary, to systemic disease

III. Congenital and developmental disorders

- Condylar hyperplasia/ hypoplasia
- Aplasia
- Condylolysis
- Neoplasms
- Fracture

Thank

you



ORGANIC ART

AIK
2014 DESIGN 2005
alex@piscu.net