



# D.Y.PATIL DENTAL SCHOOL

DEPARTMENT OF PUBLIC HEALTH DENTISTRY

# ATRAUMATIC RESTORATIVE TREATMENT



# DEFINITION

- ▶ Atraumatic restorative treatment (ART), also known as Alternative restorative treatment, is defined as “a dental caries treatment procedure involving the removal of soft, demineralized tooth tissue using hand instrument alone, followed by restoration of the tooth with an adhesive restorative material, routinely glass ionomer”.

# PRINCIPLES

- ▶ • Removing carious tooth tissues using hand instruments only.
- ▶ • Restoring the cavity with a restorative material that sticks to the tooth.

# REASONS OF USING HAND INSTRUMENTS FOR ART

- ▶ 1. It makes restorative care accessible for all population groups.
- ▶ 2. The use of a biological approach, which requires minimal cavity preparation that conserves sound tooth tissues and causes less trauma to the teeth.
- ▶ 3. The low cost of hand instruments compared to electrically driven dental equipment.
- ▶ 4. The limitation of pain that reduces the need for local anesthesia to a minimum and reduces psychological trauma to patients.
- ▶ 5. Simplified infection control. Hand instruments can easily be cleaned and sterilized after every patient.

# MATERIAL USED

Glass ionomer cement is used as the restorative material in

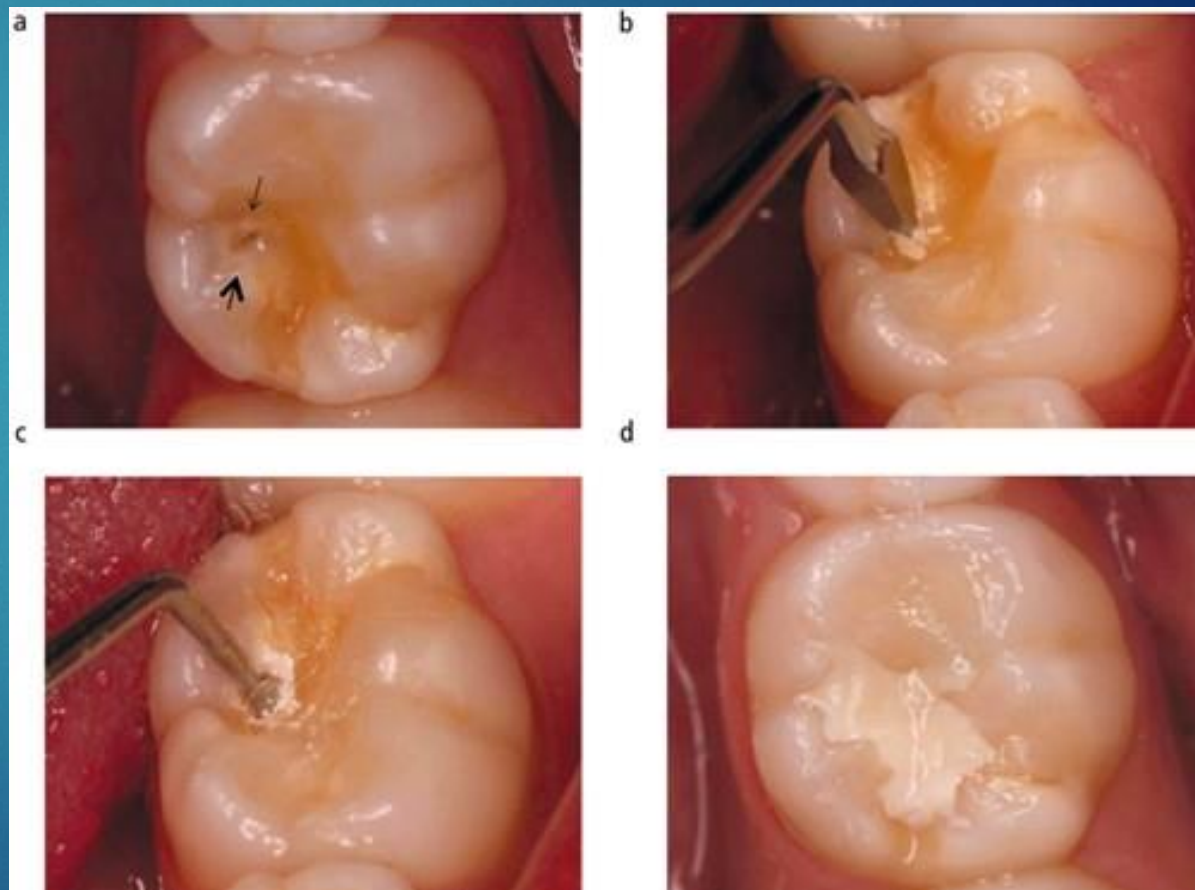
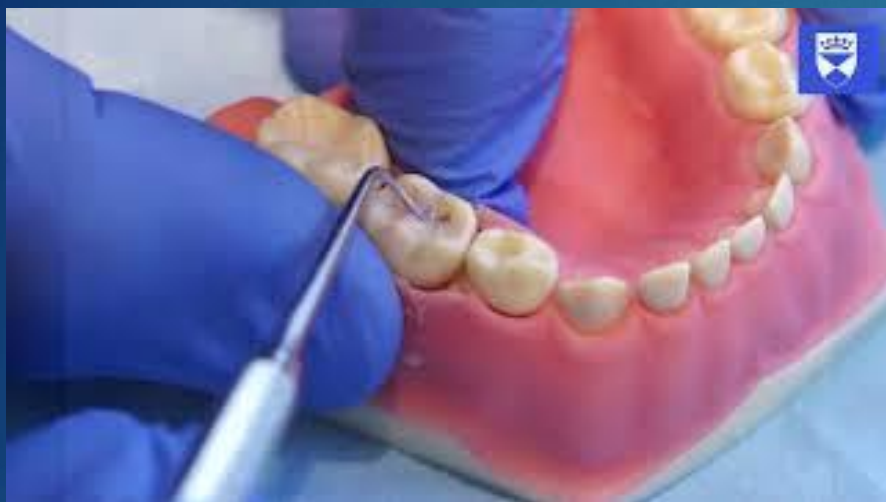ART.

## ▶ INSTRUMENTS

- ▶ • Mouth mirror
- ▶ • Explorer
- ▶ • Pair of tweezers
- ▶ • Dental hatchet
- ▶ • Spoon excavator, small
- ▶ • Spoon excavator, medium
- ▶ • Spoon excavator, large
- ▶ • Applier/carver
- ▶ • Glass slab or paper mixing pad
- ▶ • Plastic spatula

# RESTORING CAVITIES USING ART

- ▶ 1. Place cotton wool rolls alongside the tooth to be treated.
- ▶ 2. Remove plaque from tooth surface with wet cotton wool pellets.
- ▶ 3. Dry the tooth surface with dry cotton wool pellets.
- ▶ 4. If necessary, make the entrance of the cavity wider with a dental hatchet.
- ▶ 5. Remove the carious dentine (Fig. 34.1) with excavators starting at the enamel-dentine junction.
- ▶ 6. Fracture of unsupported thin enamel with the hatchet.
- ▶ 7. Clean the cavity with wet and then dry cotton wool pellets.
- ▶ 8. Remove the caries near the pulp carefully.
- ▶ 9. Clean the cavity again with wet cotton wool pellets.
- ▶ 10. Check the relation of the tooth to be restored with the opposing teeth by asking the patient to bite.
- ▶ 11. Complete the procedu



# ADVANTAGES

- ▶ 1. The use of easily available and relatively inexpensive hand instruments rather than expensive electrically driven dental equipment.
- ▶ 2. A biologically friendly approach involving the removal of only decalcified tooth tissues, which results in relatively small cavities and conserves sound tooth tissue.
- ▶ 3. The limitation of pain, thereby minimizing the need for local anesthesia.
- ▶ 4. A straightforward and simple infection control practice without the need to use sequentially autoclaved handpieces.
- ▶ 5. The chemical adhesion of glass ionomers that reduces the need to cut sound tooth tissue for retention of the restorative material.
- ▶ 6. The leaching of fluoride from glass ionomers, which prevents secondary caries development and probably remineralizes carious dentine.
- ▶ 7. The combination of a preventive and curative treatment in one procedure.
- ▶ 8. The ease of repairing defects in the restoration; and
- ▶ 9. Low cost.

# LIMITATIONS

- ▶ 1. Long-term survival rates for glass ionomer ART restorations and sealants are not yet available; the longest study reported so far is of three years duration.
- ▶ 2. The technique's acceptance by oral health care personnel is not yet assured.
- ▶ 3. The possibility exists for hand fatigue from the use of hand instruments over long periods.
- ▶ 4. Hand mixing might produce a relatively unstandardized mix of glass ionomer, varying among operators and different geographical/climatic situations.