

D Y PATIL DENTAL SCHOOL

DEPARTMENT OF
PUBLIC HEALTH DENTISTRY

Cultural Taboos In Dentistry

Taboos

Taboos: -

It is a social or religious custom which prohibits or puts restriction on particular thing or person

Reasons for tooth mutilations:

- Tribal identifications
- Sign of manhood or bravery.
- Differentiation of sexes.
- Sign of marriageable age in females.
- Form of punishment
- Aesthetics and fashion
- Local superstition associated with phenomenon such as rain.
- Therapeutic purposes.

Mutilation of teeth & other soft tissues

<i>1. Mutilation of teeth involves practices such as</i>	<i>2) Mutilation of soft tissues</i>
1. Non-therapeutic tooth extraction (avulsion)	1) Tattooing
2. Breaking of tooth crowns.	2) Piercing of lips & perioral soft tissues & insertion of materials such as wood, ivory or metal.
Alteration in shape :-Chipping & filling	3) Temporary piercing of or orofacial soft tissues for ceremonial purposes.
Alteration in appearance :-Dental inlay Lacquering & dyeing	

Tooth Avulsion

Reasons:-

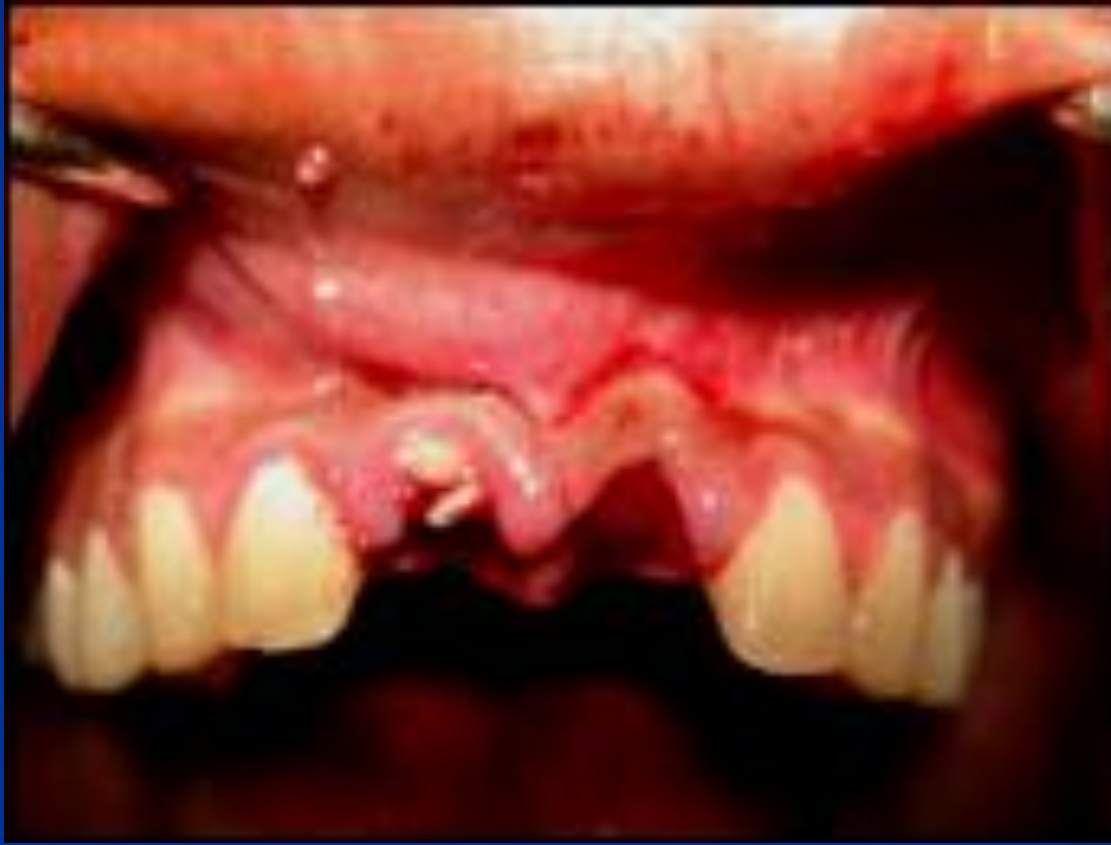- Ritual tooth avulsion
- Religious & spiritual reasons

Age & sex distribution

- Infancy or childhood.
- Puberty
- Adulthood

Tooth Avulsion

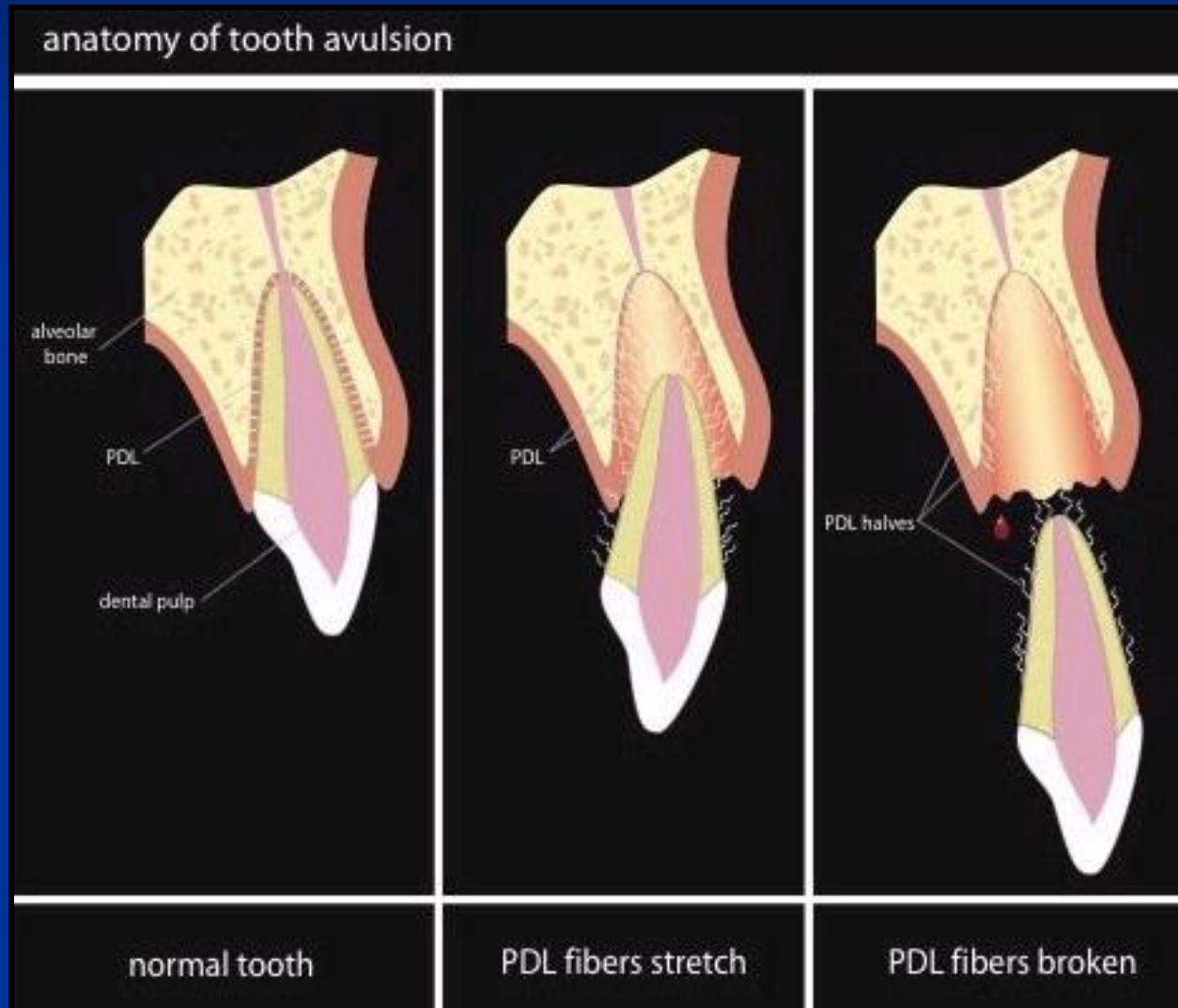
It is purposeful removal of a tooth.



Methods of tooth avulsion

- Teeth are knocked out rather than extracted.
- This is carried out by placing a piece of wood or metal against the crown & then striking the end with some form of mallet.
- Tooth may be completely removed or loosened to allow removal using fingers.
- Pain relieving or anesthetic measures are not routinely prescribed .
- Operation causes considerable suffering & mental anguish for the patients.
- Following tooth avulsion, attempts to control post-operative hemorrhage may be employed.

Mechanism of tooth avulsion



COMPLICATIONS



Complications following tooth avulsion

Complications include:

- Alveolar bone fracture
- Damage to mucosal tissues
- Fracture of tooth crown leaving the tooth root in site
- Wound sepsis
- Hemorrhage
- Extensive soft tissue laceration.

Fate of Avulsed teeth

- great care is some times taken to dispose of avulsed teeth in appropriate manner.
- the avulsed teeth fragments are placed in a piece of meat.
- embedding of avulsed teeth in bark of a tree
- burying of teeth beside water pool.
- Throwing the extracted teeth into water.

Mutilations of the Tooth Crown

Altering the shape of teeth

Chipping & Filling

Reasons:-

- Aesthetics
- Tribal identity
- Religious motives

■ Tribal women with Chipped & filled teeth



Methods of chipping and filling

- Operations producing deformations generally involve a process of chipping away enamel & dentine with some form of chisel and mallet until desired shape is achieved.
- the chipped teeth may be left as they are or subjected to a secondary process of smoothing using file or abrasive stone.

Complications of tooth chipping & filling.

Initial Complications :-

- Includes, severe pain,
- unintended tooth fracture
- Pulp exposure
- Laceration of oral soft tissues

Delayed complications includes:-

- Pulp necrosis
- Inflammatory periapical pathology
- Sequelae of periapical pathology
- Tooth loss.
- Caries

Lacquering & Dyeing of Teeth

Reasons:-

- Blackening of tooth was primarily used to signify faithfulness in marriage.
- Concepts of beauty & Sexual Appeal or Maturity.
- In Vietnam, Tooth lacquering is used for Cosmetic purposes.
- Some people blacken their teeth to help prevent tooth decay.

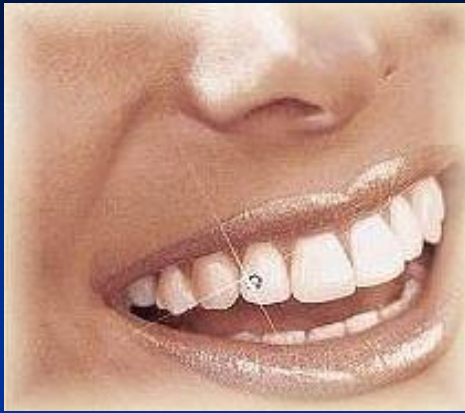Blackening of teeth



Methods

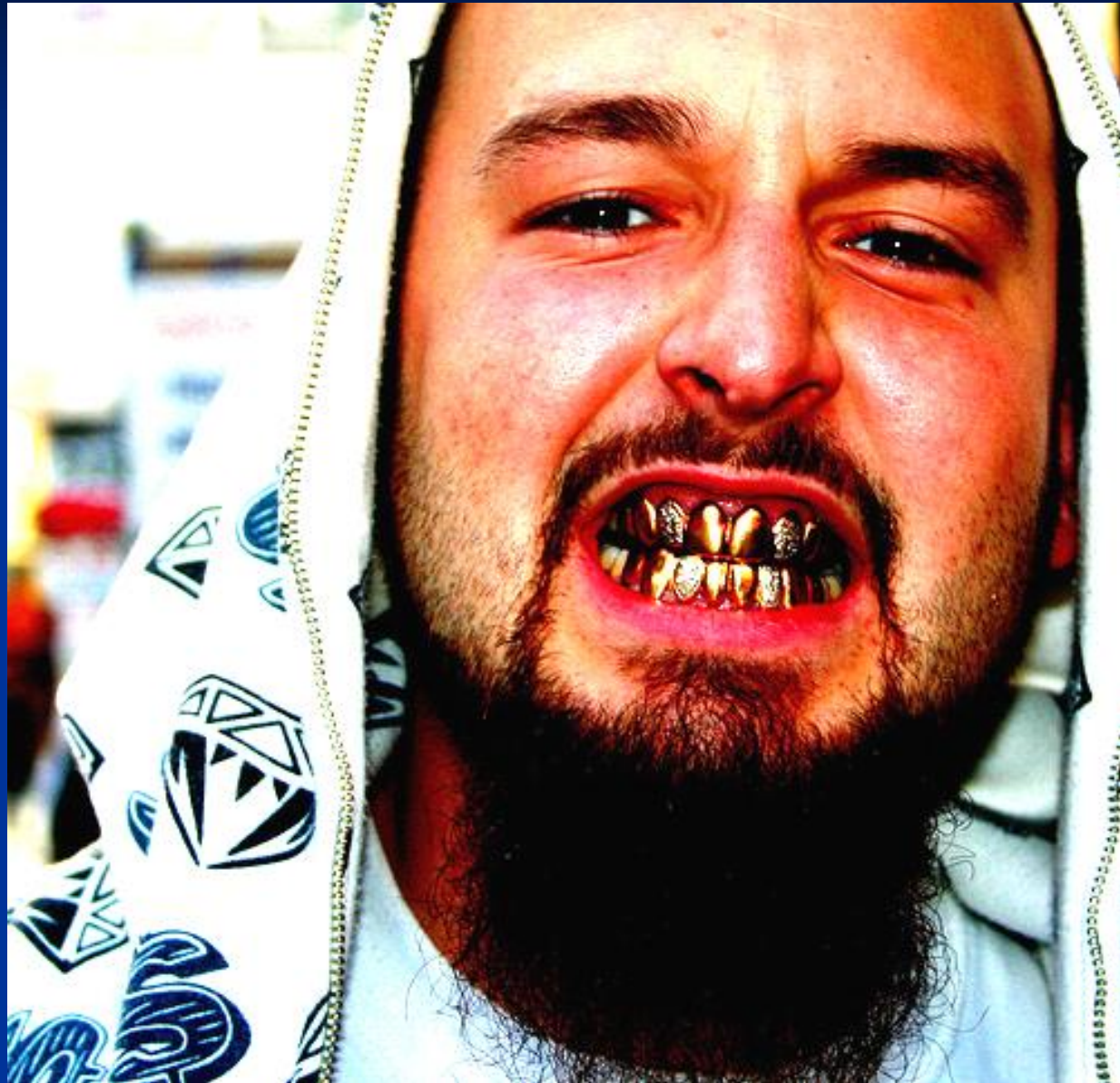- Staining of tooth is usually accomplished by (chewing the leaves or bark of specific plant species)
- Lacquering involved the etching of enamel for two days using lemon juice followed by application of black paints, ginger & mango

Decorative Dental Inlays & Crowns



- Purposes of beautifications, to signify wealth or to signify some event.
- Inlay materials used are hematite, jade, pyrite, turquoise, obsidian & gold.
- Among muslims the presence of a gold crown (Cap) on a front tooth is used to signify that the wearer has visited “Mecca” the spiritual centre of religion.

Visitor to Mecca



Mutilations of soft tissues

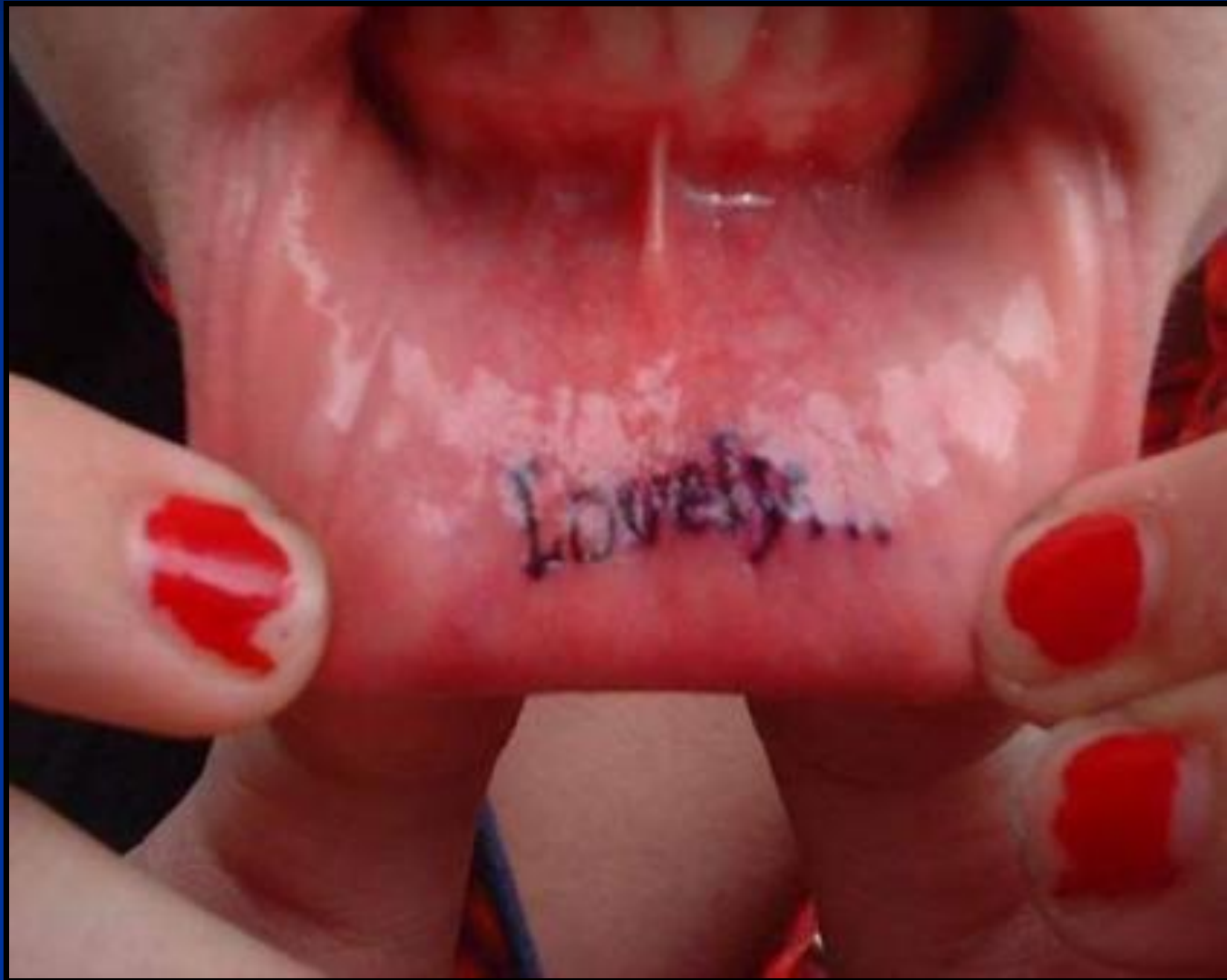■ *Tattooing*

■ Reasons :-

■ Fashion

■ Customs :- e.g. Gingival & Lip
tattooing

Lip tattoo



Technique

- The technique involves painting the gingiva or lip with a layer of pigmented material usually carbon which is then impregnated into the mucosa by means of sharp thorns or needles which pierce the mucosa.
- A blue black coloration is the usual hue achieved with tattoos.
- Material used to tattoo may be obtained from calcified peanuts, burned wood or from lamp black.
- Among some tribes, tattooed lower lip in woman signifies that woman is married.

Piercing of Soft tissues

- Practiced by :- Both urban & rural people
- URBAN PIERCING
 1. Tongue
 2. Lip
 3. Face
- RURAL PIERCING
 1. Lip Plating

Lip Plating



Piercing for Ceremonial Purpose

- Festival :- Thaipusam festival
- Celebrated in :- Tamilnadu, Thailand, Singapore.
- Method :-

Long Steel rods are pierced through the skin of devotees. No pain is experienced by the devotees because of their firm belief in god.

Piercing for ceremonial purpose



Thank You...