



# **The Periodontal Flap**

**Department of Periodontics**

**Dr Rakesh Mutha**

# THE PERIODONTAL FLAP

## Ω Definition

- ① It is a section of the gingiva and/or mucosa
- ① surgically separated from the underlying tissue
- ① to provide access & visibility to the bone and root
- ① for the purpose of debridement.

## **Ω Accomplishments**

- ≈ Increased access to root deposits
- ≈ Pocket elimination or reduction
- ≈ Exposure of bone for osseous surgery

## **Ω Indications**

- ≈ Pocket elimination or reduction**
- ≈ Treatment of gingival enlargements**
- ≈ Resective or reconstructive osseous surgery**
- ≈ Esthetic and muco-gingival surgery**
- ≈ Treatment of furcation involvement**
- ≈ Pre-prosthetic surgery**

## **Ω Contra – Indications**

- ① **When optimal results can be achieved by Non surgical therapy.**
- ① **Presence of unprepared , soft, and edematous gingival tissues.**
- ① **Medically compromised patients.**
- ① **Teeth with hopeless prognosis.**
- ① **When surgery would result in extreme aesthetic disfigurement.**

# THE PERIODONTAL FLAP

## Ω Classification of flaps

① As per thickness or bone exposure

↳ Full thickness

↳ Partial thickness

① As per placement of flap after surgery

↳ Non-displaced

↳ Displaced

① As per management of papilla

↳ Conventional (Split papilla)

↳ Papilla preservation

# FULL THICKNESS FLAP

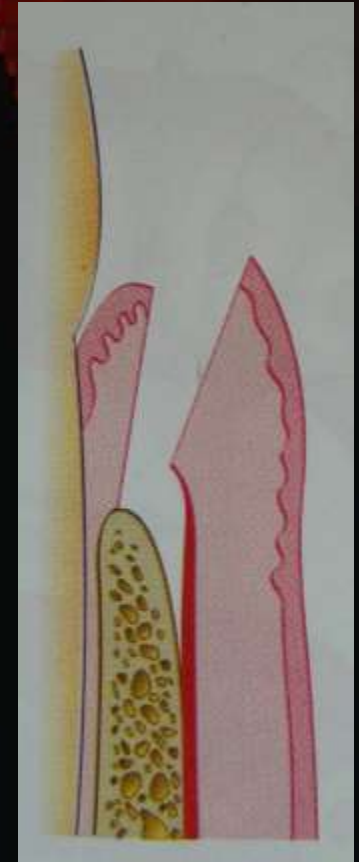
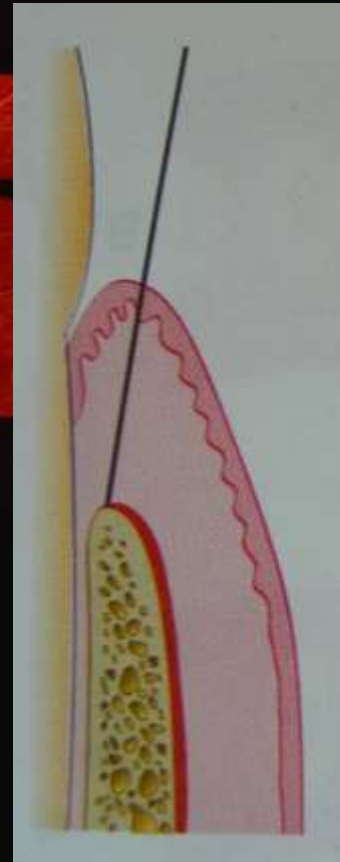
Ω Also called as muco-periosteal flap

① Gingiva as well as periosteum is reflected

↳ Exposure of underlying bone is achieved

↳ Indicated for

- ⊡ Pocket reduction
- ⊡ Osseous surgery



# PARTIAL THICKNESS FLAP

Ω Also called as mucosal flap

① Only gingival epithelium and part of connective tissue is reflected

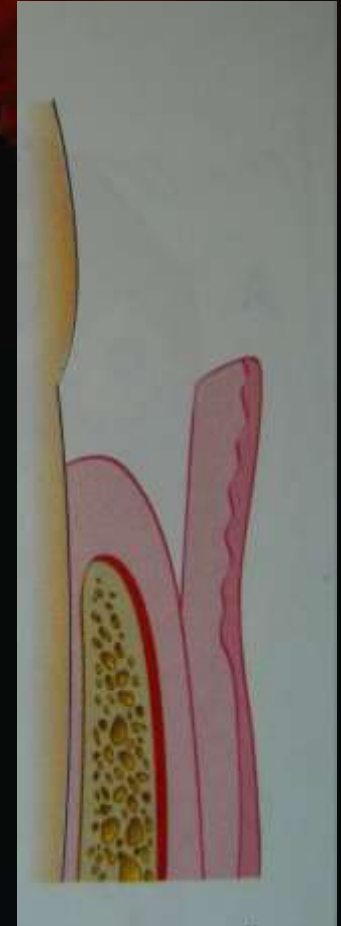
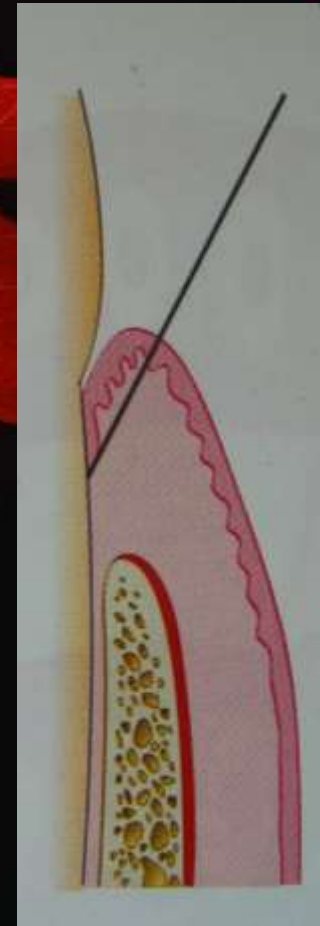
↳ Bone is left with a covering of periosteum

↳ Indicated when

△ Marginal bone is thin

△ Flap displacement

» Periosteum can be used to suture the displaced flap



# NON-DISPLACED FLAP

Ω Returned to original position on suturing

① Vertical incisions not necessary

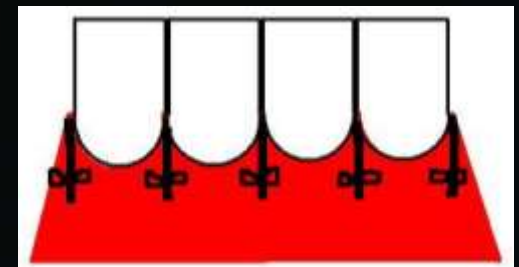
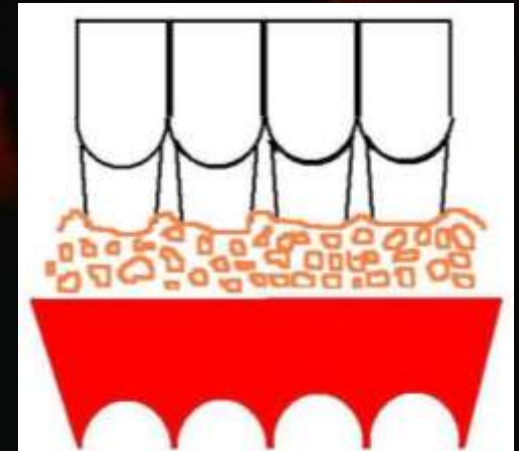
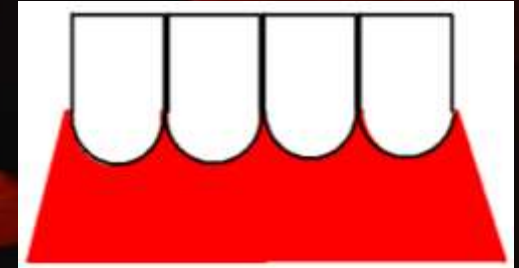
↳ Attached gingiva need not be totally separated

② Examples

↳ Modified Widman Flap

↳ Undisplaced Flap

↳ Palatal Flap



# DISPLACED FLAP

Ω Not returned to original position

① Vertical incisions necessary

↳ Attached gingiva must be separated

△ Extend beyond mucogingival junction

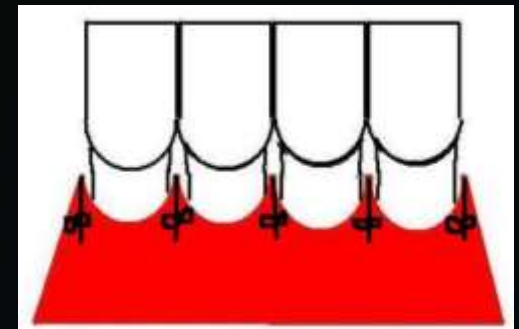
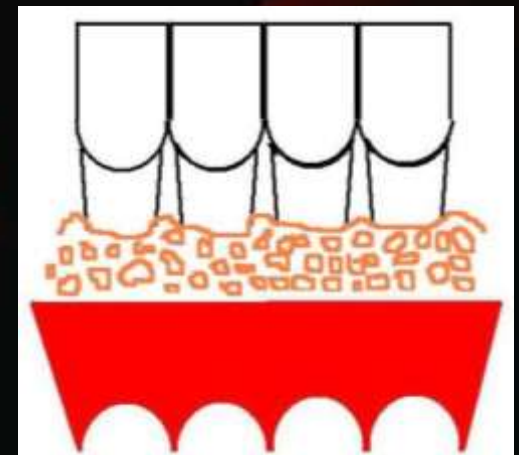
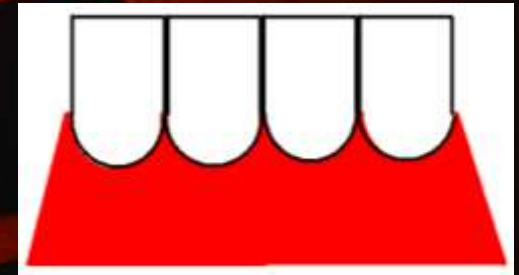
↳ Both full thickness and partial thickness flaps can be displaced

① Displacement in three directions

↳ Apically; Coronally; Laterally

① Indicated for

↳ Muco-gingival surgery



# CONVENTIONAL FLAP

## Ω Called split papilla flap

① Interdental papilla is split into buccal & lingual part

↳ Both flaps reflected

② Used when


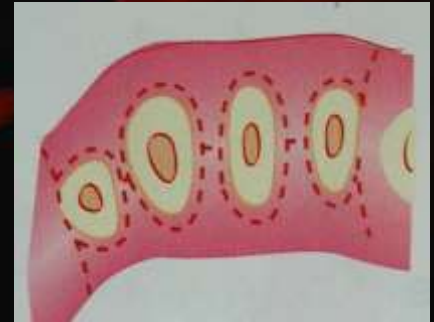
↳ Interdental space is narrow

↳ Flap has to be displaced

③ Types of flaps

↳ Modified Widman

↳ Apically Displaced



# PAPILLA PRESERVATION FLAP

## Ω Papilla preserved

① Incorporated in the buccal/lingual flap

↳ Cannot be displaced

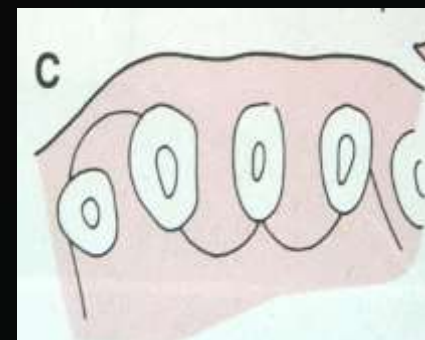
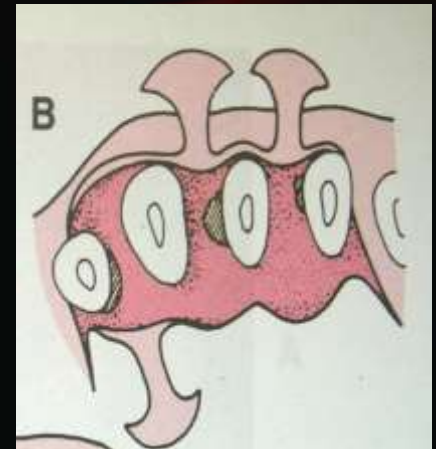
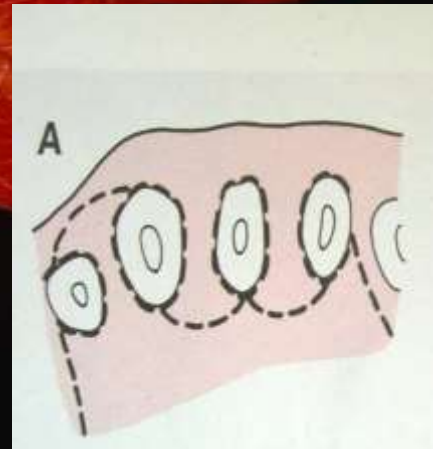
① Used when

↳ Interdental area is broad

↳ Conservation of papilla for esthetics

↳ Regenerative surgery

△ In interdental region



# DESIGN OF THE FLAP

## Ω Dictated by the following

- ① **Surgical skill and judgment of the surgeon**
  - ↳ **Full thickness or partial thickness flap**
- ① **Objectives of the operation**
  - ↳ **Pocket reduction or elimination**
  - ↳ **Resective or regenerative osseous surgery**
- ① **Amount of access and visibility needed**
  - ↳ **Of the underlying root and bone**
- ① **Final positioning of the flap**
  - ↳ **Displaced or undisplaced flap**
- ① **Preservation of the blood supply**
  - ↳ **Palatal flap**

# PLANNING OF FLAP SURGERY

Ω Should be done in detail before procedure

① Based on clinical & radiographic findings of case

① It should include the following

↳ Type of flap

↳ Location and type of incisions

↳ Management of underlying bone

↳ Final placement of flap

↳ Sutures used

① Plan may be modified in case of any variations

# INCISIONS IN FLAP SURGERY

## Ω Horizontal incisions

① Along the gingival margin

↳ In mesio-distal direction

① Types of incisions

↳ Internal bevel incision

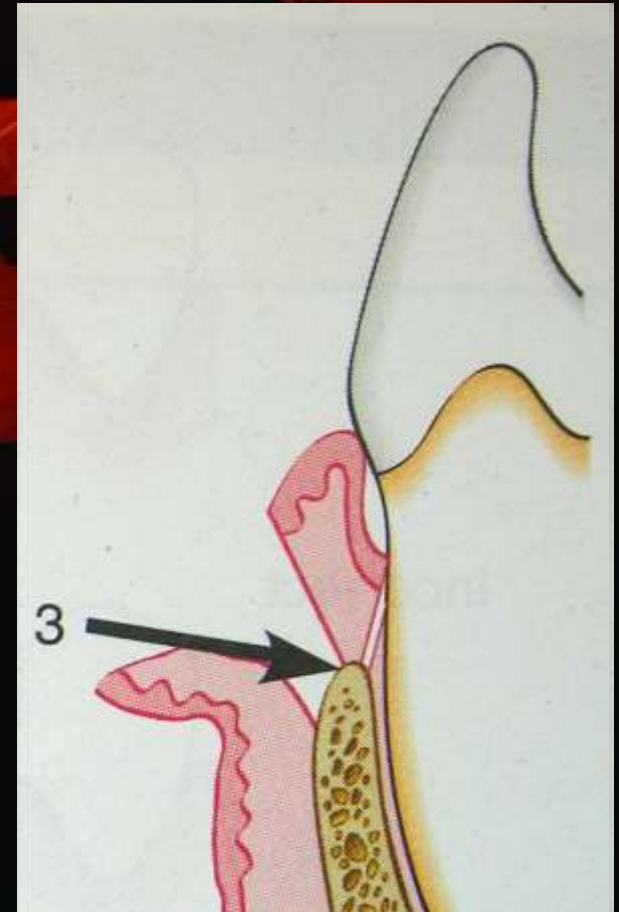
↳ Crevicular incision

↳ Interdental incision

## Ω Vertical incision

① Used for flap displacement

① For increased access



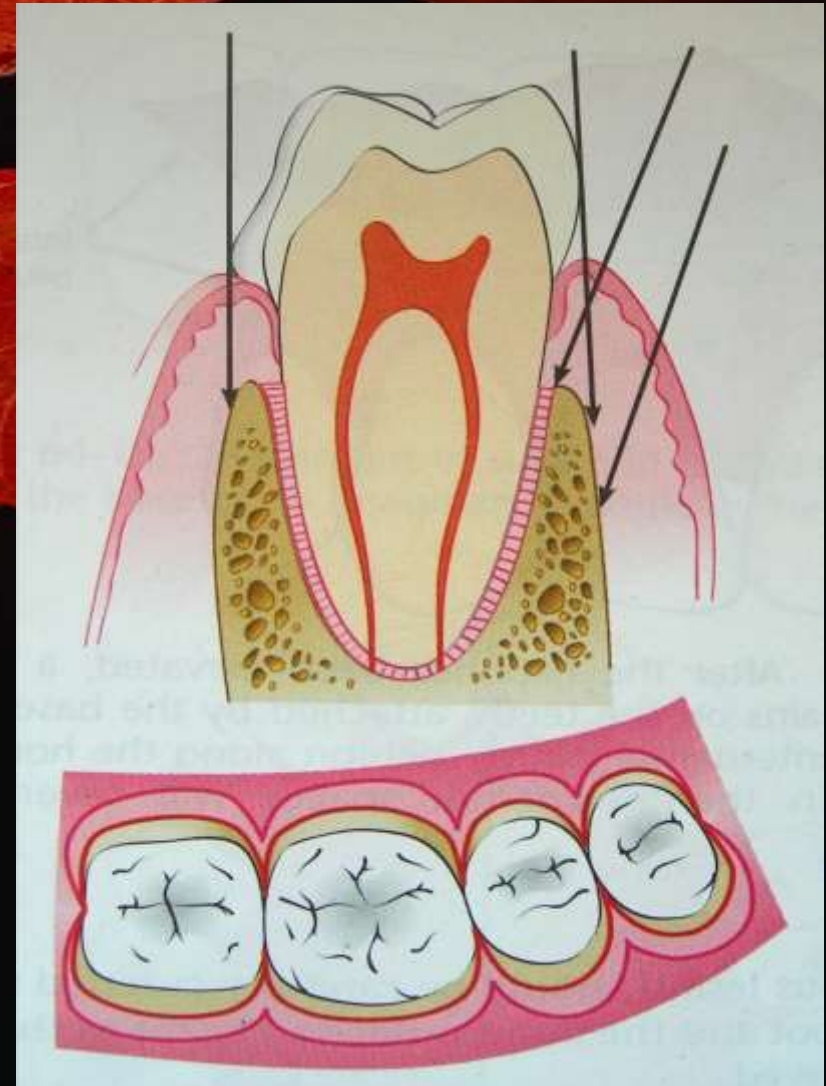
# INTERNAL BEVEL INCISION

## Ω Other names

- ① Initial or first incision
- ① Reverse bevel incision

## Ω Direction of incision

- ① 0.5 - 1mm from gingival margin
- ① Aimed at
  - ↳ Crest of alveolar bone
  - ↳ Apical to crest of bone
- ① BP blade no. 11 or 15 used



# INTERNAL BEVEL INCISION

## Ω Basic to flap surgery

① Exposure of root and underlying bone

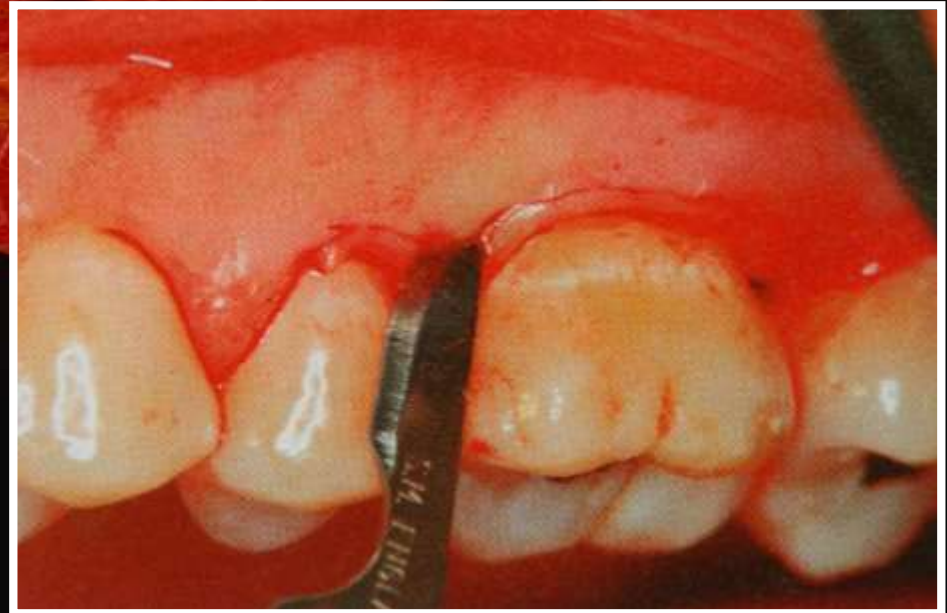① Accomplishments

↳ Removes pocket lining

↳ Conserves uninvolved outer gingiva

↳ Produces a sharp, thin flap margin

↳ Places the connective tissue close to the root



# CREVICULAR INCISION

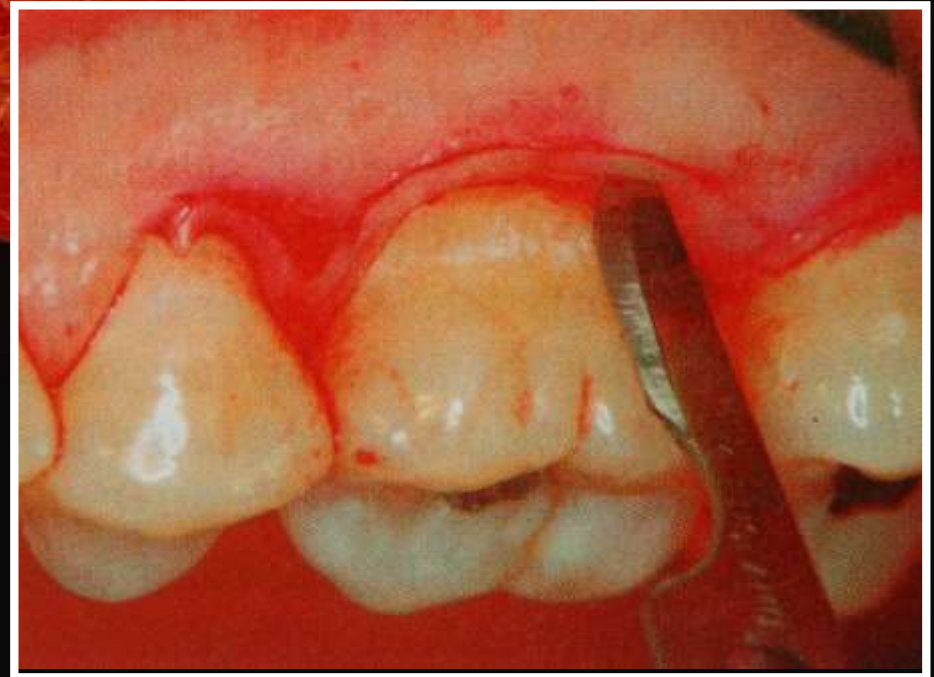## Ω Second incision

① Made from base of the sulcus to the crest of bone

↳ With first incision forms “V” shaped wedge of tissue which contains

- ⊆ Infected granulation tissue
- ⊆ Junctional epithelium
- ⊆ Supra-crestal fibers

① BP blade no. 12 used



# INTERDENTAL INCISION

Ω Called as third incision

Ω Direction

① Interdentally at alveolar crest

↳ In labio-lingual direction

↳ After flap reflection

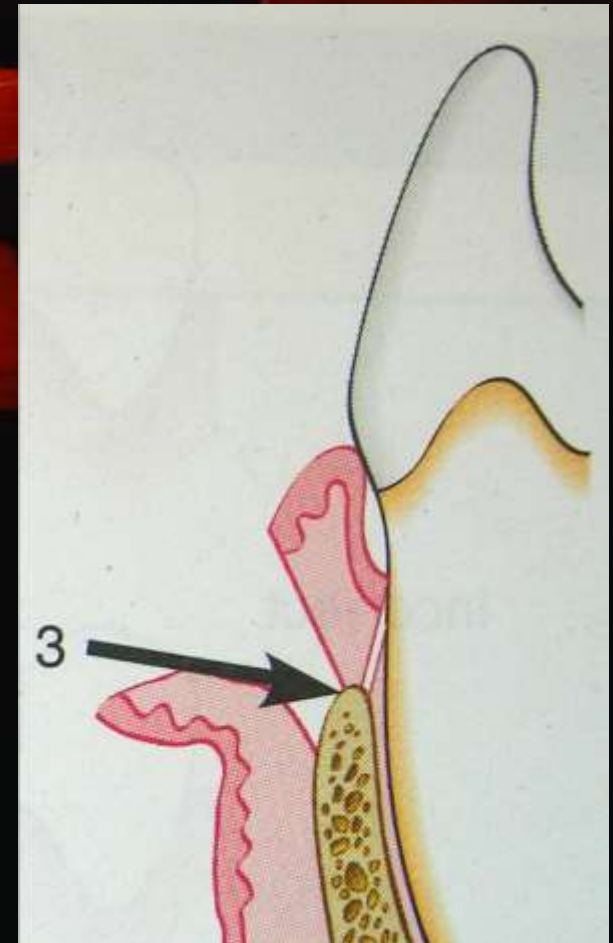
Ω Separates wedge of tissue

① Containing infectious tissue

Ω Instrument used

① Orbans knife

① BP blade no. 11



# VERTICAL INCISIONS

**Ω Also called as oblique or releasing incision**

- ① Depend upon flap design and purpose
- ① Can be used on one or both sides of the flap

**Ω For a displaced flap**

- ① Two vertical incisions are a must
- ① Extend beyond the muco-gingival junction
  - ↳ Allow the attached gingiva to be detached

**Ω Flap without vertical incision is called as  
“Envelop Flap**

# VERTICAL INCISION

## Ω Areas of incision

### ① At line angles of papilla

- ↳ To avoid papilla
- ↳ To include papilla

### ② Never on the

- ↳ Mid-papillary region
- ↳ On radicular surface

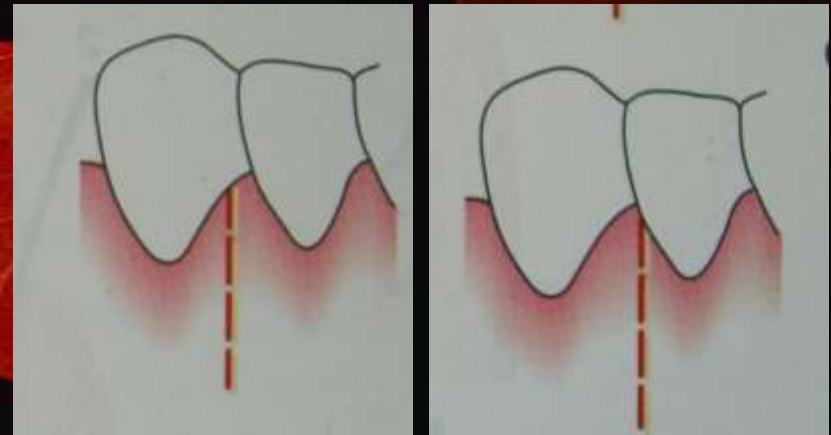
### ③ Areas to avoid

- ↳ Lingual area
- ↳ Palatal area

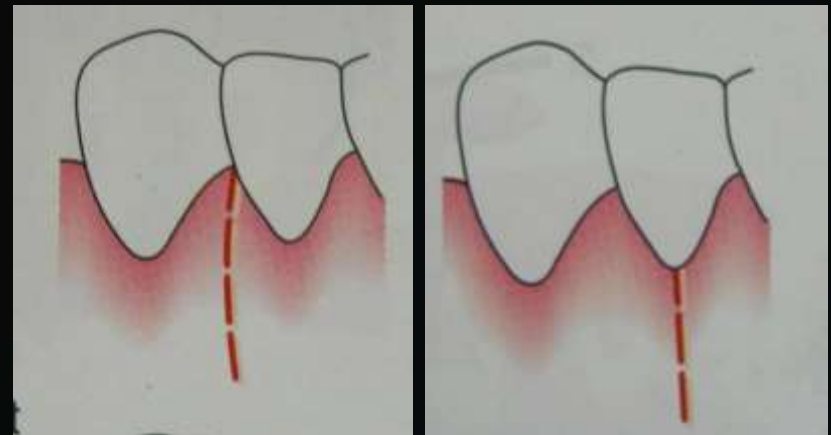
### ④ Extent

- ↳ Beyond muco-gingival junction

## CORRECT INCISIONS



## INCORRECT INCISIONS



# ELEVATION OF FLAP

Ω Needed for access and visibility of

① Root surface

↳ For debridement

① Bone

↳ For osseous surgery

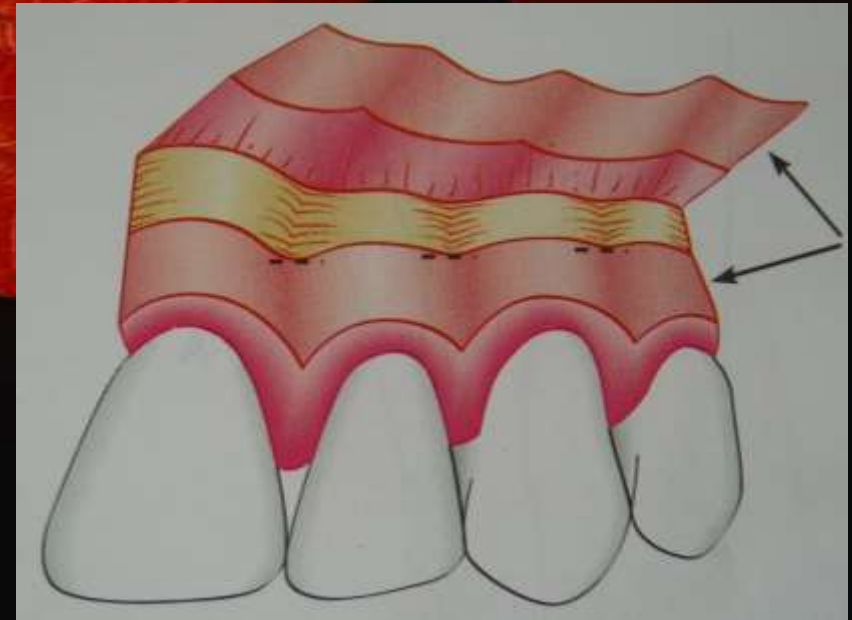△ Resective

△ Reconstructive

Ω Types

① Full thickness flap

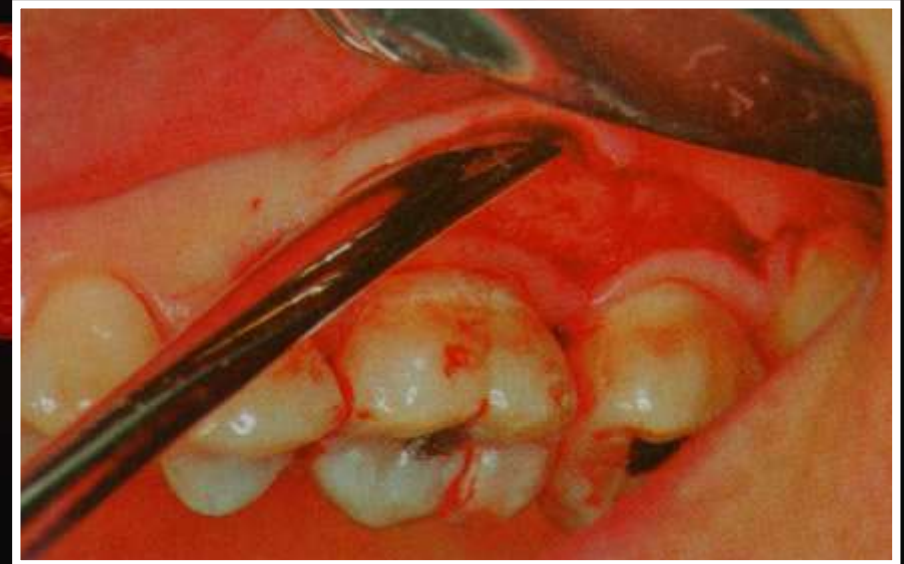
① Partial thickness flap



# ELEVATION OF FLAP

## Ω Full thickness flap

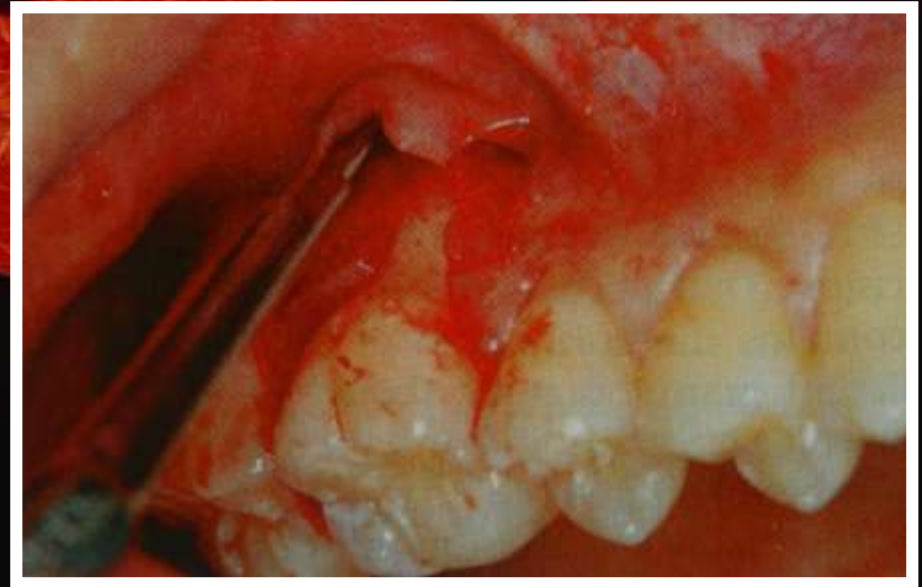- ① Called as blunt dissection
- ① With periosteal elevator
  - ↳ Moved in mesial, distal and apical direction
- ① Optimum bone exposure achieved



# ELEVATION OF FLAP

## Ω Partial thickness flap

- ① Called as sharp dissection
- ① Done with surgical blade no. 11 or 15
  - ↳ Moved in mesial, distal and apical direction
- ① Bone left with covering of periosteum



# FLAP SUTURING

## Ω Purpose

- ① Maintain flap in desired position till healing has progressed to a point where they are not needed

## Ω Materials

### ① Non absorbable

- ↳ Braided silk; Nylon (monofilament); Polyester (braided)
- ↳ Expanded polytetrafluoroethylene (EPTFe)

### ① Absorbable

- ↳ Plain catgut; Chromic catgut (both monofilaments)

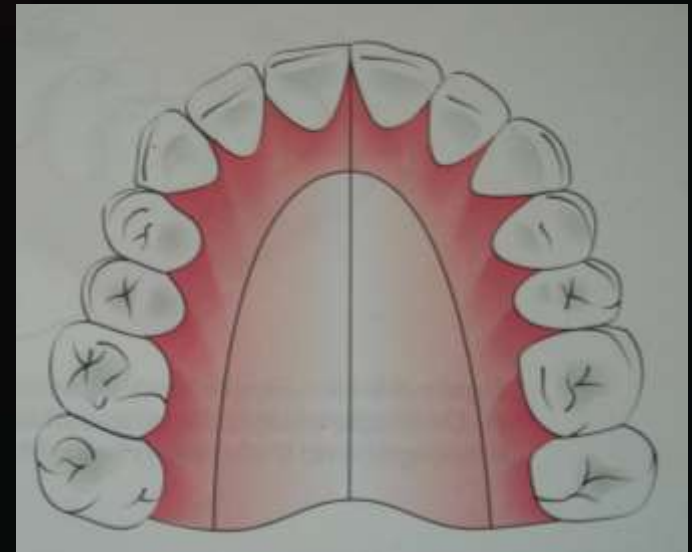
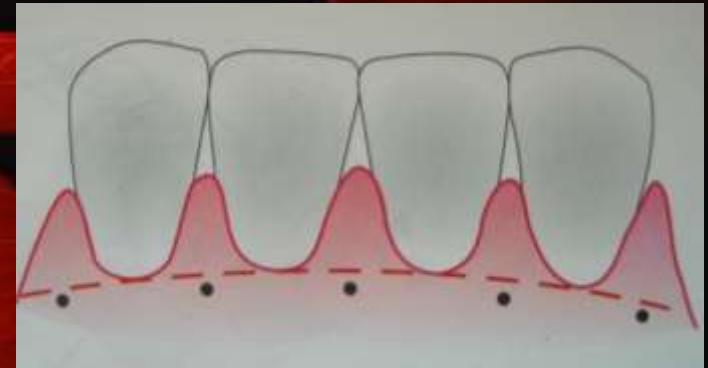
### ① Synthetic

- ↳ Polyglycol; Polyglecaprone; Polyglyconate

# SUTURING TECHNIQUE

## Ω Method

- ① Use needle holder
- ① Enter tissue at right angles
  - ↳ 2-3mm away from incision
- ① Carry suture through the tissue
  - ↳ following needle curvature
- ① Interdental sutures should pass to lingual/palatal area
  - ↳ At the base of the papilla
  - ↳ Should return to buccal side
    - △ Through inner papilla



# LIGATION

## Ω Independent

### ① Interdental

↳ Direct or simple loop suture; Figure of 8 suture

### ① Sling ligation

### ① Anchor suture; Closed anchor suture

### ① Mattress sutures

↳ Horizontal; Vertical

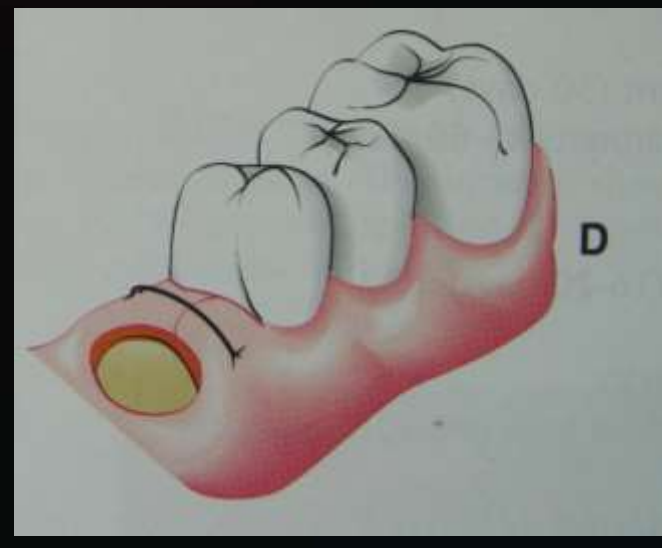
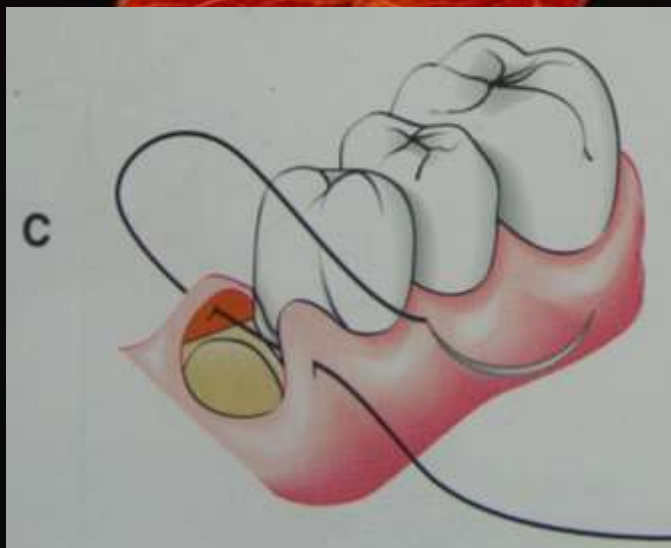
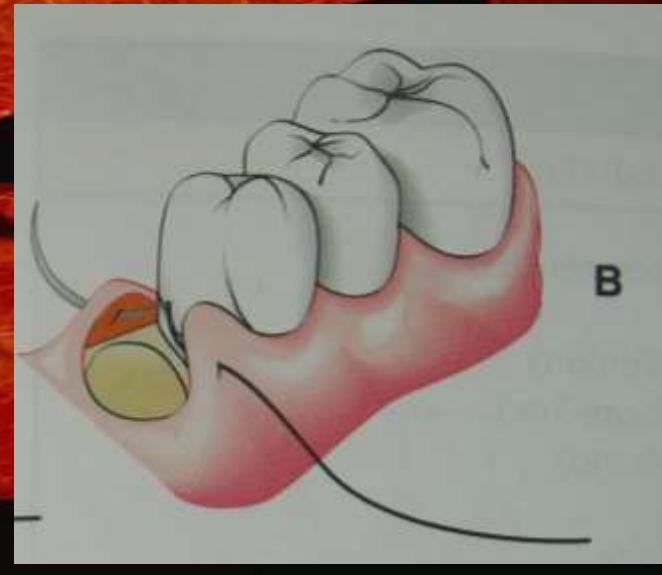
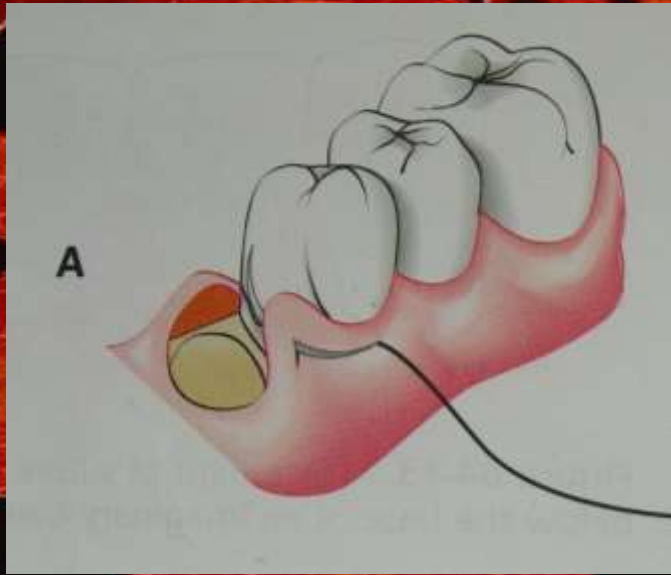
### ① Periosteal suture

## Ω Continuous independent sling ligation

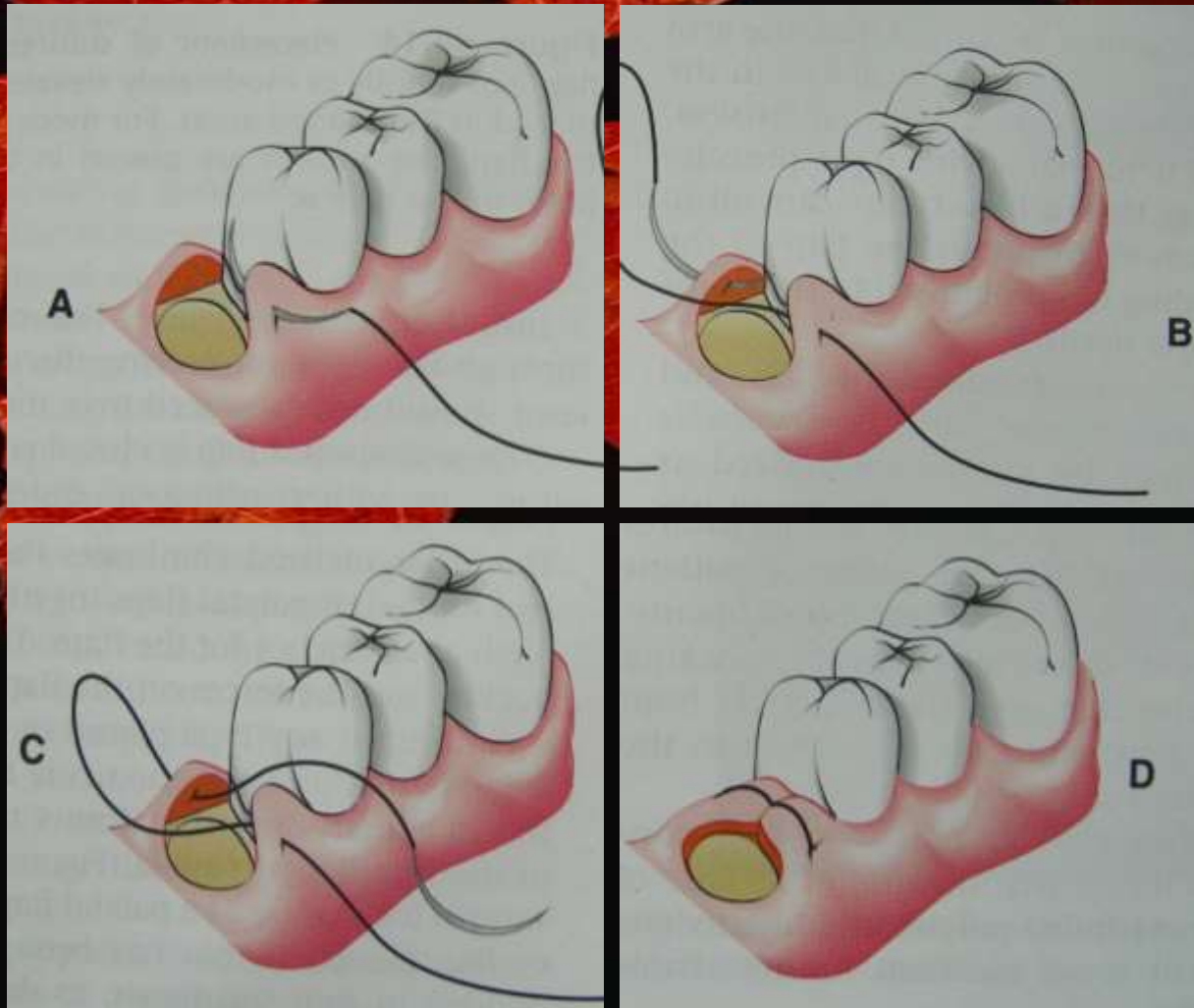
### ① Separate for buccal and lingual flap

↳ Teeth used as anchors; Single knot given

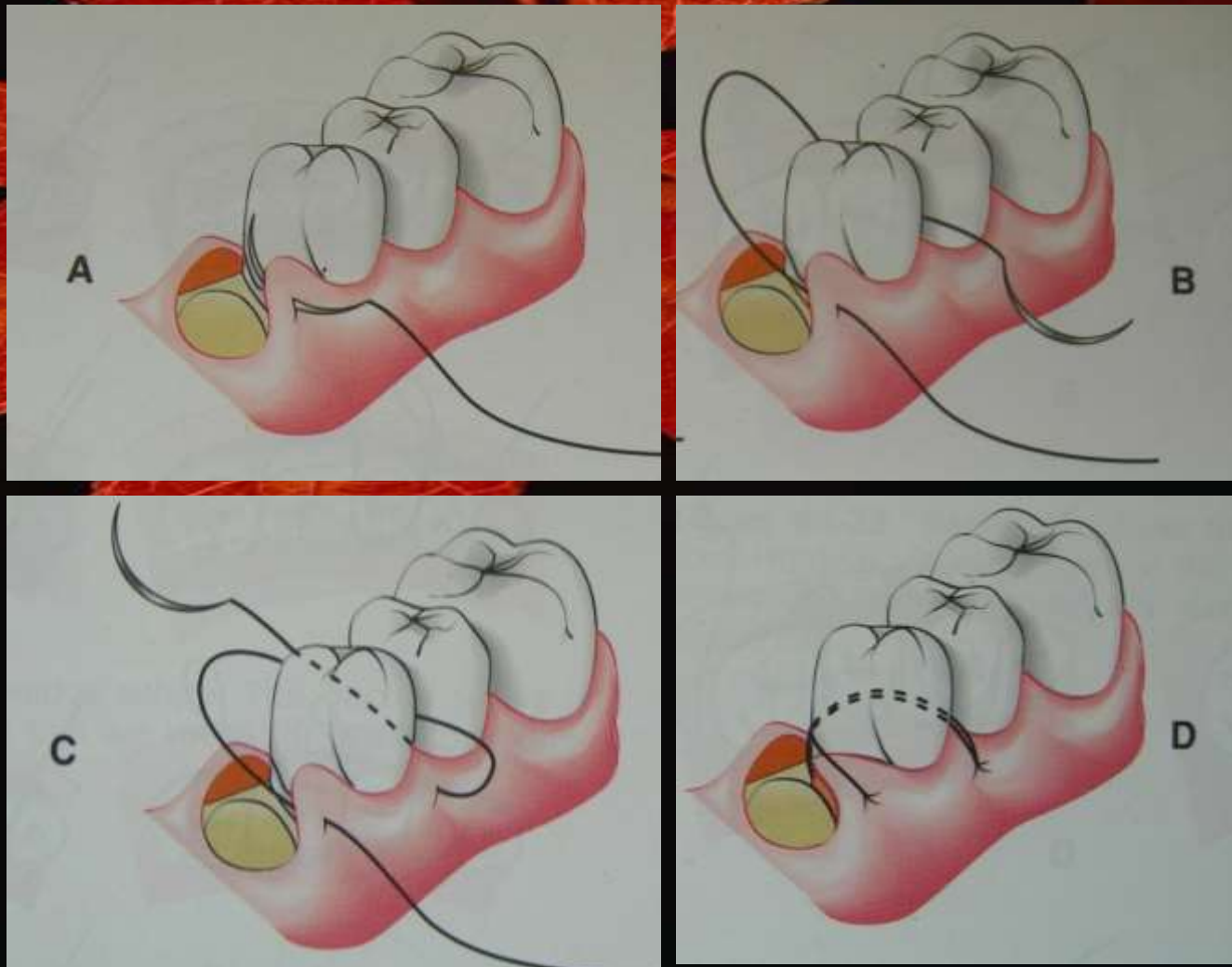
# SIMPLE LOOP SUTURE



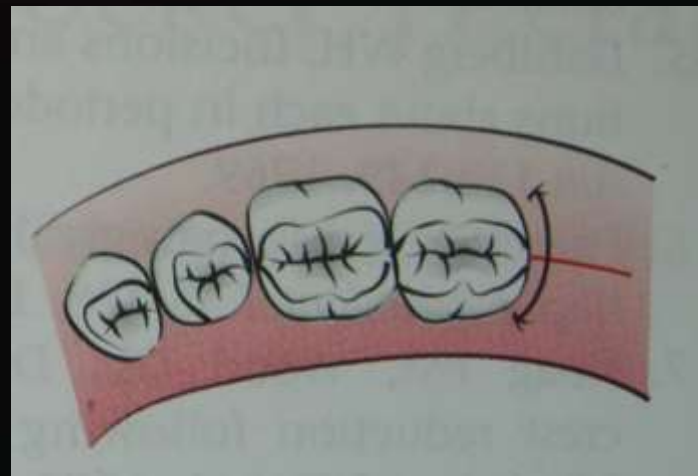
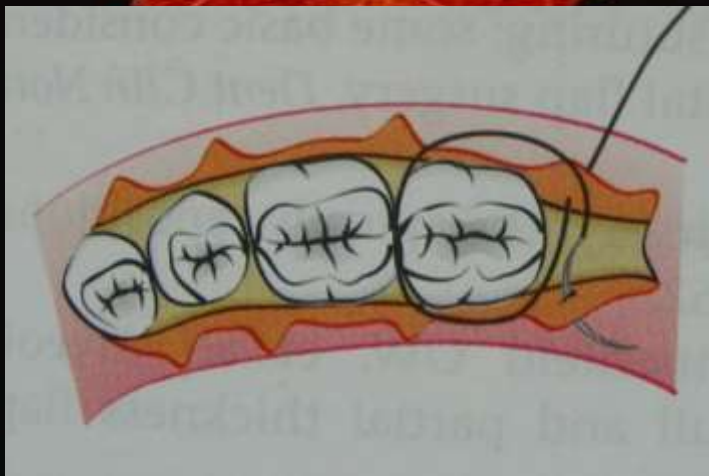
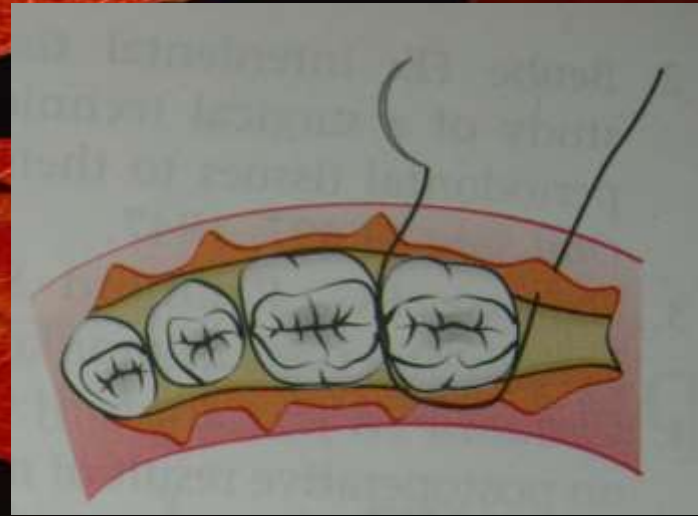
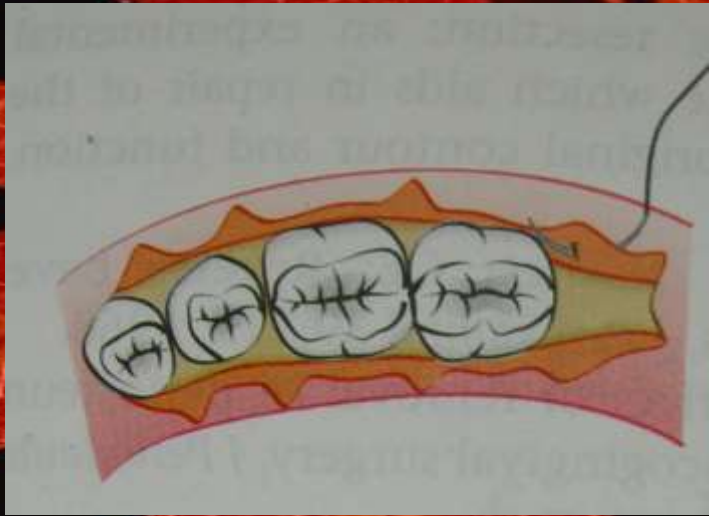
# FIGURE OF 8 SUTURE



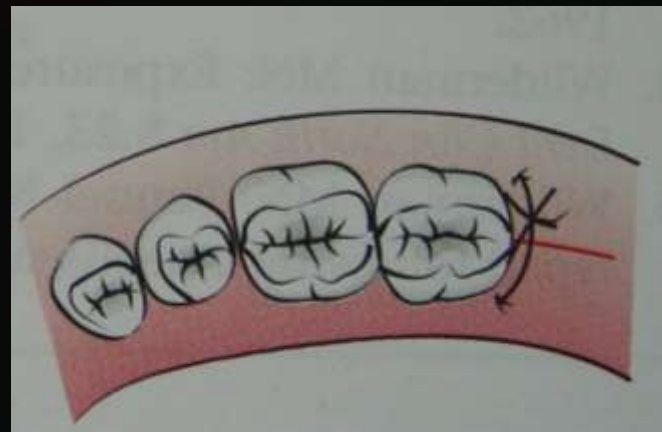
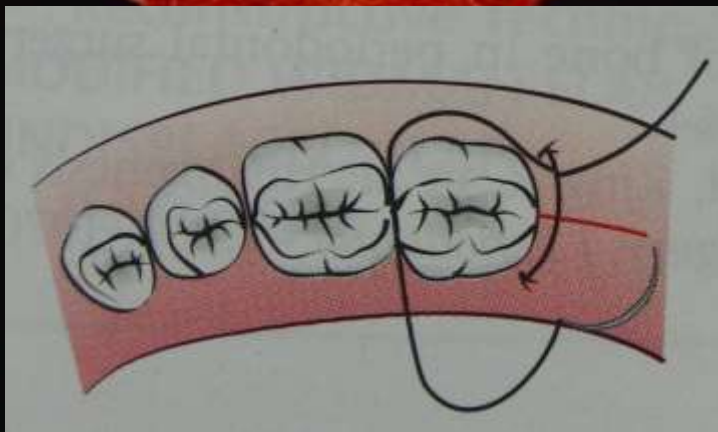
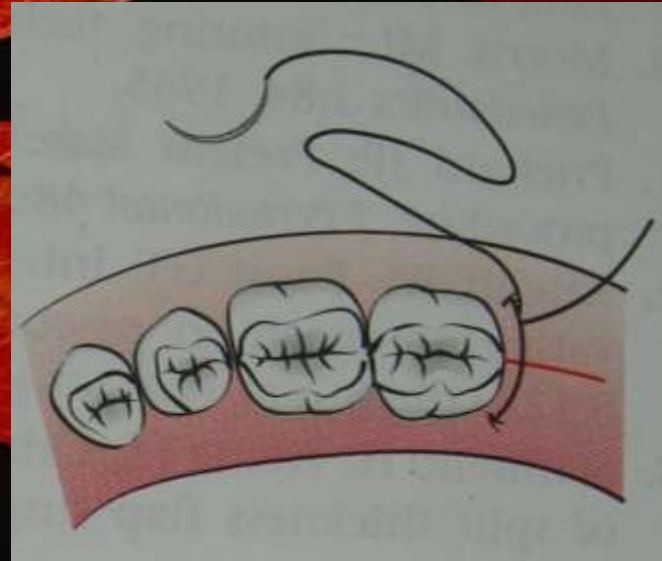
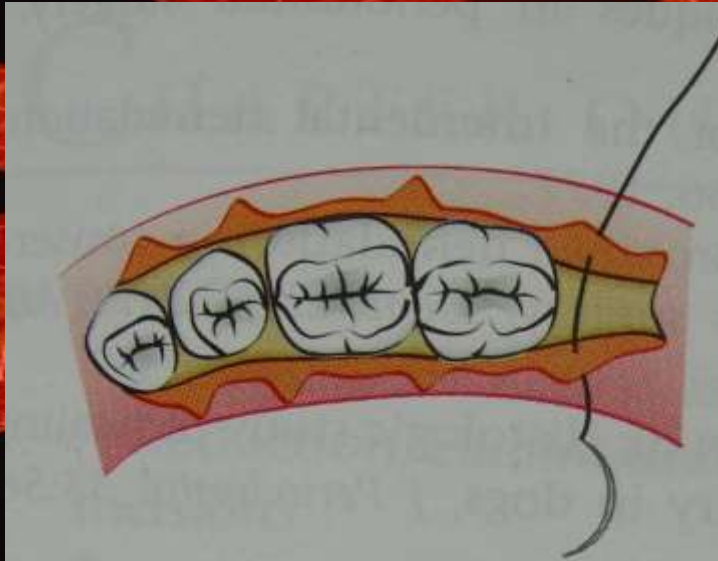
# SLING SUTURE



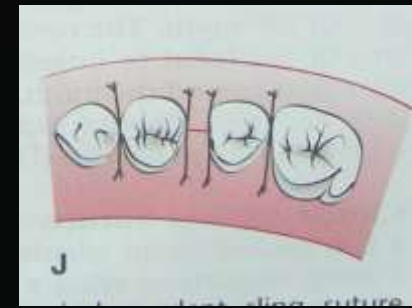
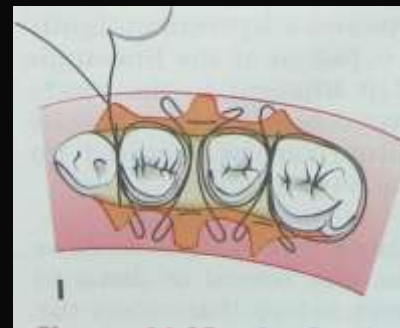
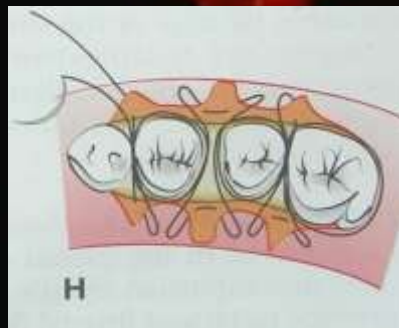
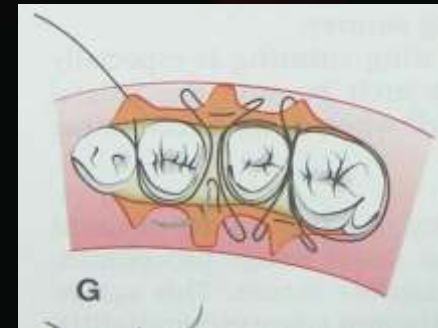
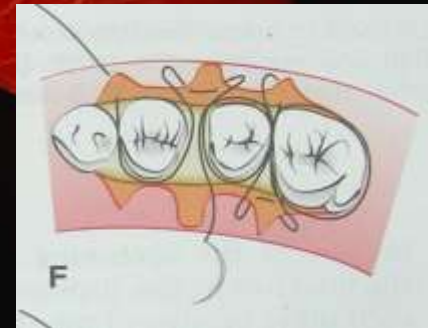
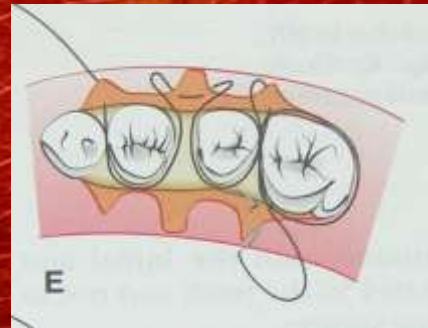
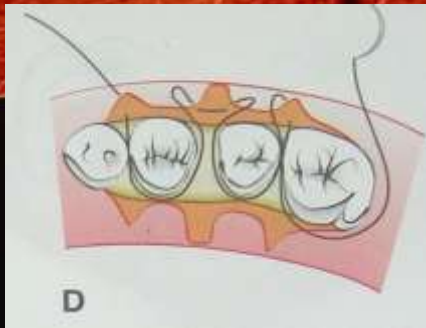
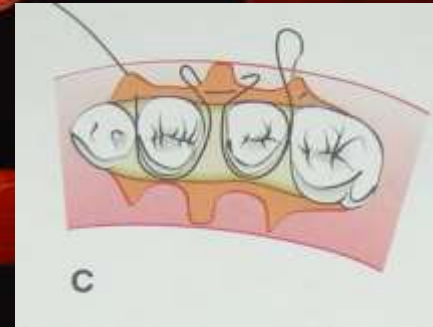
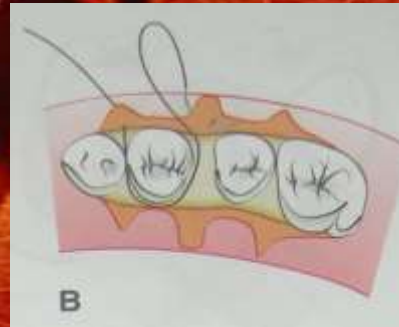
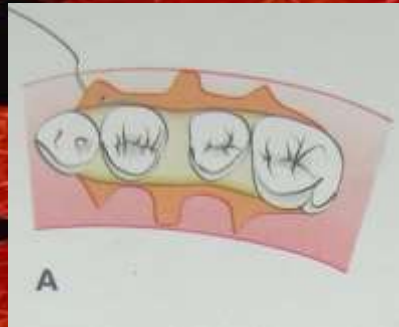
# DISTAL WEDGE SUTURE



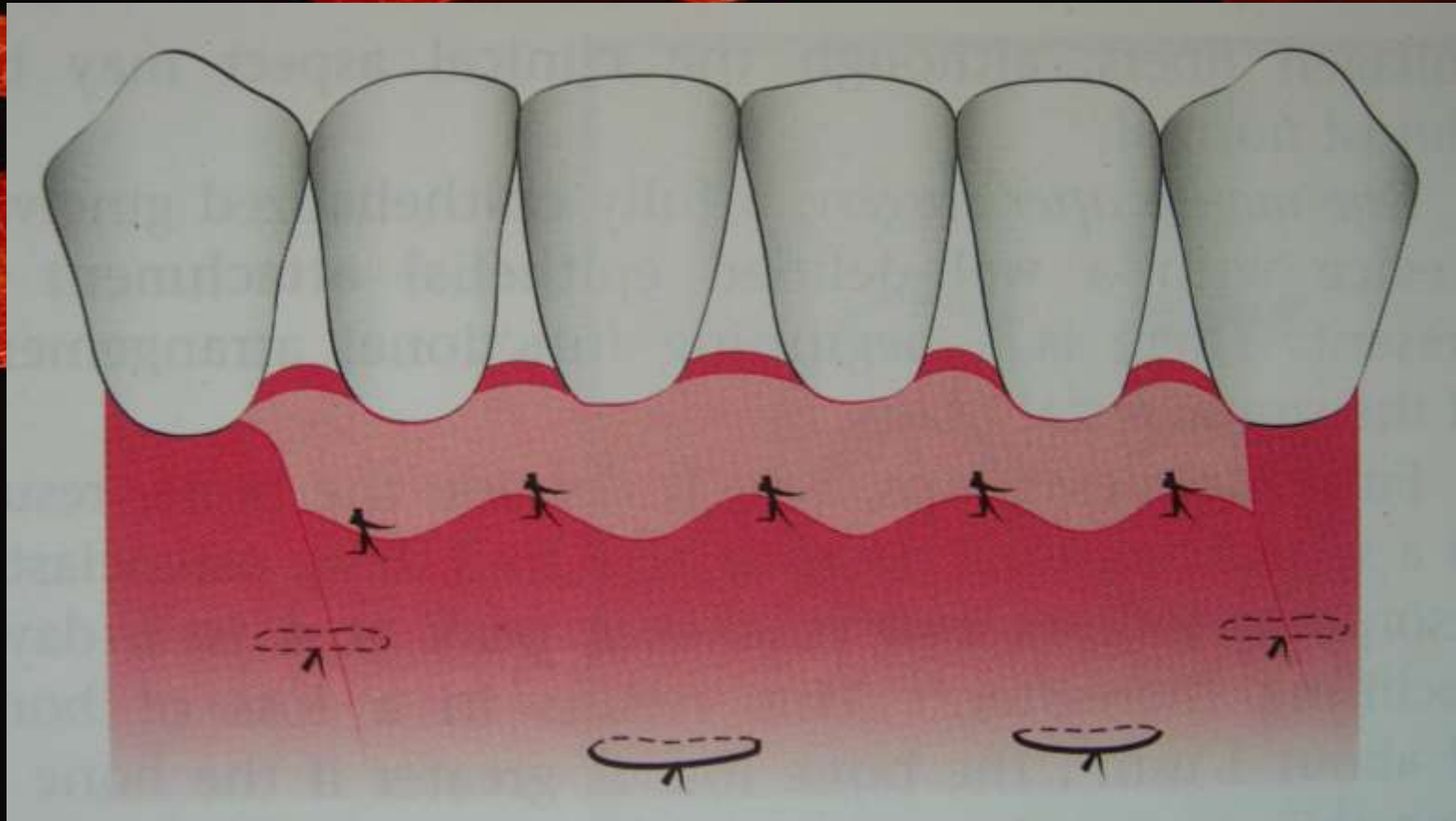
# CLOSED ANCHOR SUTURE



# CONTINUOUS LIGATION



# PERIOSTEAL SUTURE



# HEALING AFTER FLAP SURGERY

## Ω 0-24 hours

- ① Clot connects flap and tooth/bone surface
- ① Contains fibrin network of
  - ↳ PMNLs and erythrocytes
  - ↳ Cell debris
  - ↳ Capillaries at wound edge
- ① Exudate results

## Ω 1-3 days

- ① Space between bone/tooth and flap is thinner
- ① Epithelial cells migrate over wound edge
- ① Minimal inflammatory response seen

# HEALING AFTER FLAP SURGERY

## Ω 1 week

- ① Epithelial attachment is established by
  - ↳ Hemidesmosomes and basal lamina
- ① Blood clot replaced by granulation tissue from
  - ↳ Gingival connective tissue; bone marrow and PDL

## Ω 2 weeks

- ① Collagen fibers parallel to tooth surface
- ① Clinically normal but immature junction

## Ω 4 weeks

- ① Fully epithelized sulcus; well defined attachment
- ① Functional orientation of supra-crestal fibers

**Crazy Definitions**

**PERIODONTOLOGY**

**A BIG ISSUE**

**OVER A  
THANKS**

**SMALL TISSUE**

