

Endo-Perio Lesions – Pathways , Problems , Interrelationships

Presented by
-Dr. Kanchan Jagtap



“Success is dependent upon combined efforts”

Introduction

- Pulpal and periodontal problems are responsible for more than 50% of tooth mortality.
- The relationship between the periodontium and the pulp was first discovered by **Simring and Goldberg in 1964.**
- Many studies in the literature indicate that combined periodontal and endodontic therapy is essential for successful healing of a periodontal-endodontic lesion.
- Treatment and prognosis of primarily endodontic and primarily periodontal disease is very straightforward. However, prognosis of combined forms of the lesions is more difficult to predict

Definition

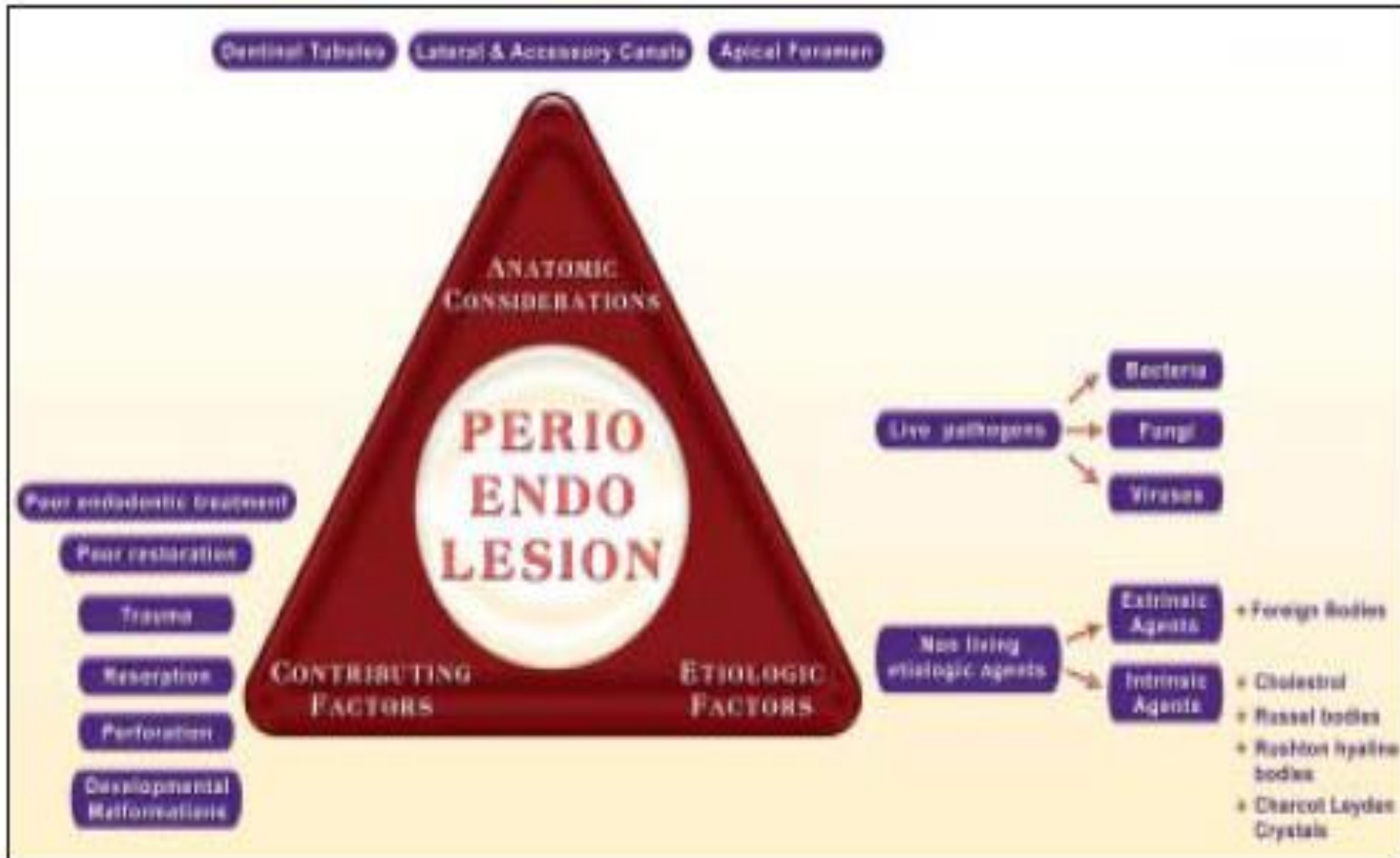
- ENDODONTIC LESION :-

IT IS USED TO DENOTE AN INFLAMMATORY PROCESS IN THE PERIODONTAL TISSUES RESULTING FROM NOXIOUS AGENTS PRESENTS IN THE ROOT CANAL SYSTEM OF THE TOOTH, USUALLY A ROOT CANAL INFECTION .

- PERIODONTAL LESION :-

IT IS USED TO DENOTE AN INFLAMMATORY PROCESS IN THE PERIODONTAL TISSUE RESULTING FROM ACCUMULATION OF DENTAL PLAQUE ON THE EXTERNAL TOOTH SURFACE .

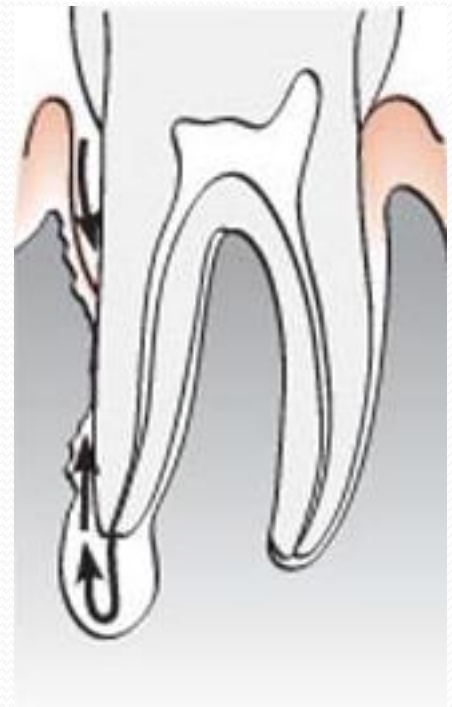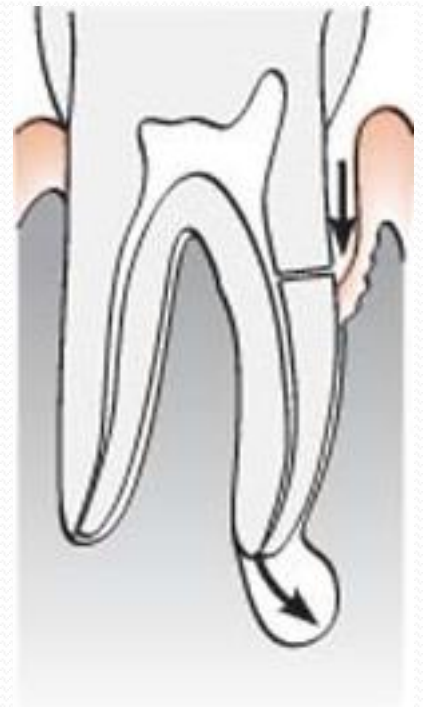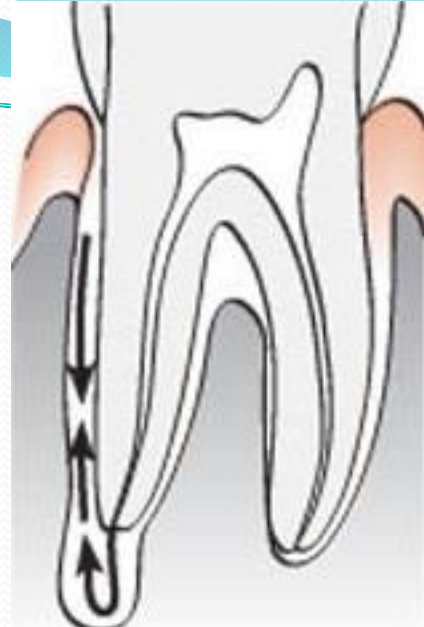
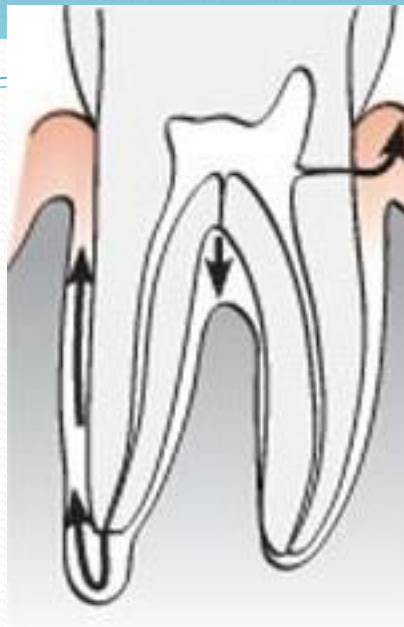
Etiopathogenesis



CLASSIFICATION OF ENDO - PERIO LESIONS

SIMON 1972

- 1. PRIMARY ENDODONTIC LESION.**
- 2. PRIMARY ENDODONTIC LESION WITH SECONDARY PERIODONTAL INVOLVEMENT.**
- 3. PRIMARY PERIODONTIC LESION.**
- 4. PRIMARY PERIODONTIC LESION WITH SECONDARY ENDODONTIC INVOLVEMENT.**
- 5. TRUE COMBINED LESION.**



GROSSMAN 1991

- **LESIONS THAT REQUIRE ENDODONTIC TREATMENT PROCEDURES ONLY**
- **LESIONS THAT REQUIRE PERIODONTAL TREATMENT PROCEDURES ONLY**
- **LESIONS THAT REQUIRE COMBINED ENDODONTIC - PERIODONTAL TREATMENT PROCEDURES**

CLINICAL FINDINGS IN ENDODONTIC AND PERIODONTIC LESIONS

CLINICAL FINDINGS	ENDO LESION	PERIO LESION
PULPAL RESPONSE	ABSENT	PRESENT
BONE DEFORMITY	TUBULAR 'U'	TRIANGULAR 'V'
PLAQUE & CALCULUS	ABSENT	PRESENT
CARIES/ RESTORATION	PRESENT	ABSENT
MOBILITY	ABSENT	PRESENT
GEN PERIODONTITIS	ABSENT	PRESENT

CLINICAL FINDINGS IN ENDODONTIC AND COMBINED ENDODONTIC-PERIODONTIC LESIONS

CLINICAL FINDINGS	ENDO LESION	COMBINED LESION
PULPAL STATUS	NECROTIC	NECROTIC
PERIO STATUS	NORMAL	GEN PERIODONTITIS
PROBING	NARROW POCKET	WIDE POCKET
PLAQUE & CALCULUS	ABSENT	PRESENT
TREATMENT	ENDODONTIC	COMBINED
PROGNOSIS	GOOD	DEPENDS ON PERIODONTAL STATUS

TREATMENT

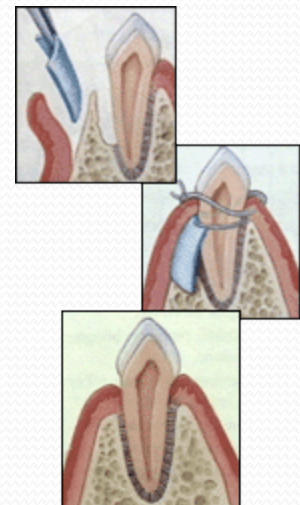
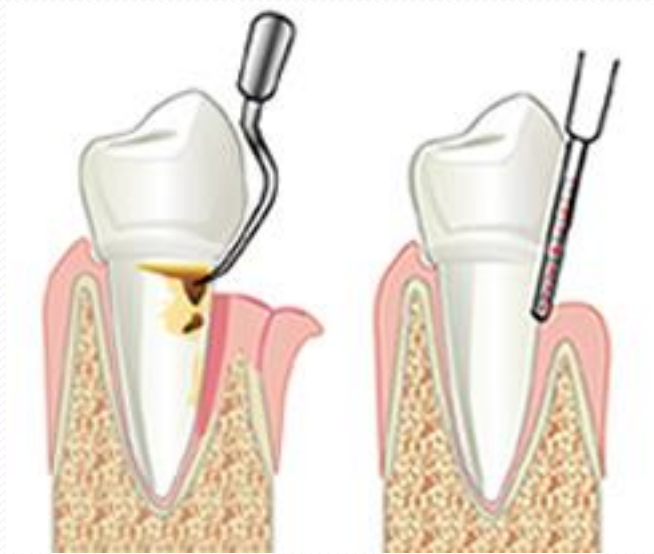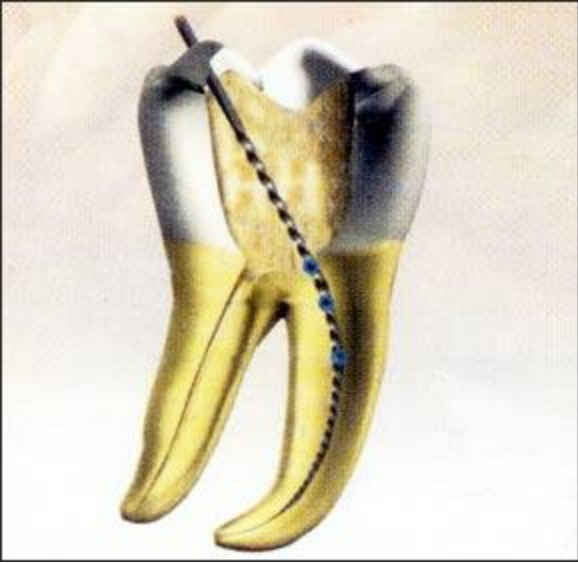- PRIMARY ENDODONTIC LESION –
CONVENTIONAL ENDODONTIC THERAPY
- PRIMARY ENDODONTIC LESION WITH
SECONDORY PERIODONTAL INVOLVEMENT
–
ENDO PERIO THERAPY
- PRIMARY PERIODONTAL LESION -
 1. PERIODONTAL THERAPY
 2. GUIDED TISSUE REGENERATION
 3. ROOT AMPUTATION & HEMISECTION
 4. PULP SPACE THERAPY

- PRIMARY PERIODONTAL LESION WITH SECONDARY ENDO LESION

1. PULP SPACE THERAPY
2. PERIODONTAL THERAPY
3. ROOT AMPUTATION
4. GTR

- TRUE COMBINED LESION

1. ENDO THERAPY
2. PERIO DONTAL THERAPY
3. HEMISECTION
4. BICUSPIDIZATION
5. ROOT AMPUTATION



Hemisection

