



GINGIVA

Dr. Parag Hadge

Periodontium

- the gingiva,
- periodontal ligament,
- alveolar bone and
- cementum

The oral mucosa consists of three zones:

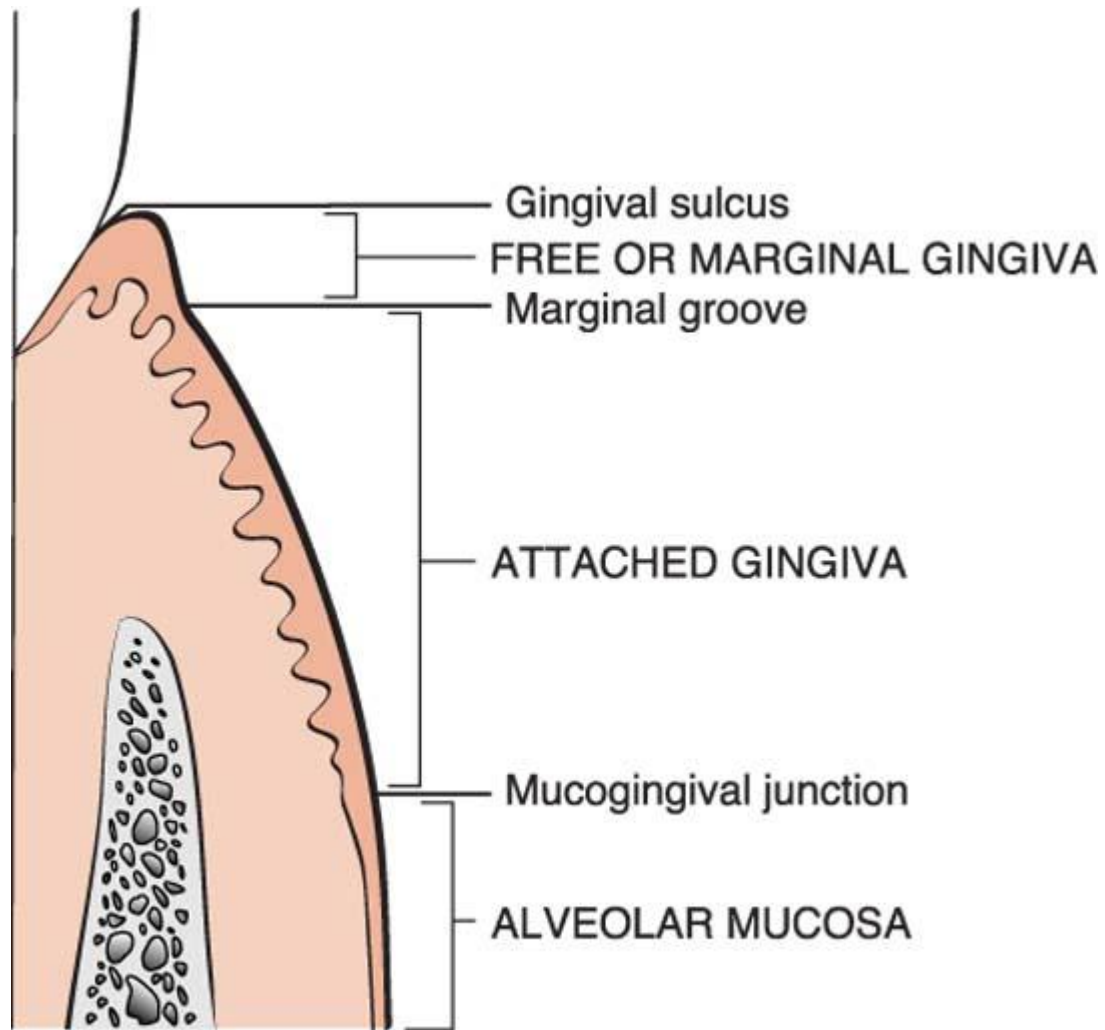
- the gingiva and the covering of the hard palate, termed the **masticatory mucosa**;
- the dorsum of the tongue, covered by **specialized mucosa**; and
- the oral mucous membrane **lining** the remainder of the oral cavity.

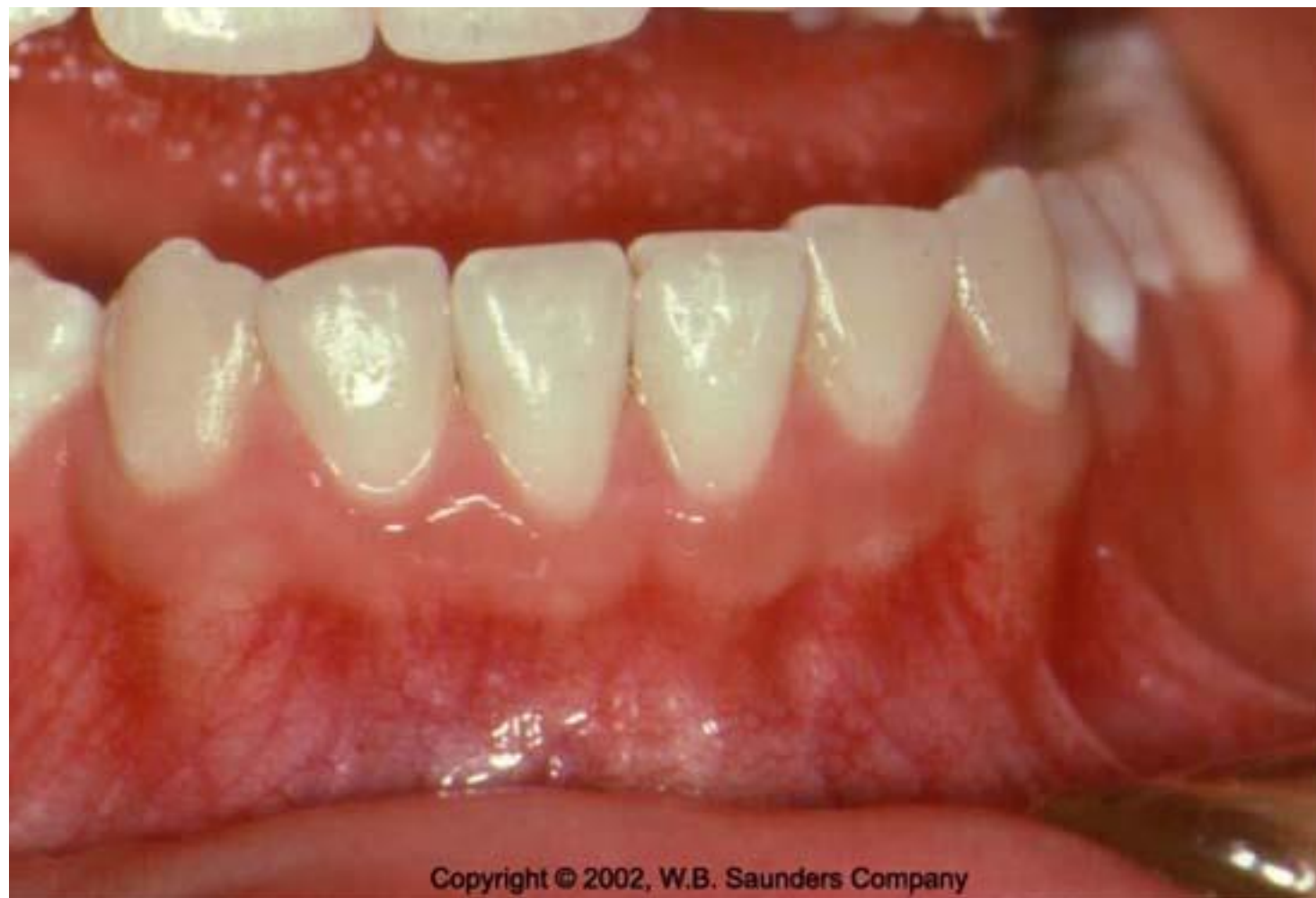The gingiva is the part of the oral mucosa that covers the alveolar processes of the jaws and surrounds the necks of the teeth in collar like fashion.

The gingiva is divided anatomically into

- ❖ Marginal gingiva,
- ❖ Attached gingiva, and
- ❖ Interdental gingiva

- Histologically, it is composed of two distinct components – the overlying epithelial structures and the underlying connective tissue.





Copyright © 2002, W.B. Saunders Company

Dr. Parag Hadge

Marginal Gingiva

- The marginal, or unattached, gingiva is the terminal edge or border of the gingiva surrounding the teeth in collar like fashion.
- In about 50% of cases-the **free gingival groove**.
- Usually about 1 mm wide, it forms the soft tissue wall of the gingival sulcus.
- It may be separated from the tooth surface with a periodontal probe.

Gingival Sulcus

- The gingival sulcus is the shallow crevice or space around the tooth bounded by the surface of the tooth on one side and the epithelium lining the free margin of the gingiva on the other.
- It is **V shaped** and barely permits the entrance of a periodontal probe.

Clinical Importance

- Under absolutely normal or ideal conditions, the depth of the gingival sulcus is or is about 0.
- These strict conditions of normalcy can be produced experimentally only in germfree animals or after intense, prolonged plaque control.

- In clinically healthy gingiva in humans, as determined in histologic sections, has been reported as 1.8 mm, with variations from 0 to 6 mm.
- The so-called probing depth of a clinically normal gingival sulcus in humans is **2 to 3 mm**.

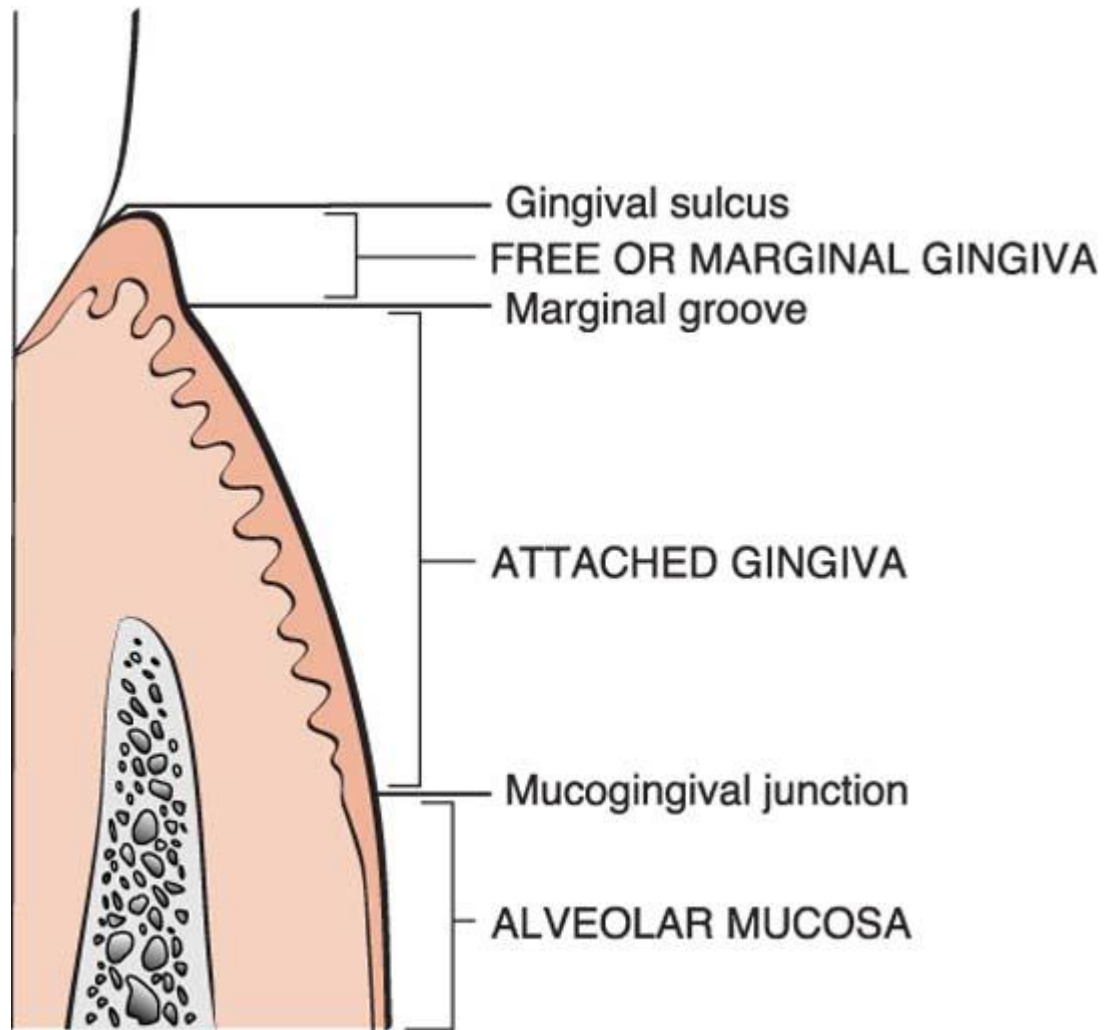
Attached Gingiva

- The attached gingiva is continuous with the marginal gingiva. It is **firm, resilient**, and tightly bound to the underlying periosteum of alveolar bone.
- The facial aspect of the attached gingiva extends to the relatively loose and movable alveolar mucosa, from which it is demarcated by the **mucogingival junction**.

The MGJ particularly on the vestibular aspect can be localized

- Functionally – by passive movement of lips and cheek
- Anatomically – by differences of colour and surface characteristics.
- Histochemically – by application of Schiller's iodine solution to reveal the glycogen stored in the epithelium of the lining mucosa
- *Topographically - its location remains rather stable with increasing age, at least in relation to the nasal floor and the lower border of the mandible. Normally, this junction resides about 3-5 mm apical to the level of the alveolar crest.*
- *By functional method, the MGJ is about 0.5 mm apical to that found with a histochemical method (**Bernimoulin et al 1971**).*

- The **width of the attached gingiva** is another important clinical parameter.
- It is the distance between the mucogingival junction and the projection on the external surface of the bottom of the gingival sulcus or the periodontal pocket.
- It should not be confused with the **width of the keratinized gingiva** because the latter also includes the marginal gingiva.



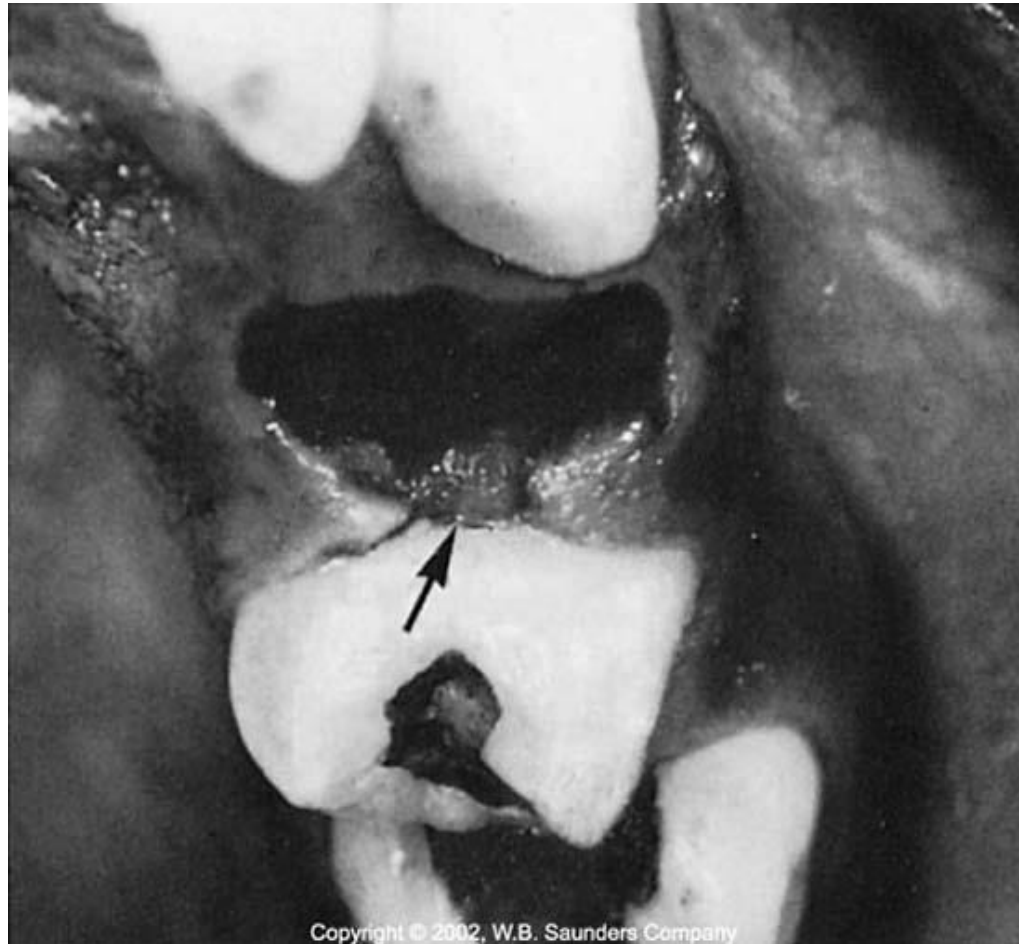- The width of the attached gingiva on the facial aspect differs in different areas of the mouth.
- It is generally greatest in the incisor region (3.5 to 4.5 mm in the maxilla and 3.3 to 3.9 mm in the mandible) and less in the posterior segments, with the least width in the first premolar area (1.9 mm in the maxilla and 1.8 mm in the mandible).

- Because the mucogingival junction remains stationary throughout adult life, changes in the width of the attached gingiva are caused by modifications in the position of its coronal end.
- The width of the attached gingiva increases with age and in supraerupted teeth.

Interdental Gingiva

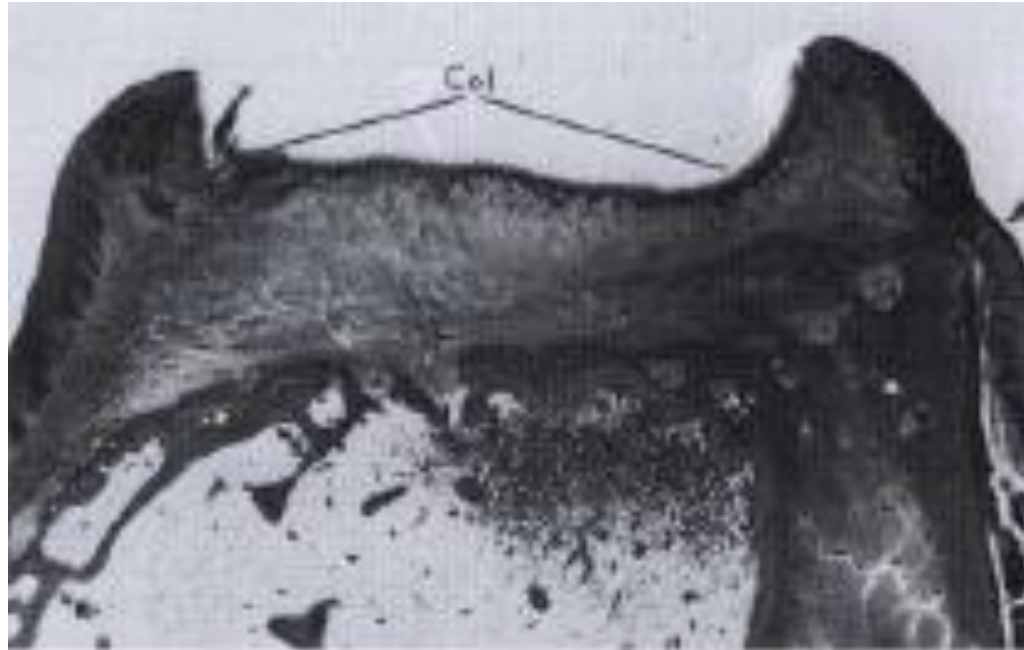
- The interdental gingiva occupies the gingival embrasure, which is the interproximal space beneath the area of tooth contact.
- The interdental gingiva can be **pyramidal** or have a "**col**" shape. In the former, the tip of one papilla is located immediately beneath the contact point;
- **Col** presents a valley-like depression that connects a facial and lingual papilla and conforms to the shape of the interproximal contact.

Dr. Parag Hadge



Copyright © 2002, W.B. Saunders Company

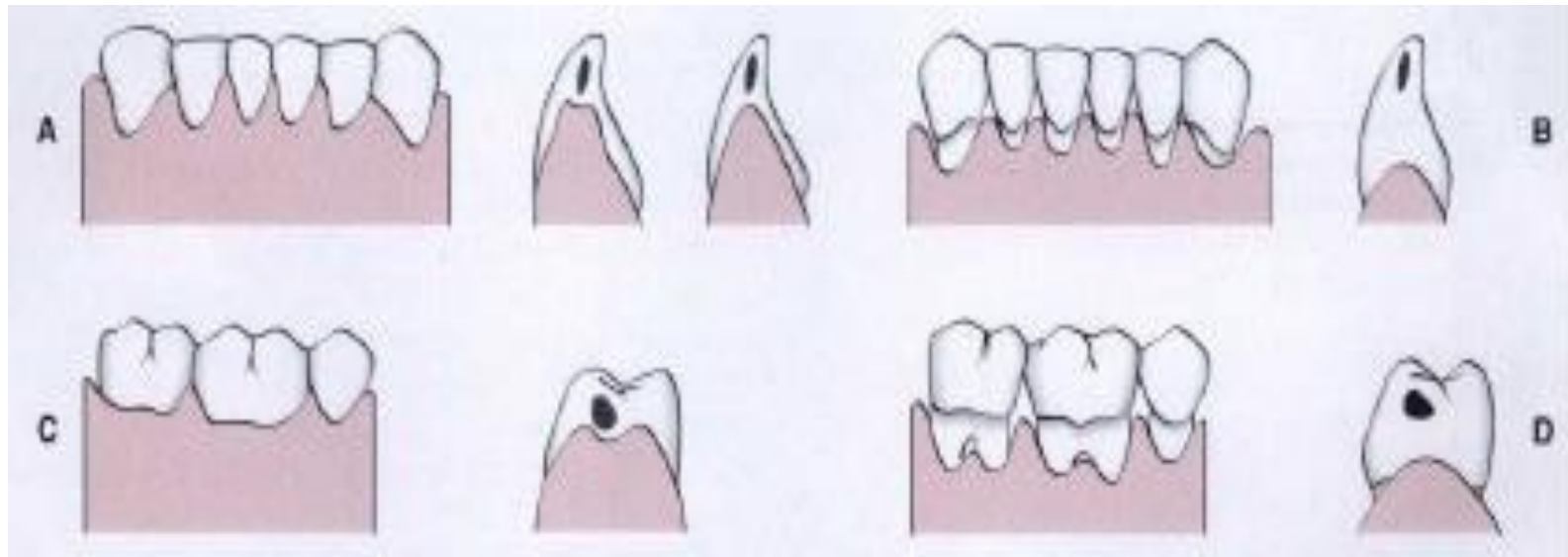
Dr. Parag Hadge



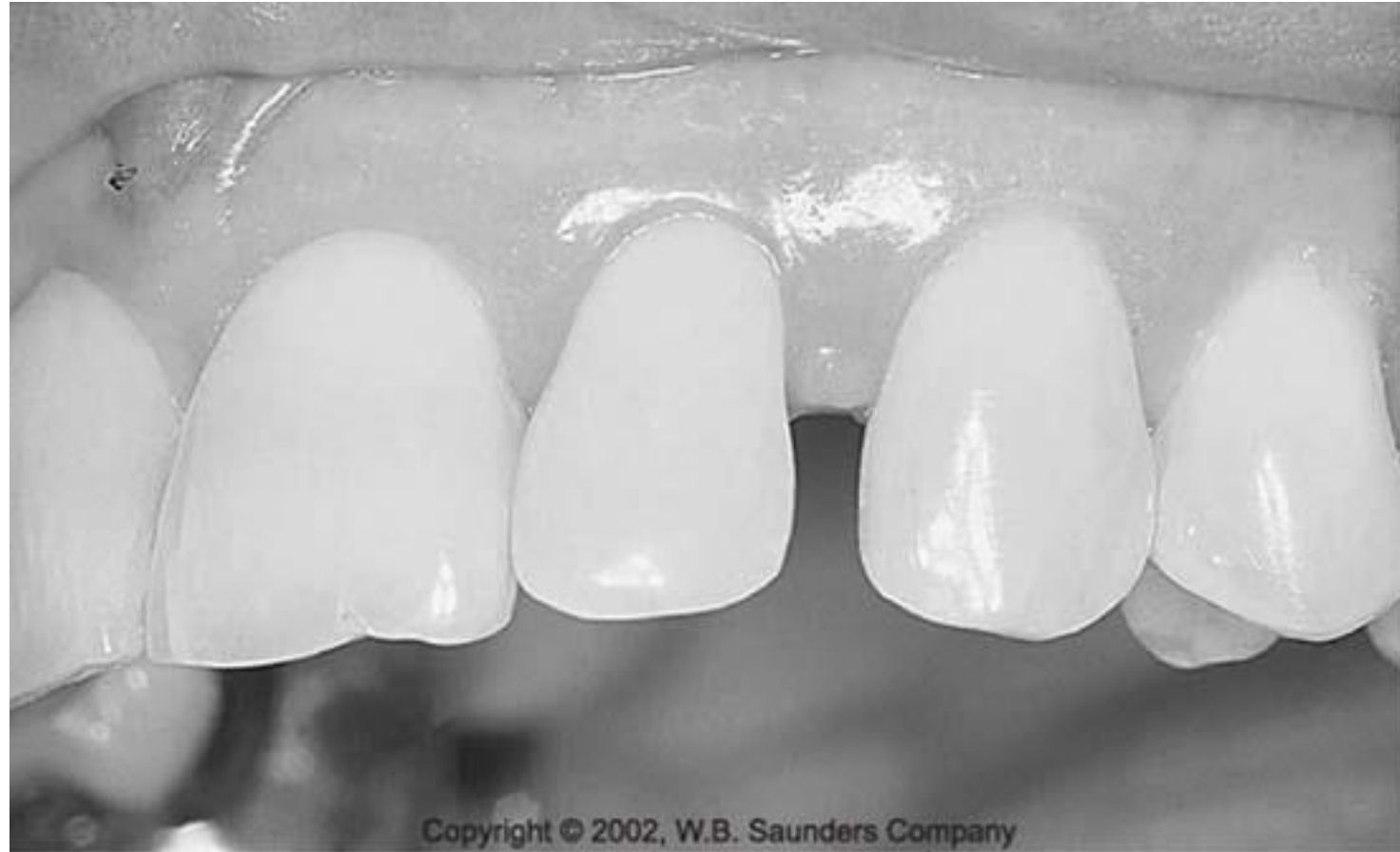Dr. Parag Hadge

- The shape of the interdental gingiva depends on the contact point between the two adjoining teeth and the presence or absence of some degree of recession.
- If a diastema is present, the gingiva is firmly bound over the interdental bone and forms a smooth, rounded surface without interdental papillae.

Dr. Parag Hadge



Dr. Parag Hadge



Dr. Parag Hadge

Gingival Epithelium

Gingival epithelium consists of

- Outer or Oral epithelium
- Sulcular epithelium
- Junctional epithelium

- The **oral epithelium** extends from the mucogingival junction to the tip of the gingival crest and is subdivided into the **free marginal gingiva** and **the attached gingiva**.
- The **sulcular epithelium** lines the gingival sulcus and extends from the tip of the gingival crest to coronal most portion of the junctional epithelium. It is not keratinised.
- The **junctional epithelium** extends from the base of the gingival sulcus to an arbitrary point approximately 1.97mm coronal to the alveolar bone crest and is closely adapted to the tooth surface to form sealing and attachment functions.

CLINICAL FEATURES OF HEALTHY GINGIVA

Dr. Parag Hadge

Colour

- The colour of healthy gingiva is normally described as coral pink.
- It is dependent on:
 - Vascular supply
 - Thickness of epithelium
 - Degree of keratinization
 - Presence of pigment containing cells.

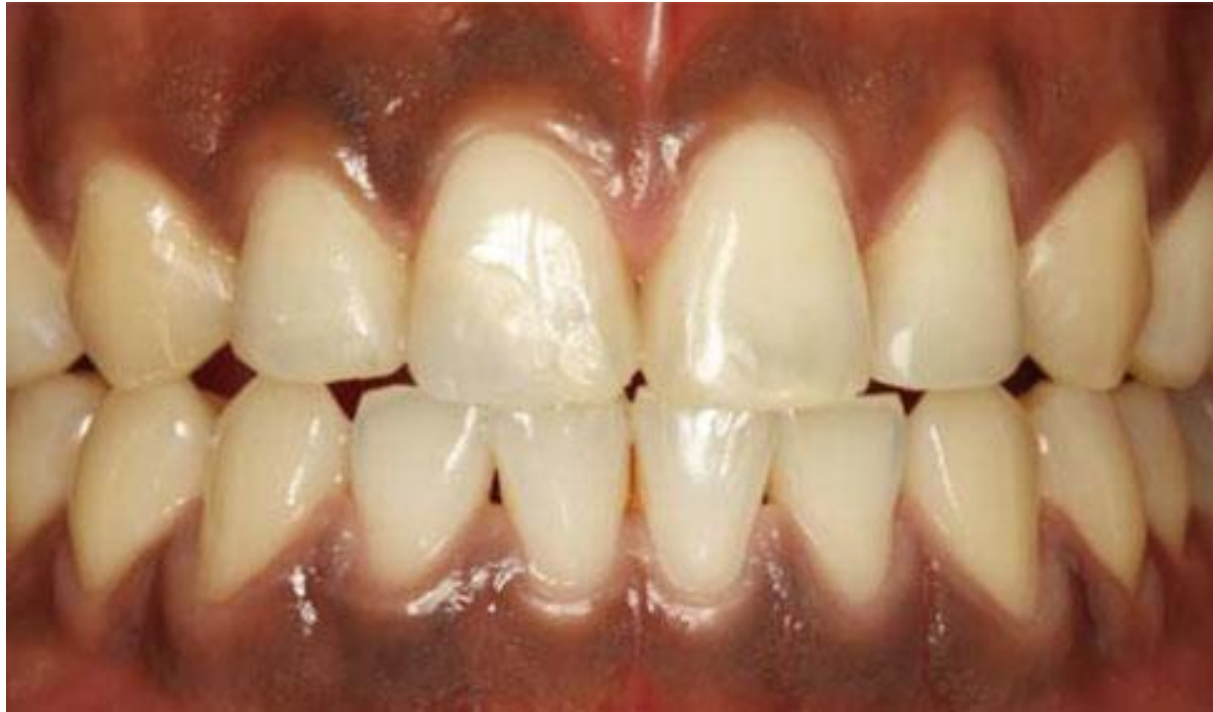- The attached gingiva is demarcated from the adjacent alveolar mucosa on the buccal aspect by a clearly defined mucogingival line.
- The alveolar mucosa is red, smooth, and shiny rather than pink and stippled.
- This difference is due to the epithelium of the alveolar mucosa being thinner, nonkeratinized and contains no rete pegs.
- The CT of the alveolar mucosa is loosely arranged, and the blood vessels are more numerous.

Physiologic Pigmentation

- Melanin, a non haemoglobin- derived brown pigment, is responsible for the normal pigmentation of skin, gingiva, oral mucosa.
- It is present in all individuals but absent in albinos and prominent in blacks.

According to Dummett (1946), the distribution of oral pigmentation in black individuals-

1. Gingiva – 60%
2. Hard palate
3. Mucous membrane
4. Tongue



Dr. Parag Hadge

- It may appear in the gingiva as early as 3 hours after birth and often is the only evidence of pigmentation.

Size

- The size of the gingiva corresponds to the sum total of the bulk of the **cellular and intercellular** elements and their vascular supply.
- Alteration in size is a common feature of gingival disease.

Contour

- The contour of the gingiva varies considerably and depends on:
 - Shape of the teeth
 - Alignment in the arch
 - Location of the area of proximal contact
 - Size of the area of the proximal contact
 - Dimensions of the facial and lingual gingival embrasures.

- scalloped - on the facial and lingual surfaces.
- straight line - teeth with relatively flat surfaces.
- pronounced mesiodistal convexity or teeth with labial version- accentuated and the gingiva is located farther apically.
- lingual version - the gingiva is horizontal and thickened.

Becker et al, 1997 classified gingival scalloping as

1. Flat
2. Scalloped
3. Pronounced

Shape


- Shape of IDG governed by the:
 - Contour of the proximal tooth surface
 - Location of contact point
 - Shape of gingival embrasure
- When the proximal surfaces of the crowns are relatively flat FL the roots are close together, the interdental bone is thin MD and the gingival embrasures and IDG are narrow MD.

Consistency

- The gingiva is **firm and resilient** and with the exception of the movable free margin, tightly bound to the underlying bone.
- The collagenous nature of the LP and its contiguity with the mucoperiosteum of the alveolar bone determine the firmness of the AG.
- The gingival fibres contribute to the firmness of the gingival margin.

Surface texture

- The gingiva presents a textured surface similar to an **orange peel** and is referred to as being **stippled**.
- The AG and central portion of IDG is stippled, MG is not.
- The pattern and extent of stippling varies among individuals and different areas of the same mouth.
- Stippling varies with age.
- It is absent in infancy, appears in some children at about 5 years of age, increases until adulthood and frequently begins to disappear in old age.

- 
- Microscopically stippling is produced by alternate rounded protuberances and depressions in the gingival surface.
 - The papillary layer of the CT projects into the elevations, and the elevated and depressed areas are covered by stratified squamous epithelium.
 - The degree of keratinization and the prominence of stippling appear to be related.

- Stippling is a form of **adaptive specialization** or reinforcement for function.
- It is a feature of healthy gingiva.
- Reduction or loss of stippling is a common sign of gingival disease.
- When the gingiva is restored to health the stippled appearance returns.
- It increases when the gingiva is stimulated as in tooth brushing.

Position

- The position of gingiva refers to the level at which the gingival margin is attached to the tooth (apparent position).
- The level of epithelial attachment to tooth is referred to as the actual position

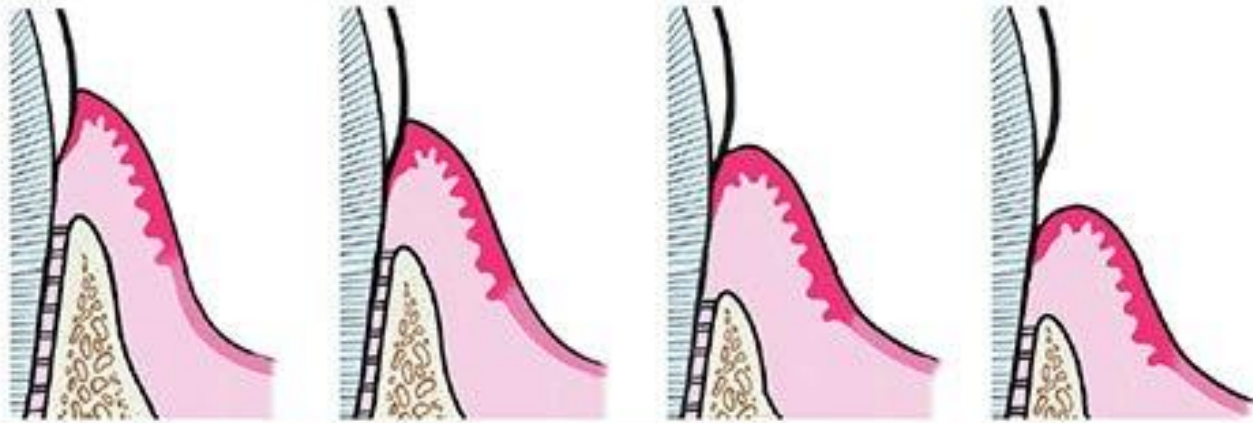


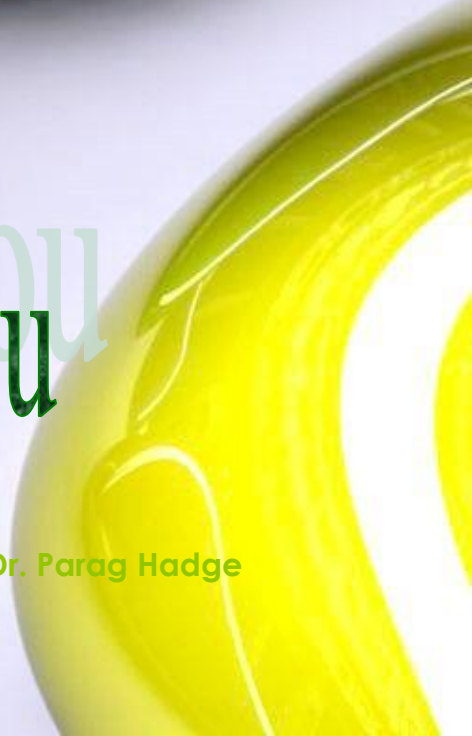Figure 1: Passive Eruption stages (Gottlieb and Orban)

Stage I – dentogingival junction is located on enamel.

Stage II – dentogingival junction is located on enamel, as well as cementum.

Stage III – dentogingival junction is located entirely on cementum, extending coronally to the CEJ.

Stage IV – dentogingival junction is located entirely on cementum and the root surface is exposed, resulting in gingival recession.



Thank You
Thank You

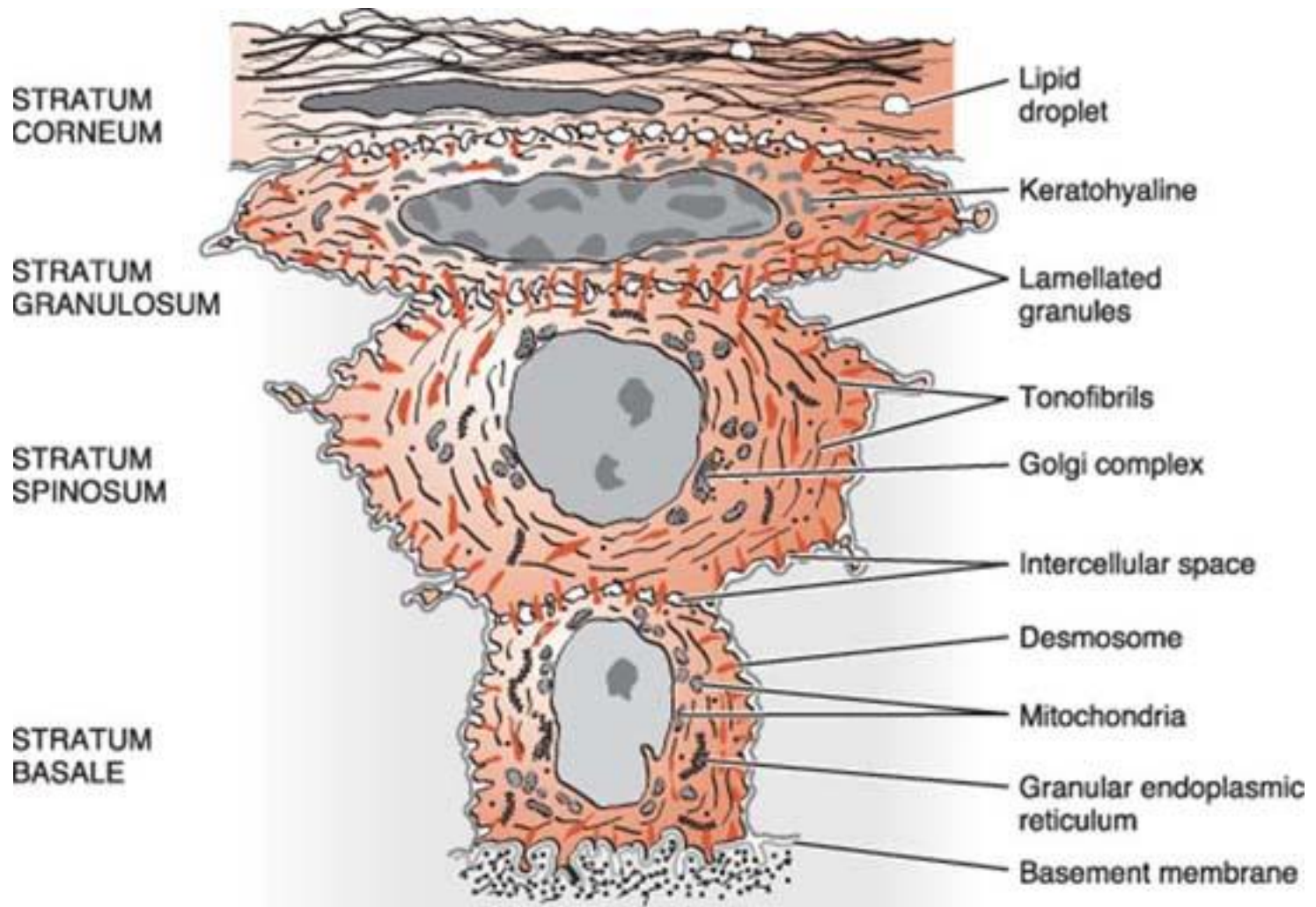
Dr. Parag Hadge

Microscopic features of Gingiva

Dr. Parag Hadge

- Stratified squamous epithelium
- Connective tissue

- The oral epithelium is a stratified squamous keratinizing epithelium composed of four layers, namely
 1. stratum basale (basal layer),
 2. stratum spinosum (prickle cell layer),
 3. stratum granulosum (granular layer) and
 4. stratum corneum (cornified layer).
- On average the oral epithelium of the gingiva is between 0.2 and 0.3 mm in thickness.



Copyright © 2002, W.B. Saunders Company

Dr. Parag Hadge

- The principal cell - the **keratinocyte**.
- Other cells found in the epithelium are the clear cells or nonkeratinocytes, which include the Langerhans cells, Merkel cells, and melanocytes.

- The main function of the gingival epithelium is to protect the deep structures while allowing a selective interchange with the oral environment.
- This is achieved by proliferation and differentiation of the keratinocyte.

- **Proliferation**- mitosis
- **Differentiation** – keratinization - sequence of biochemical and morphologic events that occur in the cell as it migrates from the basal layer.
- **progressive flattening** of the cell with an increasing prevalence of tonofilaments and intercellular junctions
- **production of keratohyaline granules** and
- the **disappearance of the nucleus.**

Stratum Basale

- cuboidal, sometimes cylindrical
- Basal cell possess the ability of mitosis and the - **stratum germinativum** and can be considered as the progenitor compartment of the epithelium.
- attached to the underlying basal lamina - **hemidesmosomes**.
- attached laterally to each other via both **gap junctions**

Functions of basal cells

- Protecting underlying structures.
- Produce new epithelial cells.
- Basal cells synthesize and secrete macromolecules that constitute the basal lamina that separates the stratum basale from underlying connective tissue.
- Nutrition.
- Disposal of metabolic by-products.

Stratum Spinosum

- composed of cells that no longer synthesize basal lamina constituents.
- This epithelial layer is characterized at the light microscopic level by apparent “bridges” between adjacent cells.
- 10-20 layers of relatively large, polyhedral cells, desmosomes -cytoplasmic processes gives **“prickly appearance”**.

- The uppermost cells of the stratum spinosum contain numerous dense granules, **keratinosomes** or **Odland bodies**, which are modified lysosomes.
- They contain a large amount of acid phosphatase, an enzyme involved in the destruction of organelle membranes, which occurs suddenly between the granulosum and corneum strata

Stratum granulosum

- flattened cellular elements containing ***keratohyaline granules*** and enzyme containing Odland bodies.

Stratum Corneum

- As the cells approach the outer most layer of the oral epithelium, the stratum corneum, the intercellular process of keratinization nears completion as the cells are transformed into **corneocytes**
- compressed flatly parallel to the surface of the gingiva.

- A complete keratinization process leads to the production of an ***orthokeratinized*** superficial horny layer similar to that of the skin with no nuclei in the stratum corneum and a well-defined stratum granulosum.

- In ***parakeratinized epithelia***, the stratum corneum retains pyknotic nuclei and the keratohyalin granules are dispersed, not giving rise to a stratum granulosum.
- The ***nonkeratinized epithelium*** (although cytokeratins are the major component, as in all epithelia) has neither granulosum nor corneum strata, and superficial cells have viable nuclei

- ❖ **K1**, **K2**, and **K10** to **K12** high intensity in orthokeratinized areas and less intensity in parakeratinized areas.
- ❖ **K6** and **K16**, characteristic of highly proliferative epithelia, and
- ❖ **K5** and **K14**, stratification-specific cytokeratins
- ❖ Parakeratinized areas express **K19**, which is usually absent from orthokeratinized normal epithelia.
- ❖ **K4** and **K13**, the so-called esophageal type cytokeratins, found in sulcular epithelium.

- Other proteins - **keratolinin** and **involucrin**, which are precursors of a chemically resistant structure (the envelope) located below the cell membrane, and
- **filaggrin**, whose precursors are packed into the keratohyalin granules.
- In the sudden transition to the horny layer, the keratohyalin granules disappear and give rise to filaggrin, which forms the matrix of the most differentiated epithelial cell, the **corneocyte**.

Dr. Parag Hadge

Non-keratinocytes


- **Melanocytes** are dendritic cells located in the basal and spinous layers of the gingival epithelium.
- They synthesize melanin in organelles called *premelanosomes* or *melanosomes*.

- **Langerhans cells** are dendritic cells located among keratinocytes at all suprabasal levels.
- modified monocytes derived from the bone marrow.
- They are considered macrophages with possible antigenic properties.
- Langerhans cells have an important role in the immune reaction as antigen-presenting cells for lymphocytes.

- They contain granules (***Birbeck's granules***)
- Recent studies have shown that Birbeck granules take part in transfer of molecules entering the cell via endocytosis
- As the only cells in which enzyme ATPase is coupled to the cell membrane, they are easily identified by detection of ATPase activity.

- **Merkel cells** are located in the deeper layers of the epithelium, harbor nerve endings, and are connected to adjacent cells by desmosomes.
- They have been identified as **tactile perceptors**.

- The epithelium is joined to the underlying connective tissue by a *basal lamina*.
- The basal lamina consists of ***lamina lucida*** and ***lamina densa***.



Epithelial cells

Lamina Lucida

Lamina Densa

Reticular
layer

Dr. Parag Hadge

JUNCTIONAL EPITHELIUM

- The ***junctional epithelium*** consists of a collarlike band of stratified squamous nonkeratinizing epithelium.
- It is three to four layers thick in early life, but the number of layers increases with age to 10 or even 20 layers. These cells can be grouped in two strata: basal and suprabasal.
- The length of the junctional epithelium ranges from 0.25 to 1.35 mm.

Dr. Parag Hadge

- The junctional epithelium is formed by the confluence of the oral epithelium and the reduced enamel epithelium during tooth eruption.
- the junctional epithelium is completely restored after pocket instrumentation or surgery.
- It expresses the stratification-specific cytokeratins **K5** and **K14**
- lack of expression of **K6** and **K16**, which is usually linked to highly proliferative epithelia, although the turnover of the cells is very high.

- The junctional epithelium is attached to the tooth surface (epithelial attachment) by means of an **internal basal lamina** and to the gingival connective tissue by an **external basal lamina**.

- JE has a very **high turnover rate**
- BL differs from other BL opposed to connective tissue in that **type IV collagen is absent.**

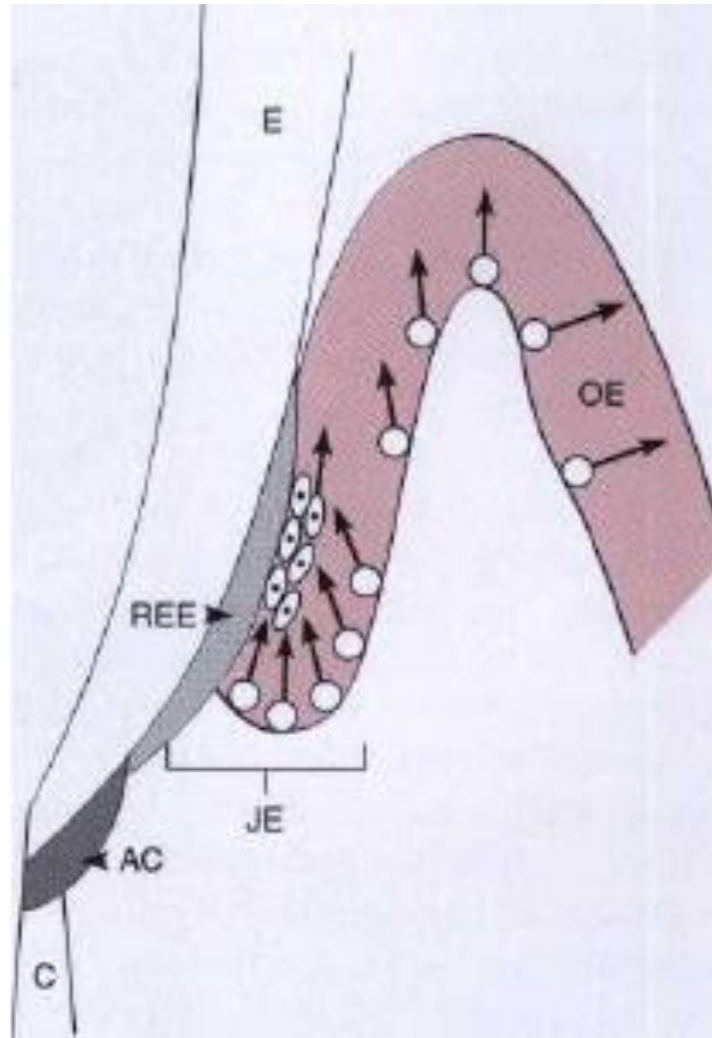
- One of the remarkable properties of the JE is that it **readily regenerates** from the adjacent oral or sulcular if it is damaged or surgically excised.
- The new JE has all the characteristics of the **original tissue**, including the same types of cytokeratins and an attachment to the tooth that is indistinguishable from the original one.

- The attachment of the junctional epithelium to the tooth is reinforced by the **gingival fibers**, which brace the marginal gingiva against the tooth surface.
- For this reason, the junctional epithelium and the gingival fibers are considered a functional unit, referred to as the **dentogingival unit**.

Development of the Gingival Sulcus

- When the tooth penetrates the oral mucosa, the **reduced enamel epithelium** unites with the **oral epithelium** and transforms into the **junctional epithelium**.
- As the tooth erupts, this united epithelium condenses along the crown, and the ameloblasts, which form the inner layer of the reduced enamel epithelium, gradually become squamous epithelial cells.

Dr. Parag Hadge



Dr. Parag Hadge

- The junctional epithelium is a continually self renewing structure with mitotic activity occurring in all cell layers.
- The regenerating epithelial cells move toward the tooth surface and along it in a coronal direction to the gingival sulcus, where they are shed.
- The migrating daughter cells provide a continuous attachment to the tooth surface.

Renewal of Gingival Epithelium

- The oral epithelium - continuous renewal. Its thickness is maintained by a balance between new cell formation in the basal and spinous layers and the shedding of old cells at the surface. The mitotic activity exhibits a 24-hour periodicity, highest -morning and lowest - evening
- The mitotic rate is higher in nonkeratinized areas and is increased in gingivitis, without significant gender differences.

Cuticle

- **Developmental** - during tooth development- REE, Coronal cementum, Dental Cuticle
- **Acquired** – from exogenous origin such as saliva, bacteria, calculus and surface stains

Gingival Sulcular Fluid (GCF)

Dr. Parag Hadge

Gingival Connective Tissue

Dr. Parag Hadge

- Connective tissue of gingiva – **Lamina Propria**
- **Papillary layer**- papillary projections between rete pegs
- **Reticular layer**- contiguous with the periosteum

- Collagen Fibres 60%
- Fibroblasts 5%
- Blood vessels, nerves and Marix 35%

Gingival Fibers

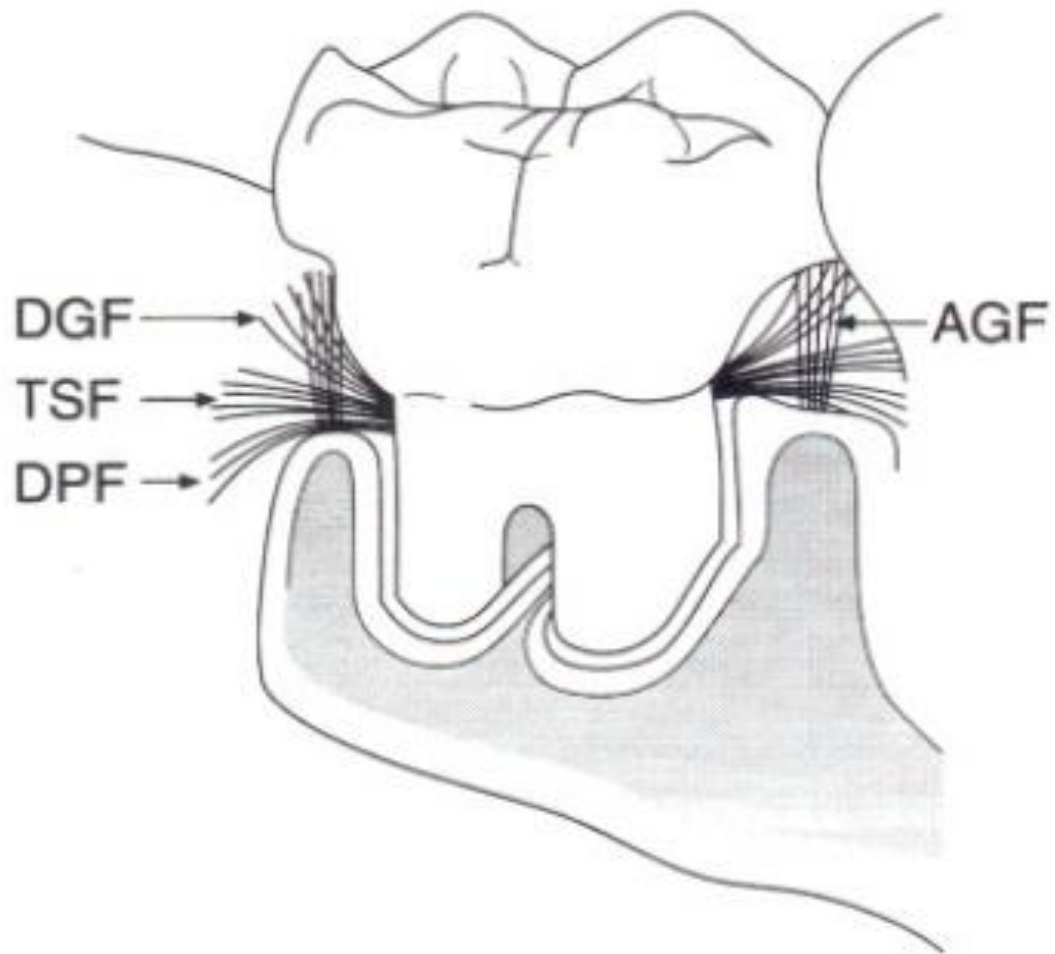
- The gingival tissues attach to the root surface at or below the cemento-enamel junction via fiber insertion into the cementum of the root surface which lies coronal to the alveolar crest.
- These fibres are classified into various groups based on their location, origin and insertion. (***Schluger et al., 1990***)

The **Primary group** includes: (*R. Page et al 1974*)

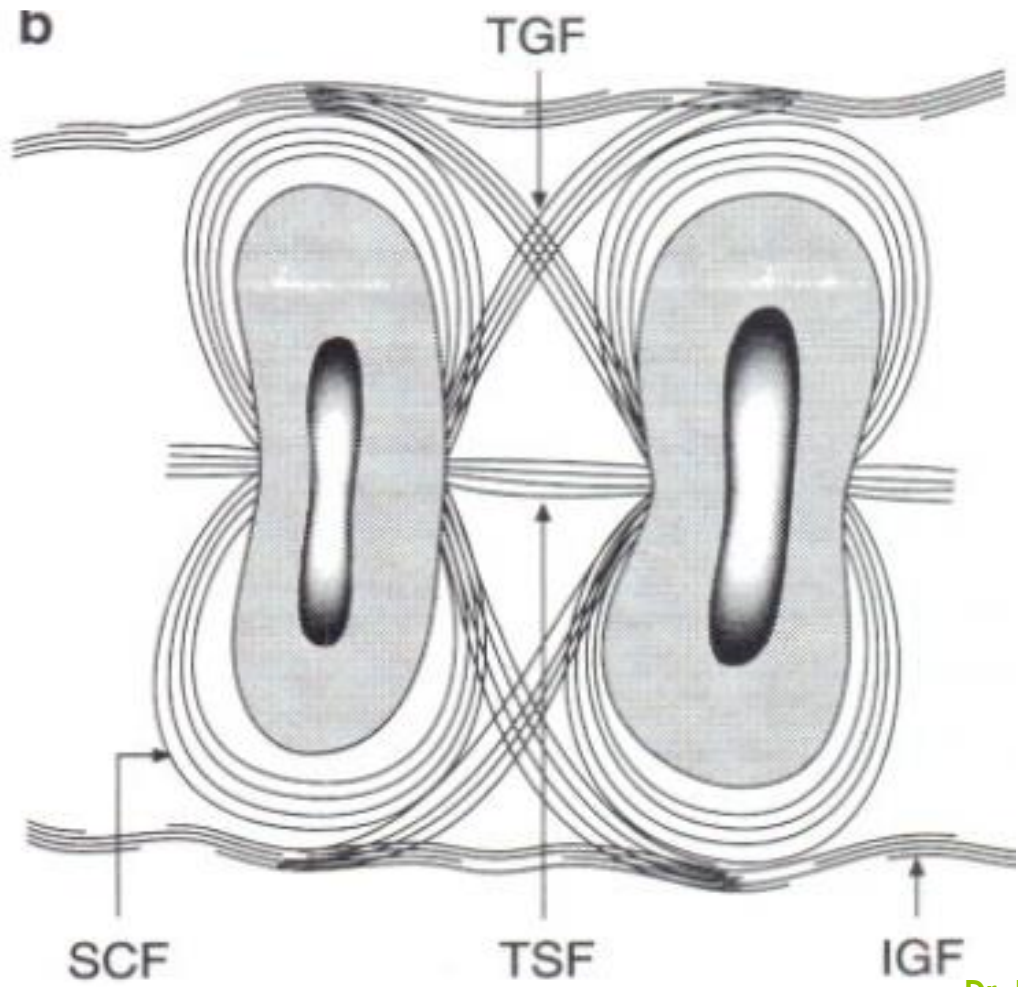
1. Dentogingival fibers
2. Alveologingival fibers
3. Circular fibers
4. Dentoperiosteal fibers
5. Transseptal fibers

The **secondary or minor collagen fiber bundles** are:

- 1.Periosteogingival
- 2.Interpapillary
- 3.Transgingival
- 4.Intercircular
- 5.Intergingival
- 6.Semicircular fibers

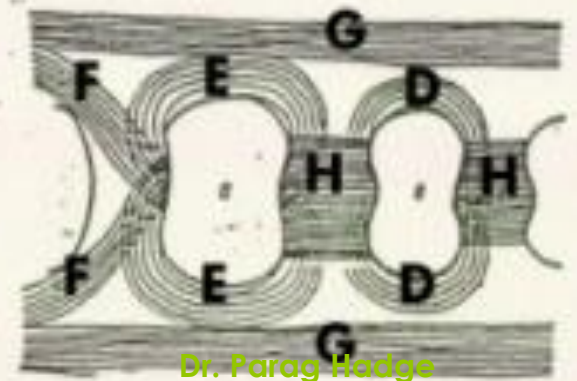
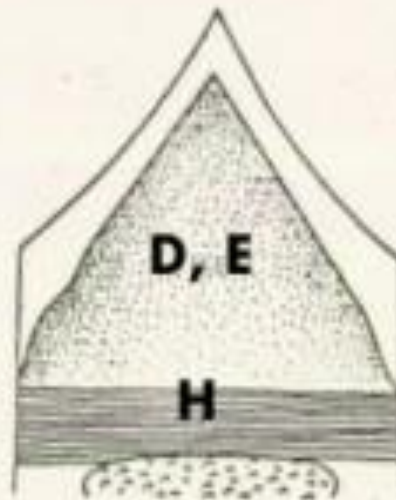
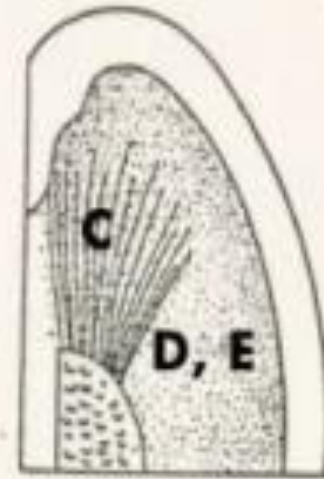
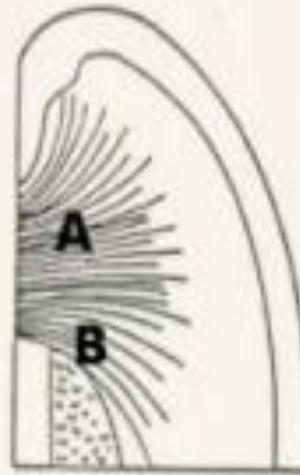


Dr. Parag Hadge



Dr. Parag Hadge

- A. Dentogingival
- B. Dentoperiosteal
- C. Alveologingival
- D. Circumferential
- E. Semicircular
- F. Transgingival
- G. Intergingival
- H. Transseptal



Dr. Parag Hodge

- These gingival fiber groups constitute gingival ligament complex.
- Their functions are:
 1. To brace the marginal gingiva firmly against the tooth.
 2. To provide rigidity necessary to withstand the forces of mastication.
 3. To unite the free marginal gingiva with the cementum of the root and the adjacent attached gingiva.

- Portions of transseptal fibers remain unaffected even in advanced stages of periodontitis, and those that are destroyed appear to reform at a more apical level.

Cells of the Connective Tissue

- Fibroblast
- Mast cells
- Fixed macrophages and Histiocytes
- Adipose cells
- Eosinophils
- T-lymphocytes, B-lymphocytes and plasma cells

Repair

- High turnover rate
- good regenerative capacity
- good healing

Blood Supply

- Microcirculatory tracts – nutrition – drainage – spread of inflammation
 1. Supraperiosteal arterioles
 2. Vessels of Periodontal ligament
 3. Arterioles – from alveolar crest – anastomose with vessels of Periodontal ligament

Lymphatics

- Lymphatic drainage – removes –
 1. excess fluids,
 2. cellular and protein debris,
 3. microorganisms

Innervation

- From nerves of PDL, facial, buccal and palatal nerves
- Meissner-type tactile corpuscles
- Krause type end bulbs – temperature
- Encapsulated spindles



Thank You
Thank You

Dr. Parag Hadge