

SMILE THAT KEEPS US GOING







Consequences of edentuliasim

Deepened
Nasolabial
groove

Sagging of
skin due
to loss of
Muscle tone

Decrease
In attached
mucosa

Decreased
Width &
Height of
bone

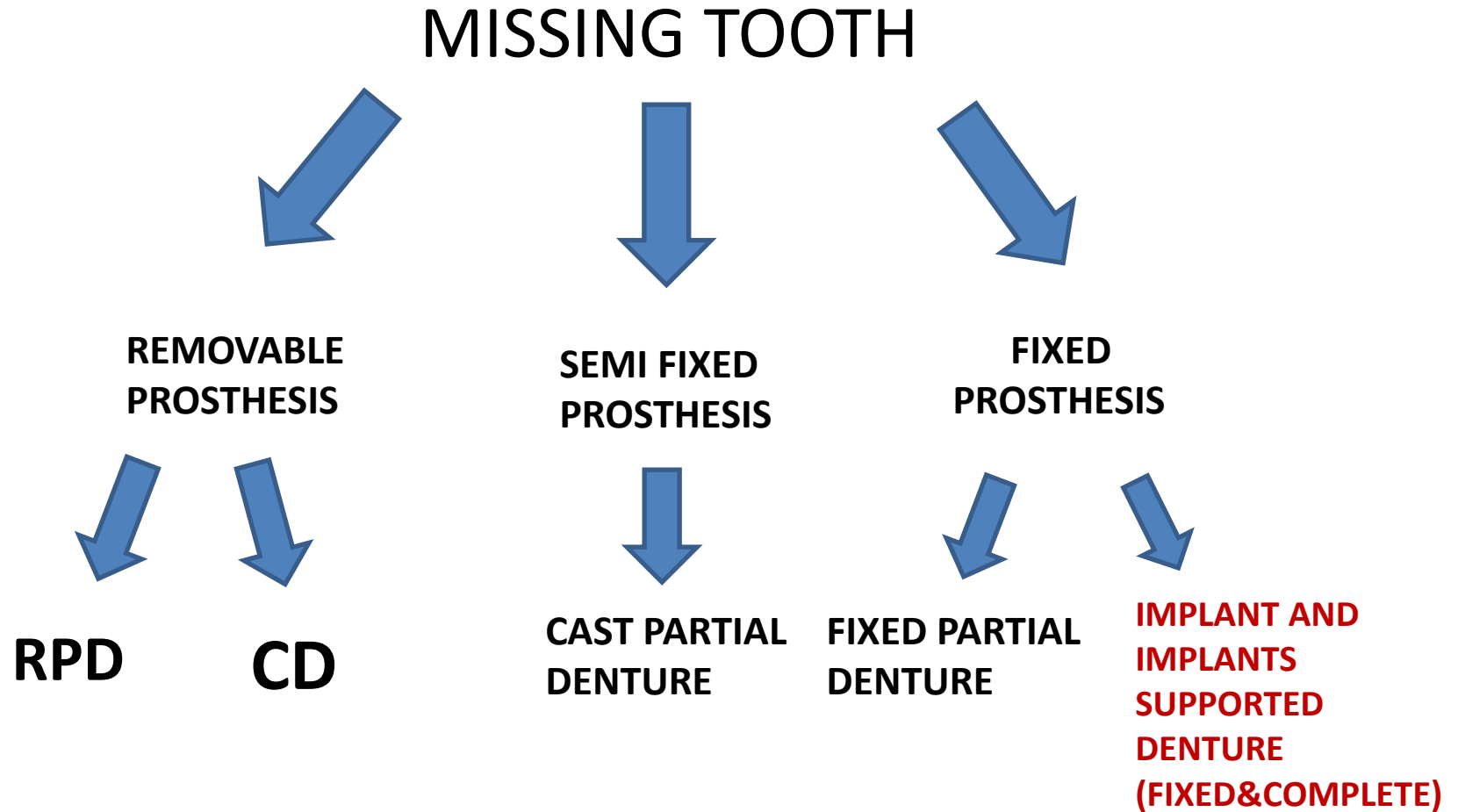
Increased
lip length



Thinning
Of lips

Prognathic
Appearance
Of chin

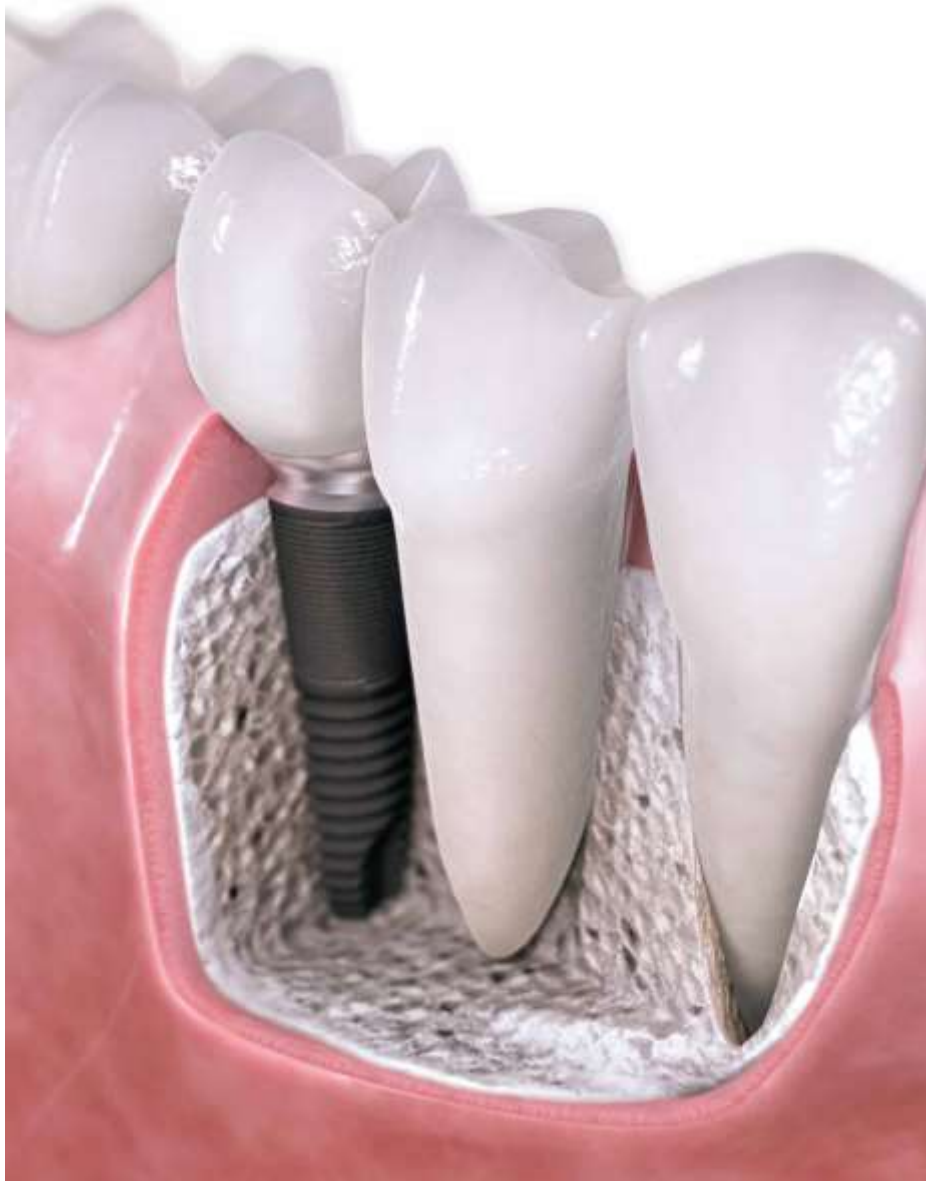TREATMENT CHART





✓ Mr. Gosta Larsson – 1st patient of prof BRÅNEMARK - A 47 year old success

WHAT IS A DENTAL IMPLANT



DEFNITION:

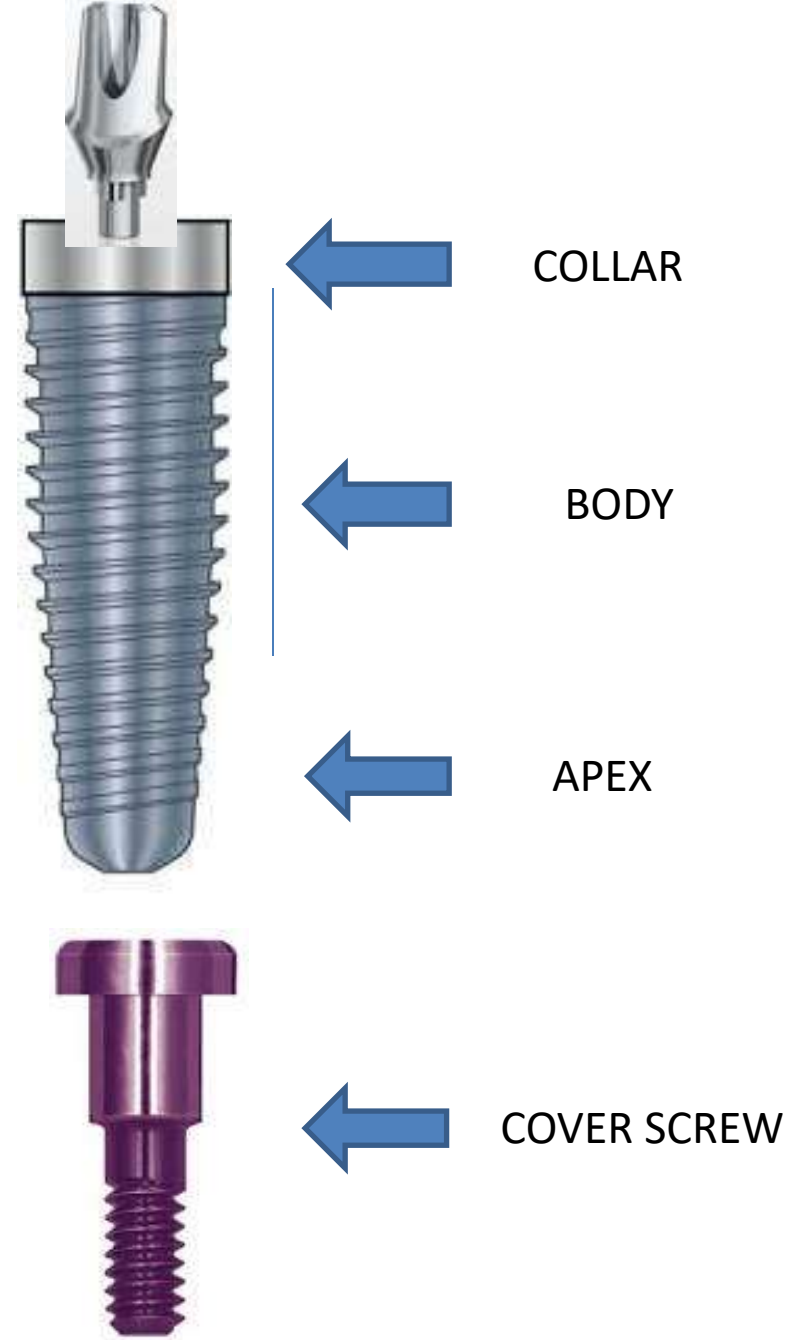
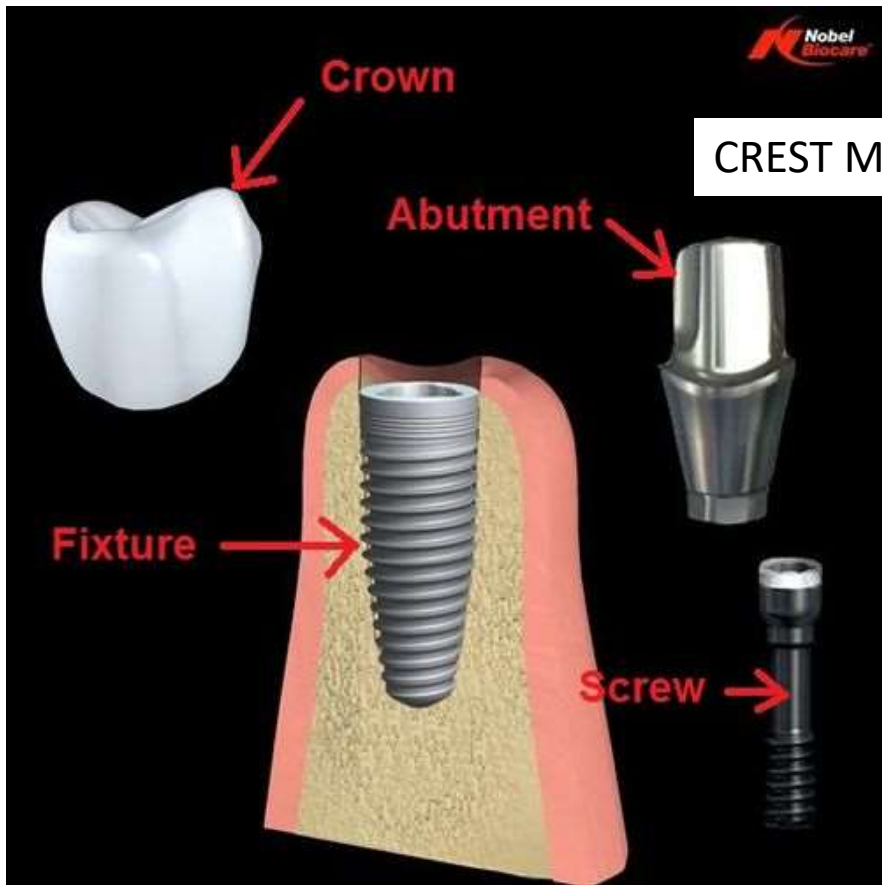
An Endosteal Alloplastic biologically compatible material surgically inserted into the edentulous bony ridge.

CRAINS AN: GLOSSARY OF IMPLANT TERMS , J ORAL IMPLANT 1990

“ENDO” - MEANS **INSIDE**

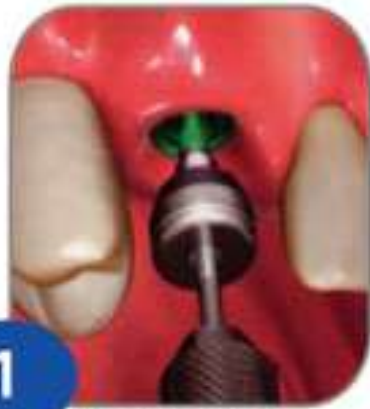“OSTEAL” - MEANS **BONE**

*SOBLONSKY .S, EDITOR ILLUSTRATED
DICTIONARY OF DENTISTRY,
PHILADELPHIA, 1982, WB SAUNDERS.*



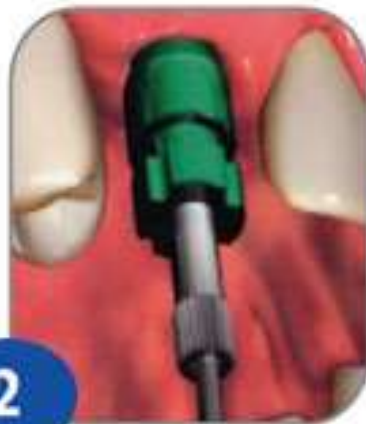PARTS OF DENTAL IMPLANT

PROSTHETIC COMPONENTS



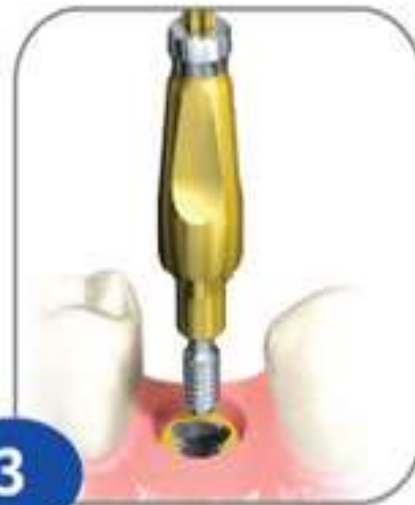1

HEALING CAP



2

IMPRESSION COPING
(Open Tray)



3

IMPRESSION COPING
(Close Tray)



4

IMPLANT REPLICA



5

IMPLANT ABUTMENT

ANTI ROTATIONAL COMPONENTS

INTERNAL HEX

EXTERNAL HEX



MORE LIKE ENDO TREATED TOOTH WITH A POST

MORE CHANCES OF ABUTMENT LOOSENING



**Internal hex for secure
accurate and reliable
abutment positioning**

CONICAL CONNECTION

BEST ANT ROTATIONAL
DESIGN RECOMEMDED



MULTIPLE OPTIONS FOR
ABUTMENT PLACEMENT

PLATFORM SWITCHING
Lazzara and Porter in 2006



EQUAL DISTRIBUTION
OF FORCES AND
SUPERIOR BENDING
TEST
WANG et al 2010

CREST MODULE AND ITS CLINICAL SIGNIFICANCE

- Crest module is that portion of a two-piece metal dental implant, designed to hold the prosthetic components in place and to create a transition zone to the load bearing implant body.

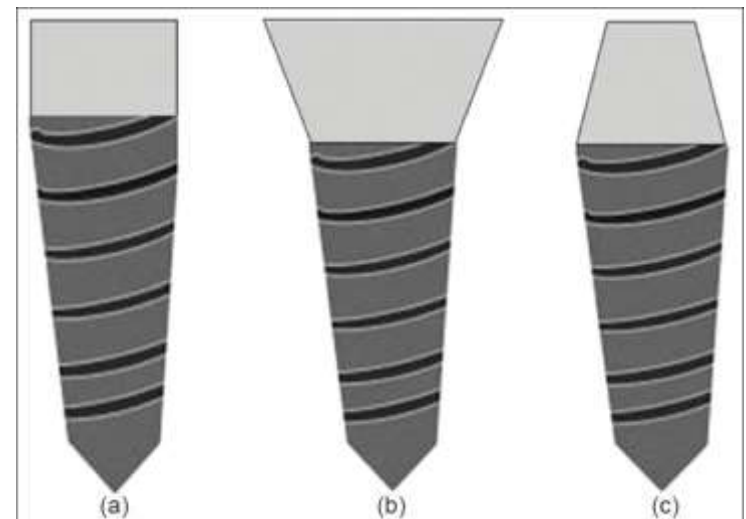
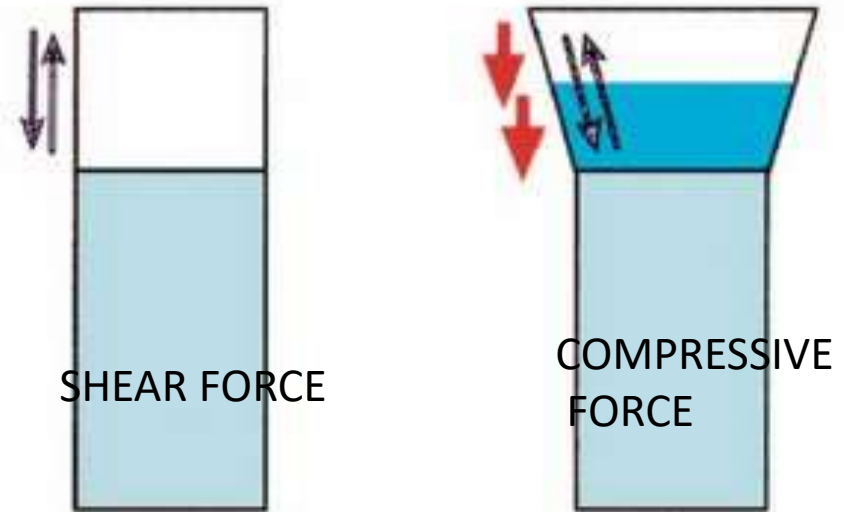
Mosby's Dental Dictionary, 2nd

Amsterdam: Elsevier; 2008

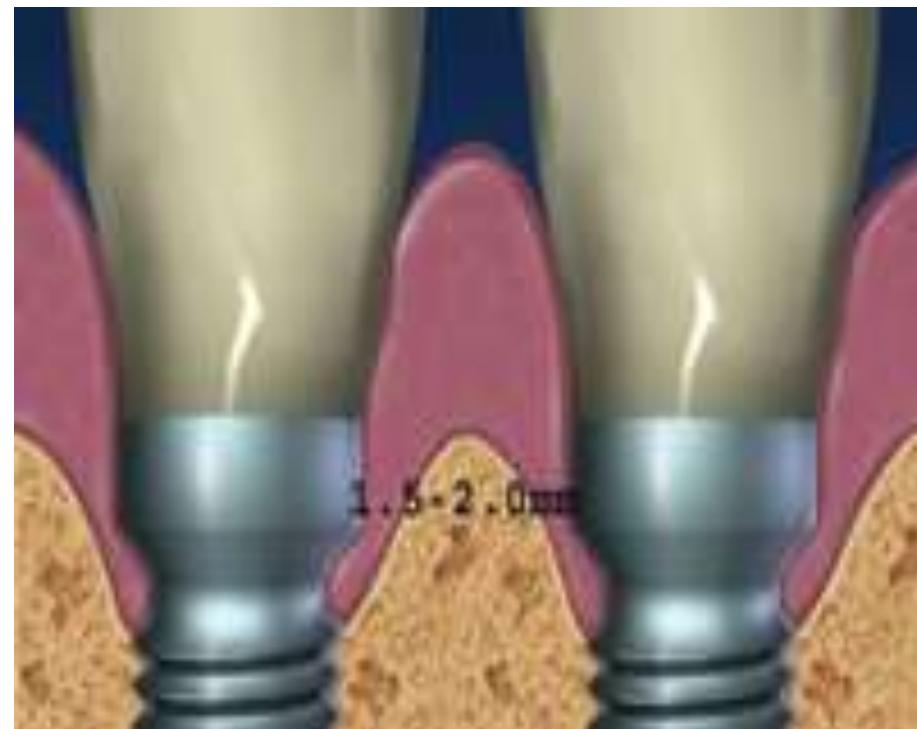
- where the highest amount of bone stress is concentrated.
- Subsequently, its design, position in relation to the alveolar crest, and an abutment implant interface being primary reasons for the tissue breakdown.

Misch et al 2002 JP

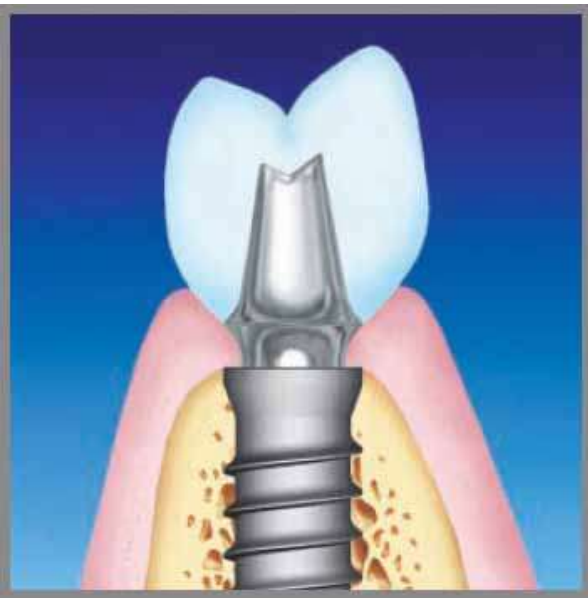CREST MODULE



- There are as many as 6 different possible hypothesis stated for marginal bone loss
 - 1) periosteal reflection,
 - 2) surgical trauma,
 - 3) occlusal overload,
 - 4) peri-implantitis,
 - 5) microgap,
 - 6) biological width, for which an implant crest module also plays a pivotal role (**Misch et al 2002**)
- The crestal bone loss further leads to an increased risk of peri-implantitis, shrinkage of tissue and poor cosmetic results.
- 0.9MM TO 1.6MM – YEAR
- 0.05 TO 0.13MM SUBSEQUENT YEARS



Platform Switching: A New Concept in Implant Dentistry for Controlling Postrestorative Crestal Bone Levels



IJPRD 26:9~17,2006.

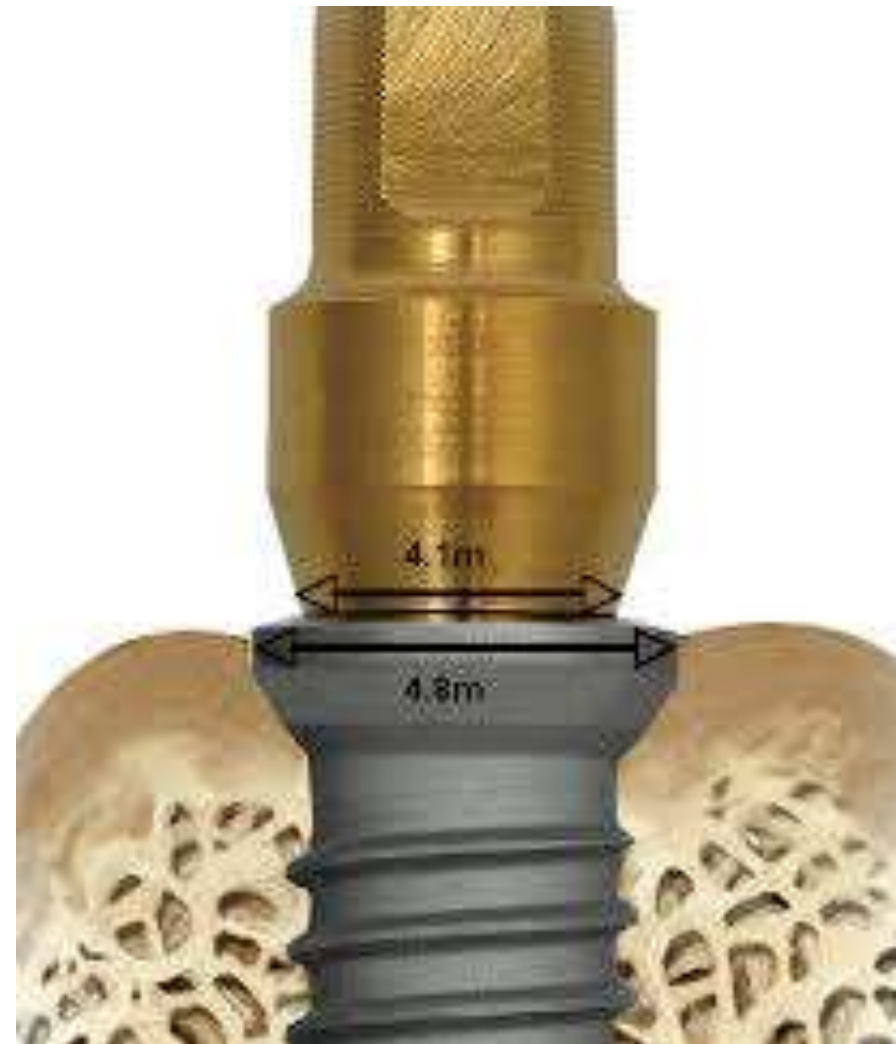*Richard J. Lazzara, DDS, MScD**

*Stephan S. Porter, DDS, MSD, MS**

Platform switching facilitates an increase in residual crestal alveolar bone volume around the neck of an implant, repositions the papilla to a more esthetic and an apposite level, reduces the mechanical stress in the crestal alveolar bone area and assists in enhancing the vascular supply to hard and soft tissue in case of reduced interdental space.


This concept however, does not increase the distance between an implant abutment junction and an alveolar crestal bone, thereby having no protective effect on the microgap, which may encase microflora

Degidi et al2006



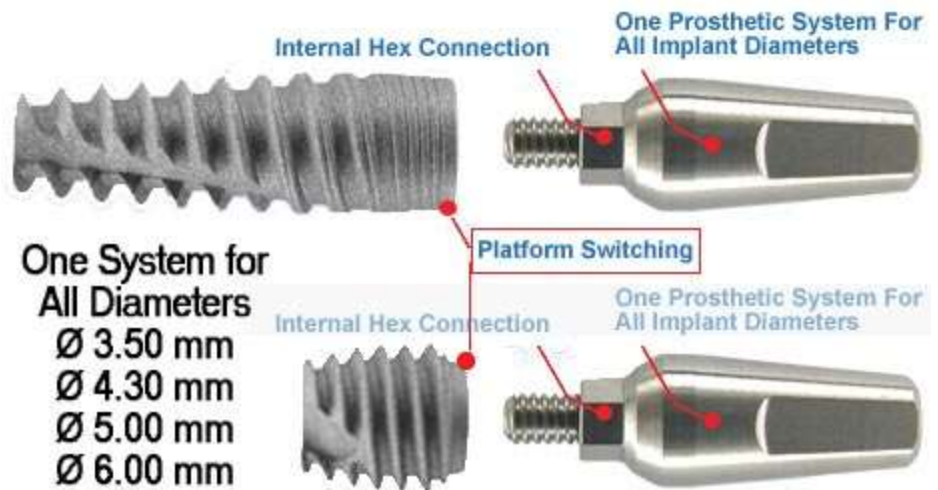
Fickl S et al 2010 observed that, in platform switched implants, an implant-abutment junction is made to move inward from an implant shoulder and further away from the bone; shifting the inflammatory cell infiltrate to the central axis of an implant and away from the adjacent crestal bone, thereby limiting crestal bone remodelling.

This was also confirmed in studies by **Cappiello et al 2007** and **Hürzeler et al 2008**



Maeda et al 2007 in a finite element analysis revealed that, platform switching configuration reduced the shear stress at the bone-implant interface, but increased the stress in abutment or the abutment screw.

Thereby, from a biologic standpoint, it was observed to be efficacious to shift an inevitable microgap of an implant-abutment junction, which is always encircled by an inflammatory cell, infiltrate away from the outer edge of an implant and adjoining bone by formation of a healthy connective tissue

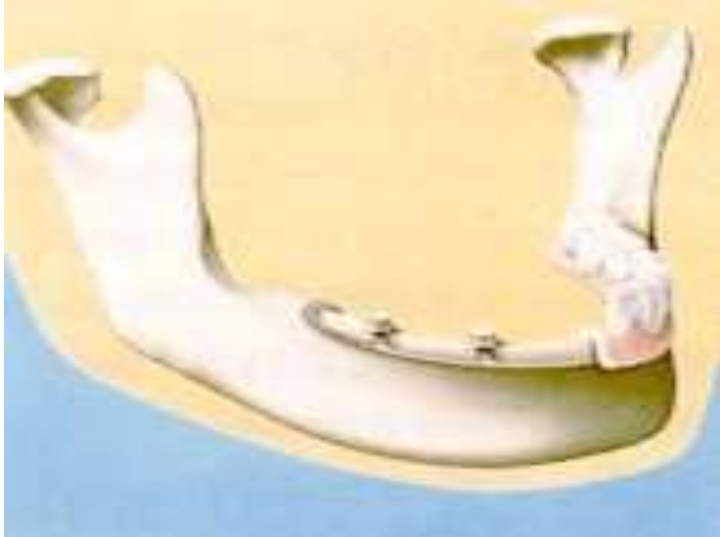

CLASSIFICATION OF DENTAL IMPLANTS

- ✓ BASED ON IMPLANT DESIGN
- ✓ BASED ON ATTACHMENT MECHANISM
- ✓ BASED ON MACROSCOPIC IMPLANT DESIGN
- ✓ BASED ON THE MATERIALS & SURFACE OF IMPLANTS (MICROSCOPIC)
- ✓ BASED ON SURGICAL PLACEMENT
- ✓ BASED ON RESTORATION OF IMPLANTS

**BASED ON IMPLANT
DESIGN**

SUBPERIOSTEAL IMPLANTS



❖ GOES UNDER THE PERIOSTEUM AND LIES ON TOP OF THE JAW BONE.

❖ STABILITY OBTAINED AROUND THE LATERAL BORDERS OF THE LOWER JAW BONE.

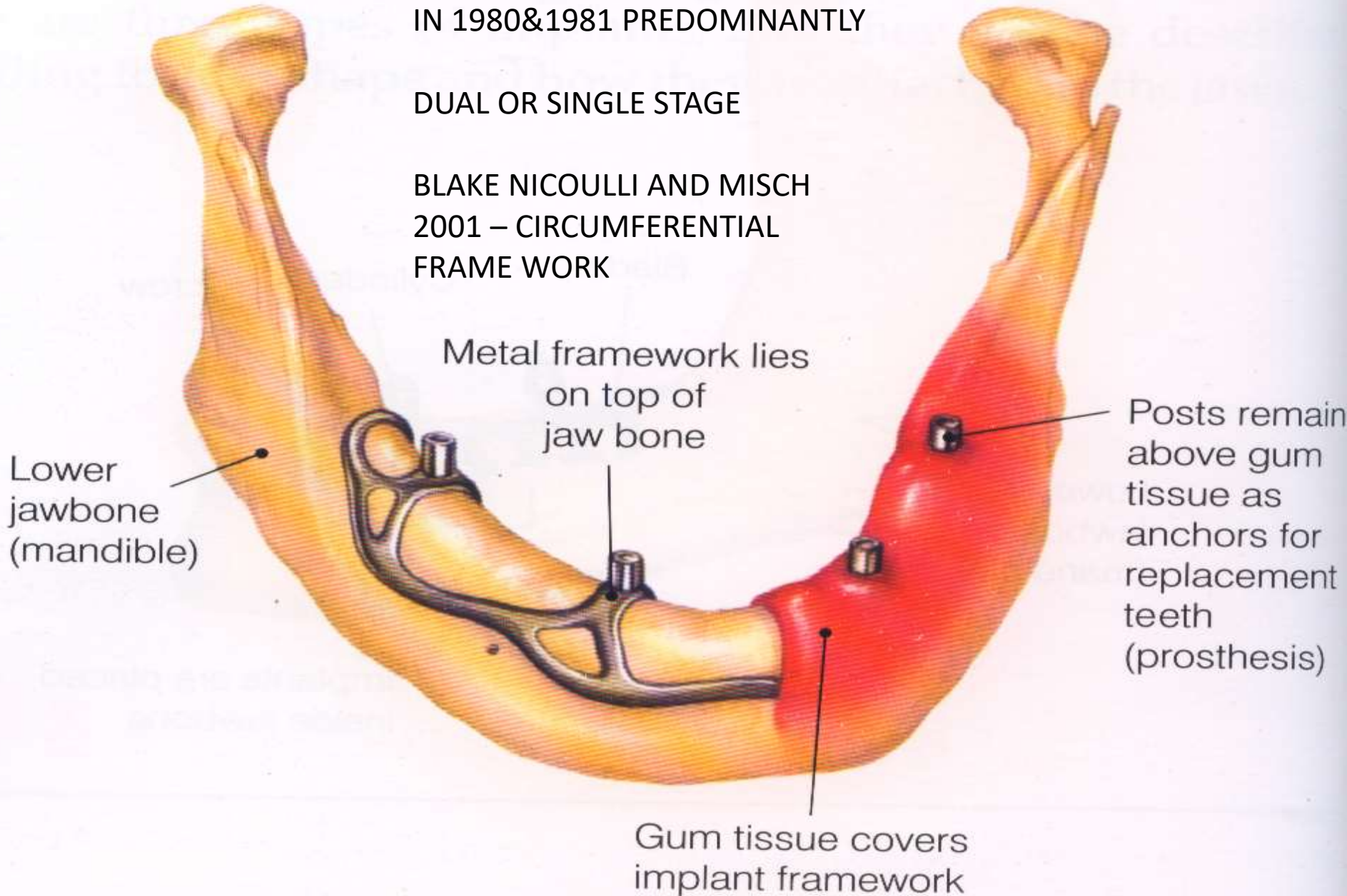


SUPERIOSTEAL IMPLANT

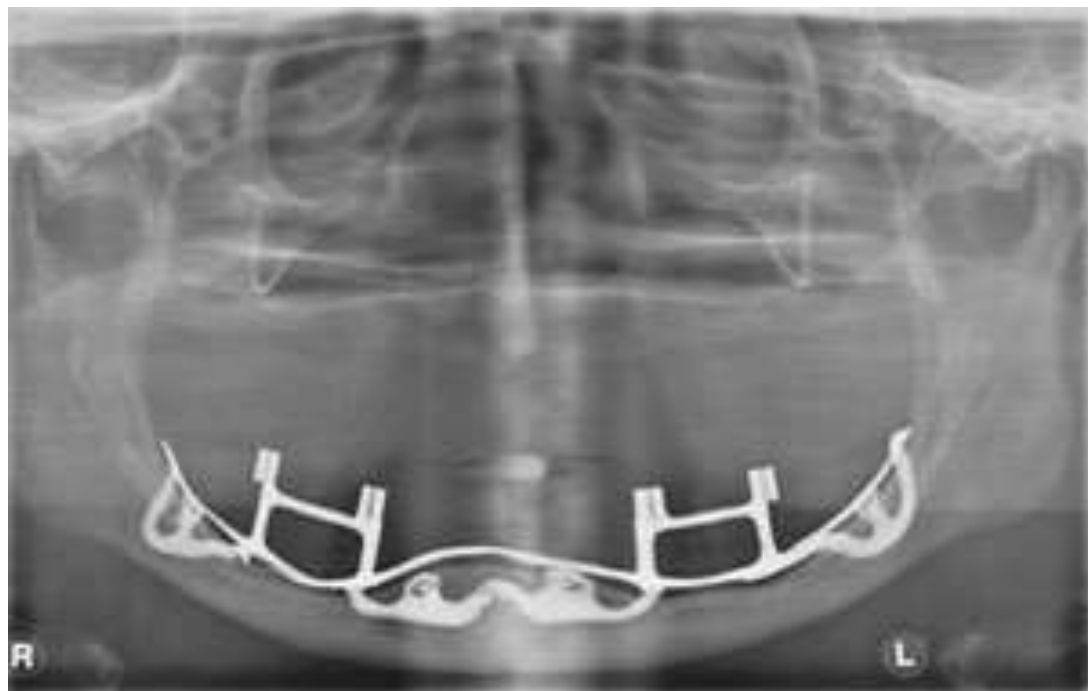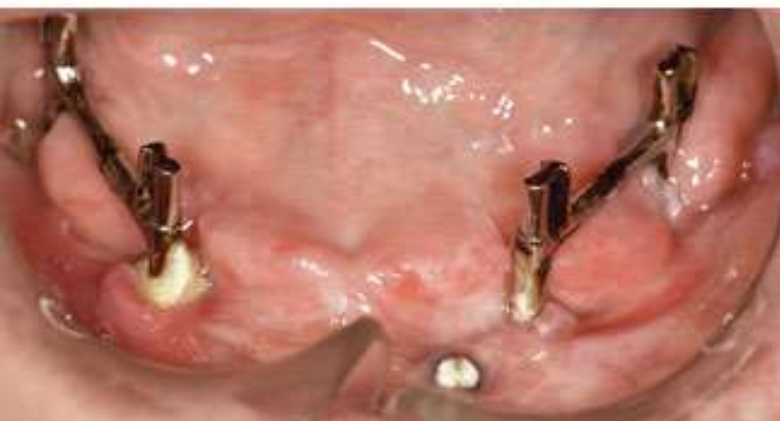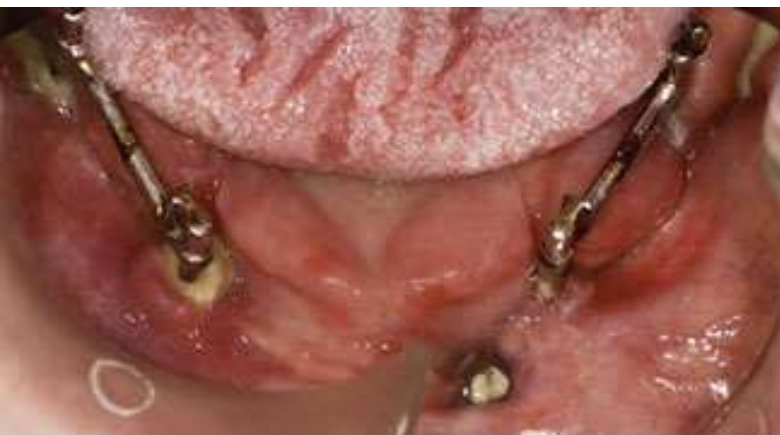IN 1980&1981 PREDOMINANTLY

DUAL OR SINGLE STAGE

BLAKE NICOULLI AND MISCH
2001 – CIRCUMFERENTIAL
FRAME WORK



A 30 yr Old follow up case
From south africa



British Dental Journal


Published online: 13 January 2012 | doi:10.1038/sj.bdj.2012.6

Subperiosteal implants

H. Beddis¹, S. Lello¹, J. Cunliffe¹ & P. Coulthard¹


TRANSOSSEOUS IMPLANTS

❖ IN SEVERELY
RESORBED CASES.



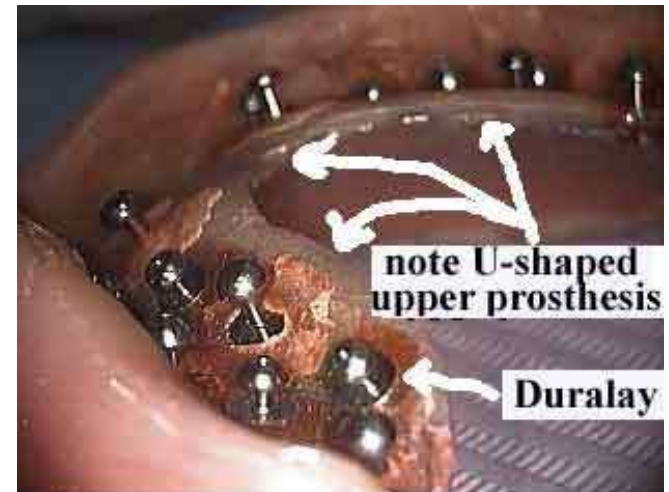
❖ PENETRATES THE JAW
BONE TO EMERGE ON THE
OPPOSITE SIDE.

❖ ONLY FOR LOWER JAW.



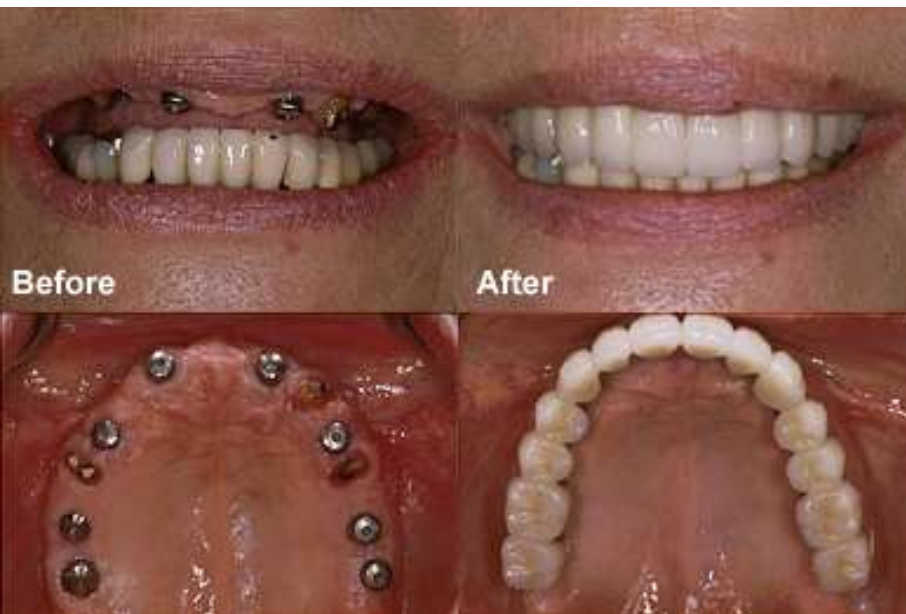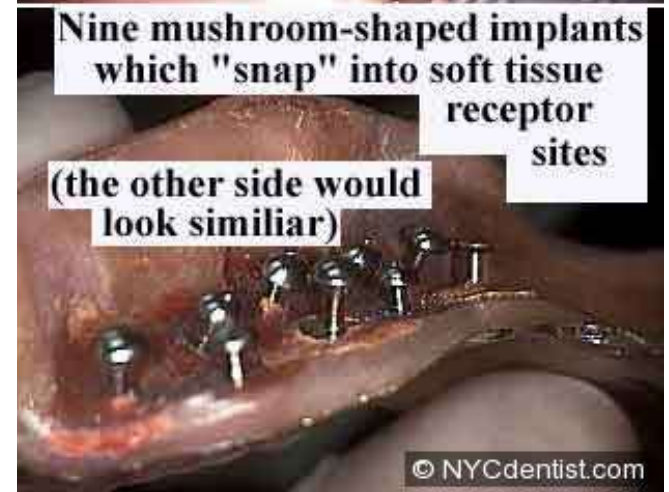INTRA MUCOSAL IMPLANTS

Not UFO's! Its a Panorex of Intramucosal Implants. This is an effective and simple way to provide significant retention to a maxillary removable prosthesis.

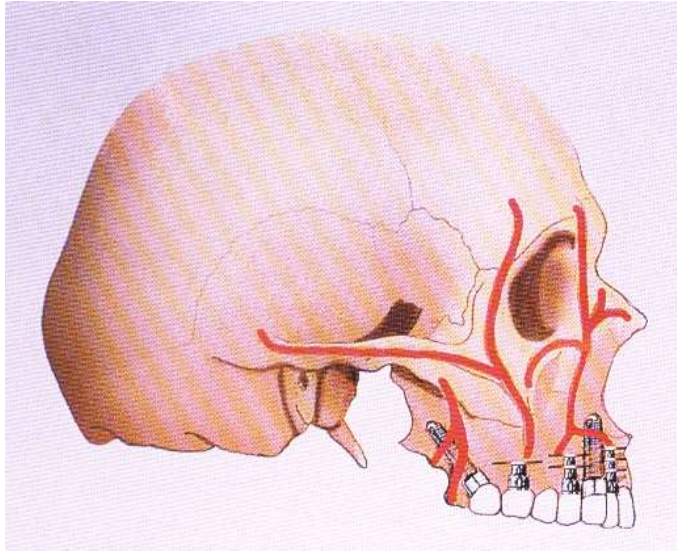


Nine mushroom-shaped implants which "snap" into soft tissue receptor sites

(the other side would look similar)



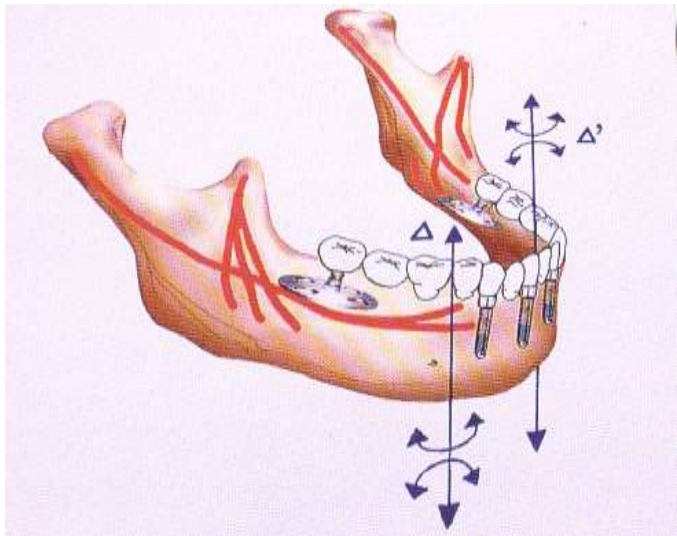
ENDOSSTEAL IMPLANTS



◆ **BLADE FORM**

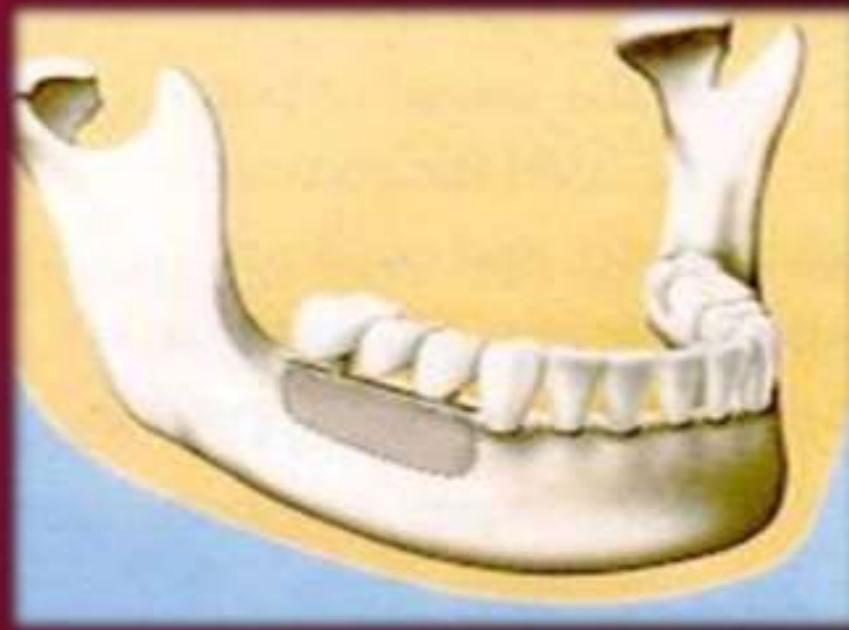◆ **FRAME FORM**

◆ **ROOT FORM**



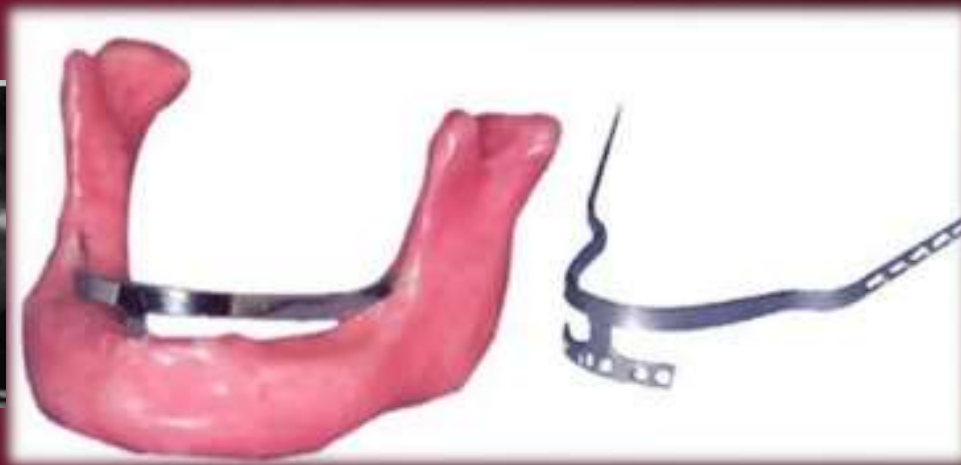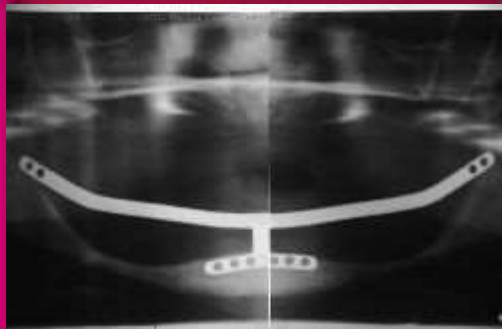a) BLADE IMPLANT

- It consist of thin plates in the form of blade embedded into the bone*



b) RAMUS FRAME IMPLANT

- *Horse shoe shaped stainless steel device*
- *Inserted into the mandible from one retromolar pad to the other*
- *It passes through the anterior symphysis area*



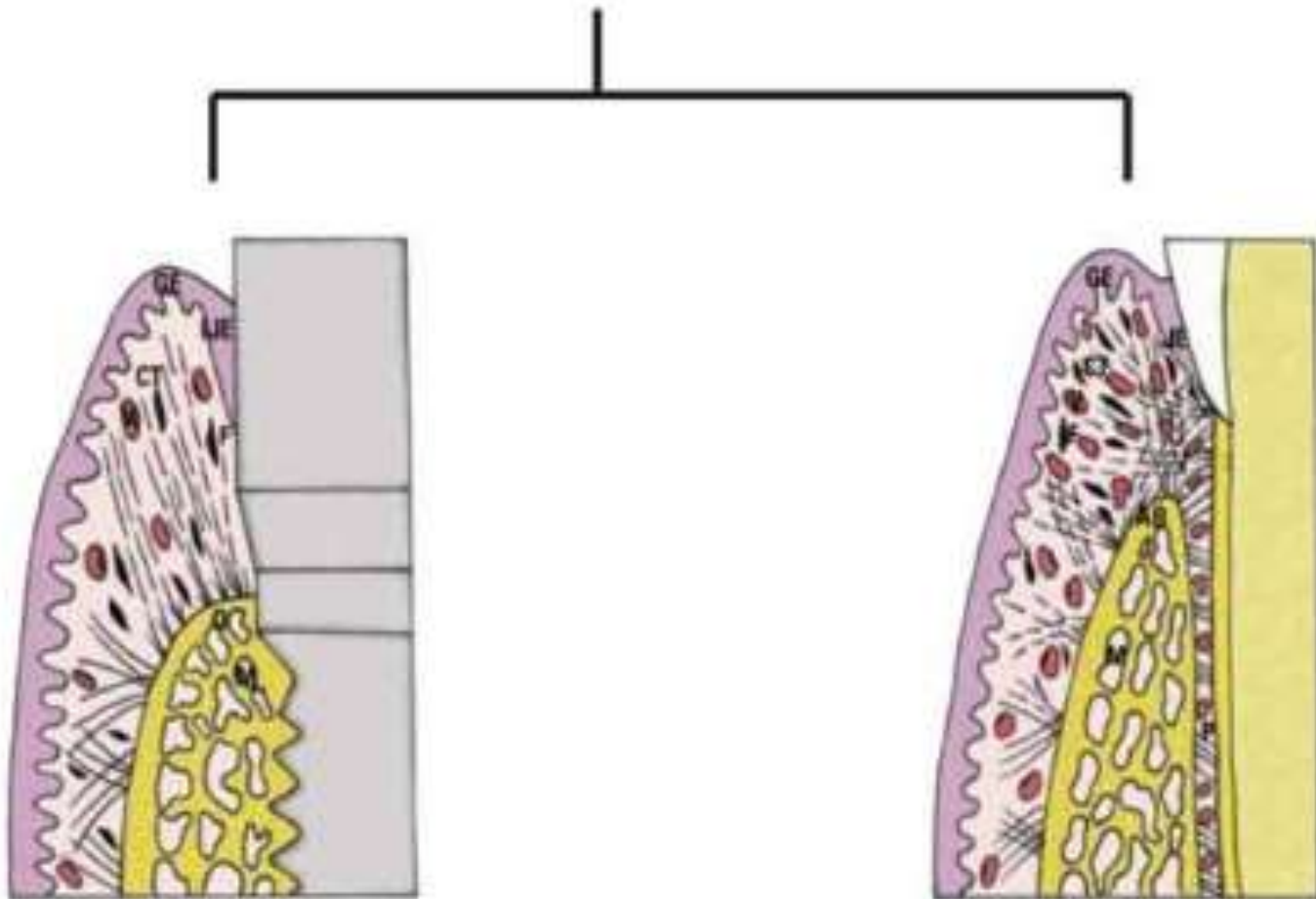
ROOT FORM IMPLANTS

- ◆ **MOST COMMON TYPE OF DENTAL IMPLANTS USED SINCE 1970s.**
- ◆ **AVAILABLE IN VARIOUS WIDTHS AND LENGTHS.**
- ◆



BASED ON ATTACHMENT MECHANISM

CLASSIFICATION BASED ON ATTACHMENT MECHANISM



OSSEOINTEGRATION

FIBRO INTEGRATION
(Peridontal Fibers)

FIBROINTEGRATION

- PROPOSED BY *DR CHARLES WEISS IN 1980'S*
- COMPLETE ENCAPSULATION OF THE IMPLANT BY THE CONNECTIVE TISSUES (AS THE BONE FORMS LATER).
- SOFT TISSUE INTERFACE COULD RESEMBLE THE HIGHLY VASCULAR PERIODONTAL LIGAMENT FIBRESS.
- **CONTROVERSIAL AND NOT ACCEPTED**

OSSEOINTEGRATION



*HISTOLOGIC CONCEPT WITH
DIRECT STRUCTURAL AND
FUNCTIONAL CONNECTION (OR)
UNION BETWEEN ORDERED
LIVING BONE AND THE IMPLANT.*

**--In 1977, Professor
Per-Ingvar
Branemark**



CLINICALLY NOT APPLICABLE

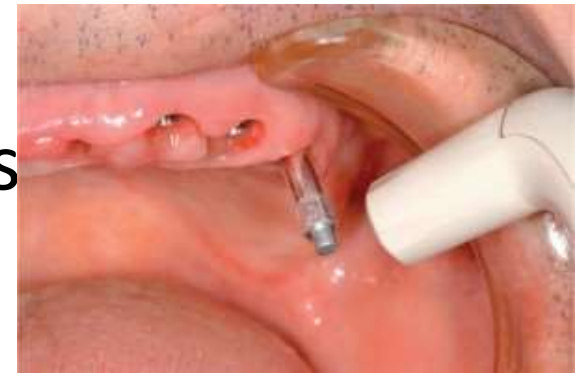NEW DEFINITION – BASED ON IMPLANT STABILITY

ZARB & ALBREKTSSON IN 1991 PROPOSED

“Osseointegration is a process whereby clinically asymptomatic **Rigid fixation** of the Alloplastic material is achieved and maintained in the bone during Functional Loading”.

HOW TO CHECK FOR RIGID FIXATION?

RFA – Resonance frequency analysis
(Merdith et al 1997).



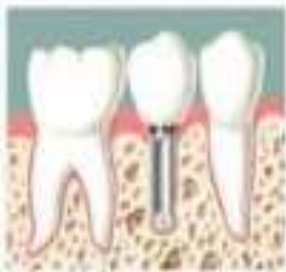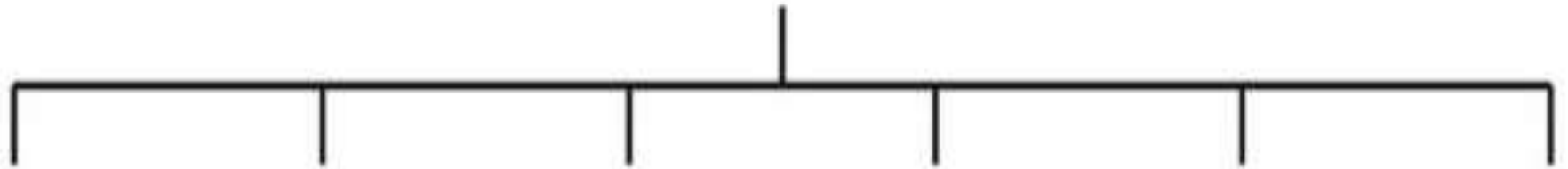
BASED ON MACROSCOPIC IMPLANT DESIGN

PRIMARY TYPES OF ROOT FORM BODY ENDOSTEAL IMPLANTS

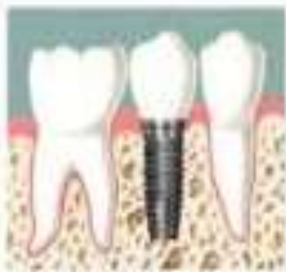- ✓ CYLINDER (Press fit)
- ✓ SCREW (Threaded)
- ✓ COMBINATIONS



CLASSIFICATION BASED ON MACROSCOPIC BODY DESIGN OF IMPLANT



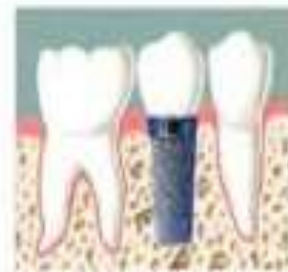CYLINDER



THREAD



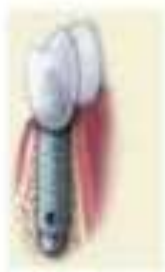PLATEAU



PERFORATED



SOLID



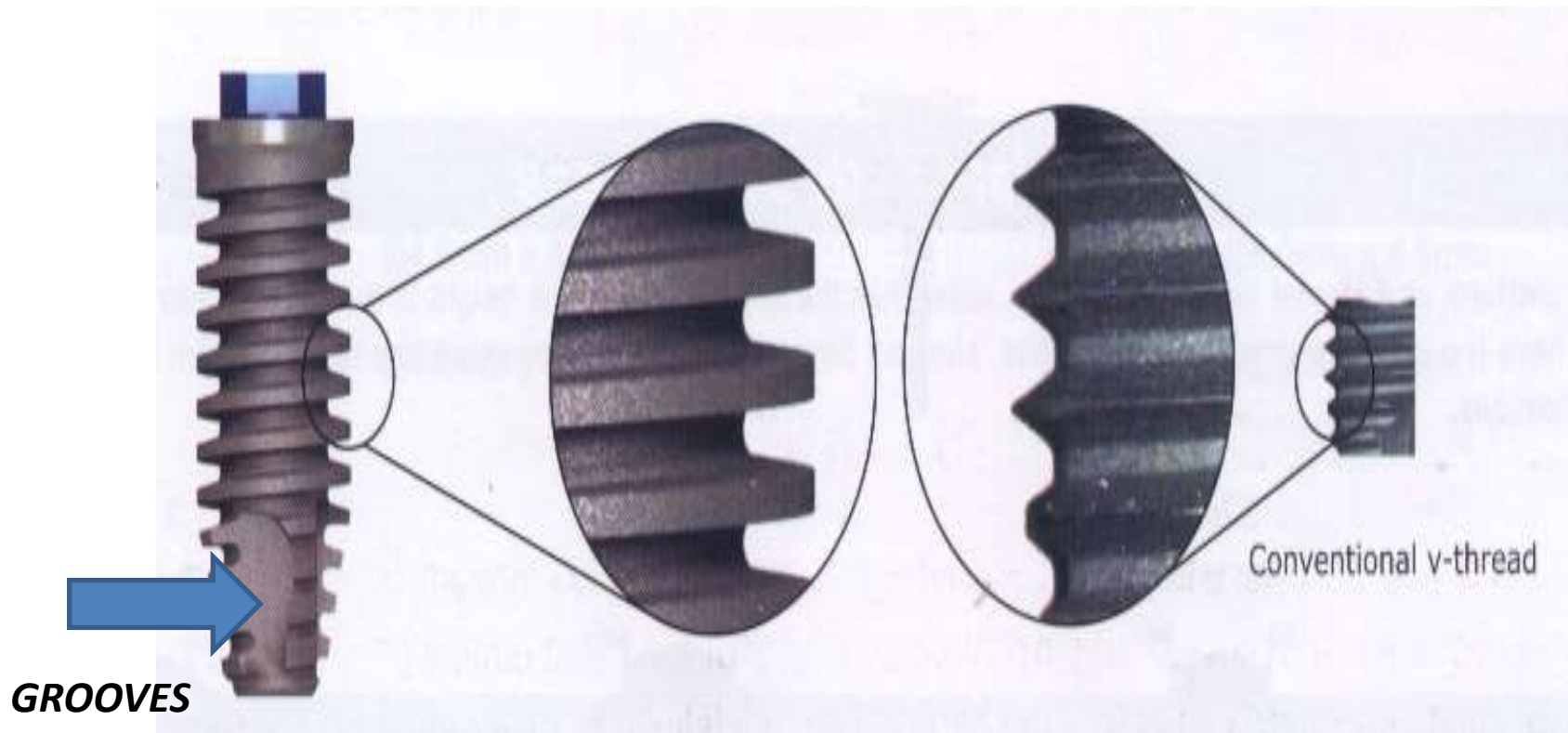
**HOLLOW
(or)
VENTED**

Machined

A machined screw type endosseous dental implant is still the most common form and there is nothing that surpasses its performance.



Macroform



BASIC IMPLANT MACRODESIGN FEATURES

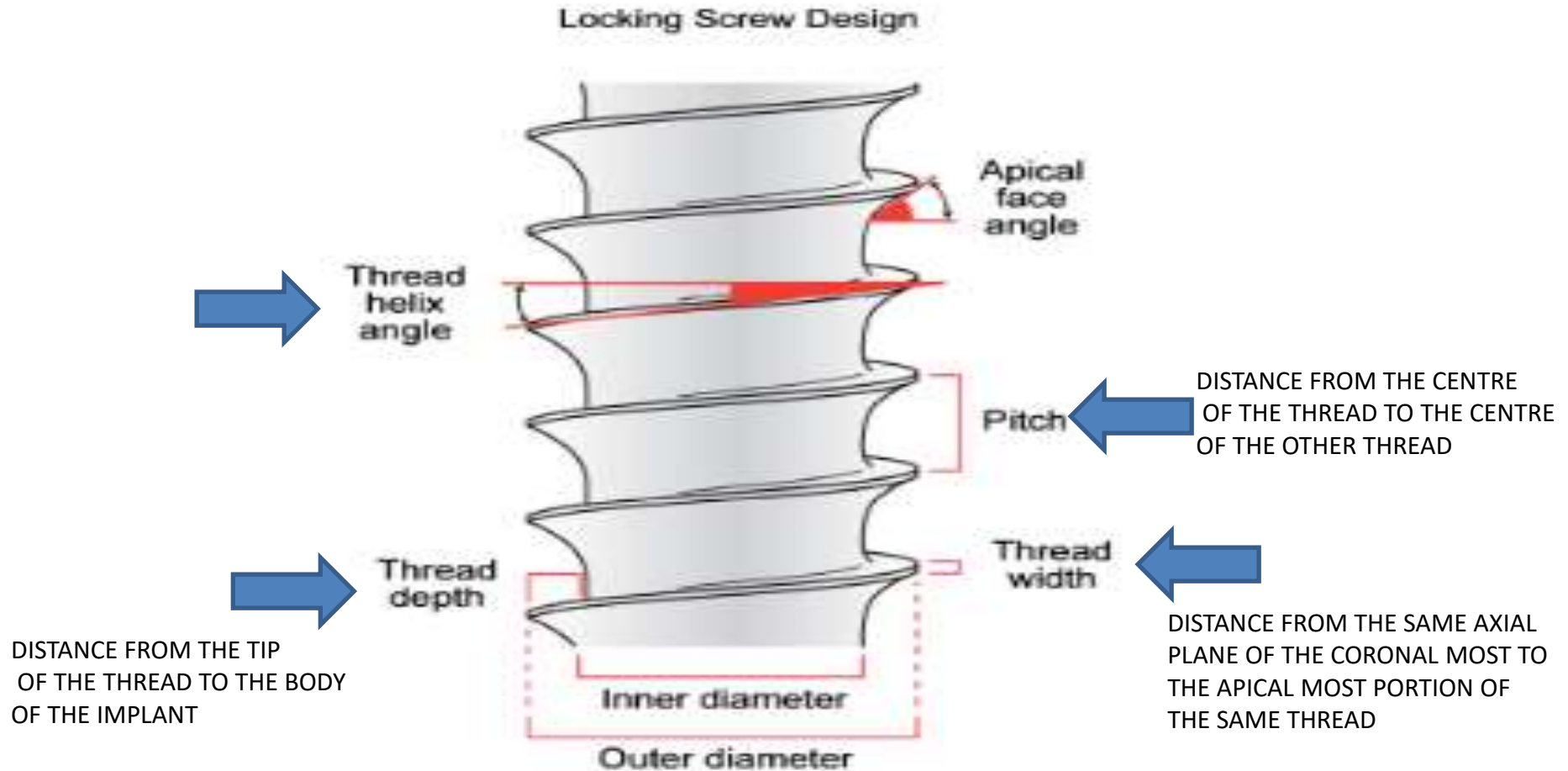


Fig. 1. Basic implant macrodesign features: face angle, thread helix, thread pitch, thread depth, thread width and inner and outer implant diameter.

(Boggan et al. 1999)



Thread Types

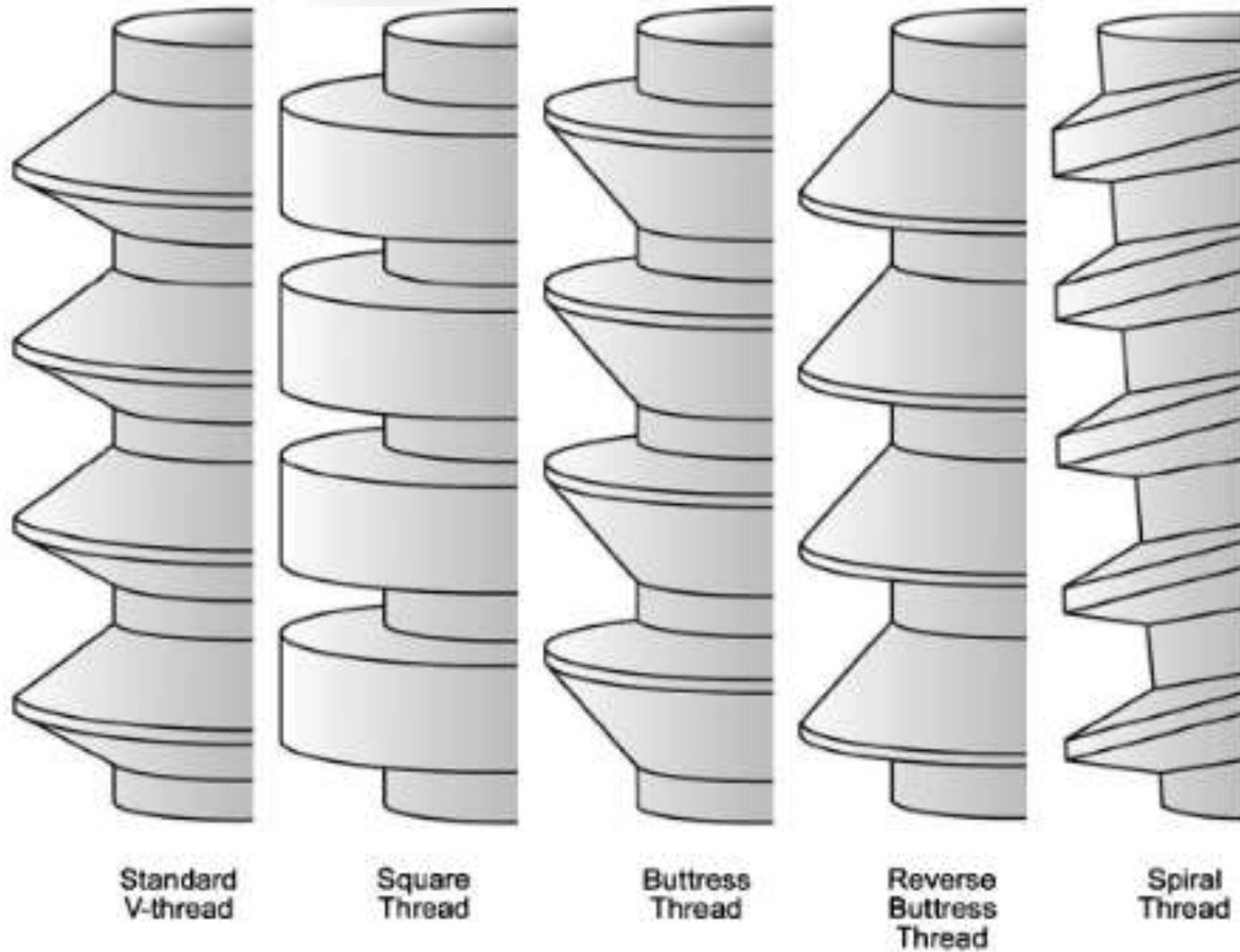


Fig. 2. Currently available implant thread pattern types.: V-thread, square thread, buttress thread, reverse buttress thread and spiral thread.

FROST et al 1990; HANSON & WERKE 2003

WOLF et al 1892

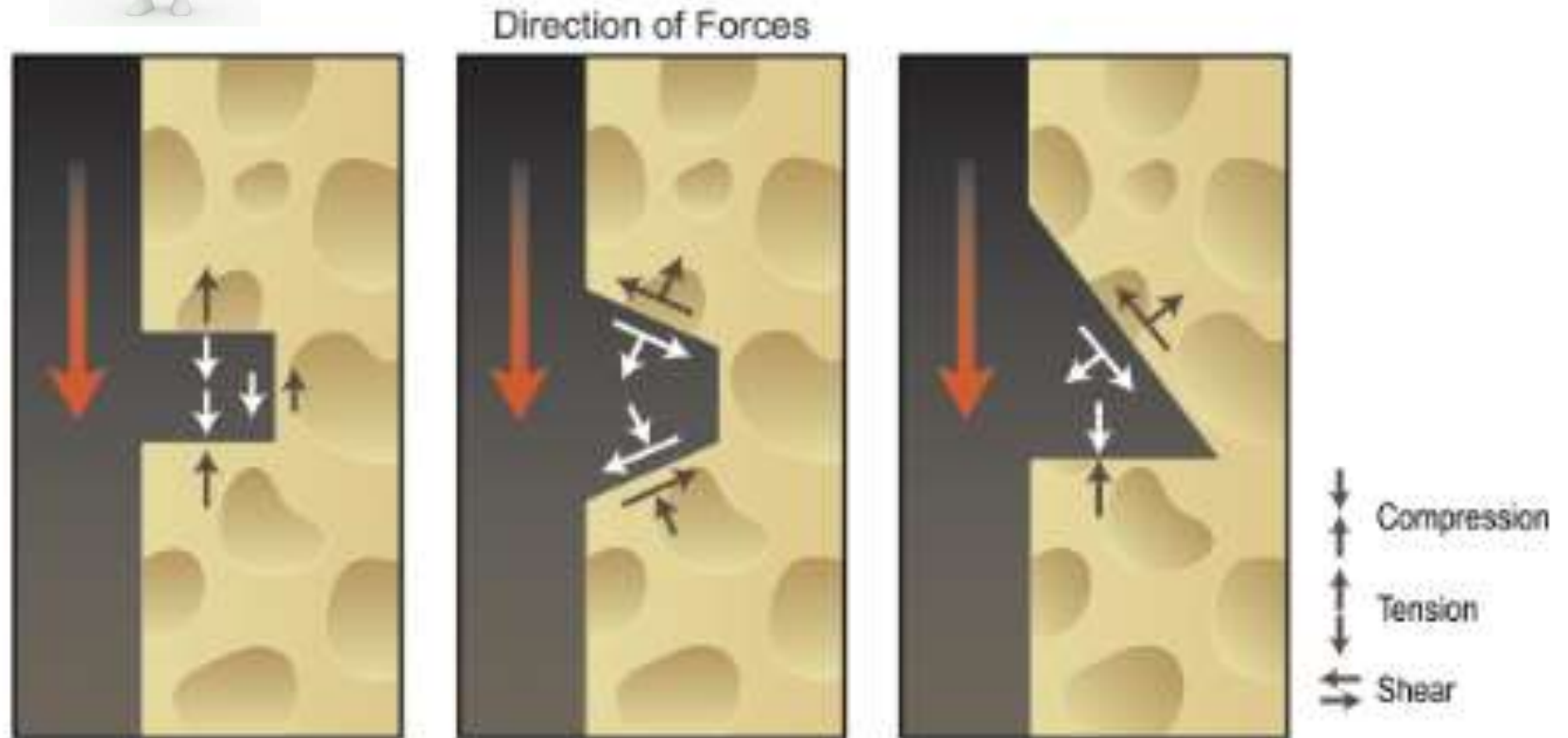


Fig. 3. Direction of forces generated at the implant and bone interface resulting from axial loading.



Single and Multiple Screw Heads

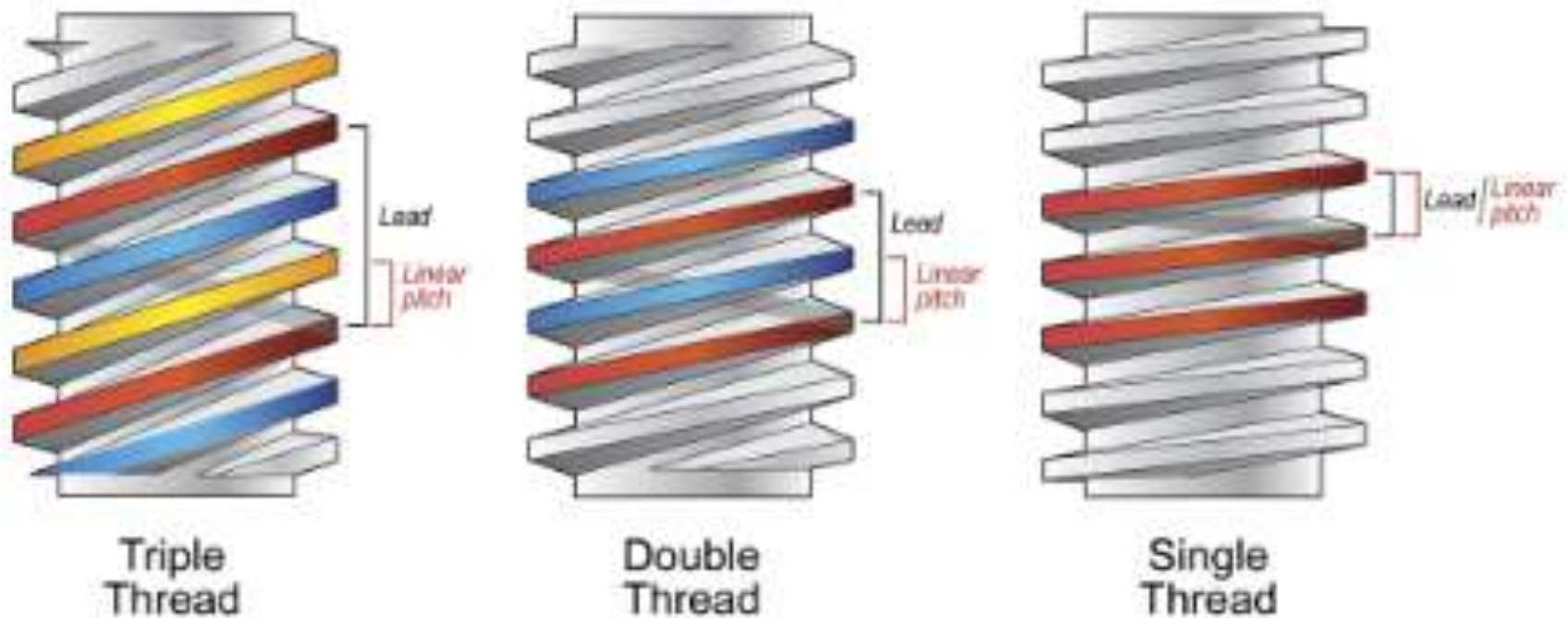
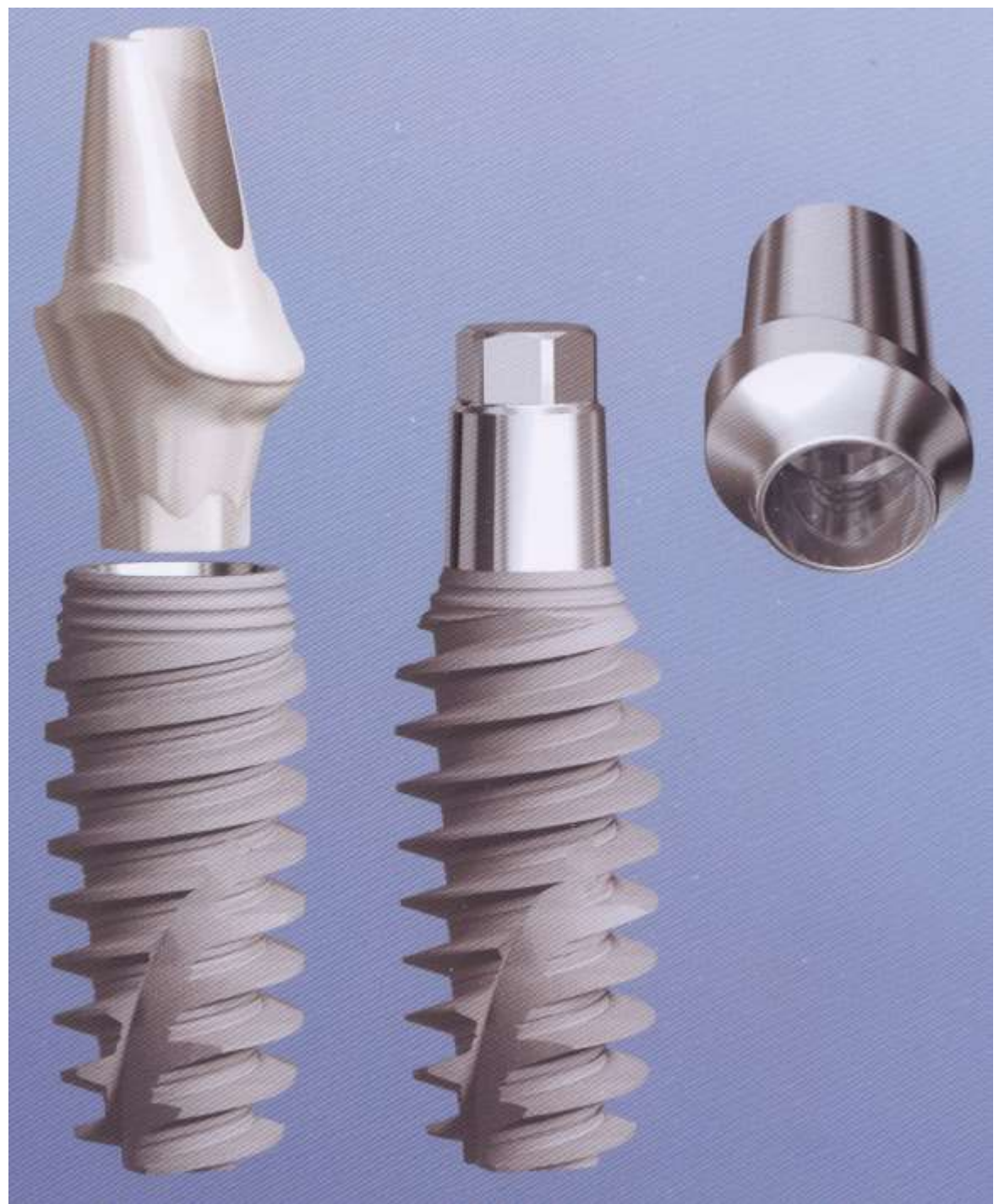


Fig. 4. This figure illustrates the thread configuration in relation to thread number, pitch and lead. Single-threaded implants have an equal thread pitch and lead. Double-threaded implants have a lead that is double the pitch. Triple-threaded implants have a lead that is triple the pitch.

Tapering Implant



- **Some manufacturer's have gone to tapering the apical end of the implant to simulate the form of a natural tooth. While this really in no way affects the outcome, it's a nice touch...**
- **Advantages Tapered implants might be advantageous when a single implant is placed between two teeth with divergent roots.**





Tapered Screw-Vent Implant



AdVent Implant

ZIMMER





*Zimmer One-Piece Implant
3.7mm Angled*

*Zimmer One-Piece Implant
3.7mm Straight*

TWO PIECES

ONE PIECE

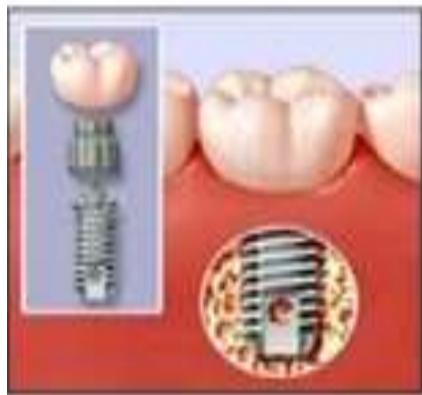
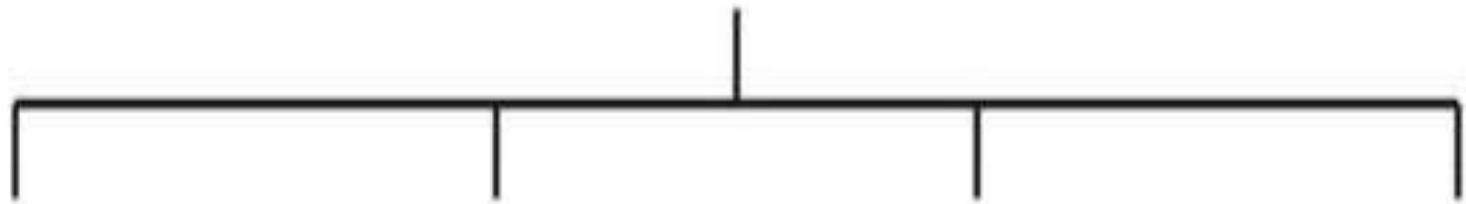
SUMMARIZE

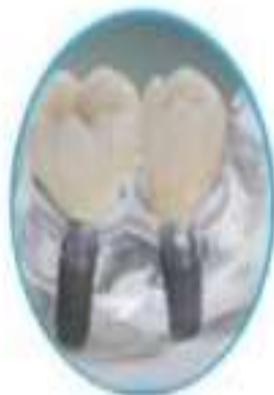- DESIGN MAKES A DIFFERENCE
- THREAD GEOMETRY – MAJOR IMPORTANCE
- GROVES AND FLANGES – MODERNIZE THE IMPLANT ERA

**BASED ON THE MATERIALS & SURFACE
– MICROSCOPIC DESIGN
OF IMPLANTS**

CLASSIFICATION BASED ON TYPE OF THE IMPLANT MATERIAL



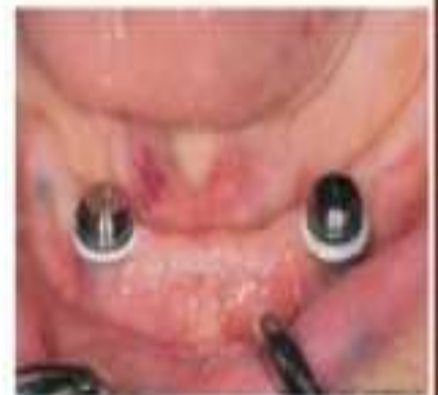METALLIC



**CERAMIC
&
CERAMIC COATED**

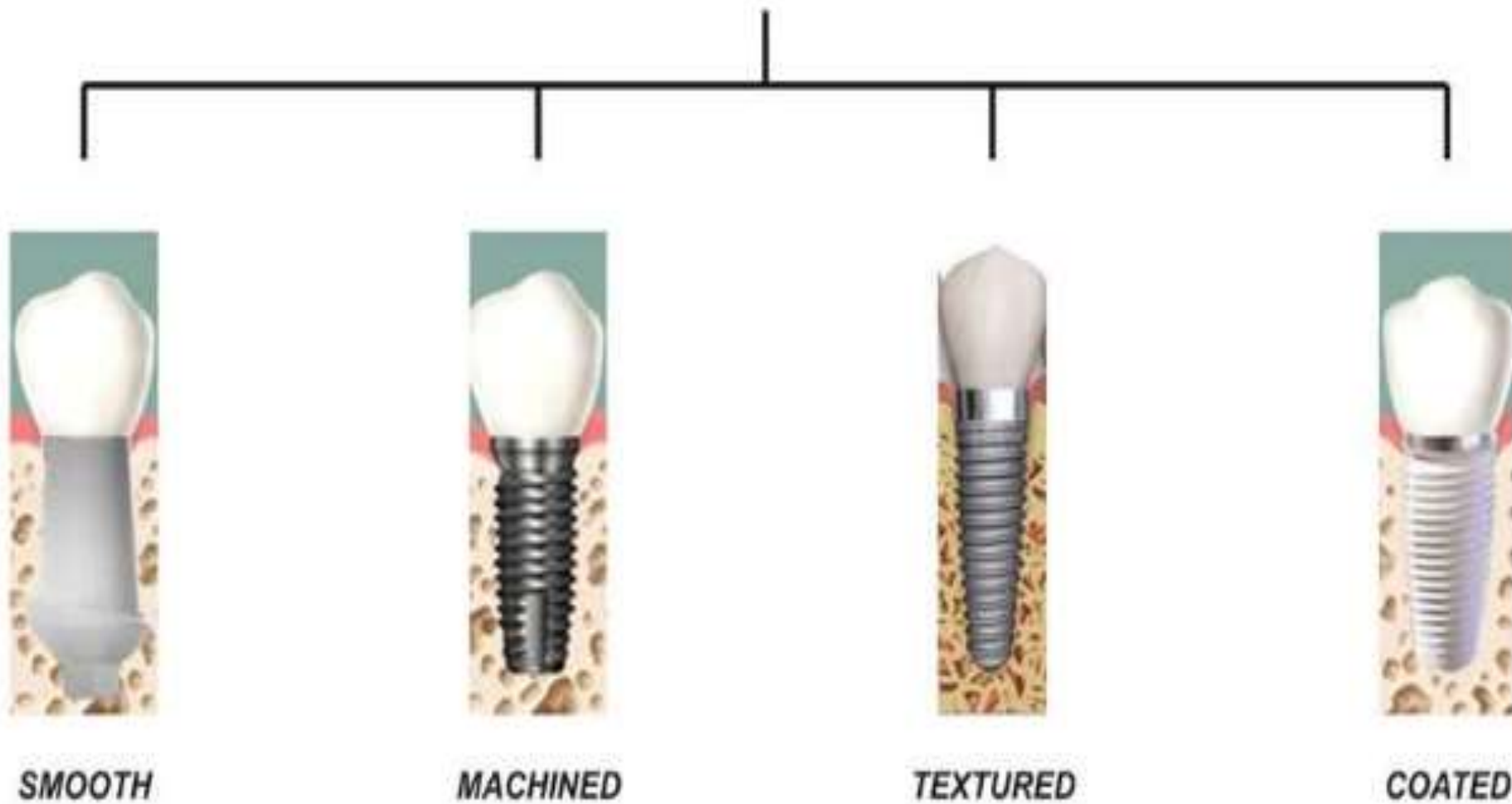


POLYMER



CARBON COMPOUND

CLASSIFICATION BASED ON SURFACE OF THE IMPLANT



- Role of Implant surface** (Mirodesign)
- Molecular interactions
 - Cellular response
 - Osseointegration

Main objective for implant surface modifications

- Promote osseointegration
- Faster& stronger bone formation
- Improve clinical performance in area of poor bone quality & quantity
- Accelerate bone healing->allowing immediate or early loading

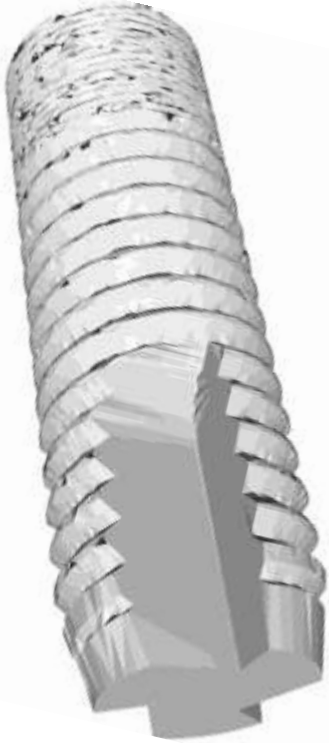
MICRO DESIGN

1st generation- Machined with smooth surface texture

2nd generation- Mechanical blasting coupled or not, with acid etch bioactive coatings, anodized and more recently laser modified surfaces.

(Cochran et al 1998, Jansen et al 1993, Palmquist et al 2010, Branemark et al 2010)

Next generation



- Micro-Nano technology
- Surface Engineering in implant dentistry
- Creating a 3 dimensional geometry
- Creating surface designs to increase osteoconductivity

(Chehrondi et al 1992 Cooper et al 1998)

- Omar et al 2010- changes in physiochemical properties of titanium results in significant modulation of cell recruitment ,adhesion, inflammation and bone remodeling activities in addition to regulation on bone formation response

WHAT DO I LOOK FOR???

SURFACE ROUGHNESS

BONE TO IMPLANT CONTACT

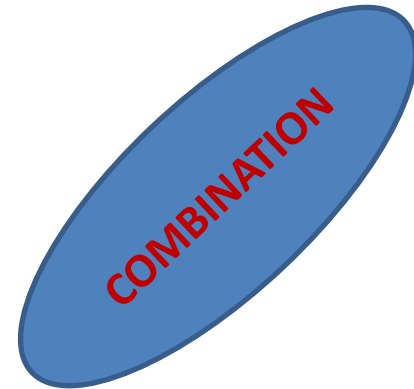
HIGH TORQUE REMOVAL

Surface roughness

Important parameter for implant for being anchored in bone tissue

Methods to increase surface roughness

1. Machining
2. Sandblasting
3. Acid etching
4. Anodic oxidation
5. Laser modification



Commercially available implants are categorized based on surface roughness(Sa)

1. Smooth (Sa < 0.5 um)
2. *Minimally rough* (Sa = 0.5-1.0 um)
3. Moderately rough(Sa=1.0-2.0 um)
4. Rough (Sa > 2.0 um)

(Albertson & wannerberg ,2004)

TERMINOLOGIES



- Sa -> Represents the mean height of peaks & pits of the surface.
- Sdr -> represents the developed surface area compared to a perfect flat area.

Larger surface area -> greater contact to bone
& tissues

(Gadlmawla et al 2002)

Machined surface

- 1st gen of osseointegrated implants had a relatively smooth machined surface (Branemark et al 1969).
- Minimally rough Sa(0.3-1.0um)
- Surface oxide consists of 2-10 nm thick, mostly amorphous layer of TiO₂ (Lausmace 1996)
- Excellent long time follow ups (1st used surface in clinical dental application) (Adell 1981, Branemark 1977)



Healing around implants

1. Increased bone implant contact starting at implantation
2. Biochemical stability slightly decrease on the 1st weeks – possible due to inflammation & bone remodelling
3. Gets fully reconnected in 4 weeks in rat tibia(Branemark 1997)
4. Endosteal down growth of bone tissue covering the implant threads occur in marrow cavity & reach upto 70%. Bone implant contact after 16 wks in rat tibia(Sennerberg 1991)
5. Sennerberg et al 1991 showed in his study that hydroxyapatite forms directly at implant surface

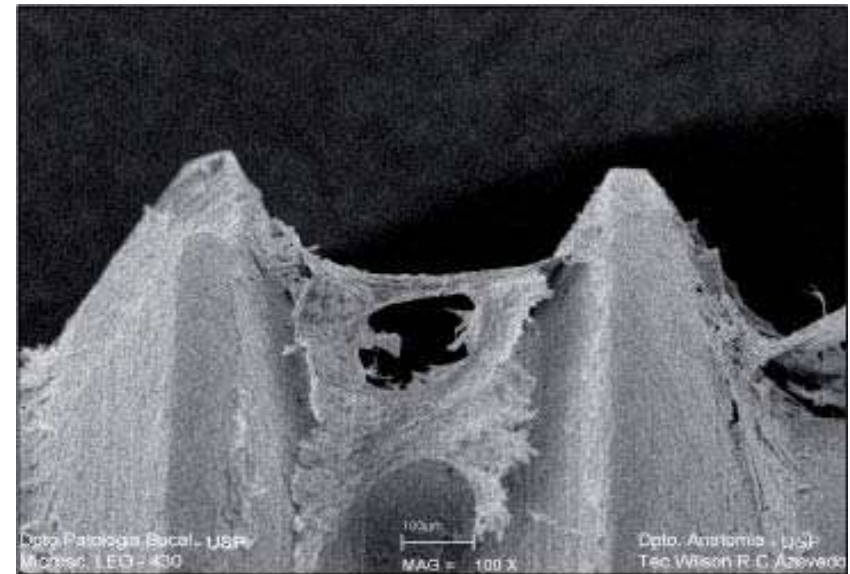
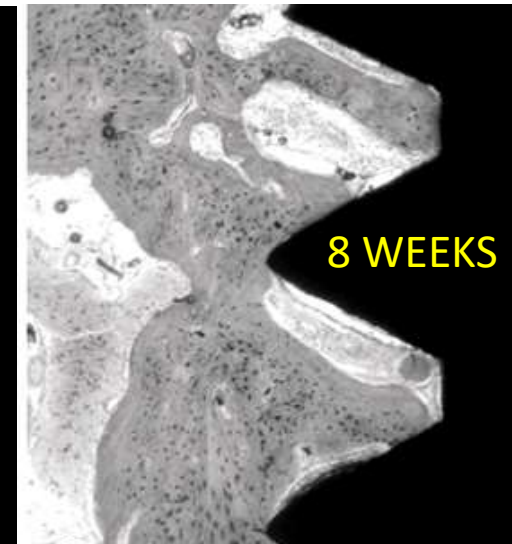
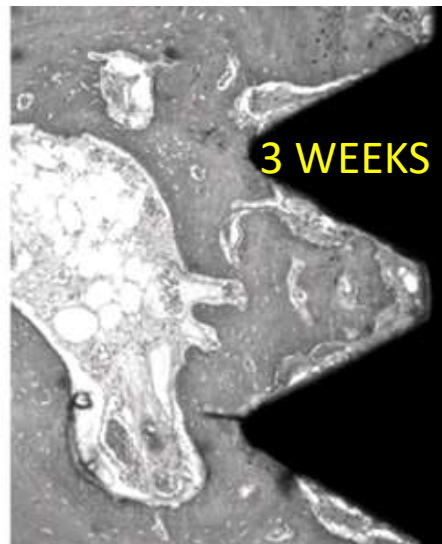




Figure 2 - SEM - 24 hours - Cell adhesion to the machined dental implant (100 X).



SAND BLASTING

- Increased roughness
- Small particles hit the implant & cause craters (grit blasting)
- Surface roughness depends on
 1. Bulk material
 2. Particle material
 3. Particle size
 4. Particle shape
 5. Particle speed
 6. Density of Particles



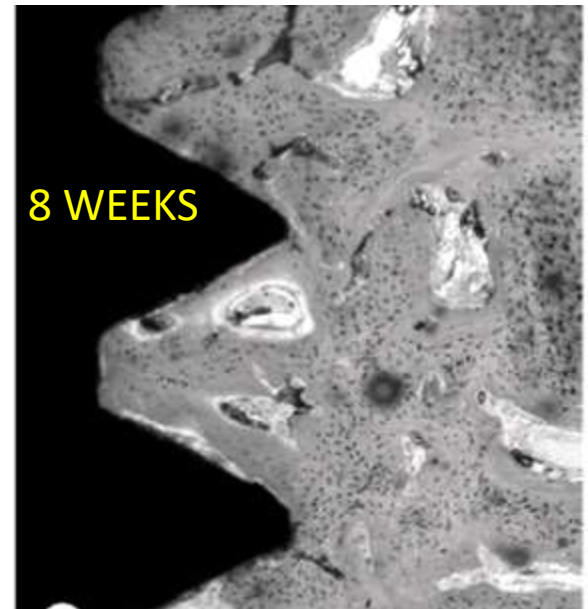
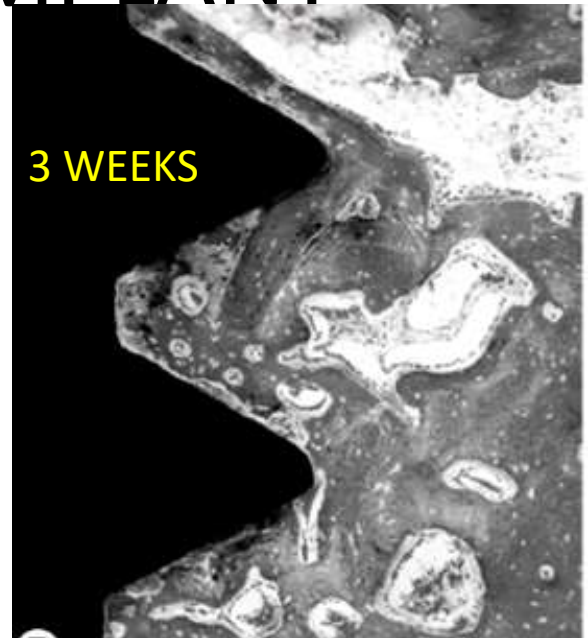
-Resulting surface is anisotropic
consisting of craters and ridges

-surface roughness increase with
size of particles

(wennerberg et al 1992)


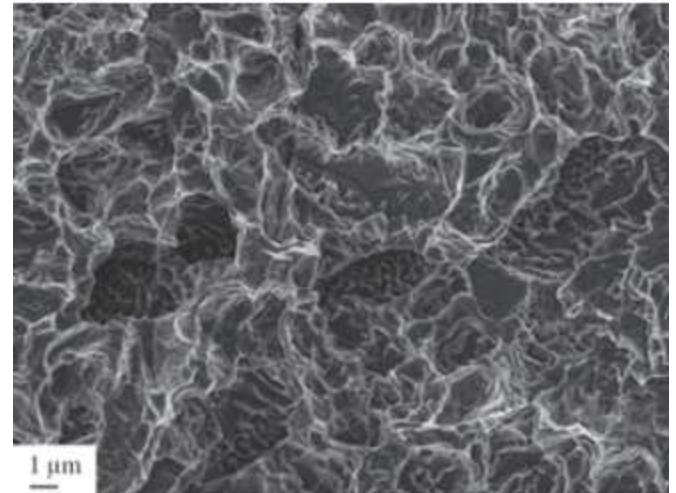
HEALING AROUND IMPLANT

- Implants blasted with 25um & 75um particles show higher removal torque compared to machined implant surfaces after 12 wks of healing in rabbit tibia or femur (wennerberg 1995).
- Bone implant contact was higher in sandblasted compared to machined.
- Blasting materials are either TiO₂ or Al₂O₃, both had no difference in healing.
- Optimal bone response was seen with roughness of 1.5um (wennerberg 1996)

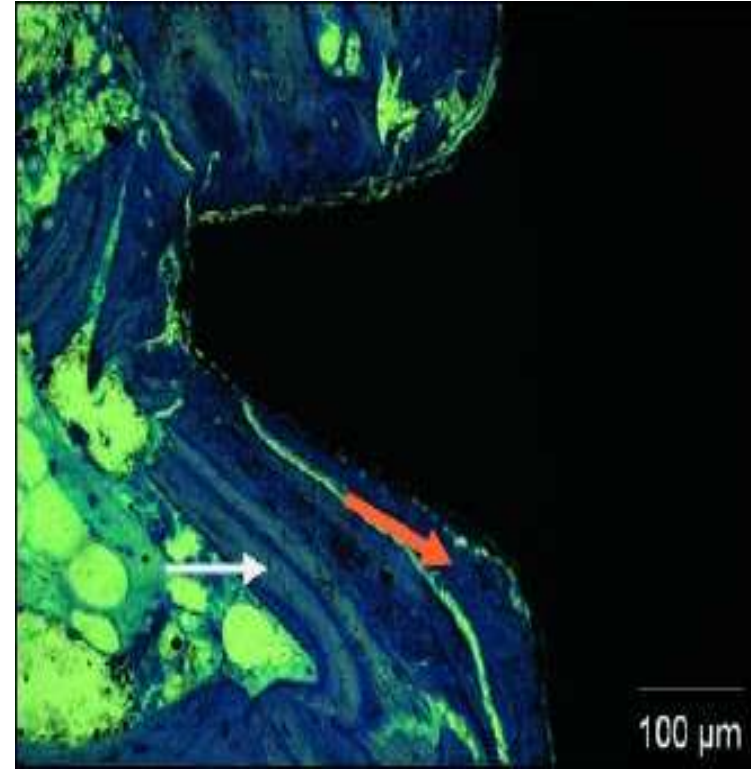


ACID ETCHED SURFACE

- Implant surface is pitted by removal of grains and grain boundaries
- Selective removal of materials is obtained as certain phases and impurities are more sensitive to etching
- Resulting roughness is depended on the acid and soaking time
- Minimally rough surface is considered($S_a \rightarrow 0.3-1.0\mu\text{m}$)



- Titanium hydride layer could form due to presence of hydrogen ions in the acid
 - Surface oxide, native amorphous TiO_2 with thickness of around 10nm (Sal et al 2006)
 - Celletti et al 2006 compared bone response to machined implants in animal models and inc bone implant contact
 - Inc removal torque
- SEM-osteocyte cellular processors was extending towards implant surface



Sand blasted & Acid etched

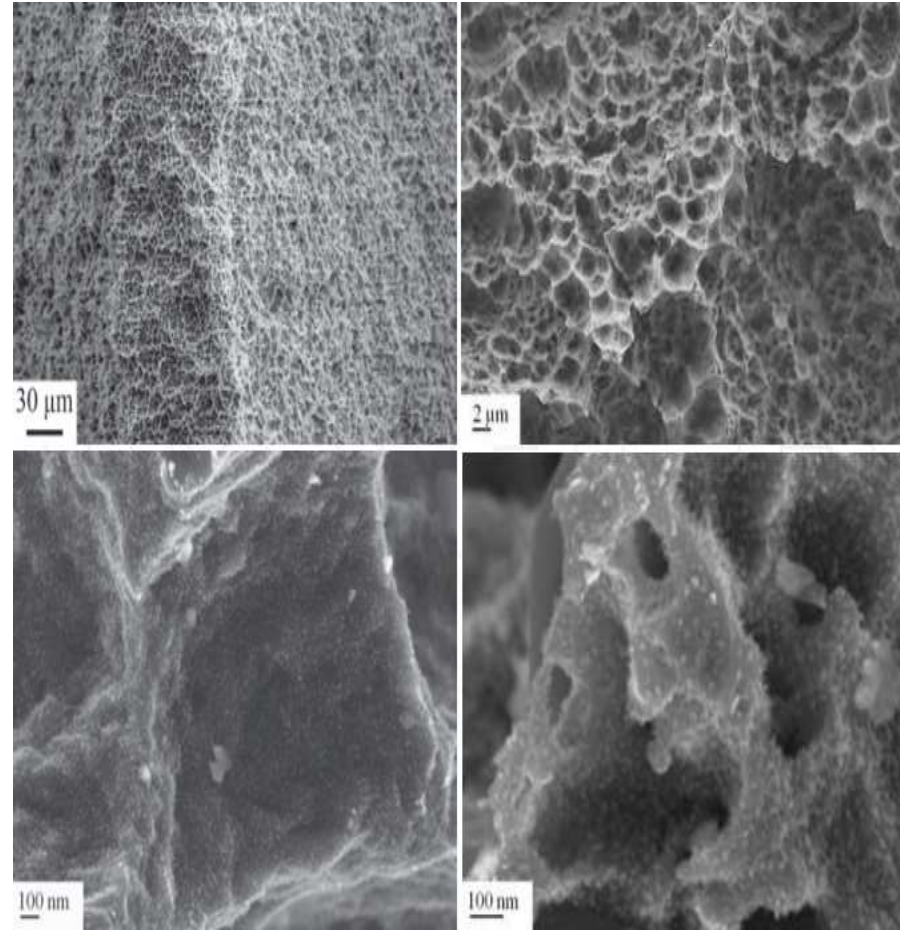
Dual surface roughness & removal of embedded blasting particles

Advantages

- * Sa values 1-2 μ m

- *Titanium hydride layer with thickness of 1-2 μ m intermediate the surface oxide and the bulk metal (Conforto 2014)



- *Further by rinsing SLA implants in a nitrogen atmosphere and storing in saline solution until installation, the amount of carbon contamination could be reduced and improve the hydrophilicity of the implant surface. (Rupp et al 2006)



This creates SLA active to maintain a chemically active surface that conditioned to the human body



- Fluoride ions could also be incorporated if etched with hydrofluoric acid
- 1, higher removal torque needed in 10 wks -> compared to Acid etched, machined & plasma sprayed
- 2, no difference in bone density compared with all three implant systems
- 3, SLA active has higher bone implant contact compared to SLA alone (6wks)

(Buser 2004, Schwartz 2007)



Anodized surface(Tiunite)

- Partial crystalline and phosphates enriched titanium oxide characterized by a micro structured surface with open pores in the low micrometer range
- Anodization or anodic oxidation- electrochemical process carried out in an electrolyte
- Structural and chemical properties could be tailored by varying diff process parameters such as
 1. anode potential
 - 2.electrolyte composition
 - 3.temperature
 - 4.current

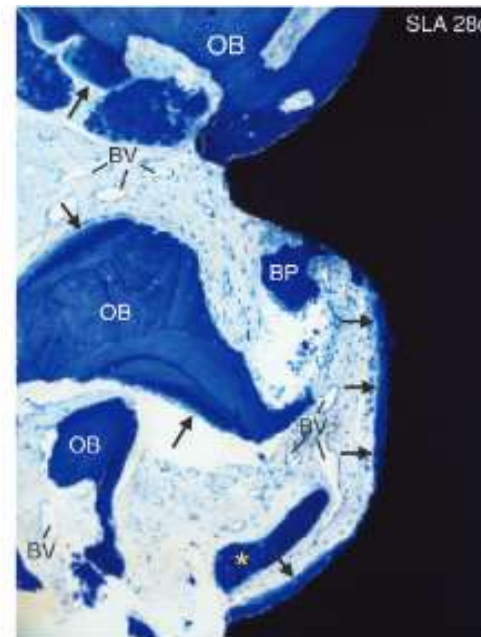




-based on electrolyte composition different ions could be interacted in the oxide layer such as

1. phosphorus (Hall & Lausman 2000)
2. calcium (Froid 2008)
3. magnesium (Sul 2005)

-BONE HEALING

1. increase bone implant contact
2. increase biomechanical removal torque values for phosphorus compared to machined in dogs & rabbits (Albertson 2000)
3. Ca ions increase bone implant contact
4. increase biomechanical removal torque was associated with Mg incorporated oxides (Sal 2005)





LASER MODIFIED MICRO-NANOSTRUCTURED INTERFACE


Micromachining tool to produce a 3D structure at micrometer and nanometer level

Surface modified with laser micro machining process to create micro-nano-structured surface roughness in the inner part of the thread which is more suitable for bone formation.

(Thomsson & Esposito 2008)



- Higher bone implant contact & higher removal torque
- Long term bonding interface length
- Thomsson & Esposito 2008 showed excellent clinical results with Branemark Bio Helix .
- RCT with suitable controls are needed



Calcium phosphate coatings in titanium implants

surface reactive materials have shown ability to form a interfacial chemical bond with surrounding tissues through a series of biophysical and biochemical reactions, causing bioactive fixation of implant(Cao & Hench 1996)

- Bioactive materials can be biostable (i.e synthetic hydroxyapatite) or bioresorbable (i.e bioactive glass & glass ceramics)
- Wilson et al 1981 demo ,bioactive glass of certain compositions have real chemical bonding with soft tissues

However bioactive ceramics in bulk form are not suitable for load bearing application as their flexural strength, strain to failure and fracture toughness are less than that of bone and their elastic moduli is greater than that of bone.

- So they are applied as coatings on metallic implants

Calcium phosphates are most commonly used bioceramics they are bioactive and osseointegrative

BIOACTIVITY IS DUE TO

Epitaxial nucleation of carbonated apatite crystals



At the surface of ceramic grains



This layer of biological apatite contains
endogenous proteins



Serve as matrix for osteogenic cell attachment
and growth

(Davies et al 2003)

SUMMARIZE

- ✓ CHANGE IS THE ONLY THING CONSTANT IN THE FIELD OF IMPLANT DENTISTRY

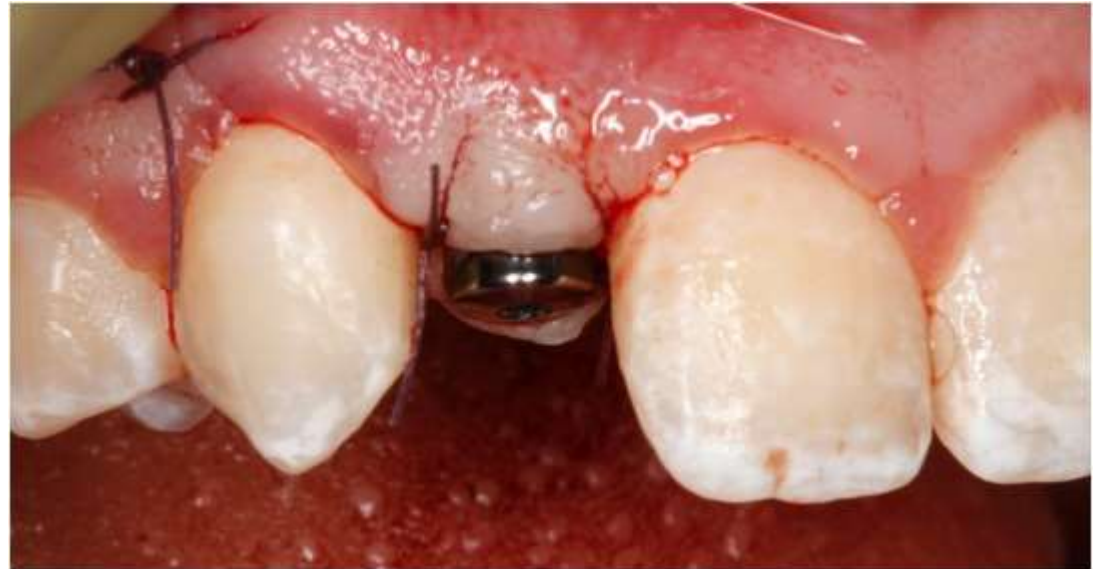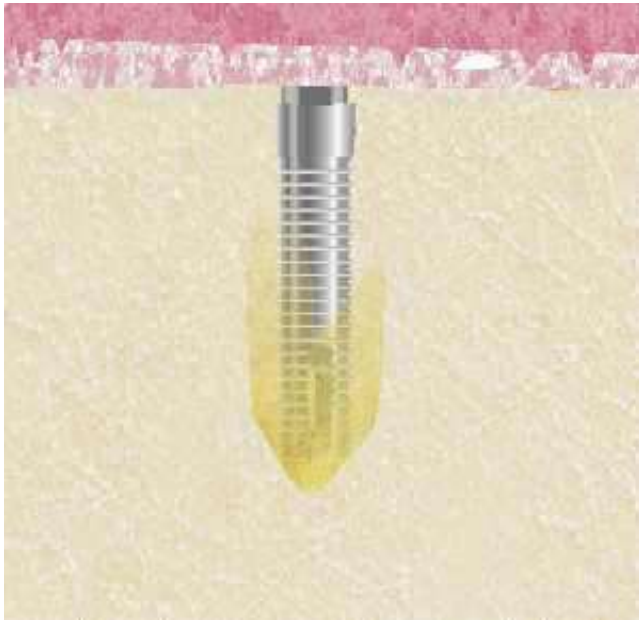A STRAND et al 2005

BASED ON SURGICAL APPROACHES

- TWO STAGE
- ONE STAGE
- IMMEDIATE IMPLANT PLACEMENT

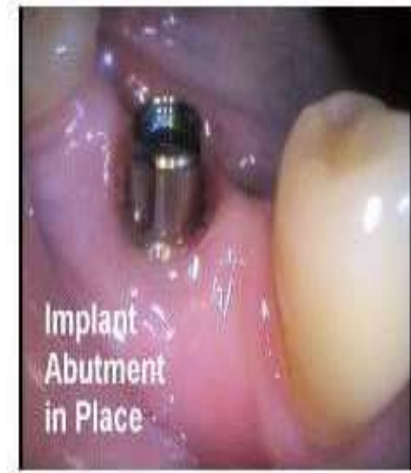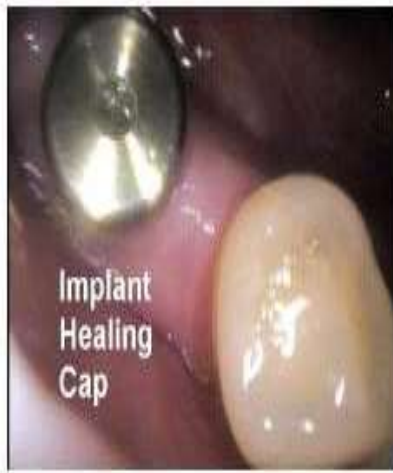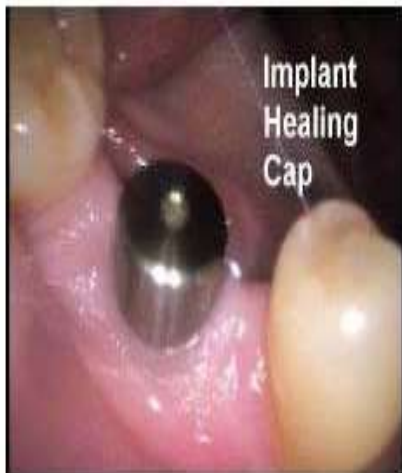TWO STAGE IMPLANTS

- THE IMPLANTS HEAL UNDER THE SOFT TISSUE AND IS , AFTER HEALING PERIOD, ACCESSED THROUGH A SECOND STAGE SURGERY.



ONE STAGE IMPLANTS

- THE IMPLANT HEALS WITHOUT THE PROTECTION OF THE ORAL MUCOSA AND IS ACCESSIBLE THROUGH THE MUCOSA DURING THE HEALING TIME



One-stage versus two-stage implant placement. A Cochrane systematic review of randomised controlled clinical trials.

[Esposito M](#), [Grusovin MG](#), [Chew YS](#), [Coulthard P](#), [Worthington HV](#)

[Eur J Oral Implantol](#). 2009 Summer;2(2):91-9.

The number of patients included in the trials was too small to draw definitive conclusions.

The one-stage approach might be preferable in partially edentulous patients since it avoids one more surgical intervention and shortens treatment times,

while a two-stage submerged approach could be indicated when an implant has not obtained an optimal primary stability, when barriers are used for guided tissue regeneration or when it is expected that removable temporary prostheses could transmit excessive forces on the penetrating abutments, especially in fully edentulous patients.

Outcomes of One-Stage Versus Two-Stage Implant Placement

[Gerard Byrne](#), BDS_c, MSD (REVIEW OF DATABASES FROM JAN 2009 TO 2010)

© October 2010 [American Dental Association](#)

doi: 10.14219/jada.archive.2010.0054

There were no significant differences between outcomes for one-stage and two-stage implant placement.

Large, well-controlled RCTs may prove the noted trend that one-stage placement may be more appropriate for partially edentate patients, whereas two-stage placement may be more suitable for patients in circumstances in which initial stability of the implant is an issue or in which barriers are used.

SUMMARIZE

No difference was observed when comparing 1- with 2-stage procedures.

However 1-stage implant placement might be at a slightly higher risk of failures and complications

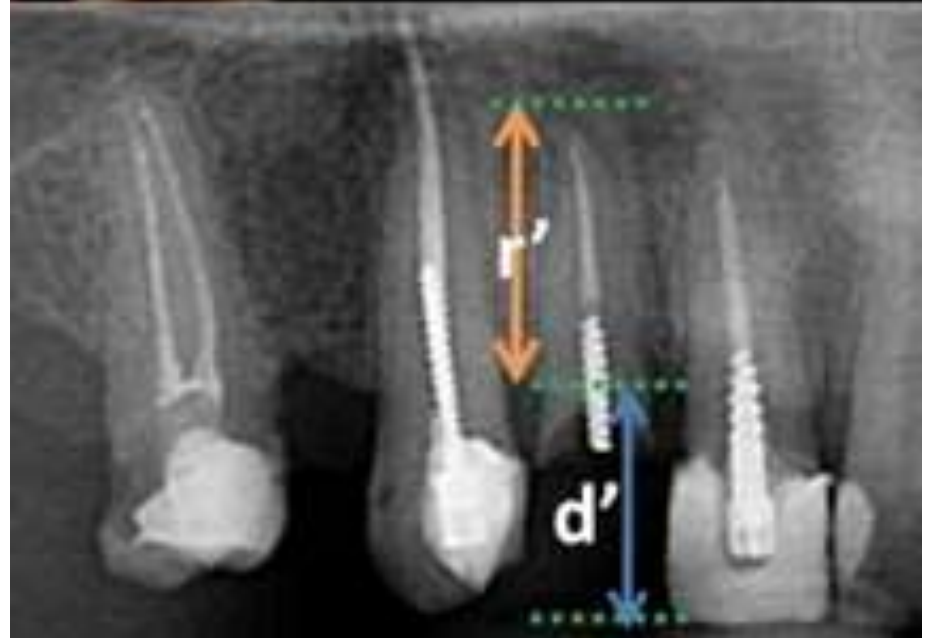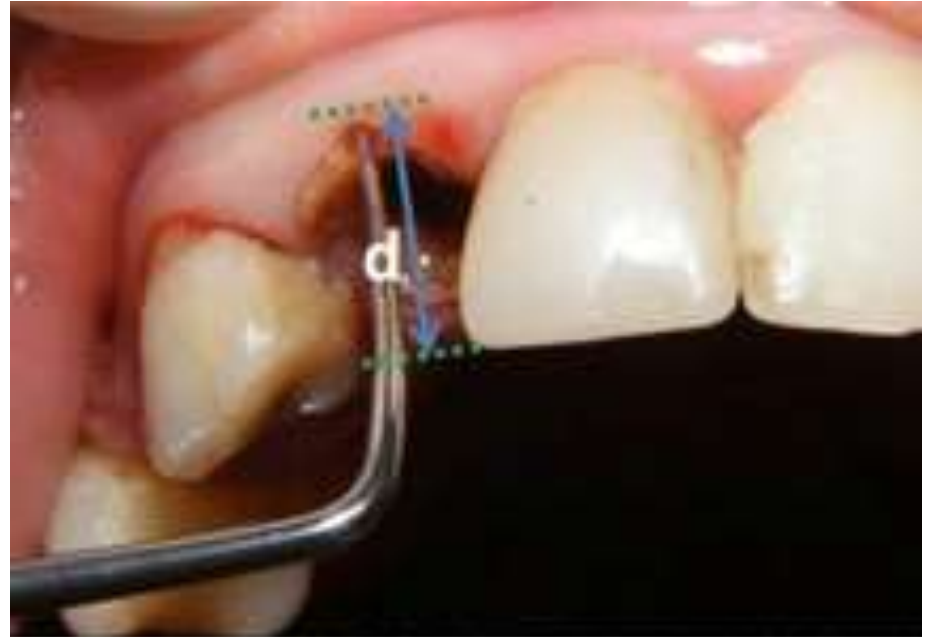IMMEDIATE IMPLANT PLACEMENT

TREATMENT PLANNING

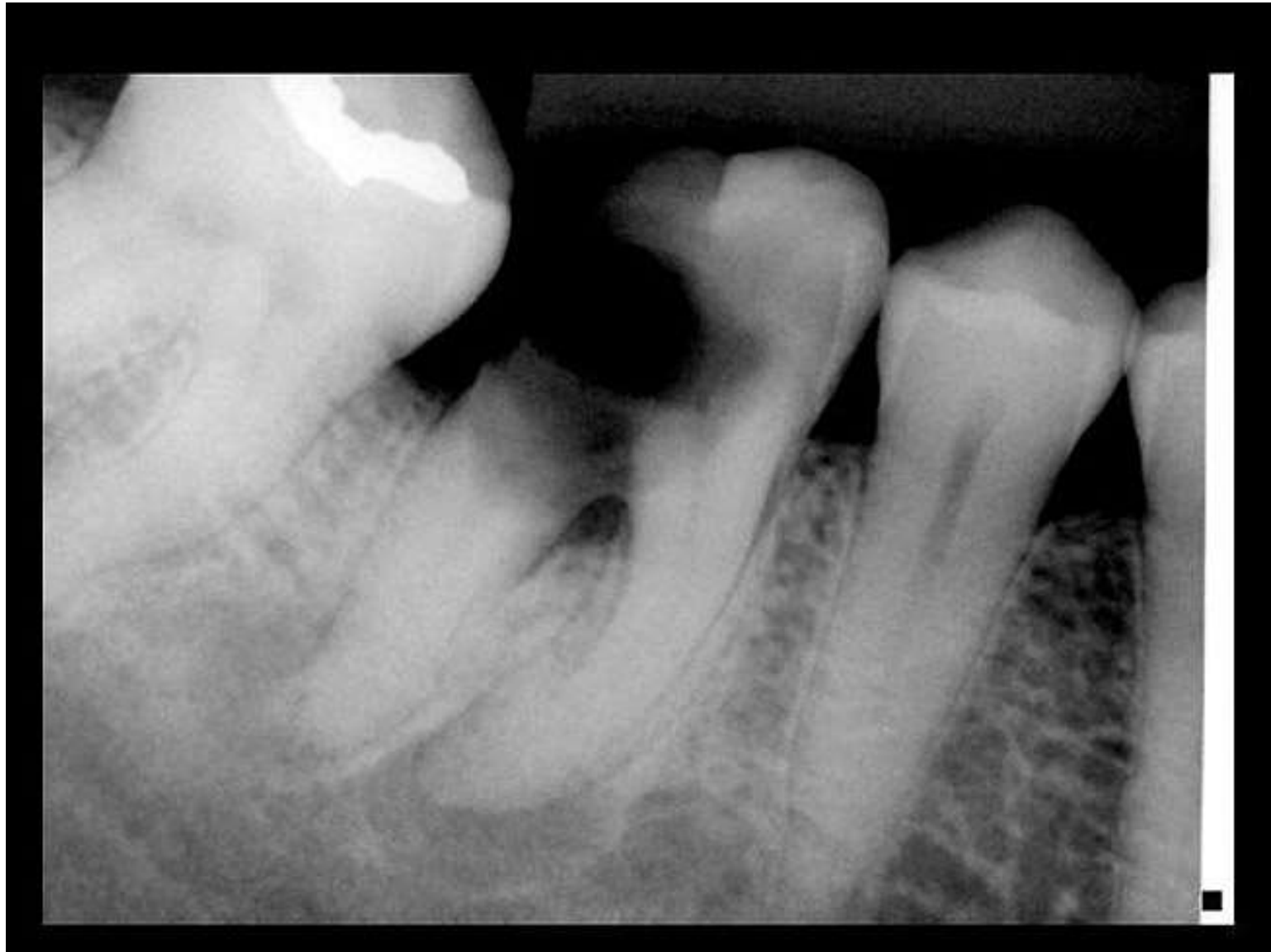- ✓ OVERALL PROGNOSIS
- ✓ INDIVIDUAL TOOTH PROGNOSIS OF THE TOOTH IN QUESTION.

REASONS FOR TOOTH EXTRACTION

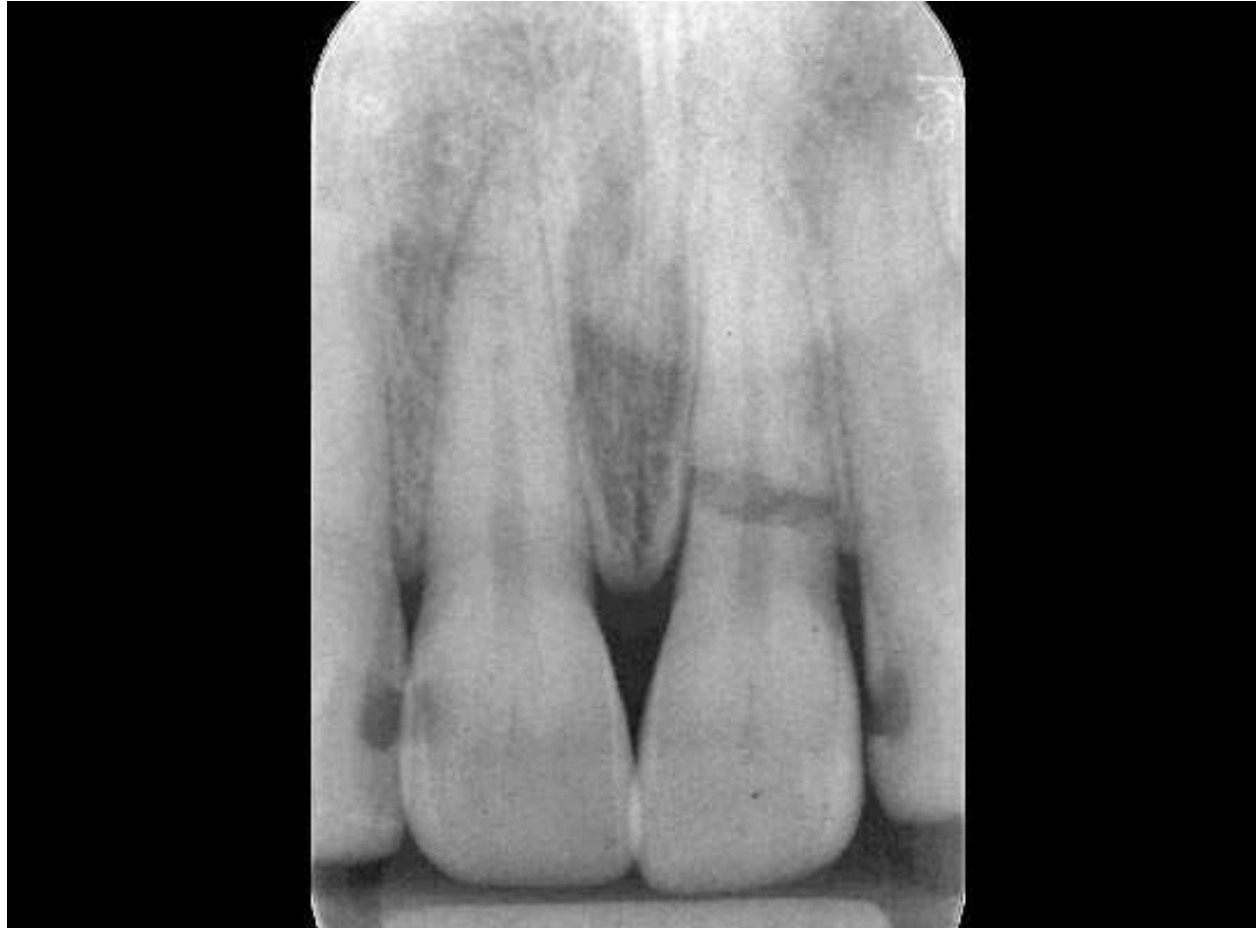INSUFFICIENT
CROWN - ROOT RATIO



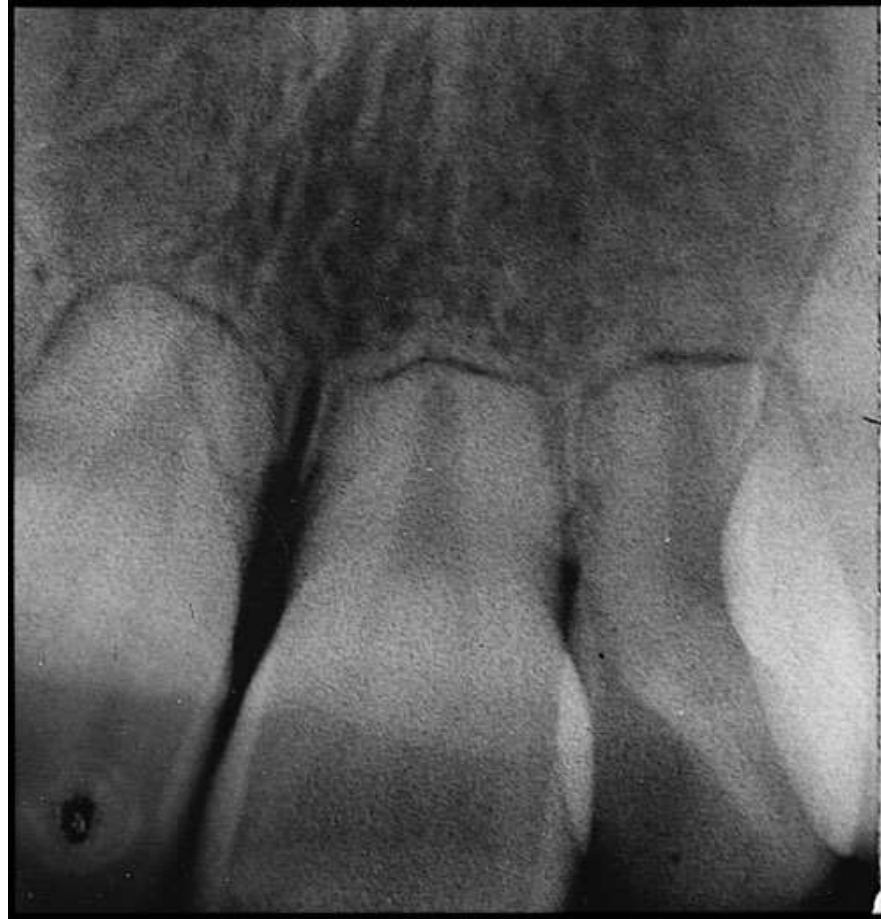NON RESTORABLE CARIOUS LESIONS



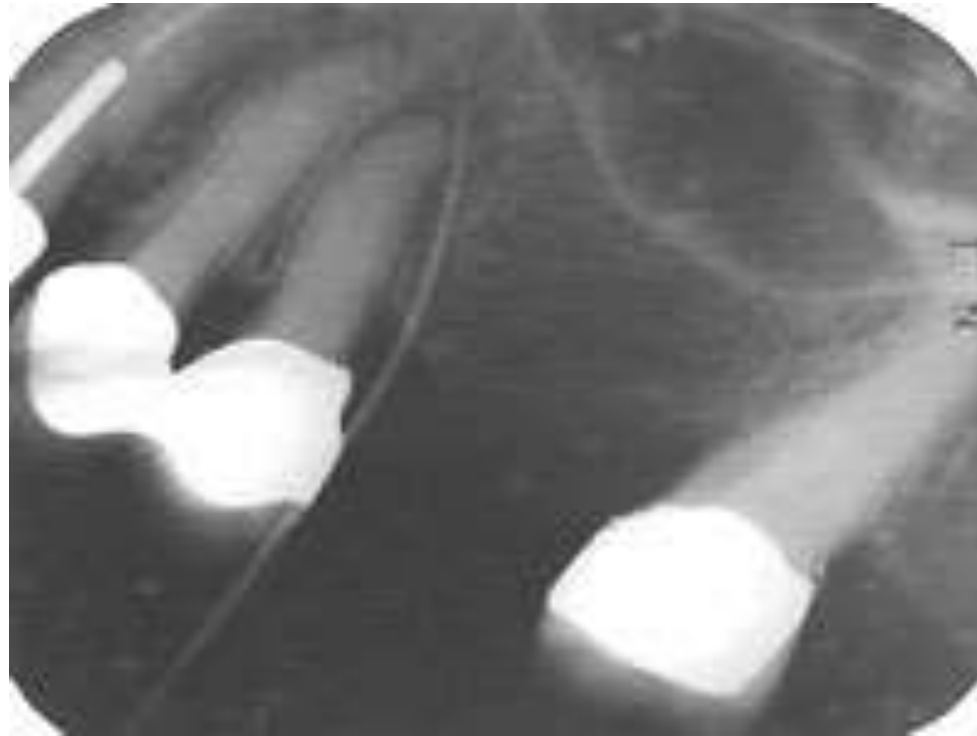ROOT FRACTURES



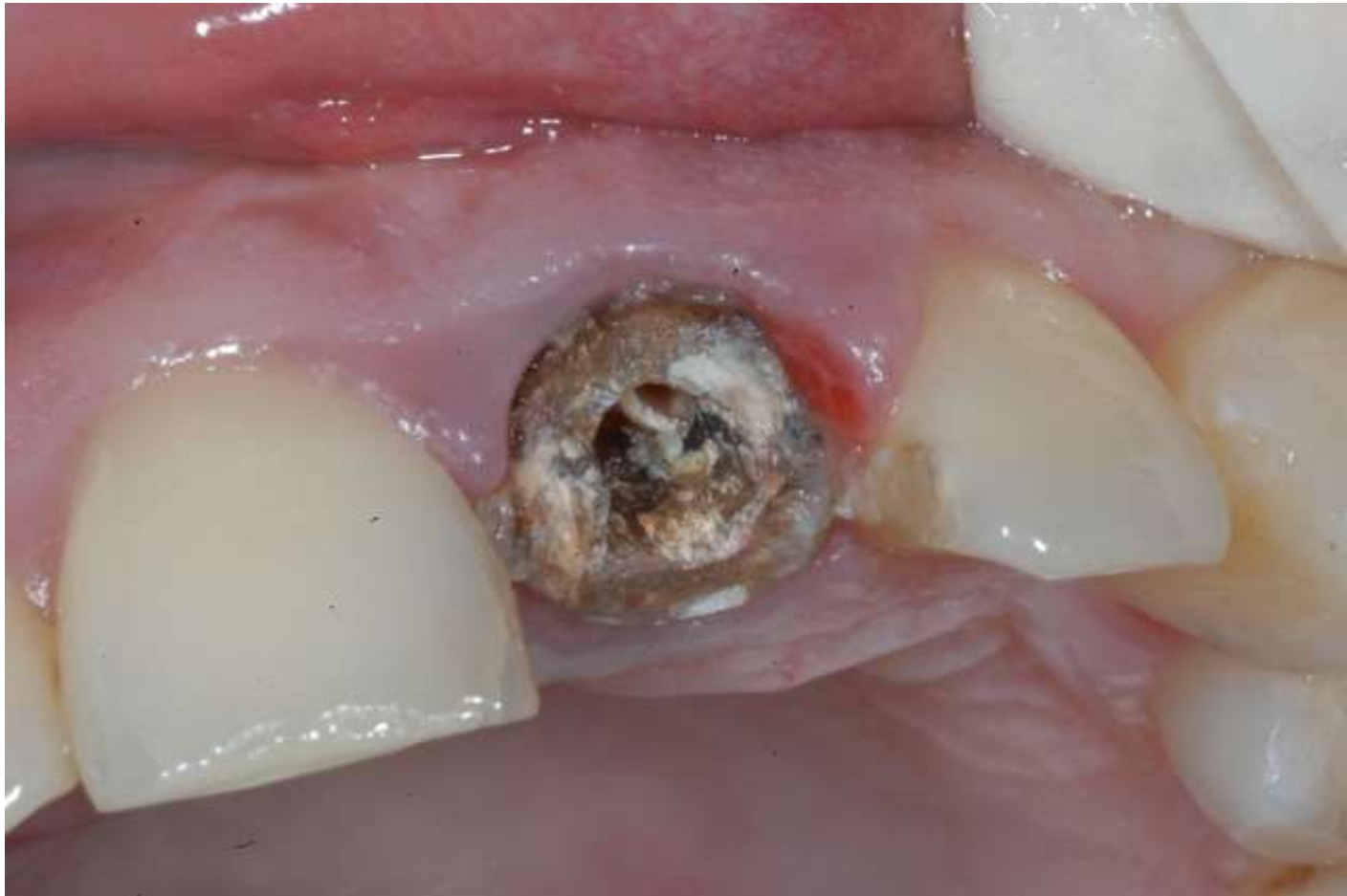ROOT RESORPTION



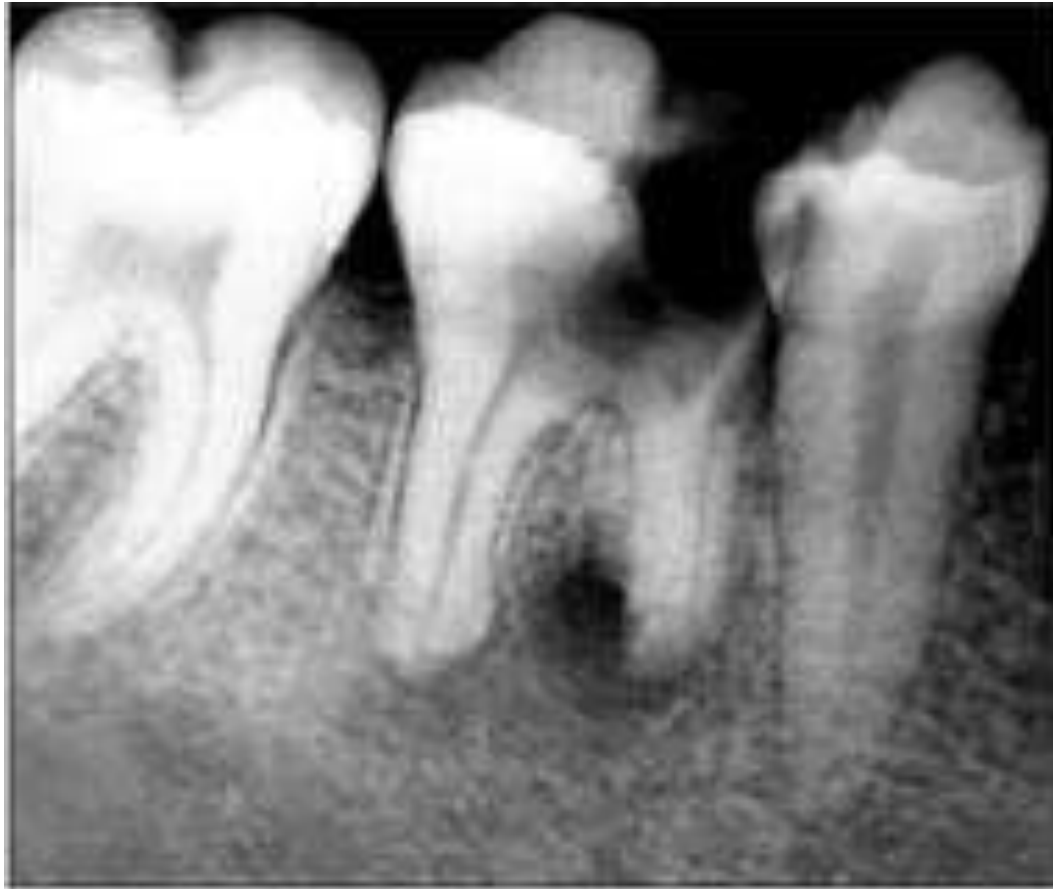QUESTIONABLE TEETH IN NEED OF ENDODONTIC TREATMENT



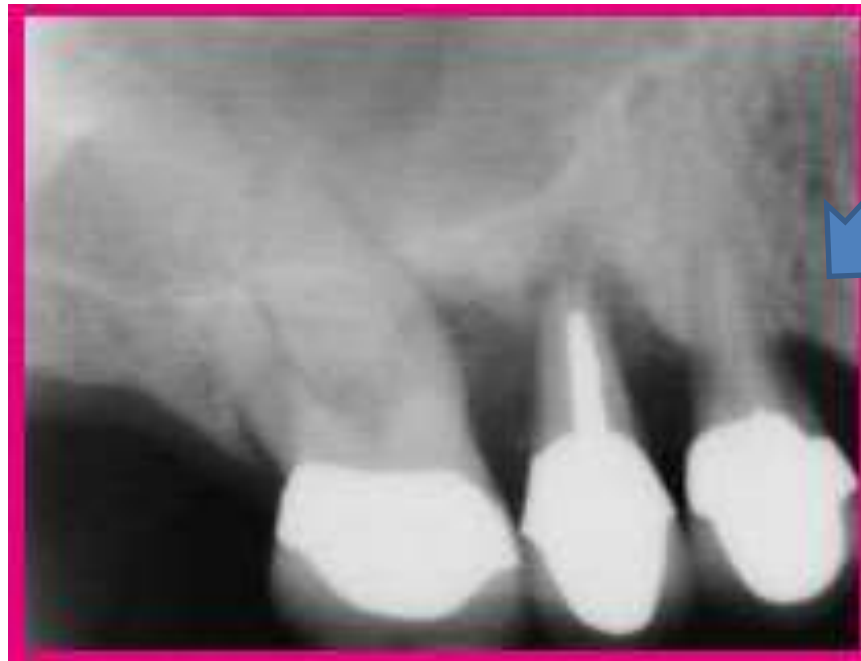TOOTH REQUIRING ROOT AMPUTATION



HEMISECTION



QUESTIONABLE PROGNOSIS



THINGS TO CONSIDER BEFORE INITIATING TREATMENT

ESTHETIC ZONE

SCALLOPING OF THE
PERIODONTIUM



BECKER et al 1997 &
KAN 2003

LEVEL OF THE CRESTAL AND
INTERPROXIMAL BONE

SMILE LINE

GINGIVAL BIOTYPE

THINGS TO CONSIDER BEFORE INITIATING TREATMENT

PROPOSED INTER
IMPLANT DISTANCE

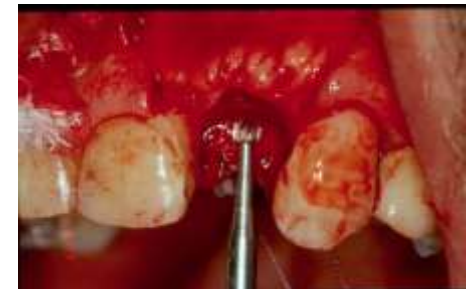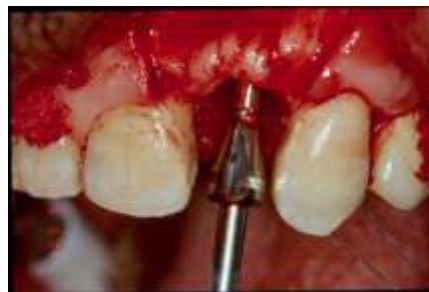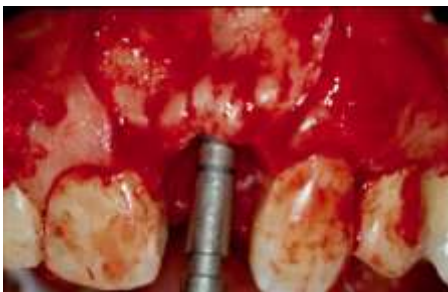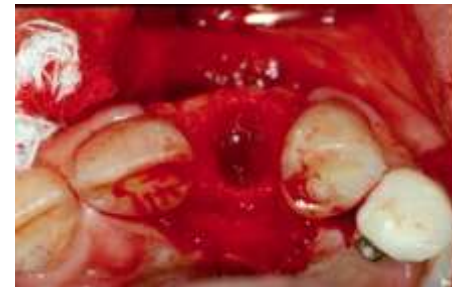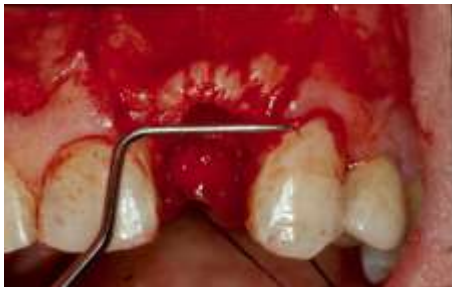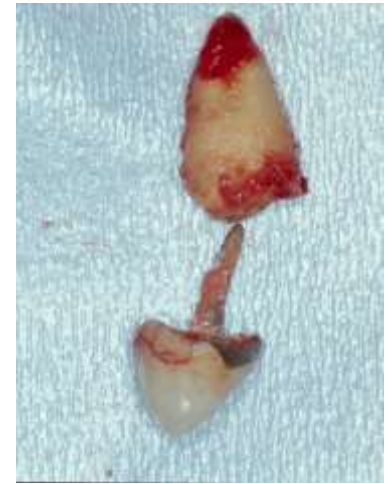
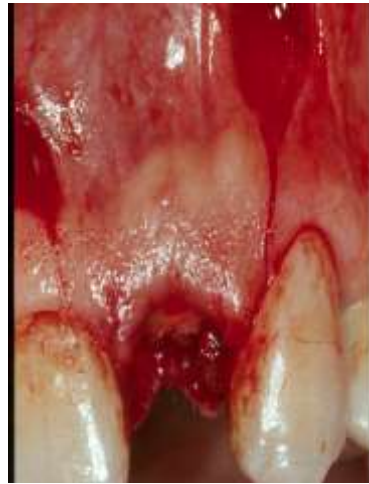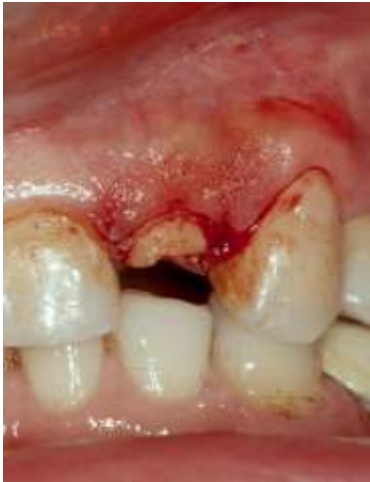EXISTING CONTACT
RELATIONSHIP

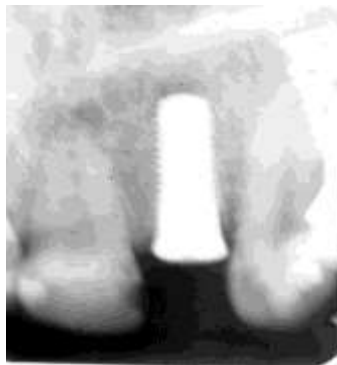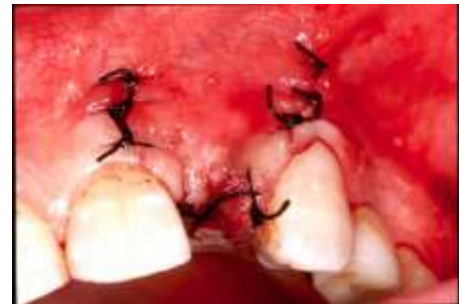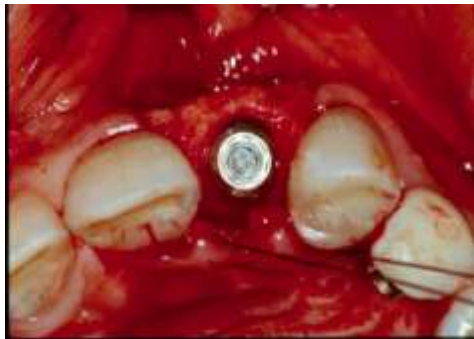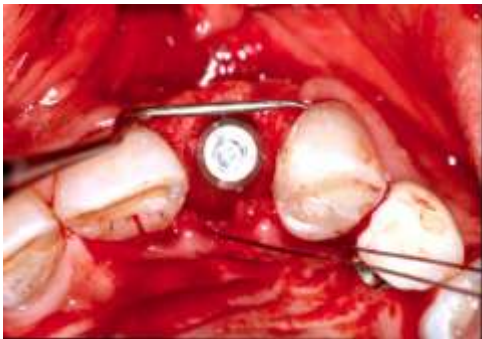
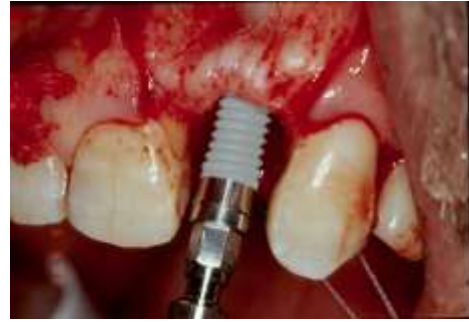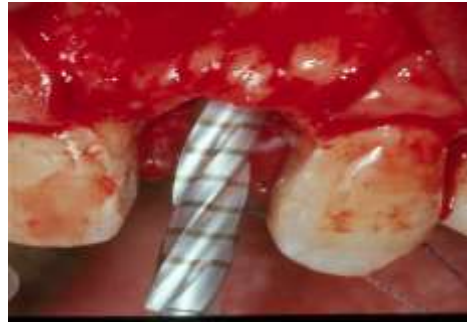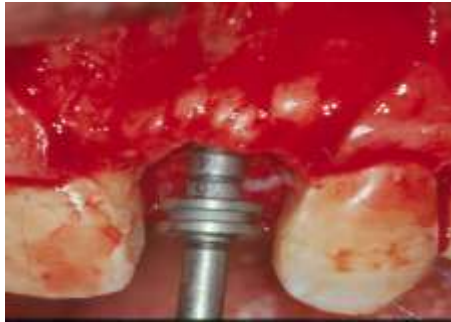
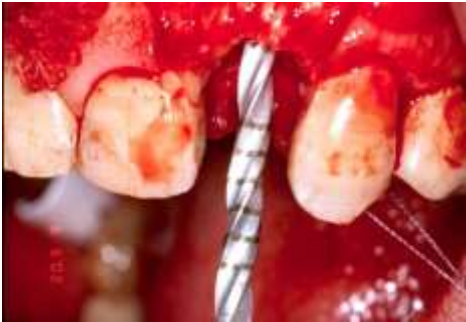INTERPROXIMAL BONE



TARNOW et al 1992, 2003

SURGICAL PROCEDURE





- USE A MOLT C2 CURETTE (HUFRIEDY) – USEFULL TO LUXATE THE ROOT MESIO – DISTALLY.
- AVOID BUCCO-LINGUAL MOVEMENTS.
- ANTERIOR MAXILLARY TOOTH REGION – AVOID THE IMPLANT PLACEMENT DIRECTLY INTO THE SOCKET – CHANCES OF PERFEORATION OF THE BUCCAL PLATE.
- AXIS OF IMPLANT SHOULD CORRESPOND TO ADJACENT TEETH OR SLIGHTLY PALATAL TO THE LANDMARK.

- IMPLANT HEAD SHOULD BE MINIMALL 3MM APICAL TO THE IMAGINARY LINE CONNECTING THE CEJ OF ADJACENT TEETH.
- IMPLANT SHOULD BE APICAL TO THE INTERPROXIMAL AND CRESTAL BONE – FACILLITATES PROPER IMPLANT EMERGENCE PROFILE AND RESTORATION.

BONY GAP – *JUMPING DISTANCE*

- **AKIMOTO et al 1999 & ALKBERTSSON et al 1988** – CONNECTIVE TISSUE FORMATION BETWEEN CORONAL IMPLANT ASPECT AND THE SURROUNDING BONE.
- **CHEN et al 1999** IN HIS PROSPECTIVE TRIAL – CONCLUDED THAT THERE WAS NO SIGNIFICANT DIFFERENCE IN EITHER VERTICAL DEFECT HEIGHT AND HORIZONTAL DEFECT DEPTH IN ANY OF THE GROUPS EITHER ALONE OR IN COMBINATION WITH MEMBRANES OR AUTOGENOUS GRAFTS.

- **BERMAN et al 2003, BOTICELLI et al 2004** – DEMONSTRATED BONE FILL BETWEEN IMPLANT AND BONE – WITH OR WITHOUT BONE GRAFTS.
- **BOTICELLI et al 2004** – CREATED 1.0 TO 2.5 MM BONY DEFECTS IN DOGS AND CHECKED FOR HEALING AFTER 4 MONTHS – COMPLETE BONE FILL.

LANDMARK STUDIES

- ✓ 1989 LAZZARA WAS THE FIRST TO PLACE IMPLANT IN EXTRACTION SOCKET.
- ✓ BECKER et al 1994,1999 REPORTED 93.5% OF IMPLANT SURVIVAL RATE – 5YR PERIOD.
- ✓ GRUDER et al 1996 & POLISHI et al 2000 WERE THE AUTHORS WHO GAVE RELIABILITY TO IMPLANTS PLACED AT THE TIME OF TOOTH EXTRACTION.
- ✓ BECKER et al 1994, ten BERGENKATE 1996 – PLACED AUTOGENOUS GRAFTS IN THE IMMEDIATE IMPLANT PLACEMENT SITE.

- ✓ **BUSER et al 1996, HERNIMEN et al 1993** – PLACED DEEP FREEZE DRIED BONE GRAFTS AND BARRIER MEMBRANES.
- ✓ **BECKER et al 2005** – CUMULATIVE IMPLANT SURVIVAL RATE OF 98% AND THE MEAN STABILITY AT THE TIME OF IMPLANT PLACEMENT WAS 62.0 ISQ AND AFTER 1YR IT WAS 64.0 ISQ
ISQ – IMPLANT STABILITY QUOTIENT UNITS
IMPLANTS WITH GREATER THAN 50 % ARE CONSIDERED AS CLINICALLY STABLE

NOVAES et al 1995, VILLA&RANGERS 2005 – CASE SERIES
– 2YR – CUMULATIVE IMPLANT SURVIVAL RATE WAS 100
%,(HE ALSO CONCLUDED THAT OPEN FLAP OR MIS – NO
DIFFERENCE).

CONCLUSION

- TOOTH WITHIN A DAY

TO

TOOTH WITHIN A HOUR

BASED ON RESTORATION OF IMPLANTS

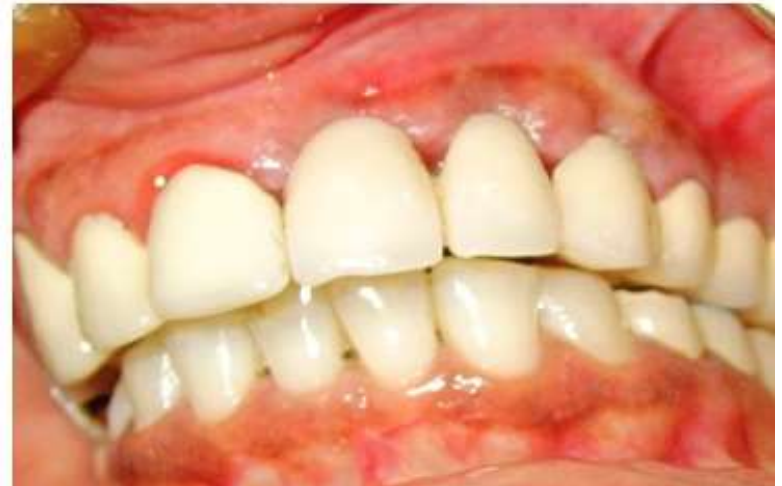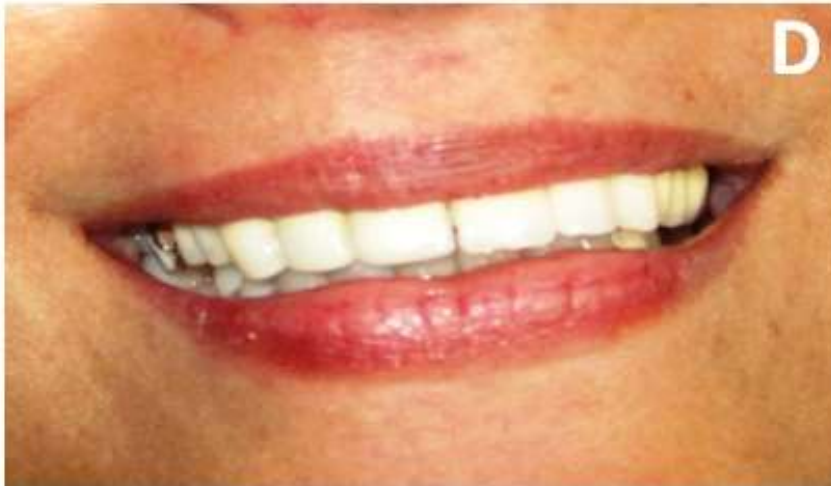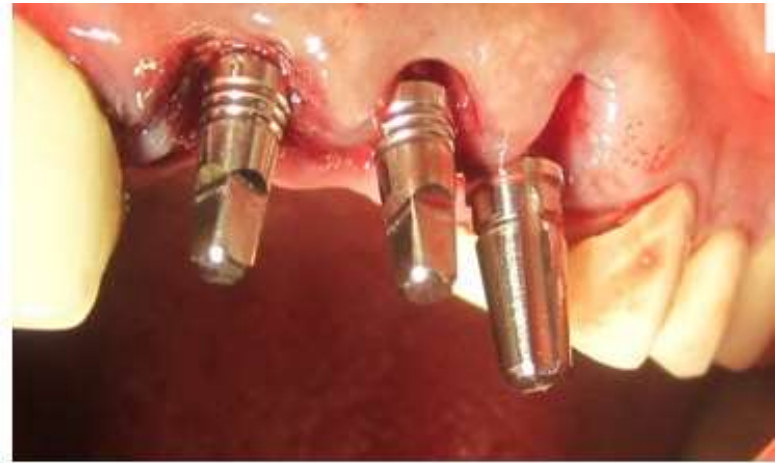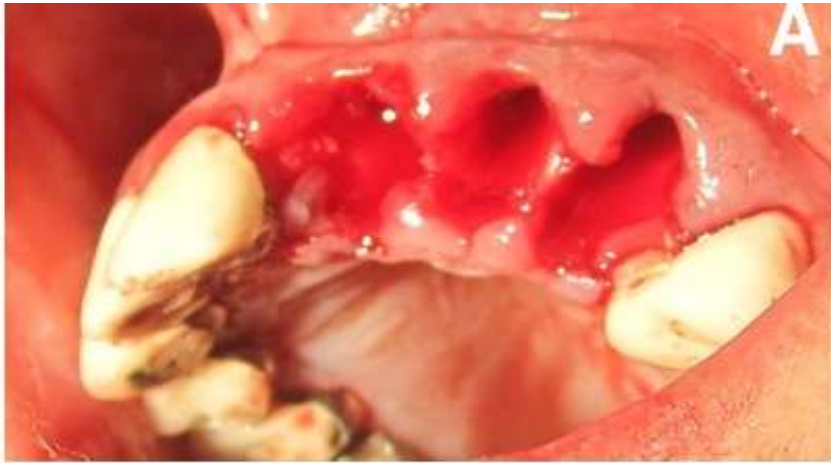- IMMEDIATE / DIRECT LOADING
- EARLY / EARLY FUNCTIONAL LOADING
- DELAYED LOADING

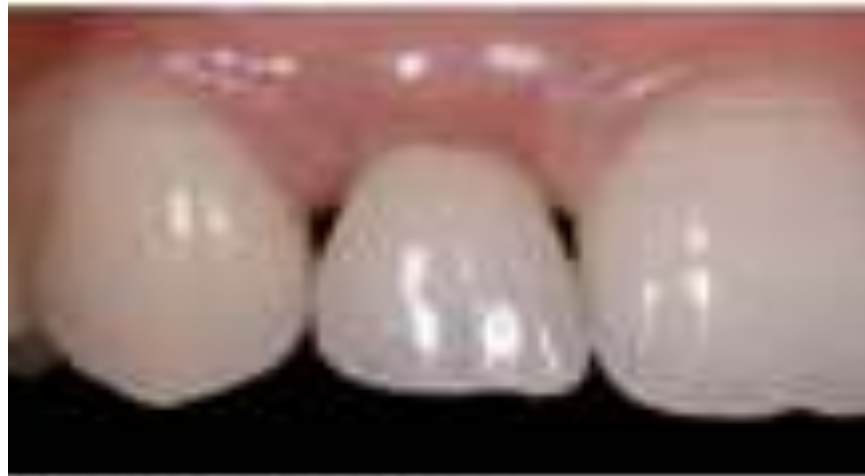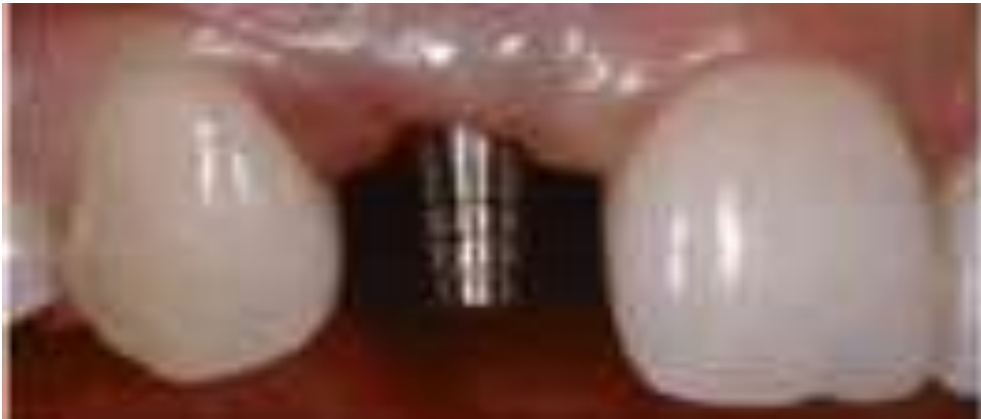IMMEDIATE / DIRECT LOADING

- THE PROVISIONAL / DEFINITIVE PROSTHETIC CONSTRUCTION IS ATTACHED TO THE IMPLANT WITHIN 24 HRS OF THE IMPLANT PLACEMENT.

EARLY / EARLY FUNCTIONAL LOADING

- THE PROVISIONAL / DEFINITIVE PROSTHETIC CONSTRUCTION IS ATTACHED TO THE IMPLANT WITHIN DAYS / WEEKS OF THE IMPLANT BEING PLACED.





Temporary crown

DELAYED LOADING

- THE PROVISIONAL / DEFINITIVE PROSTHETIC CONSTRUCTION IS ATTACHED AT A SECOND PROCEDURE AFTER A CONVENTIONAL HEALING PERIOD OF 3 TO 6 MONTHS.

Comparison of implant survival rate between Immediate loading vs Delayed loading

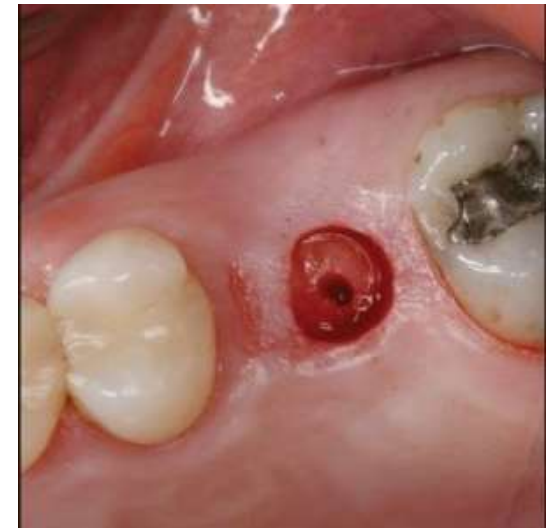
- DATAS show high survival rates of immediately loaded implants along with osseointegration, with high percentages of bone-to-implant contacts based on histologic evaluation from human and animal studies of immediately and conventionally loaded implants.
- STILL LONGTERM STUDIES ARE NEEDED ON DIFFERENT BONE QUALITIES.

Basic Surgical Principles

- I. Preoperative mouthwash with 0.1% chlorhexidine.
- II. Perioral skin disinfection with alcohol solution.
- III. Antibiotic prophylaxis 2 hrs prior to surgery.
- IV. Low speed drilling
- V. Cooling spray during drilling with chilled sterile saline.
- VI. Use sharp drills
- VII. Implant should be placed with good initial stability.
- VIII. Implants should be allowed to heal without loading or micromovement. (2-4 months for mandible, 4-6 months for maxilla.)

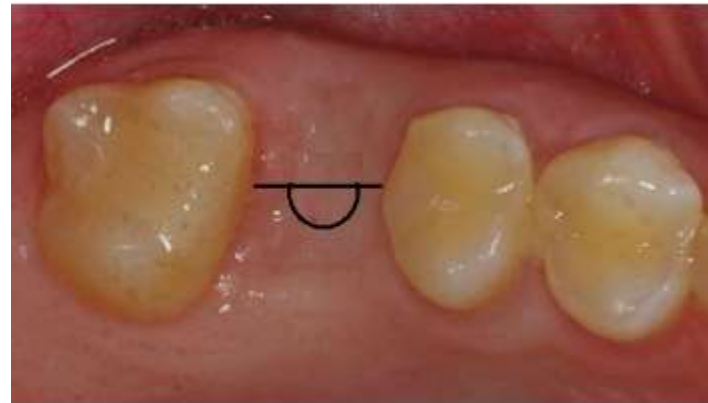
Implant Placement

- Flap elevation:
 - I. Punch approach
 - II. Crestal incision
 - III. Remote incision

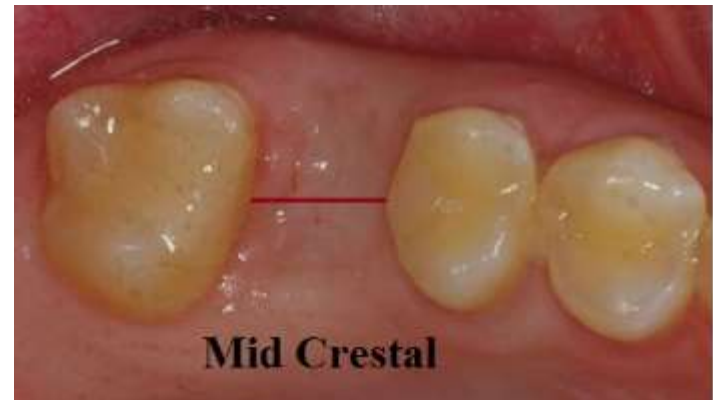

- **Punch approach:** use where tissue quality is good with minimum 2-3mm of attached gingiva is available.
- BP blade or punch drill can be used.
- To attain precise placement surgical guide can be used.

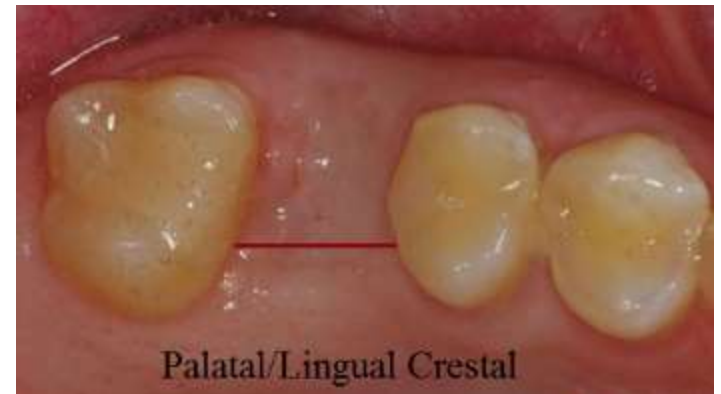- **½ punch approach:** used where buccal tissue is not sufficient.
- First create mid crestal incision and reflect a full thickness flap then use punch approach.
- Minimal amount of lingual/palatal tissue is removed.
- This flap design mostly used in cases with 1-stage procedure.



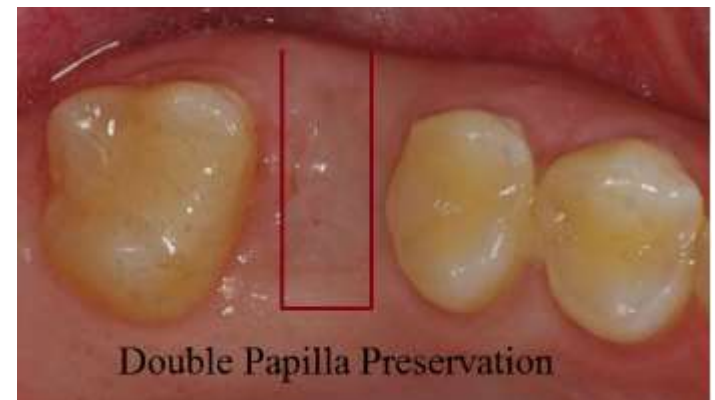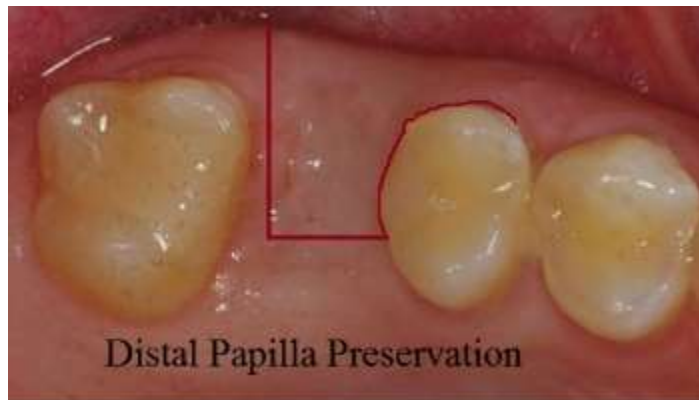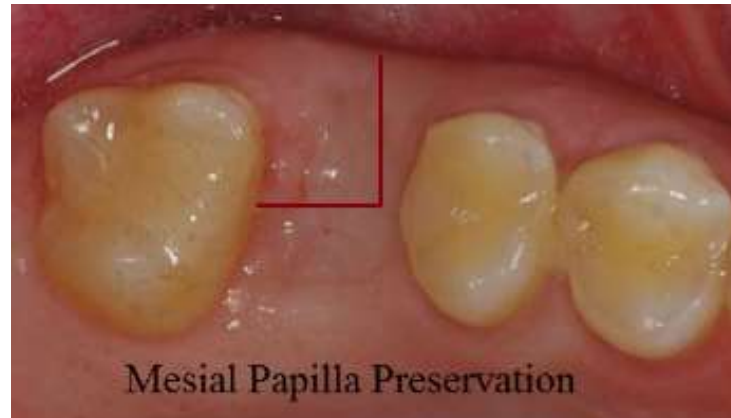- **Mid crestal incision:** used where sufficient buccal and lingual or palatal tissue is present.
- Incision is made in the crest with intrasulcular to adjacent teeth.
- Most common type of flap design after punch approach
- This design used in 1stage and 2 stage procedure



- **Palatal/lingual crestal flap:** used where there is insufficient or less buccal tissue available to rise full thickness flap.
- incision similar to midcrestal one given towards lingual or palatal side of the arch.
- Used in 1 stage and 2 stage implant procedure.



- Mesial papilla preservation:
- Distal papilla preservation
- Double papilla preservation



- **Bone preparation:**

- I. Drilling in bone may increase the temperature at the recipient site.

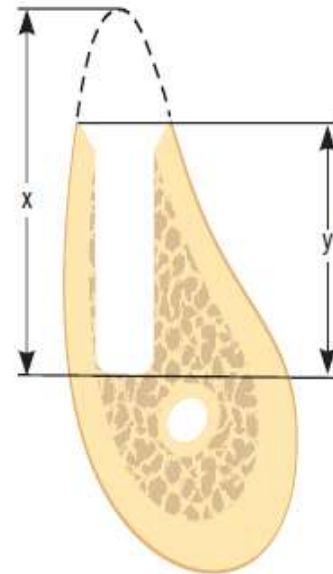
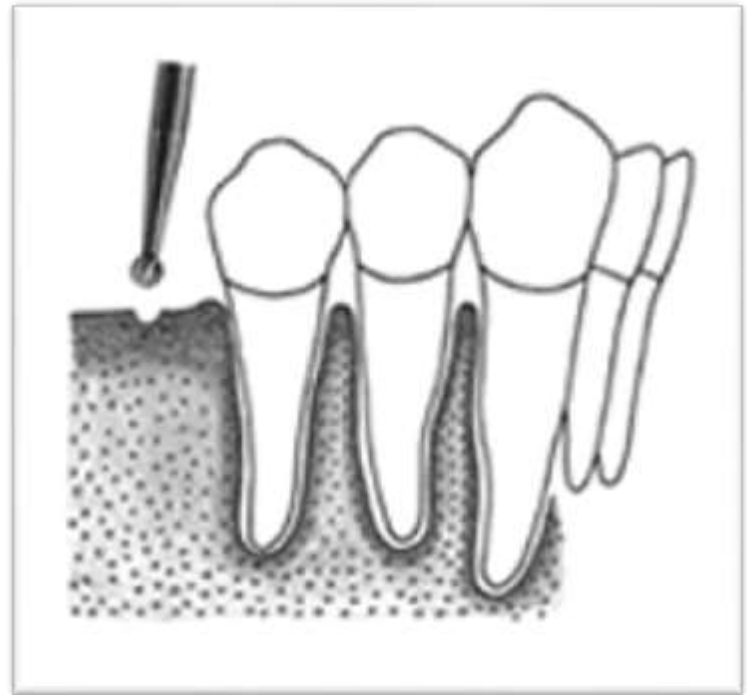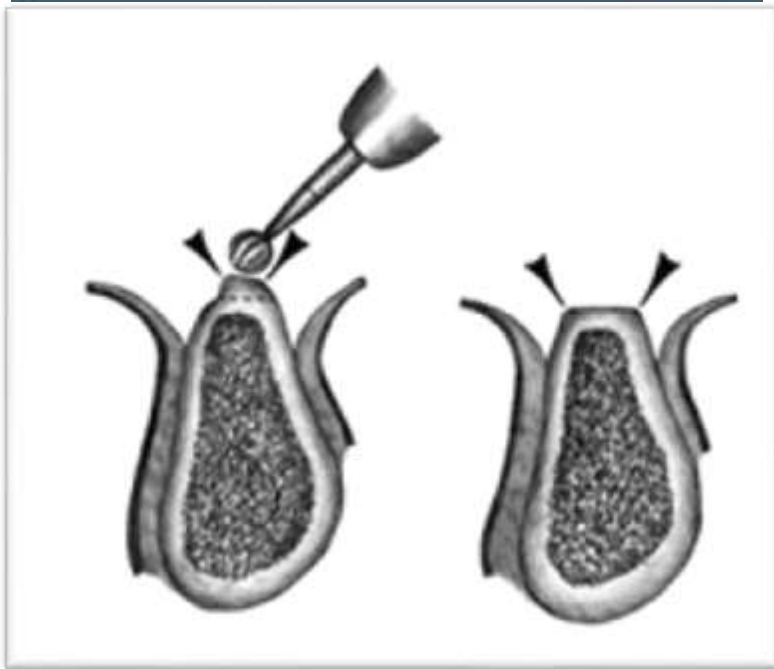
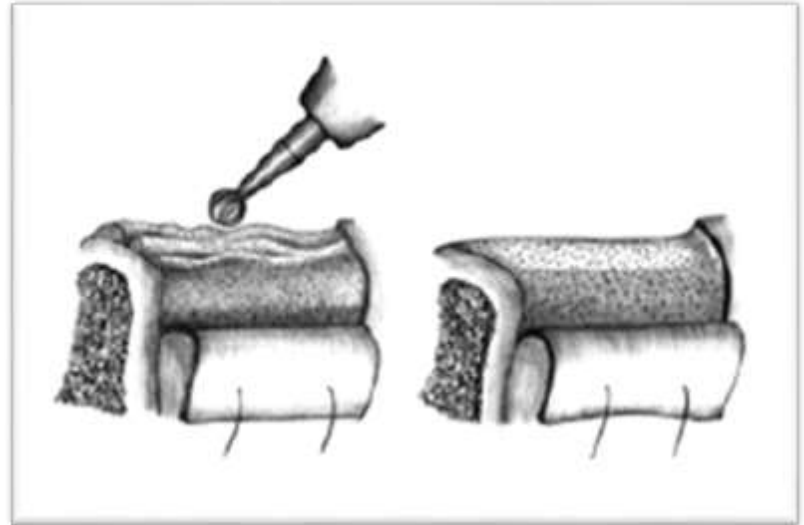
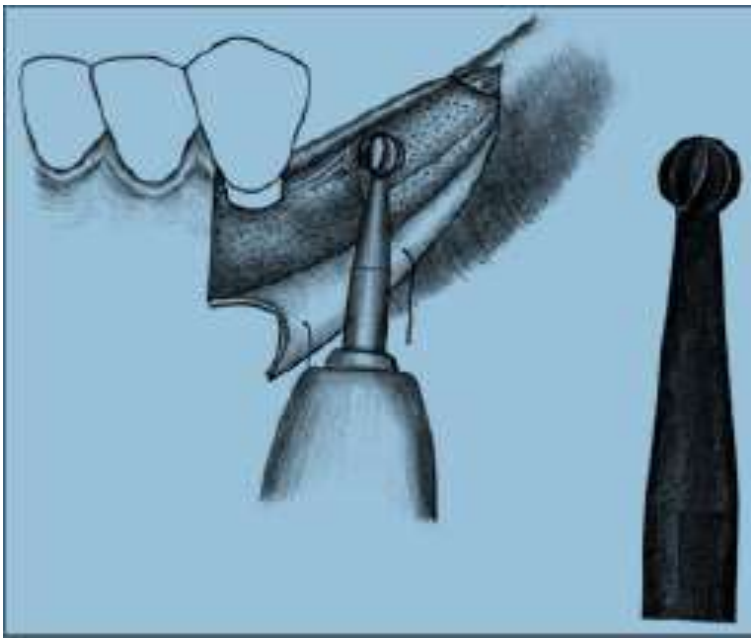

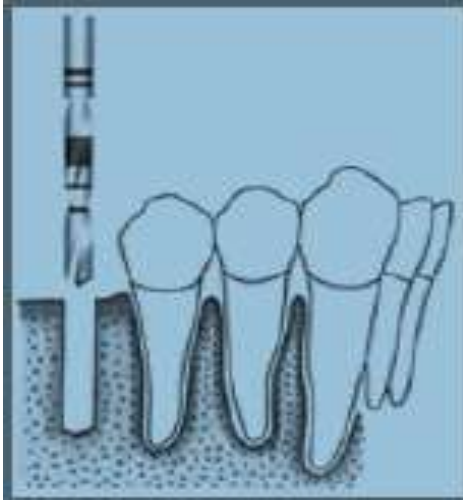
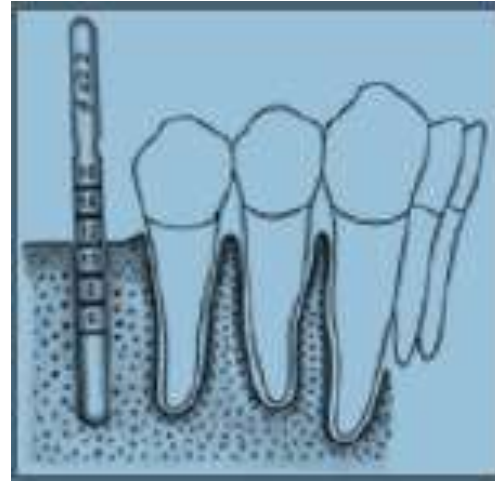Fig. 48-5 Schematic drawing showing maximum drilling depth (x) without reaching the nerve, as measured from the top of the crest, and implant site length (y), as measured from the lowest bone level in the canal entrance.

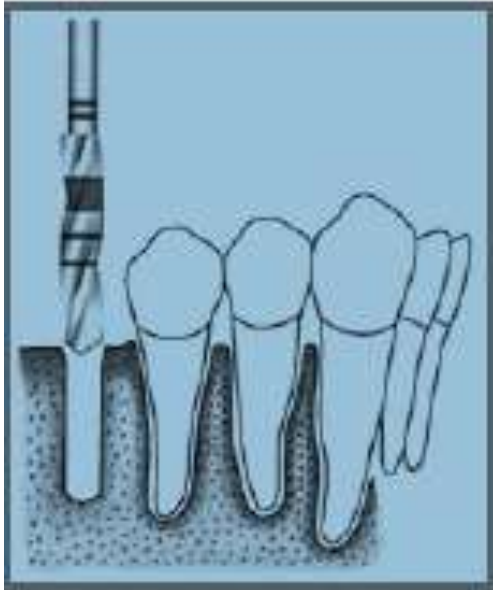




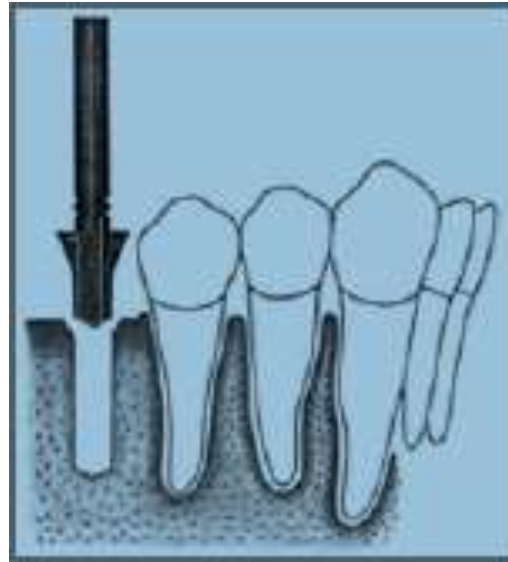Initial implant site preparation 2.2 mm diameter pilot drill



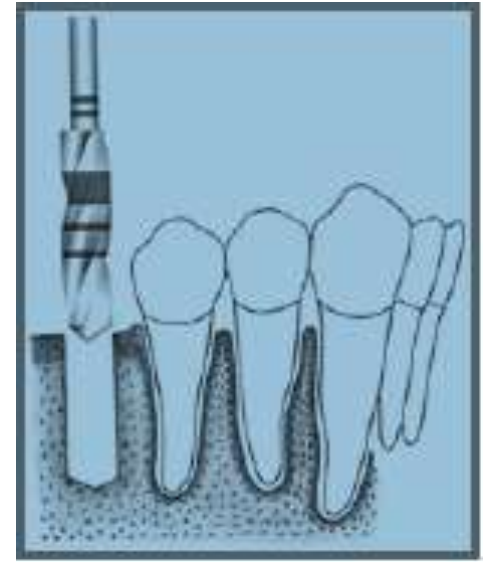
2.2 mm diameter guide pin use to check position and axis



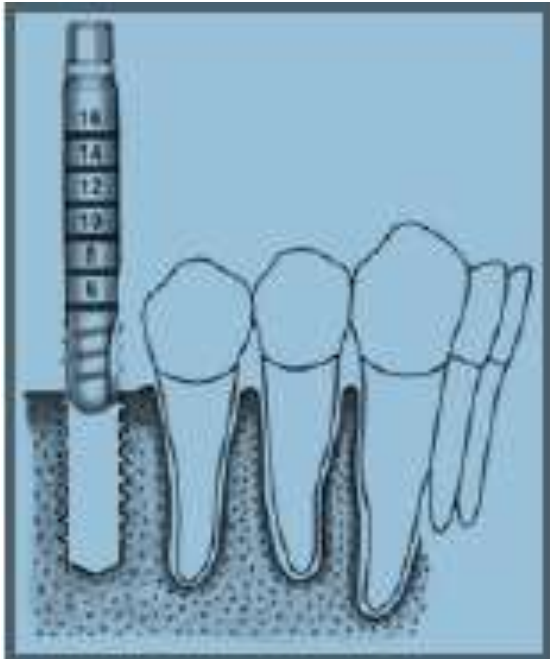
2.8mm diameter spiral drill



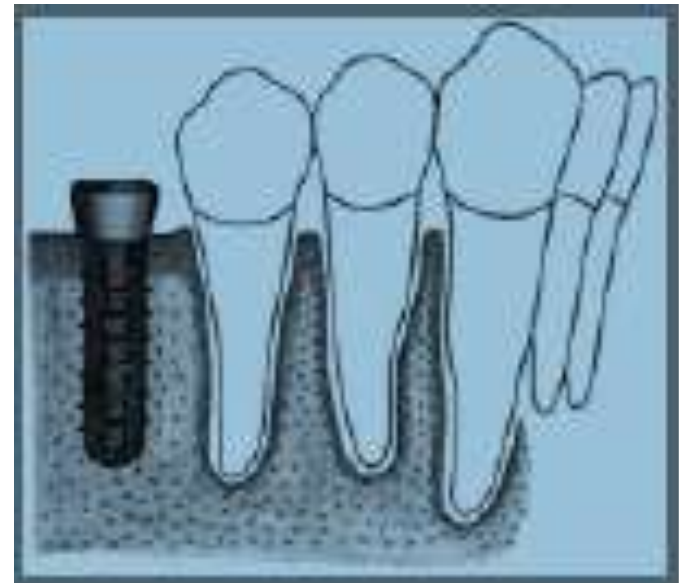
Profile drill increase surgical access to larger size drill



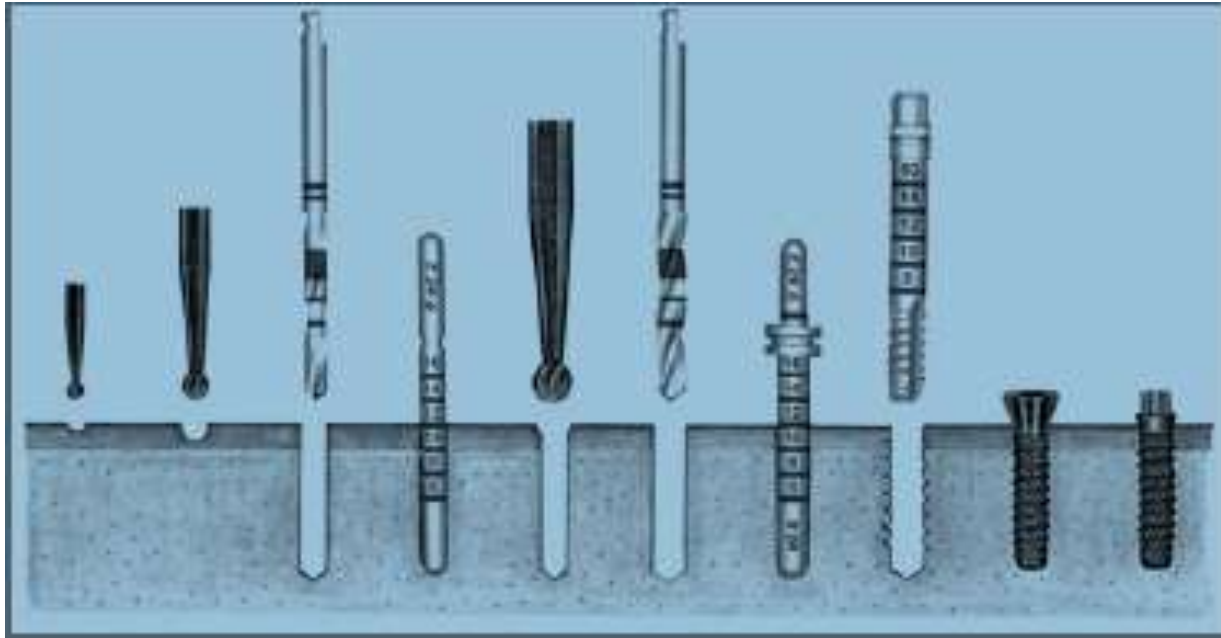
3.5 mm diameter spiral drill



Occasionally Bone tapping
prior to implant
placement (dense bone)



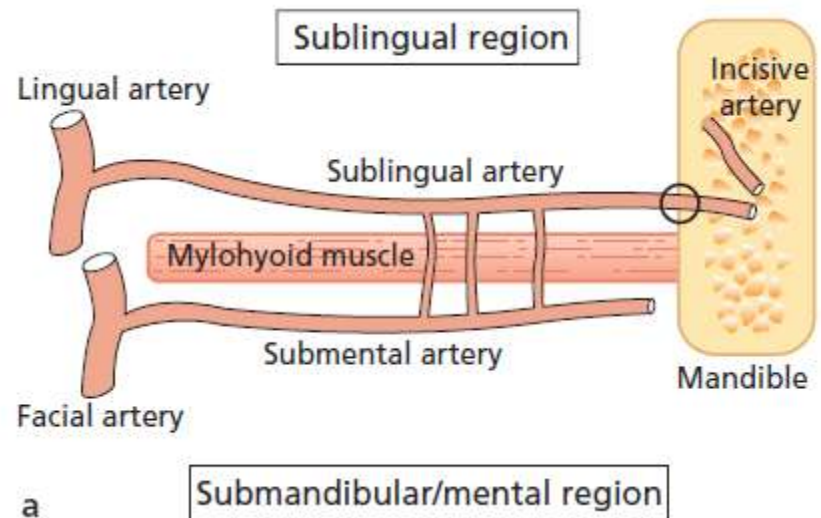
Standard implant , rough surface
positioned at the level of the alveolar
crest, implant shoulder at gingival
level.



- **Implant site is prepared to a diameter of 2.8mm to receive a narrow neck implant**
- **Standard implant site is prepared to a diameter of 3.5mm.**
- **Wide body or wide neck implant site is prepared to a diameter 4.2mm**

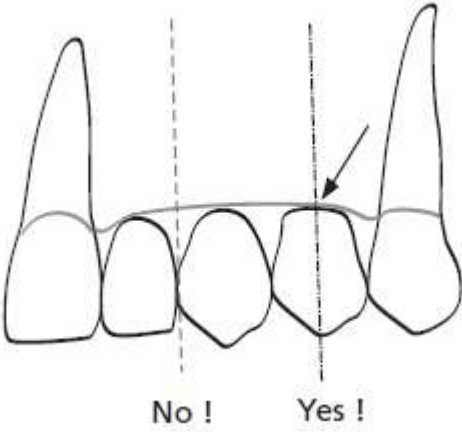
- Anatomical landmarks with potential risk:

- I. Maxillary sinus
- II. Nasal floor
- III. Inferior alveolar nerve
- IV. Submandibular fossa
- V. Mental foramina

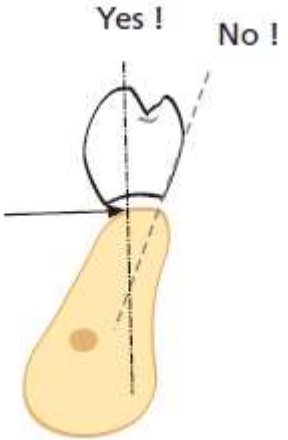
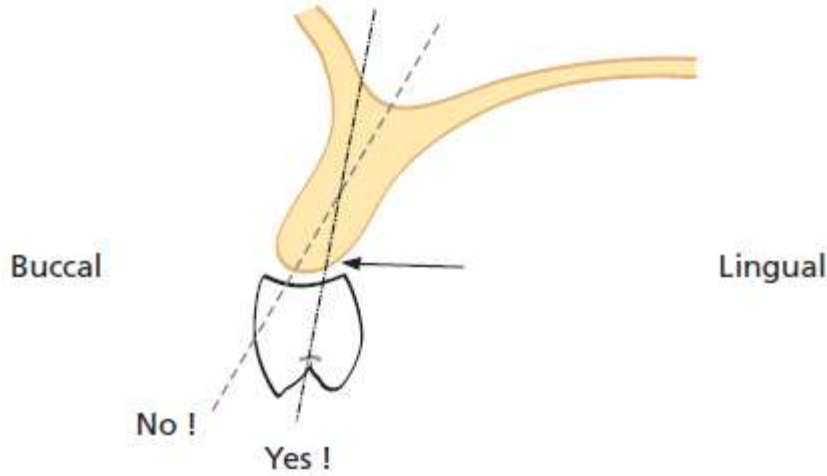


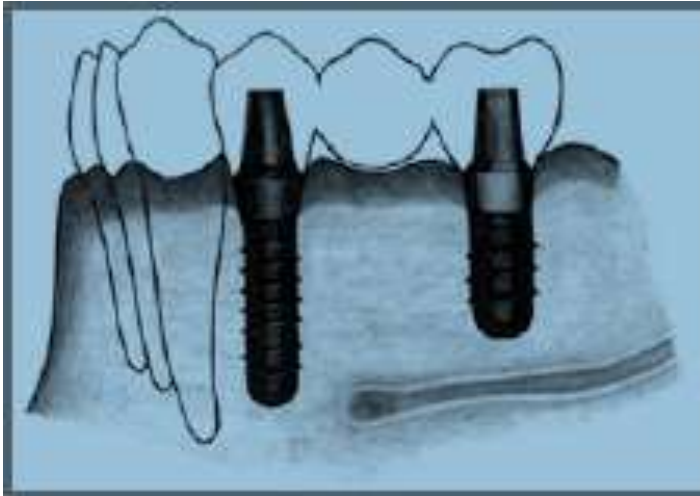
- **Implant position and length :**
 - I. If possible an implant should be placed in tooth position both in mesio-distal and bucco-lingual direction.
 - II. Starting point for insertion in bone located towards buccal side of crest in mandible, and towards palate in the maxilla due to presence of concavities.

Mesial

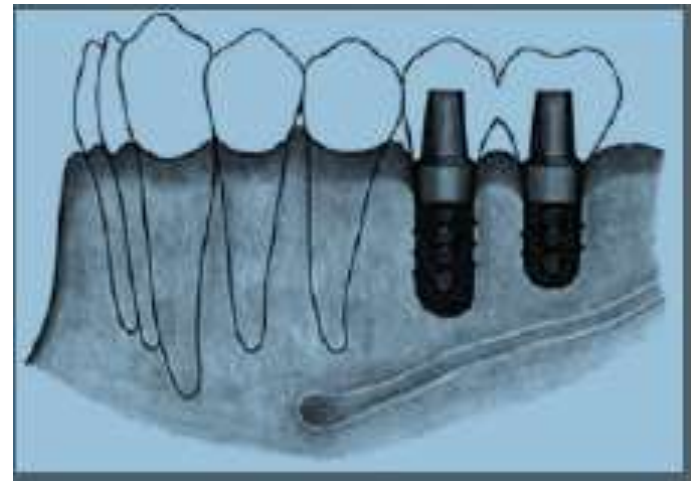


Distal

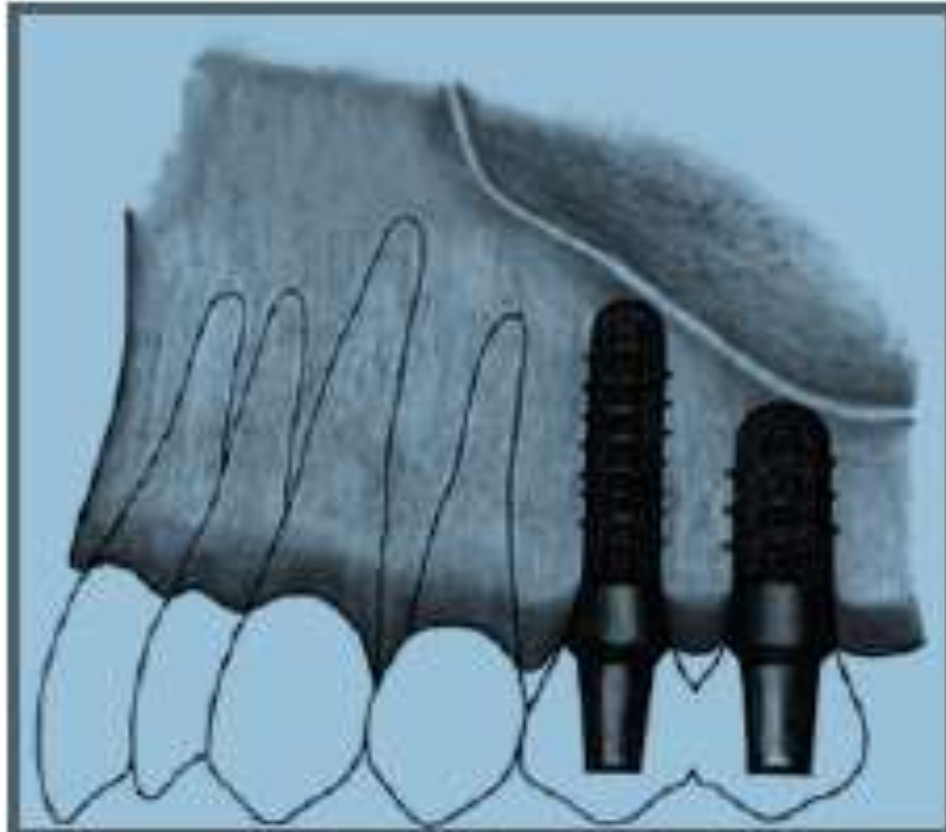




Long span mandibular distal extension- 8mm short implant in molar region

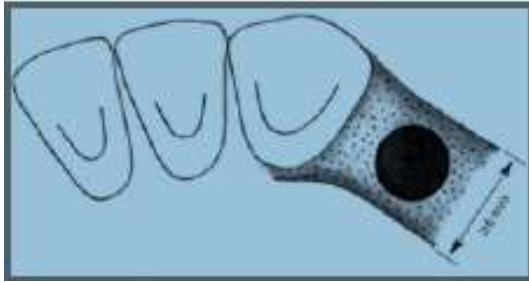


Short span mandibular distal extension, two short implants with lengths 6 and/or 8mm (splinted crowns)

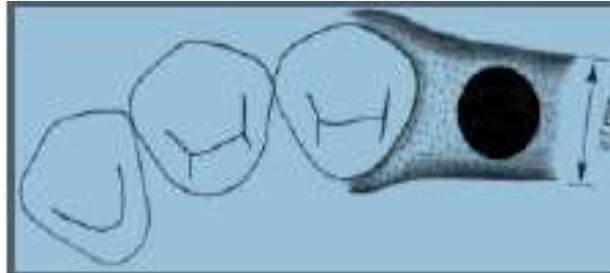


Maxillary posterior distal extension, maxillary sinus can be avoided with use of short implant. Here two implants (12 and 8mm) are inserted.

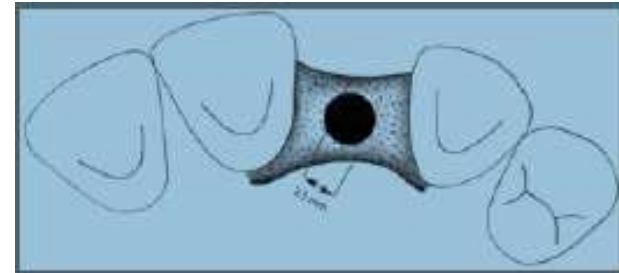
Crestal Width



Premolar site, a crest width of at least **6mm** recommended for standard implant

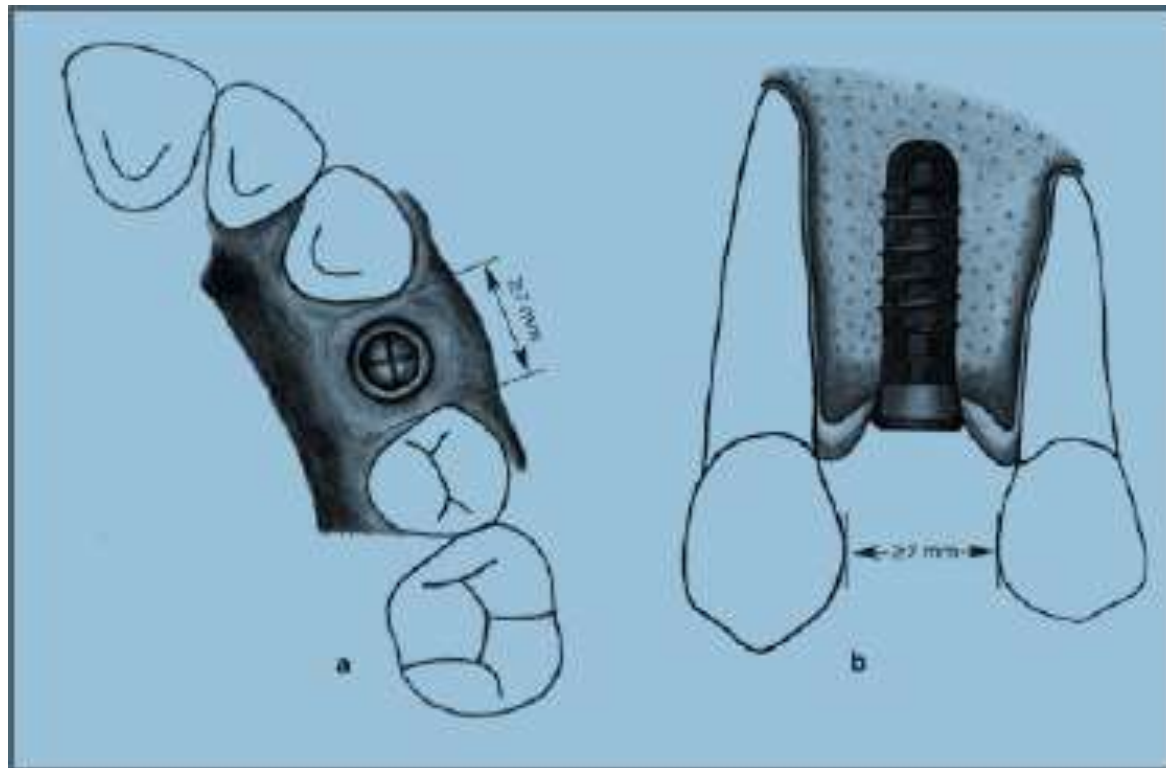


Molar site, wide body/
wide neck implant required minimum **crest width** of **7mm**

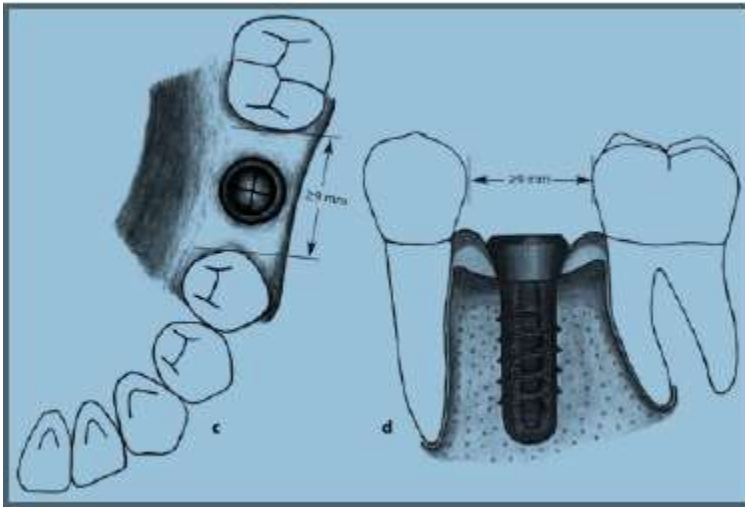


Anterior region, narrow neck implants required crestal width of **5mm**

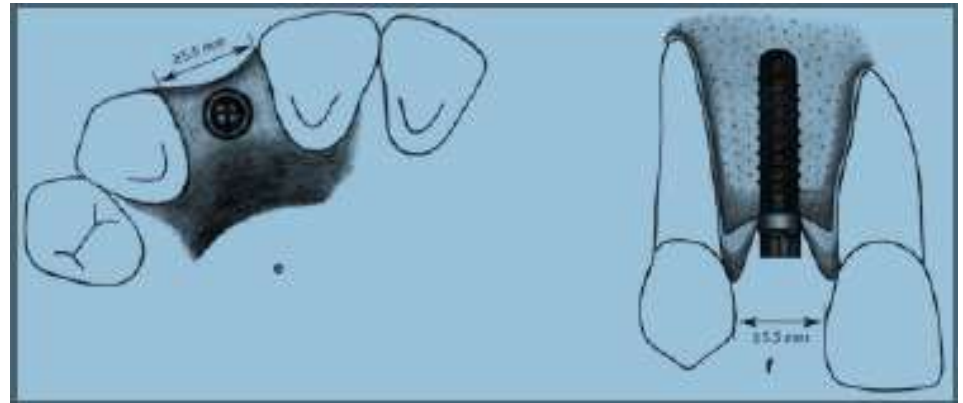
- **Minimum space of single tooth gaps for various implant types**



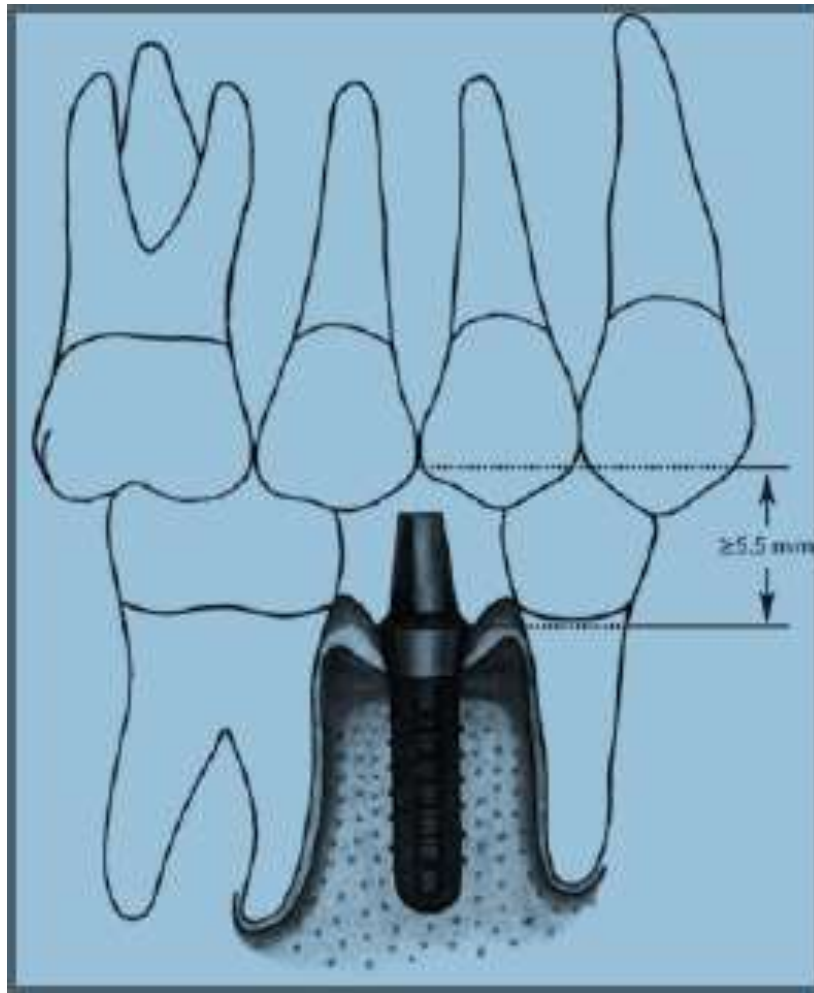
Occlusal and lateral view of regular neck implant.
A space of at least **7mm** is required for **4.8mm diameter implant shoulder**



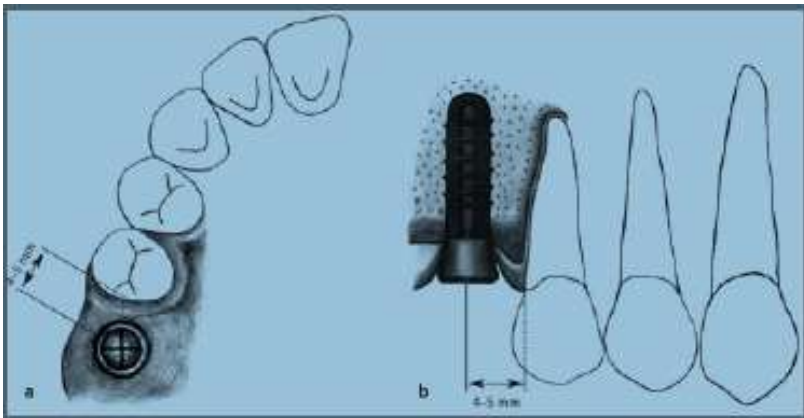
Wide neck implant, 6.5mm
 diameter implant shoulder requires
 a single tooth gap of at least **9mm**



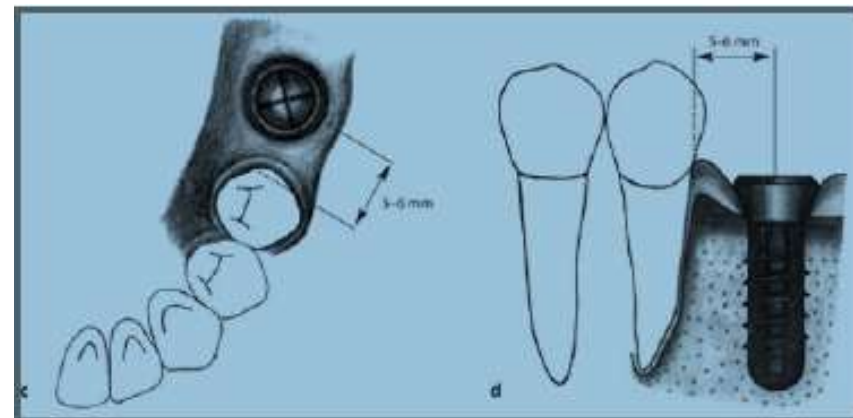
Narrow neck implant, minimum 3.5mm
 diameter implant shoulder
 is needed to accommodate the 5.5mm
 single tooth gap



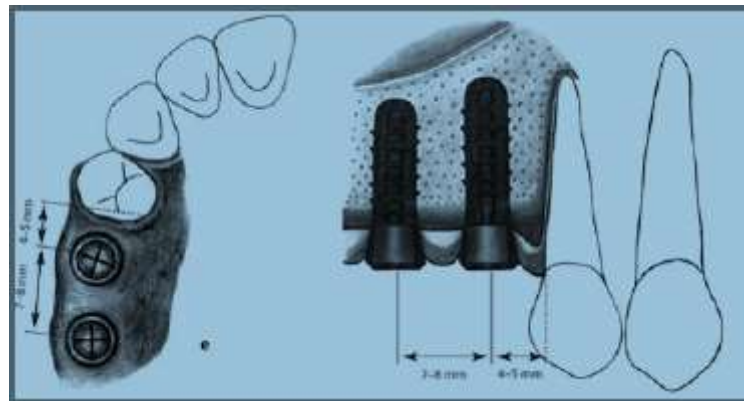
Minimum **interocclusal distance** of 5.5mm from the implant shoulder to the opposing dentation is necessary to allow the placement of abutment and crown



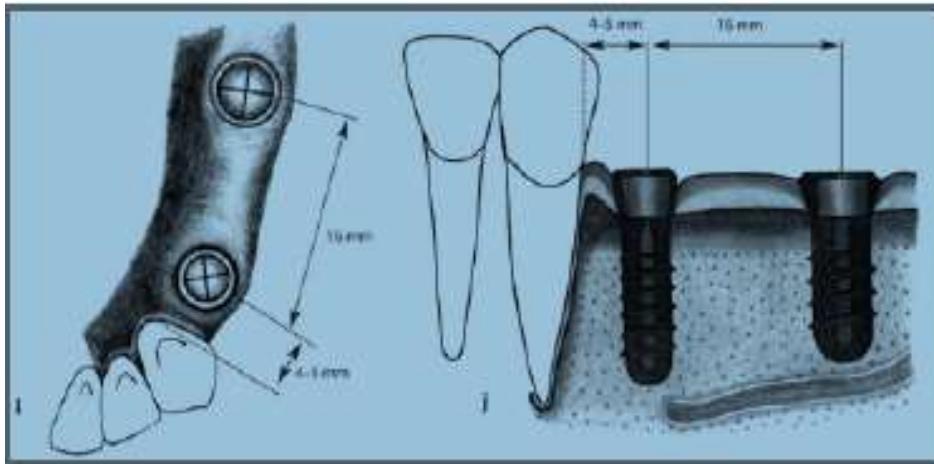
Regular neck implant placed next to tooth, **4-5mm distance** required **between central axis of the implant and root surface of tooth** at alveolar crest



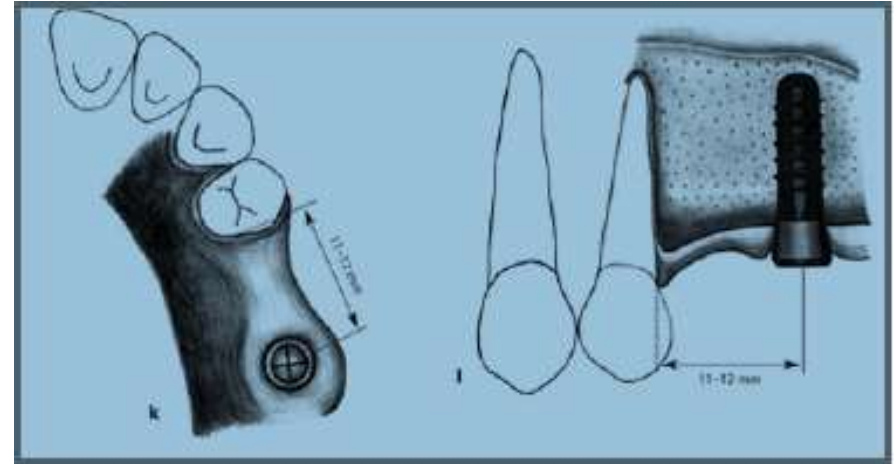
Wide neck implant placed next to second premolar, the wide neck implant is positioned approx. **5-6mm** from tooth



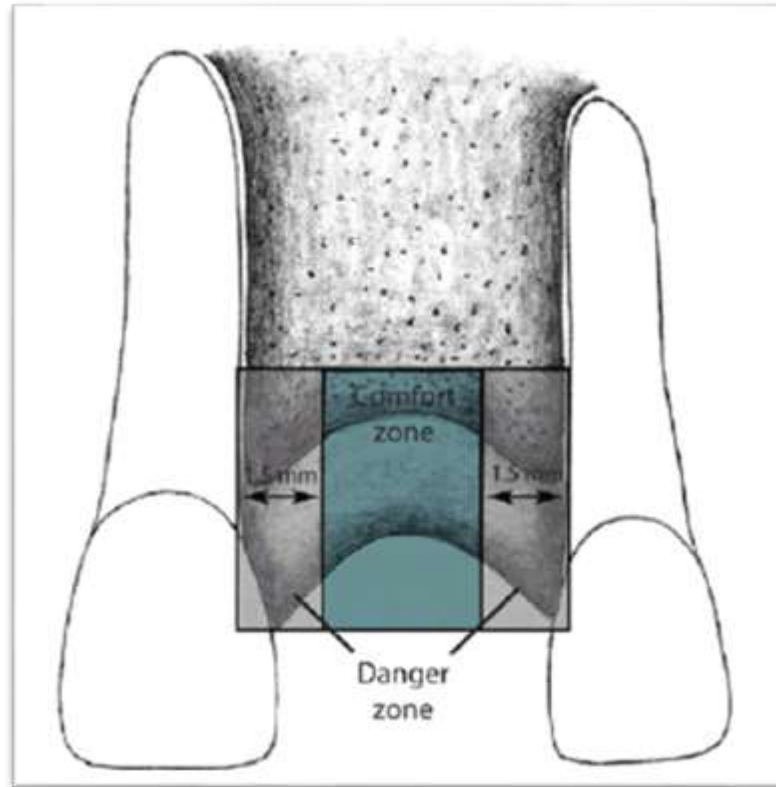
When Regular and wide neck implants are used to replace missing second premolar and molar, **regular neck should placed 4-5mm from tooth** and **wide neck implant should placed 9mm from anterior implant**



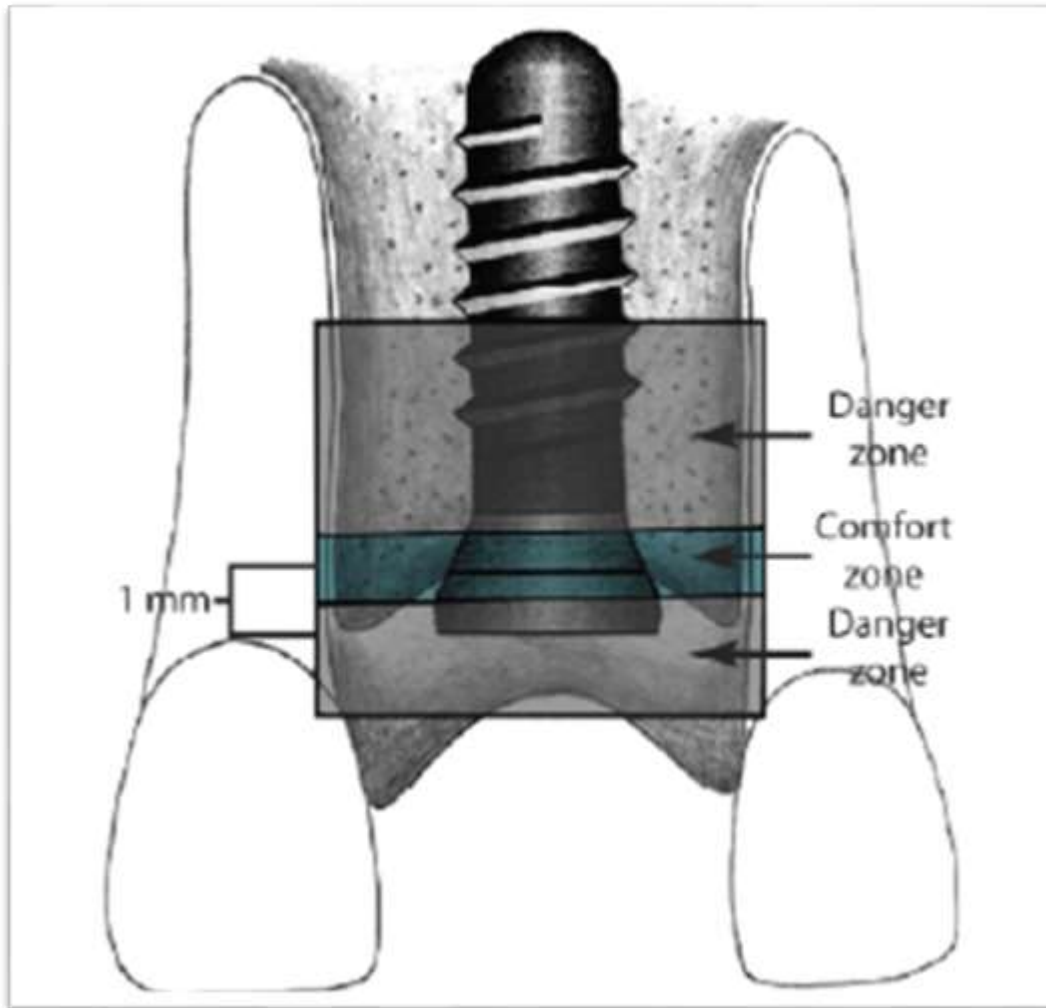
Extended posterior distal extension, the regular neck implant is positioned **4-5mm** from the tooth. The wide neck implant is inserted about **16mm** from the anterior implant.



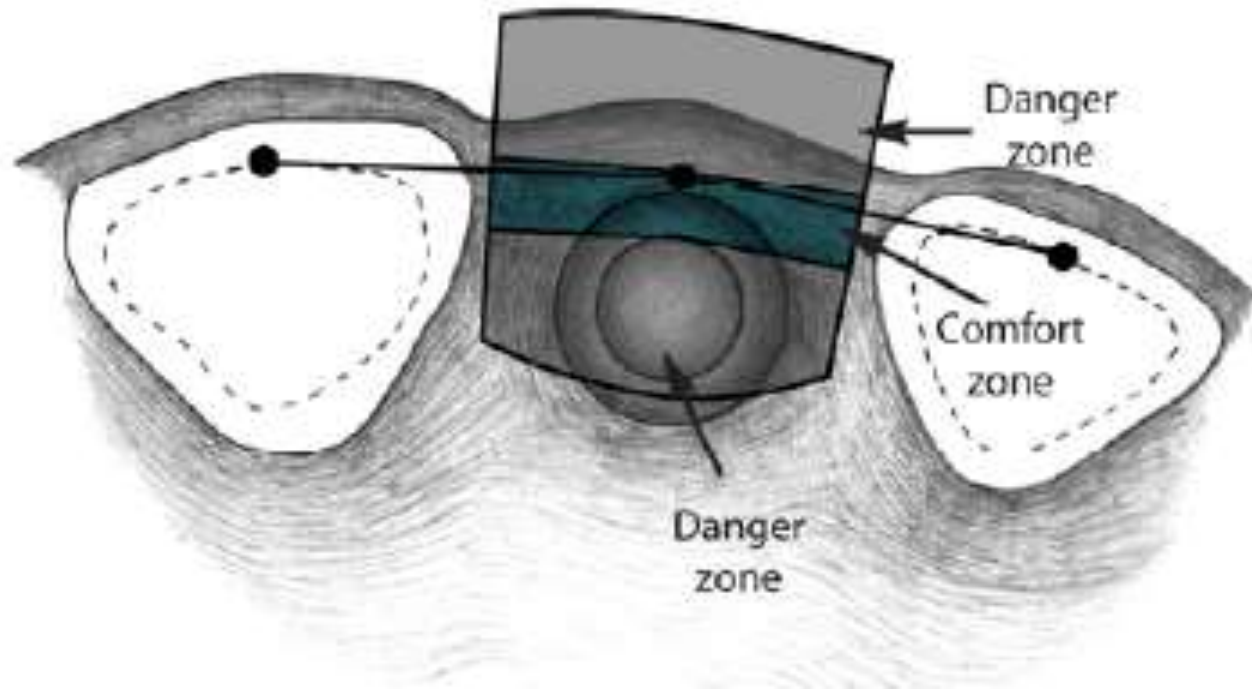
Short distal extension situation, **tooth implant supported three unit fixed partial denture**. implant is positioned **11-12mm** from the tooth



Safety zone of **approx. 1.5mm** should be maintained **between the implant and the roots of the adjacent teeth**

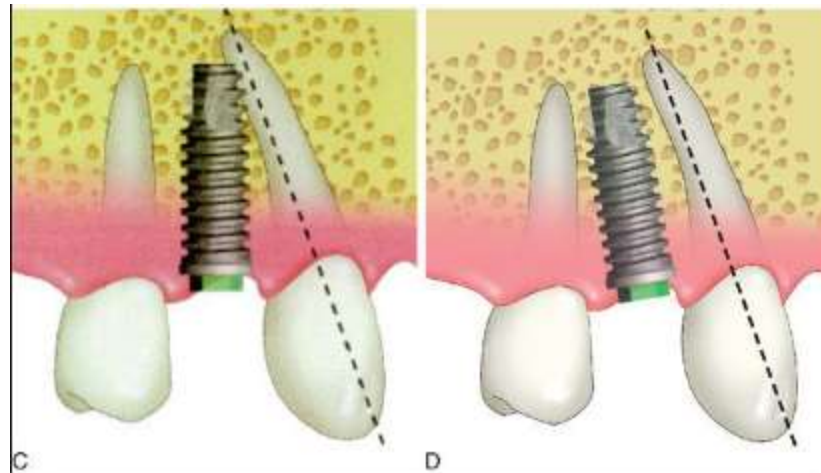


Shoulder of implant should be placed within the limited comfort zone approx 1mm apical to CEJ of contralateral incisor.



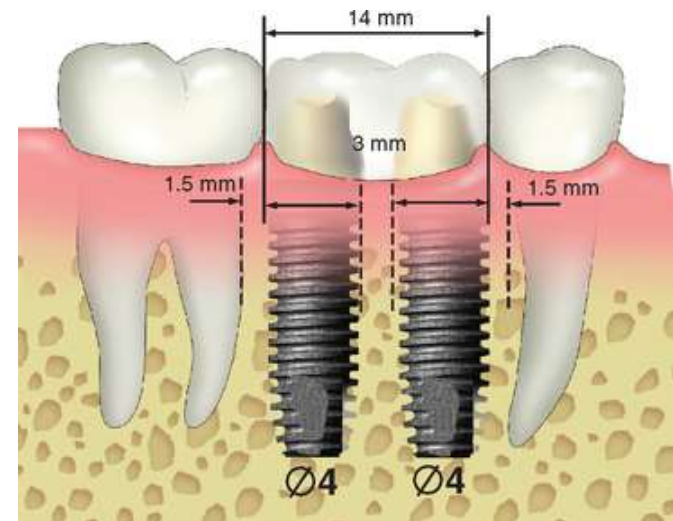
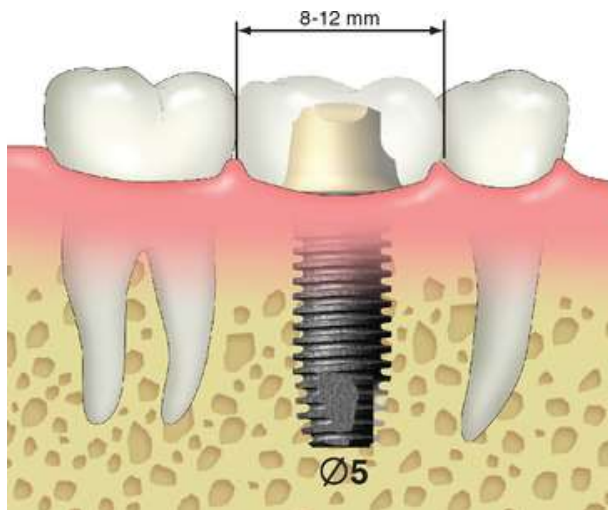
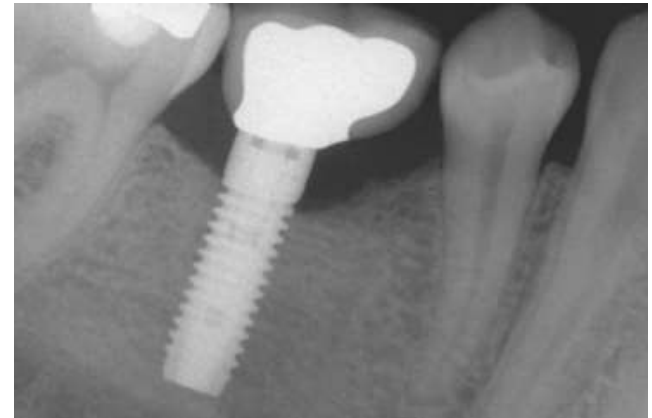The shoulder should be located in comfort zone, approx 1-1.5mm palatal

- **Premolar implant replacement:**
- The maxillary canine root is often angled 11 degree distally and present distal curve 32% of the time.



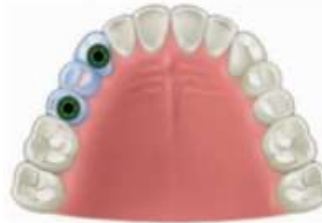- **Molar implant replacement:**

- Molar mesiodistal dimension usually ranges from 8-12mm, when 4mm diameter implant is placed to support a crown of 12mm diameter crown.

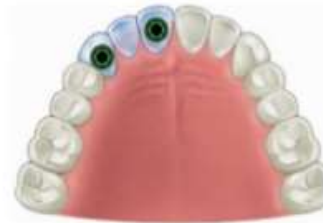

- **Guideline for key implant positions:**

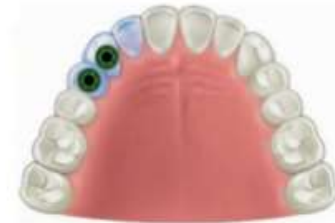- I. No cantilever
- II. No three adjacent pontic
- III. Canine molar rule



When the canine, first premolar, and second premolar teeth are missing, key implant positions are in the canine and second premolar

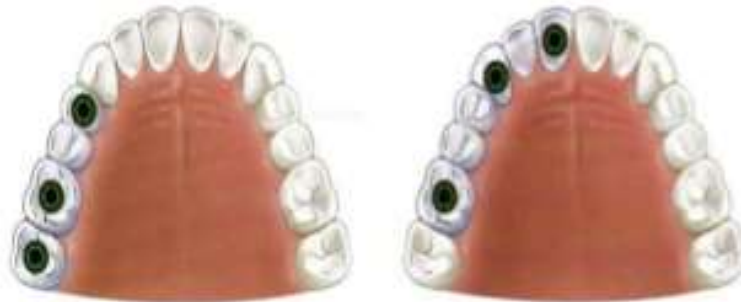

When the canine, lateral, and central incisor teeth are missing, key implant positions are in the central and canine positions



When the first premolar, canine, and lateral incisors are missing, the key implant positions are the first premolar and canine position.

- The 1st molar is also a key implant position when 3 adjacent posterior teeth are missing.
- The **bite force doubles in the molar position** compared with the premolar position in both the maxilla and mandible
- When 3 or more adjacent teeth are missing, including a 1st molar the key implant positions include the terminal abutments and the 1st molar position.

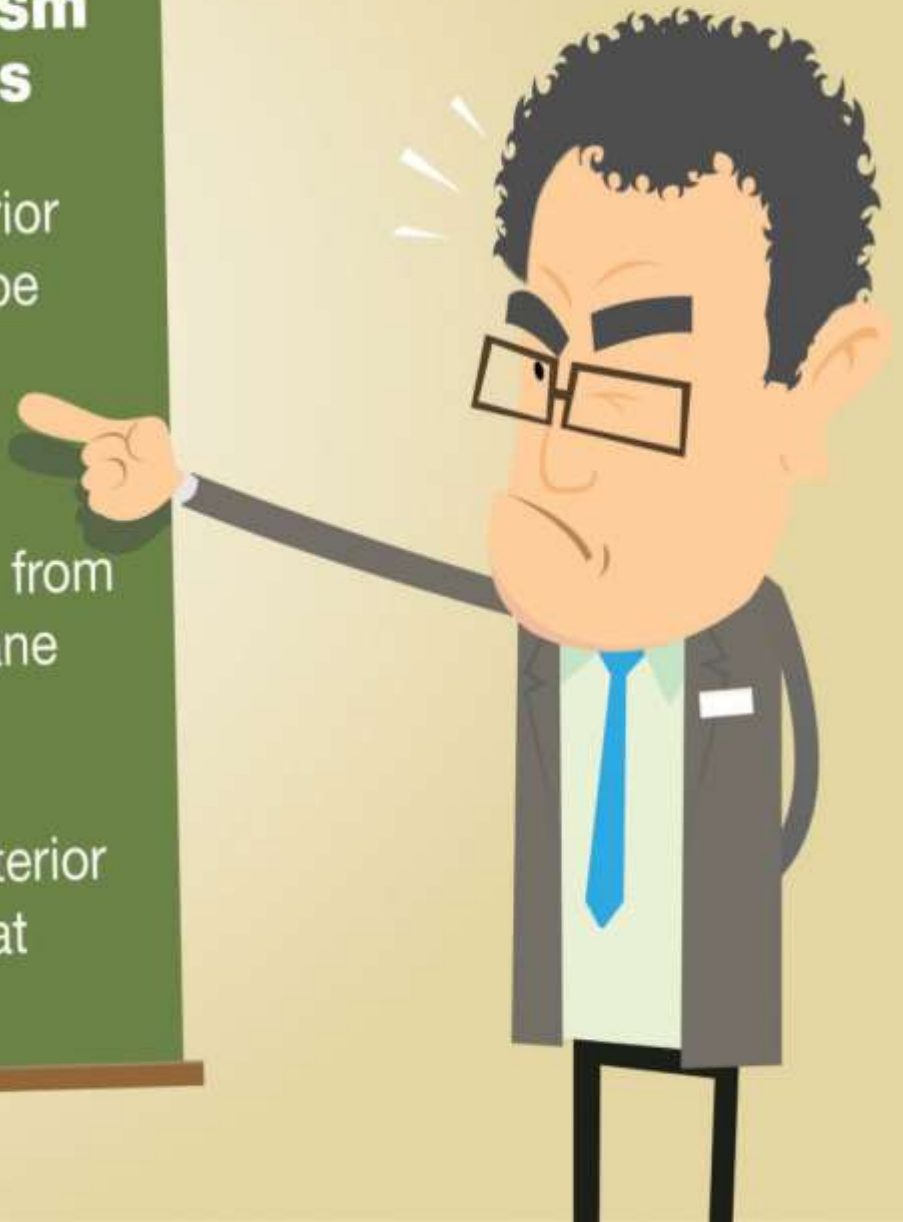

“Rules of 10” for Treatment of Mandibular Edentulism Using Dental Implants

RULE NO. 1 — The inferior/superior dimension of the mandible must be 10 mm or greater.

RULE NO. 2 — The interocclusal (restorative) dimension measured from the ridge crest to the occlusal plane must be 10 mm or greater.

RULE NO. 3 — The anterior/posterior distribution of implants must be at least 10 mm.



- Surgical approaches:
 - I. Two stage surgery
 - II. One stage surgery
 - III. Direct, one stage surgery

- Two stage surgery:

Advantages:

- I. Direct observation of crestal bone volume before osteotomy
- II. Direct observation during osteotomy preparation.
- III. Ability to bone graft the site at the time of implant placement.
- IV. Reduce risk of early loading during initial healing.
- V. Local oral hygiene and anaerobic bacterial infiltration are not critical factors

- **One stage surgery:**

- Advantages:

- I. Second surgical procedure is not necessary
- II. One stage surgical approach may have less early crestal bone loss.

- **Direct (flapless) one stage surgery:**
- **Disadvantages:**
 - I. Inability to access the bone volume before or during implant osteotomy(use when >8mm bone width present)
 - II. Bone grafting needs and procedures cannot be precisely evaluated.
 - III. Keratinized tissue is reduced



THANK YOU

FUTURE IN IMPLANTOLOGY

The nano era in dentistry

[Sneha S. Mantri](#) and [Shivkumar P. Mantri](#)¹

J Nat Sci Biol Med. 2013 Jan-Jun; 4(1): 39–44.

doi: [10.4103/0976-9668.107258](https://doi.org/10.4103/0976-9668.107258)

PMCID: PMC3633301

Nanotechnology in biomedical applications: a review

Journal	International Journal of Nano and Biomaterials
Publisher	Inderscience Publishers
ISSN	1752-8933 (Print) 1752-8941 (Online)
Subject	Biosciences and Bioinformatics , Healthcare and Medical Engineering , Materials and Manufacturing and Nanoscience and Nanotechnology
Issue	Volume 3, Number 2/2010
Pages	119-139
DOI	10.1504/IJNBM.2010.037801
Subject Group	Healthcare and Biosciences
Online Date	Monday, January 03, 2011

The effects of implant surface nanoscale features on osteoblast-specific gene expression

Biomaterials

Volume 30, Issue 25, September 2009, Pages 4053–4062

Gustavo Mendonça^{a, b}, Daniela B.S. Mendonça^{a, b}, Luis G.P. Simões^c, André L. Araújo^c, Edson R. Leite^c, Wagner R. Duarte^d, Francisco J.L. Aragão^{a, e}, Lyndon F. Cooper^{b, ,}

- ^a Universidade Católica de Brasília, Pós-Graduação em Ciências Genômicas e Biotecnologia, SGAN Quadra 916, Módulo B, Av. W5 Norte 70.790-160-Asa Norte Brasília/DF, Brazil
- ^b Bone Biology and Implant Therapy Laboratory, Department of Prosthodontics, University of North Carolina at Chapel Hill, 404 Brauer Hall, CB #7450, Chapel Hill, NC 27511, USA
- ^c Departamento de Química, Universidade Federal de São Carlos-UFSCAR, Rod. Washington Luiz, 13565-905 São Carlos, SP, Brazil
- ^d Programa de Pós-graduação em Periodontia, EBO/São Leopoldo Mandic, 70770-900 Brasília, DF, Brazil
- ^e Embrapa Recursos Genéticos e Biotecnologia, Laboratório de Introdução e Expressão de Genes, PqEB W5 Norte, 70770-900 Brasília, DF, Brazil

Nanostructured alumina-coated implant surface: effect on osteoblast-related gene expression and bone-to-implant contact in vivo.

[Int J Oral Maxillofac Implants.](#) 2009 Mar-Apr;24(2):205-15.

[Mendonça G](#), [Mendonça DB](#), [Simões LG](#), [Araújo AL](#), [Leite ER](#), [Duarte WR](#), [Cooper LF](#), [Aragão FJ](#).

Nanomedicine for implants: a review of studies and necessary experimental tools.

Liu H, Webster TJ

Biomaterials. 2007 Jan; 28(2):354-69.

Titania nanotubes: a novel platform for drug-eluting coatings for medical implants?

Popat KC, Eltgroth M, LaTempa TJ, Grimes CA, Desai TA

Small. 2007 Nov; 3(11):1878-81.

Nanostructured ceramics for biomedical implants.

Catledge SA, Fries MD, Vohra YK, Lacefield WR, Lemons JE, Woodard S, Venugopalan R

Review

J Nanosci Nanotechnol. 2002 Jun-Aug; 2(3-4):293-312.

The role of nanometer and sub-micron surface features on vascular and bone cell adhesion on titanium.

Khang D, Lu J, Yao C, Haberstroh KM, Webster TJ

Biomaterials. 2008 Mar; 29(8):970-83.

Early bone growth on the surface of titanium implants in rat femur is enhanced by an amorphous diamond coating

Acta Orthopaedica

August 2011, Vol. 82, No. 4 , Pages 499-503

(doi:10.3109/17453674.2011.579522)

Jarkko JP Jaatinen¹, Rami K Korhonen², Alpo Peltari³, Heikki J Helminen⁴, Hannu Korhonen², Reijo Lappalainen^{2,3}, and Heikki Kröger¹ Department of Orthopedics, Bone and Cartilage Research Center, Kuopio University Hospital

²Department of Applied Physics

³BioMater Center, University of Eastern Finland

⁴Department of Anatomy, Institute of Biomedicine, University of Eastern Finland, Kuopio, Finland

Correspondence: rami.korhonen@uef.fi

The role of oxygen termination of nanocrystalline diamond on immobilisation of BMP-2 and subsequent bone formation.

Kloss FR, Gassner R, Preiner J, Ebner A, Larsson K, Hächl O, Tuli T, Rasse M, Moser D, Laimer K, Nickel EA, Laschober G, Brunauer R, Klima G, Hinterdorfer P, Steinmüller-Nethl D, Lepperdinger G

Biomaterials. 2008 Jun; 29(16):2433-42

Ordered growth of neurons on diamond.

Specht CG, Williams OA, Jackman RB, Schoepfer R

Biomaterials. 2004 Aug; 25(18):4073-8.

SUMMARIZE

- CONCEPTS ORRIENTD
- PHYSIOCHEMICAL AND BIOMECHANICAL
- SURGICAL SKILLS
- FORTUNE FAVOURS THE BRAVE

ACKNOWLEDGEMENTS

DR R. SURESH CHAIR PERIODONTICS, SRDC,SRU

DR D.J VICTOR PROF & HEAD, SRMDC

MY STAFFS AND MY STUDENTS

MY FAMILY MEMBERS

BIBLIOGRAPHY & REFERENCES

- Principles and practice of implant dentistry – CHARLES N.W. WEISS
- Contemporary implant dentistry – CARL . E. MISCH
- Dental implants - MICHEAL NORTON
- Implants and restorative dentistry – GERAD M SCORTECCI, CARL E MISCH, BENNER
- CLINICAL PERIODONTOLOGY AND IMPLANT DENTISTRY – JAN LINDHE 5 TH EDITION

- CLINICAL PERIODONTOLOGY – CARRANZA 10TH EDITION.
- OSSEOINTEGRATED DENTAL TECHNOLOGY – GRAHAN WHITE
- CURRENT ISSUE IN IMPLANT DENTISTRY - PERIO 2000 VOL 47 2008
- EFFECT OF THREAD IMPLANT PATTERN ON IMPLANT OSSEINTEGRATION – CLINICAL IMPLANT ORAL RESEARCH 2009
- INTERNATIONAL JOURNAL OF DENTAL RESEARCH 2005

- INTERNATIONAL JOURNAL OF ORAL IMPLANTS
- BRAZILIAN JOURNAL OF DENTAL RESEARCH
- JOURNAL OF CLINICAL PERIODONTOLOGY
- JOURNAL OF PERIODONTOLOGY
- INDIAN SOCIETY OF JOURNAL OF PERIODONTOLOGY
- INDIAN JOURNAL OF DENTAL RESEARH
- BIOMATERIALS
- TRENDS IN BIOMATERIALS

HAPPY REPUBLIC DAY



PROUD TO BE AN INDIAN