

ANATOMICAL LANDMARKS



INTRODUCTION

IMPORTANCE OF ORAL ANATOMY

- Need for a functional prosthesis
- Different areas having different roles
- Helps in various steps of denture construction

GROSS ANATOMY


➤ FACE

➤ VESTIBULE

➤ ORAL CAVITY PROPER

A stylized silhouette of a mountain range in shades of teal, located in the bottom right corner of the slide.

FACE

- NASOLABIAL GROOVE
 - PHILTRUM
 - LABIOMENTAL GROOVE
 - LABIAL COMMISSURE
 - LABIOMARGINAL SULCUS
- 
- A decorative silhouette of a mountain range in shades of teal, located in the bottom right corner of the slide.

FACE

➤ NASOLABIAL GROOVE

- OBLIQUE LINE FROM THE ALA OF THE NOSE

- PRESENT IN ALL PATIENTS

- ACCENTUATED IN AGING & EDENTULOUS PATIENTS

- CAN BE REDUCED BY NEW DENTURE

FACE

➤ PHILTRUM

-VERTICAL FURROW IN THE
MIDLINE OF THE UPPER LIP

-PROPER SUPPORT IN DENTURE TO
MAINTAIN ITS APPEARANCE

FACE

➤ LABIOMENTAL GROOVE

-PRESENT BETWEEN LOWER LIP &
CHIN

FACE

➤ LABIAL COMMISSURE

-FOUND AT THE CORNER OF THE MOUTH

-EFFECT OF CLOSED VERTICAL DIMENSION

FACE

➤ LABIOMARGINAL SULCUS

- A FURROW THAT EXTENDS FROM THE CORNER OF THE MOUTH DOWNWARD TO THE INFERIOR BORDER OF THE MANDIBLE

-ACCENTUATED WITH AGING

-CAN BE REDUCED BY PROPER SUPPORT BY DENTURE

GROSS ANATOMY

VESTIBULE



GROSS ANATOMY

ORAL CAVITY PROPER



MICROSCOPIC ANATOMY



HISTOLOGY

ORAL MUCOUS MEMBRANE

BONE

A stylized silhouette of a mountain range in a darker shade of teal, located in the bottom right corner of the slide.

HISTOLOGY

ORAL MUCOUS MEMBRANE

➤ LINING MUCOSA

➤ MASTICATORY MUCOSA

➤ SPECIALISED MUCOSA

HISTOLOGY

ORAL MUCOUS MEMBRANE

LINING MUCOSA

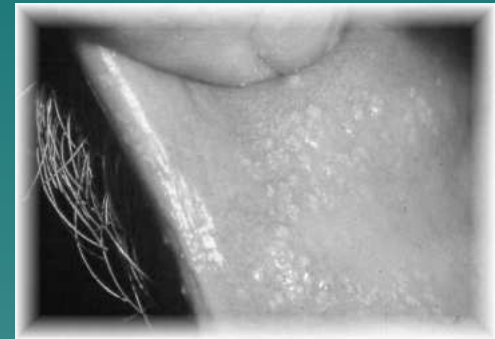Cheeks

Lips

Floor of the mouth

Ventral surface of the tongue

- Fixed to epimysium or fascia
- Highly elastic



HISTOLOGY

ORAL MUCOUS MEMBRANE

MASTICATORY MUCOSA

Palate

Gingiva

- ❖ Basement membrane contains more reticular fibres
- ❖ CT papillae high & more closely spaced.

HISTOLOGY

ORAL MUCOUS MEMBRANE

MASTICATORY MUCOSA

- Granular cells larger.
- Epithelium thinner.
- Increased tonofibrils.
- Basement membrane contains more reticular fibres .
- Wider inter-cellular spaces.

HISTOLOGY

ORAL MUCOUS MEMBRANE

SPECIALISED MUCOSA

Tongue

Taste buds

A stylized silhouette of a mountain range in shades of teal, located in the bottom right corner of the slide.

FACTORS TO BE SEEN IN STUDYING OMM

1. Type of covering epithelium
2. Structure of lamina propria
3. Junction between epithelium & lamina propria.
4. Membrane's fixation to sub mucous layer

EPITHELIUM

- Keratinised
 - Masticatory mucosa
- Non- keratinised
 - Lining mucosa
 - Specialised mucosa

EPITHELIUM

4 layers:-

- Stratum Basale
- Stratum spinosum
- Stratum granulosum
- Stratum corneum

STRATUM BASALE

- ◆ Cuboidal shape of cells
- ◆ DNA synthesizing
- ◆ Undergo mitosis
- ◆ Two types:- serrated
non-serrated
- ◆ Stratum Germinativum

STRATUM SPINOSUM

- ◆ Polyhedral shaped cells
- ◆ Join by inter-cellular bridges & by tonofibrils
- ◆ Inter-cellular spaces are large.
- ◆ Most active in protein synthesis.
- ◆ Increased number & length of desmosomes in tongue, gingiva, palate than alveolar & buccal mucosa

STRATUM GRANULOSUM

- ◆ Flatter & wider cells
- ◆ Basophilic keratohyaline granules
- ◆ Tonofilaments more dense
- ◆ Nuclei :- Degeneration & pyknosis
- ◆ Keratinosome/ Odland body/
Membrane coating granule

STRATUM CORNEUM

- ◆ Made of keratinised squame
- ◆ Larger & flatter than granular cells.
- ◆ Ribosomes, mitochondria disappeared.
- ◆ Acidophilic in nature.
- ◆ Densely packed filaments in a matrix protein ' Filaggrin' .
- ◆ Keratocytes

NON-KERATINISED EPITHELIUM

- ◆ Layers
- ◆ Para keratinisation

LAMINA PROPRIA

Two parts :- Papillary
- Reticular

Interlocking arrangement

Attachment to bone

JUNCTION BETWEEN EPITHELIUM & LAMINA PROPRIA

- ◆ Basal Lamina
- ◆ Basement membrane

JUNCTION BETWEEN EPITHELIUM & LAMINA PROPRIA

◆ Basal Lamina

- Epithelial in origin
- Seen at EM level
- Hemidesmosomes
- 2 PARTS: Lamina lucida
lamina densa

JUNCTION BETWEEN EPITHELIUM & LAMINA PROPRIA

◆ Basement membrane

- Connective tissue in origin
- Seen at light microscopic level
- 1-4 micrometer wide
- Contain GAG, argyrophilic reticulin fibers & special anchoring fibrils

SUBMUCOSA

- Contents
 - Arteries
 - Sensory Nerves
 - Adipose Tissue
 - Glandular Tissue
- Function

HISTOLOGY

BONE

MAXILLA

MANDIBLE

A stylized silhouette of a mountain range in a darker teal color, located in the bottom right corner of the slide.

ANATOMICAL LANDMARKS IN THE MAXILLA



ANATOMICAL LANDMARKS IN THE MAXILLA

LIMITING STRUCTURES

SUPPORTING STRUCTURES

RELIEF AREAS

A stylized, teal-colored silhouette of a mountain range is positioned in the bottom right corner of the slide. The mountains are rendered with vertical ridges and valleys, creating a textured, layered appearance. The color is a consistent teal, matching the background.

LIMITING STRUCTURES



LIMITING STRUCTURES

LABIAL FRENUM

FOVEA PALATINI

LABIAL VESTIBULE

PTERYGOMANDIBULAR
RAPHAE

BUCCAL FRENUM

BUCCAL VESTIBULE

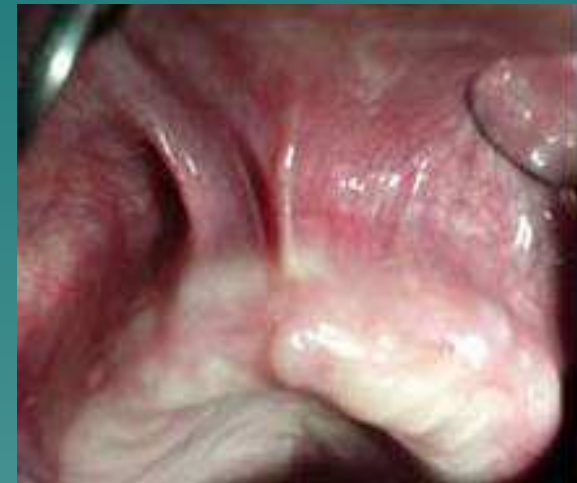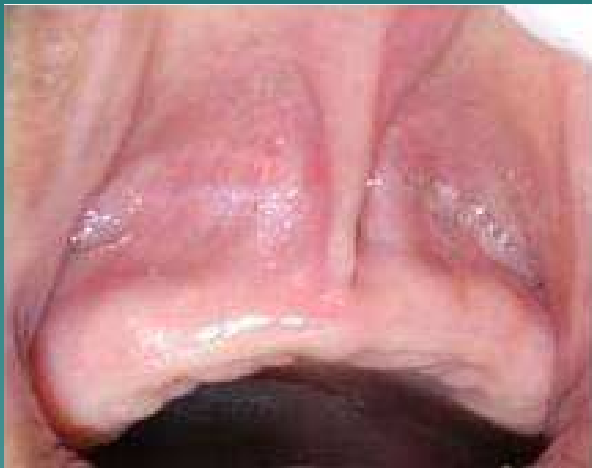CORONOMAXILLARY AREA

HAMULAR NOTCH

POSTERIOR PALATAL SEAL AREA

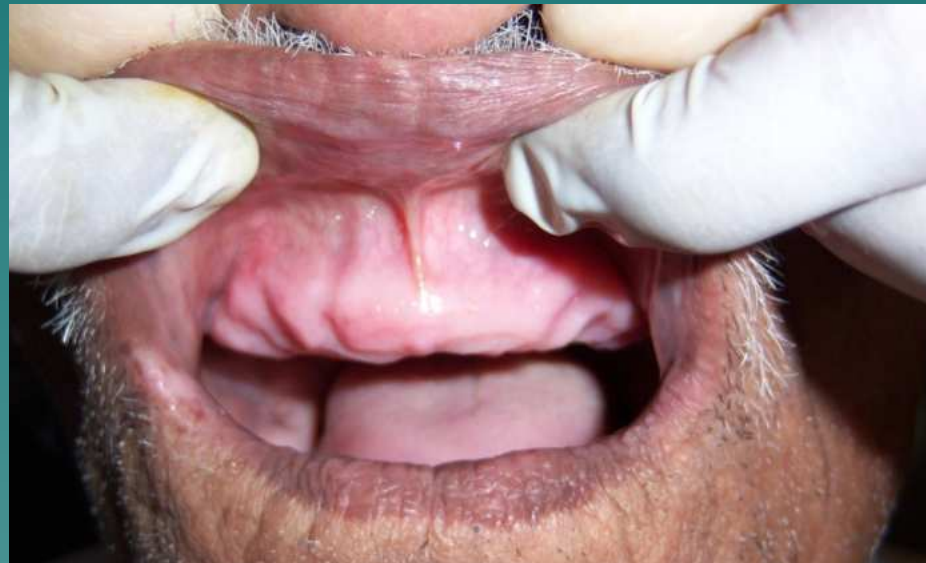LIMITING STRUCTURES

LABIAL FRENUM




LIMITING STRUCTURES

LABIAL FRENUM



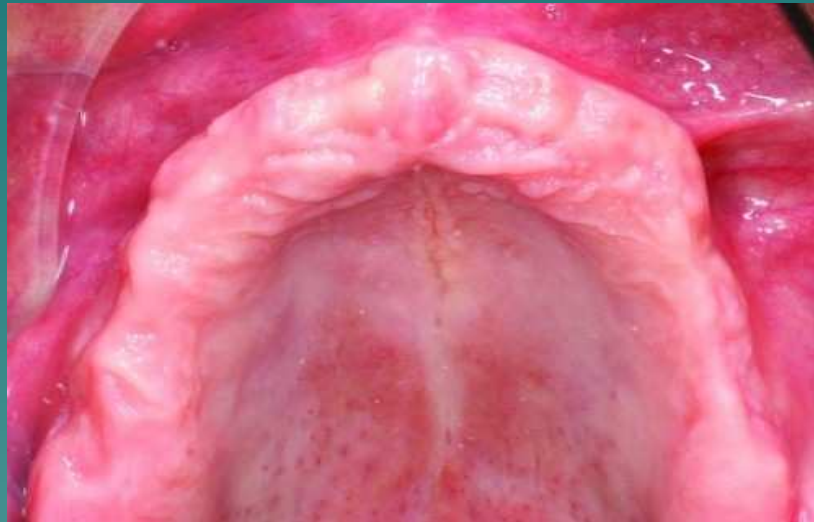
LIMITING STRUCTURES

LABIAL FRENUM

- Fan-Shaped fibrous CT band
 - Has no muscle fibres
 - No action of it's own
 - Extends from labial aspect of ridge to the lip
 - Labial seal
- 

LIMITING STRUCTURES

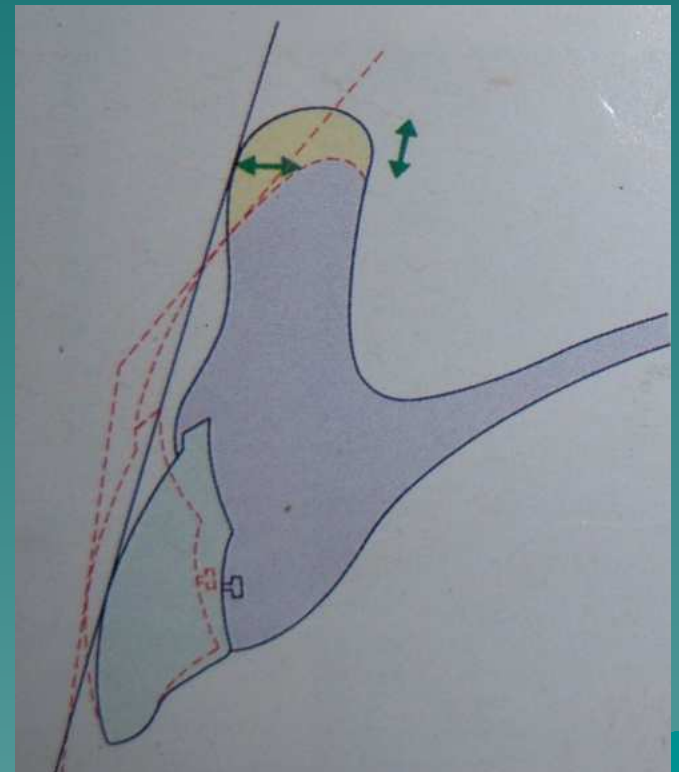LABIAL VESTIBULE



LIMITING STRUCTURES

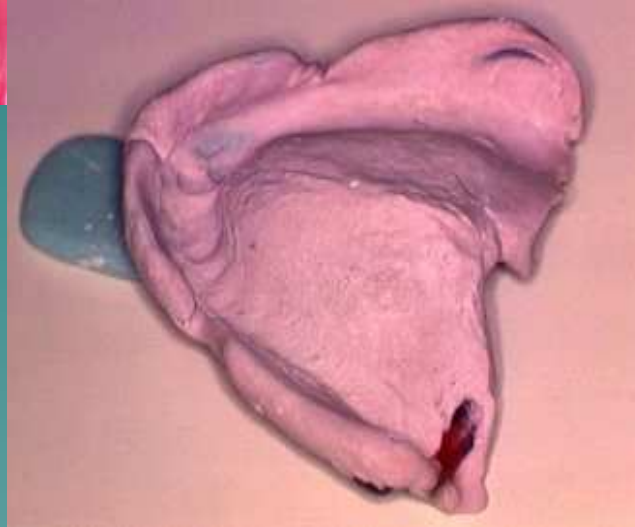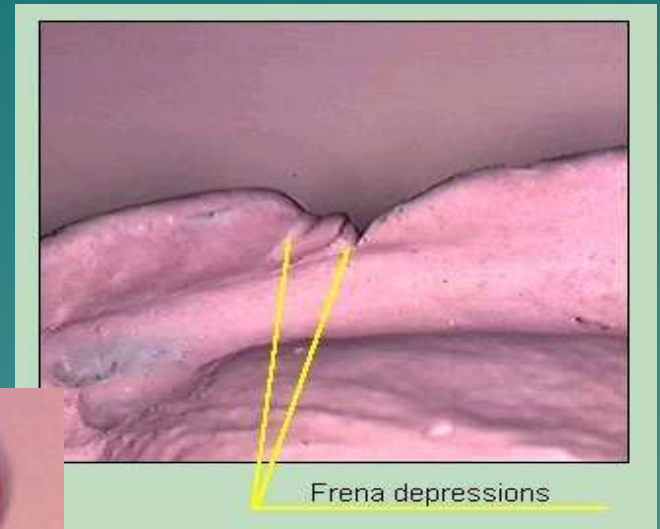
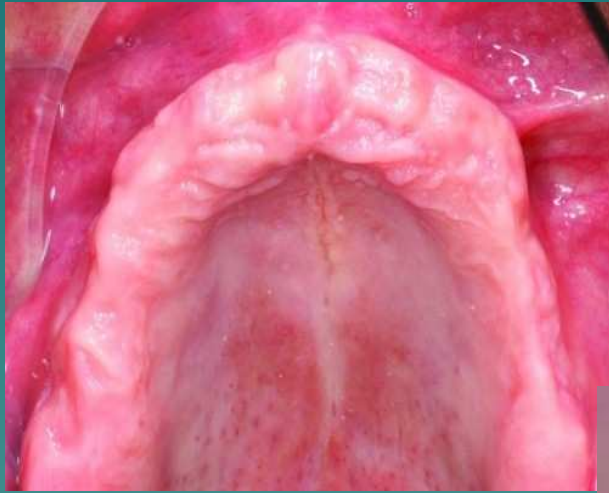
LABIAL VESTIBULE

- Boundaries
- Muscles
- Extensions
- Method to record



LIMITING STRUCTURES

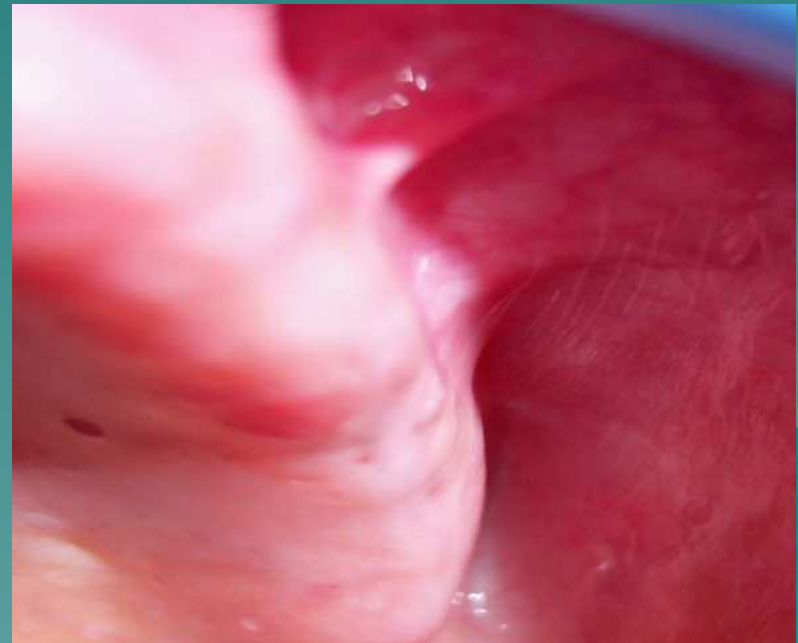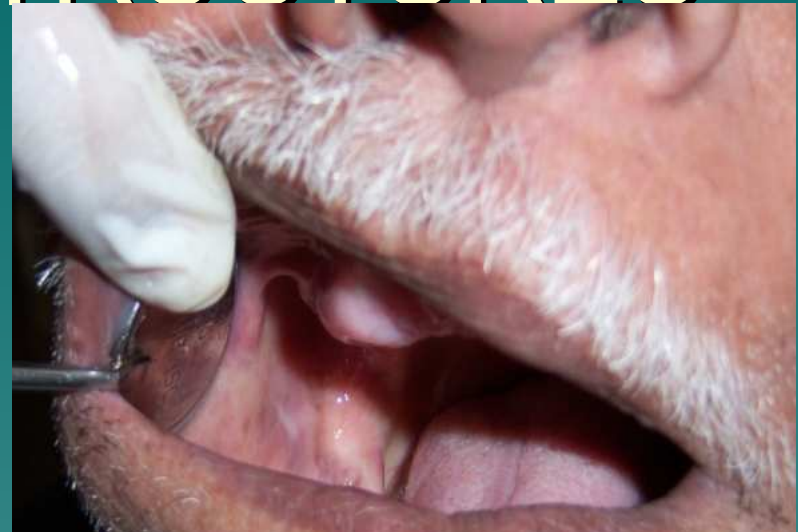BUCCAL FRENUM



LIMITING STRUCTURES

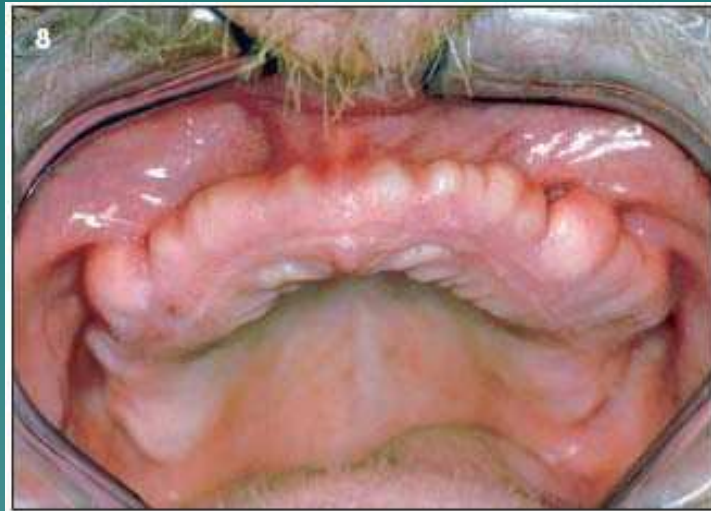BUCCAL FRENUM

- Number
- Location
- Shape
- Muscle
- Method to record




LIMITING STRUCTURES

BUCCAL VESTIBULE



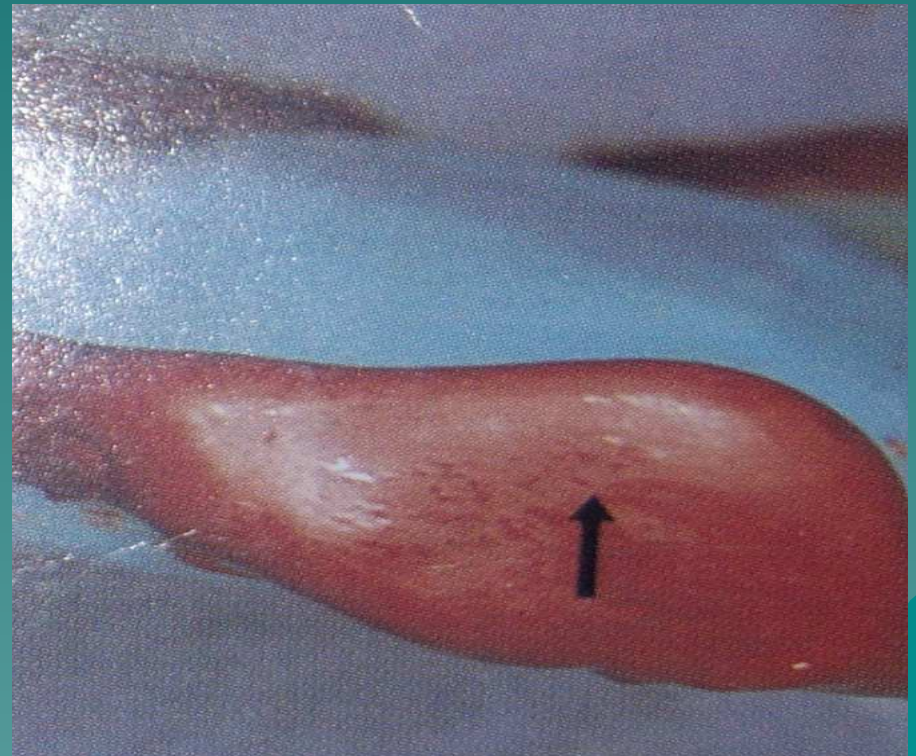
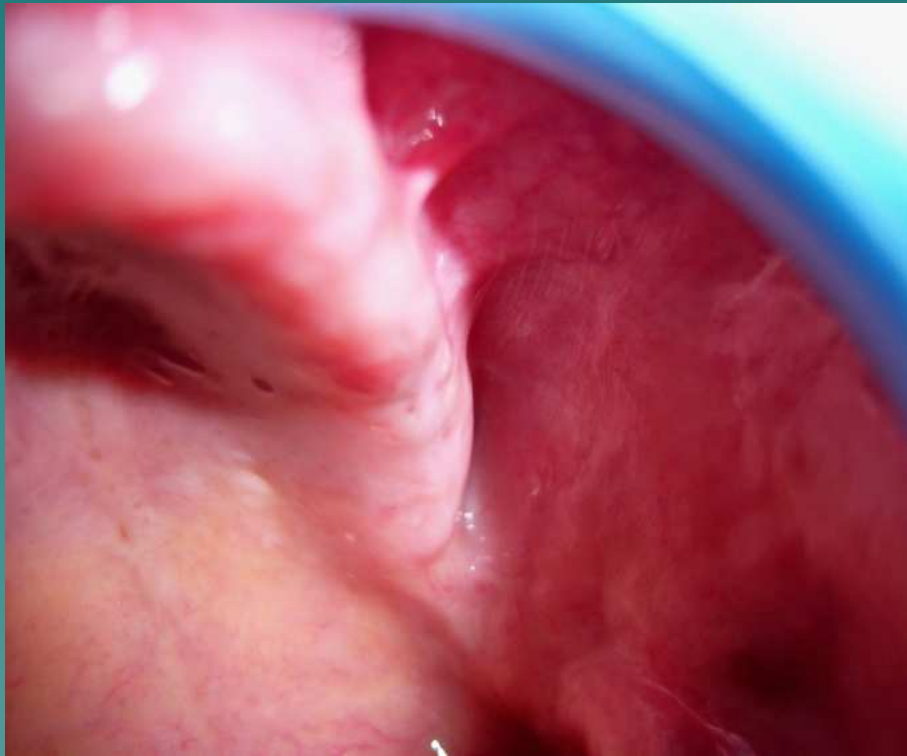
LIMITING STRUCTURES

BUCCAL VESTIBULE

- Extension
 - Factors affecting size
 - Method to record
- 

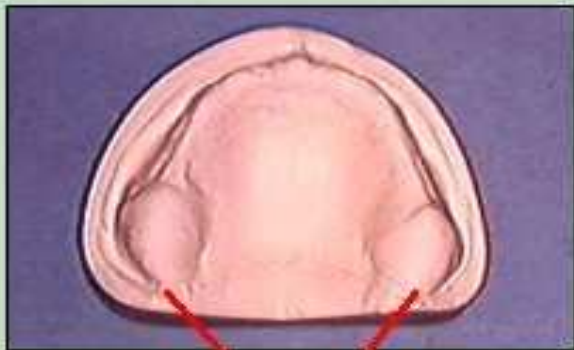
LIMITING STRUCTURES

CORONO-MAXILLARY AREA

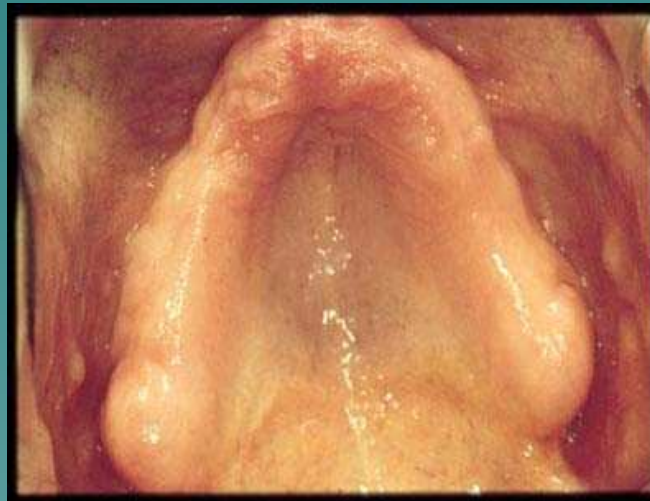

LIMITING STRUCTURES

HAMULAR NOTCH



The hamular notches



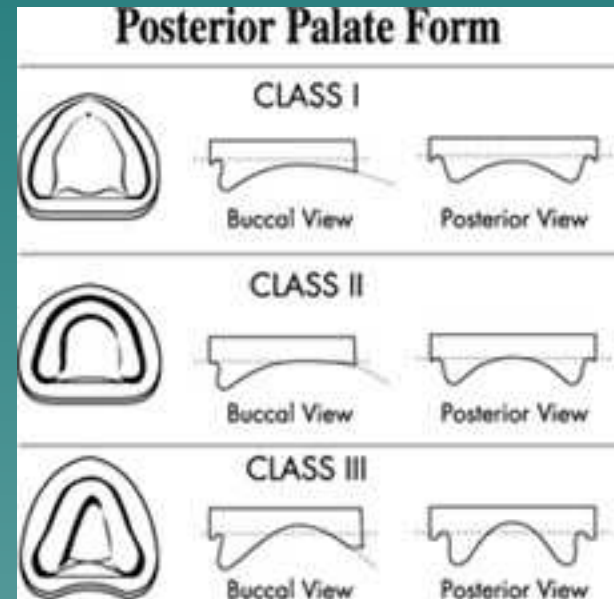
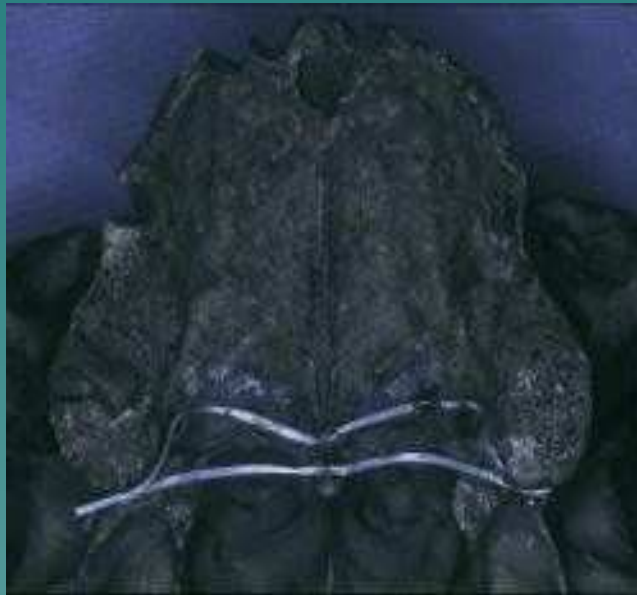LIMITING STRUCTURES

HAMULAR NOTCH

- Location
- Clinical importance

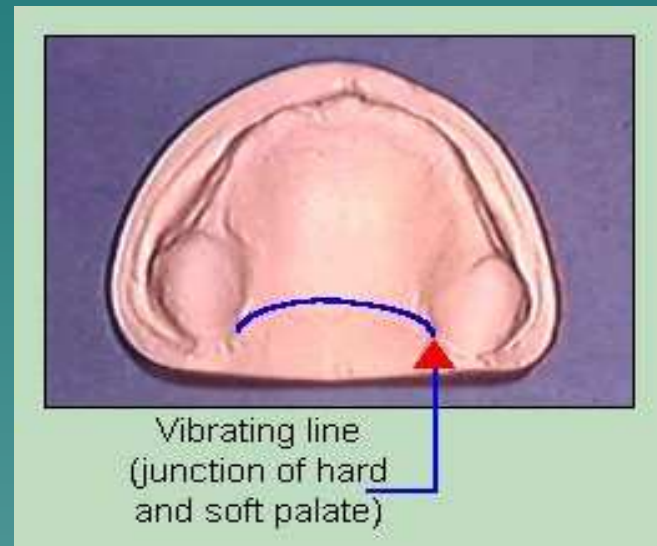

LIMITING STRUCTURES

POSTERIOR PALATAL SEAL AREA



LIMITING STRUCTURES

POSTERIOR PALATAL SEAL AREA



LIMITING STRUCTURES

POSTERIOR PALATAL SEAL AREA

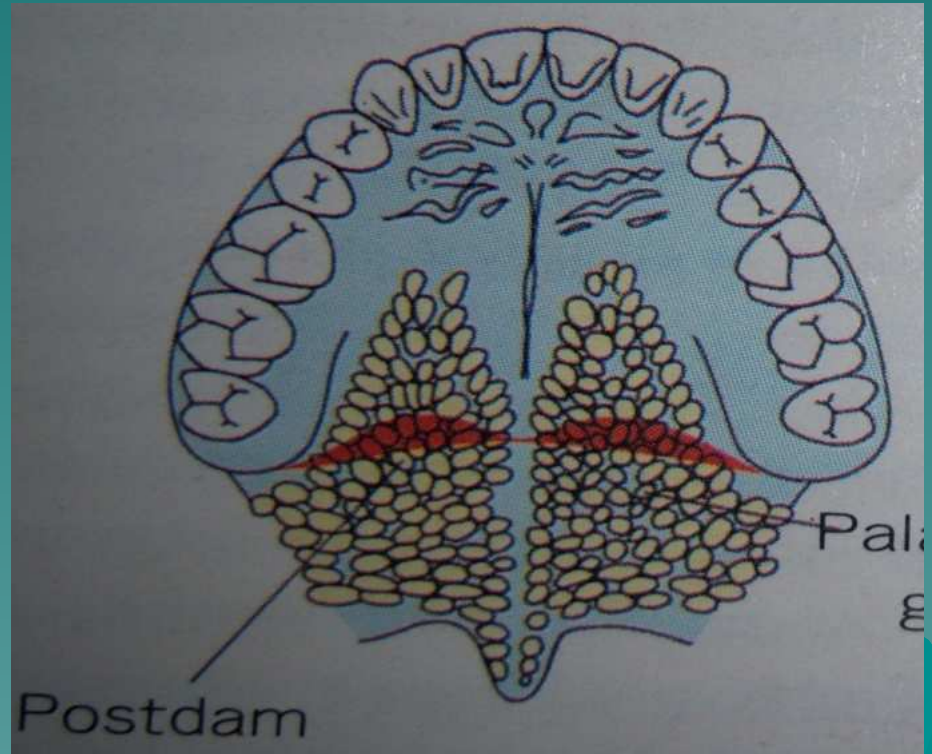
➤ DEFINITION



LIMITING STRUCTURES

POSTERIOR PALATAL SEAL AREA

➤ FUNCTION



LIMITING STRUCTURES

POSTERIOR PALATAL SEAL AREA

- 2 AREAS : POSTPALATAL SEAL
PTERIGOMAXILLARY
SEAL

LIMITING STRUCTURES

POSTERIOR PALATAL SEAL AREA

- ANTERIOR VIBRATING LINE
 - POSTERIOR VIBRATING LINE
- 
- A stylized silhouette of a mountain range in a darker teal color, located in the bottom right corner of the slide.

LIMITING STRUCTURES

POSTERIOR PALATAL SEAL AREA

- TECHNIQUES : CONVENTIONAL
FLUID WAX
ARBITRARY SCRAPING

LIMITING STRUCTURES

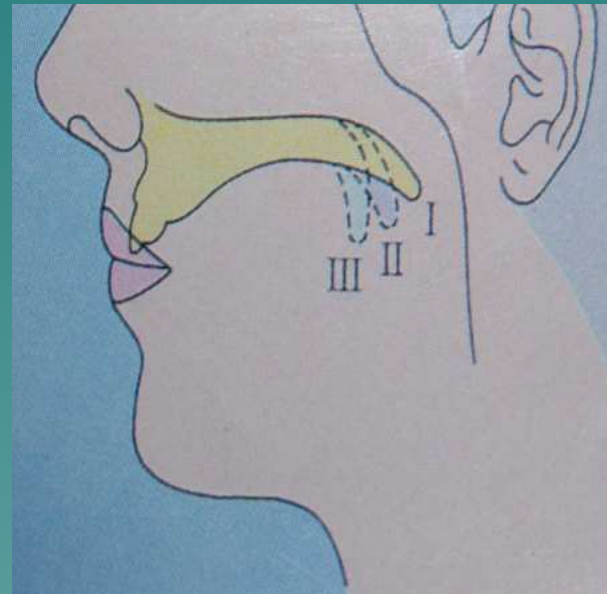
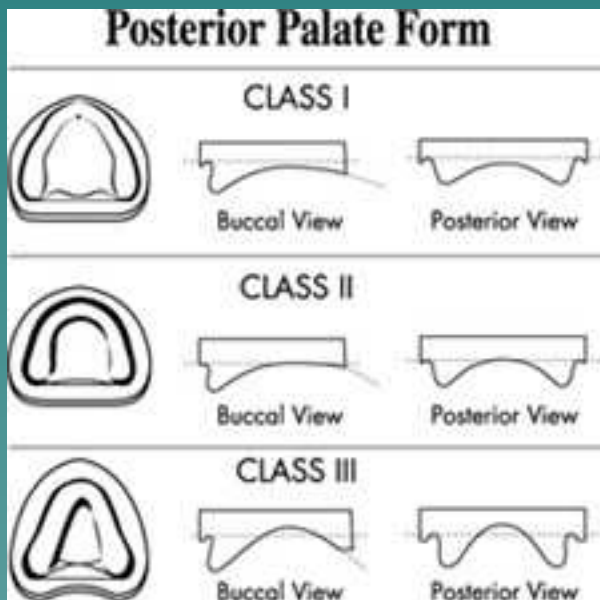
SOFT PALATE

- Fibromuscular curtain
- Muscles of soft palate

LIMITING STRUCTURES

POSTERIOR PALATAL SEAL AREA

➤ CLASSIFICATION OF SOFT PALATE



LIMITING STRUCTURES

SOFT PALATE

- Fibromuscular curtain
- Muscles
- Highly vascular
- Reddish in colour
- CT papillae few & short
- Layer of elastic fibers separate mucosa from submucosa
- Submucosa contains mucous glands, taste buds & loose CT.

LIMITING STRUCTURES

SOFT PALATE : Classification

According to Lye:

Class 1: Horizontal relation with minimum muscle activity > wide & shallow PPS

Class 2: between class 1 & class 3

Class 3: Most acute configuration with marked elevation of musculature to create velopharyngeal closure ,associated with 'V-shaped' palate > smaller & deeper PPS

LIMITING STRUCTURES

SOFT PALATE : Classification

According to House: depending on palatal throat form

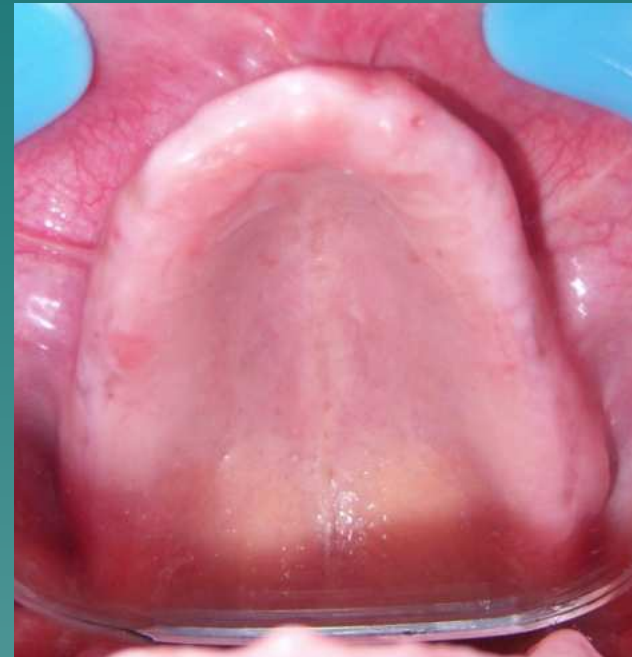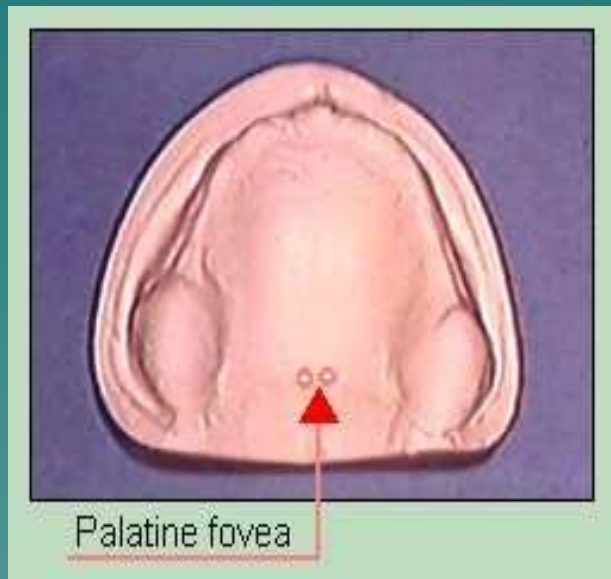Class 1: large & normal in form, immovable band of tissue 5 to 12mm distal to a line joining tuberosities

Class 2: medium size & normal in form, 3 to 5mm band of immovable tissue

Class 3: usually accompanies small maxilla, curtain of soft tissue turns down abruptly 3 to 5mm anterior to a line joining tuberosities

LIMITING STRUCTURES

FOVEA PALATINI



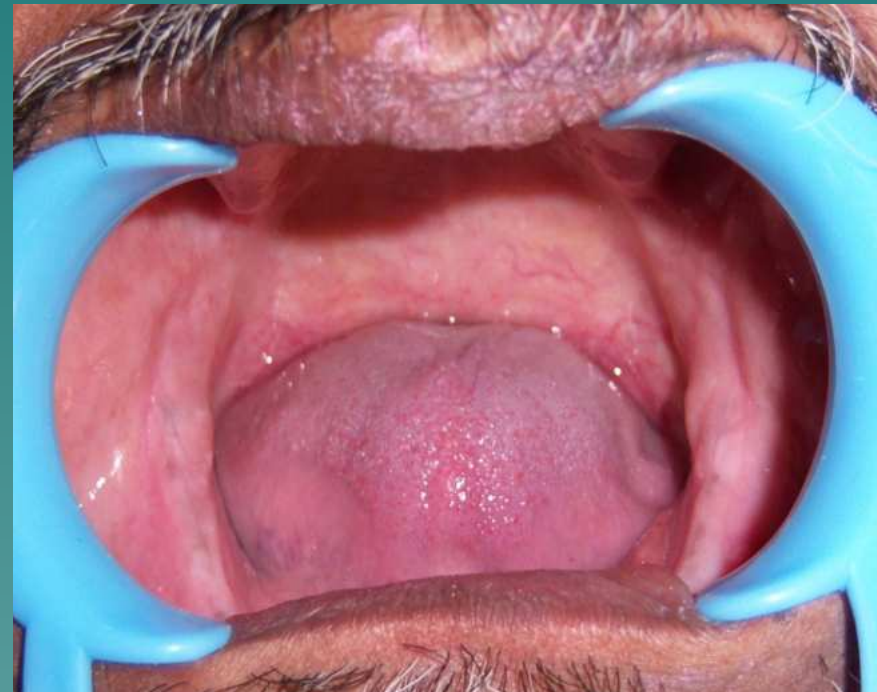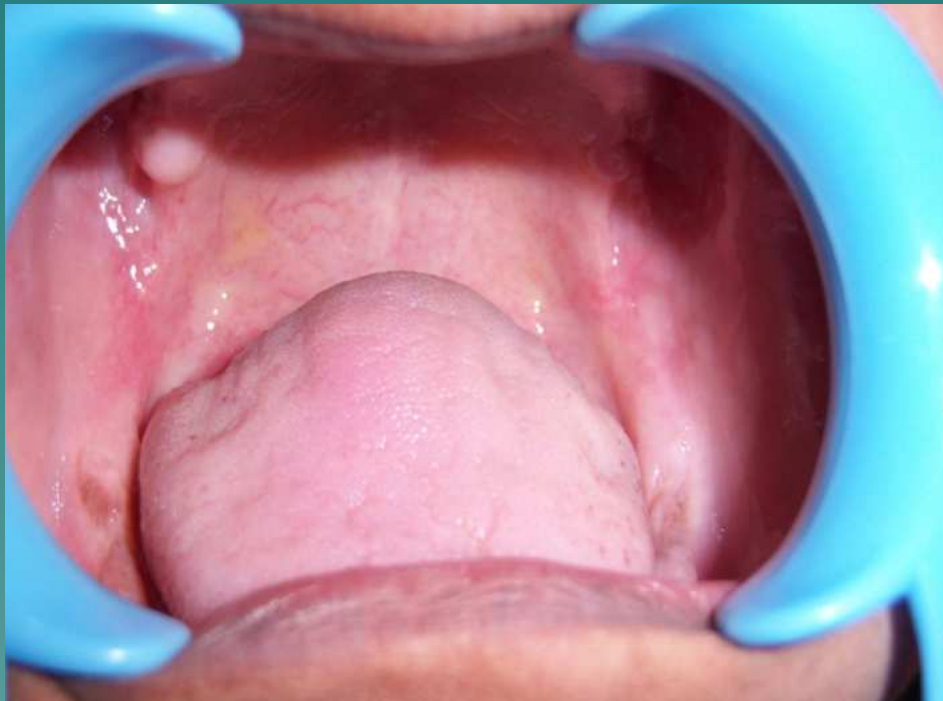
LIMITING STRUCTURES

FOVEA PALATINI

- Location
- Clinical significance

LIMITING STRUCTURES

PTERYGOMANDIBULAR RAPHAE



SUPPORTING STRUCTURES



SUPPORTING STRUCTURES

PRIMARY

FIRM TUBEROSITIES

HARD PALATE LATERAL TO
MIDPALATINE RAPHE

SECONDARY

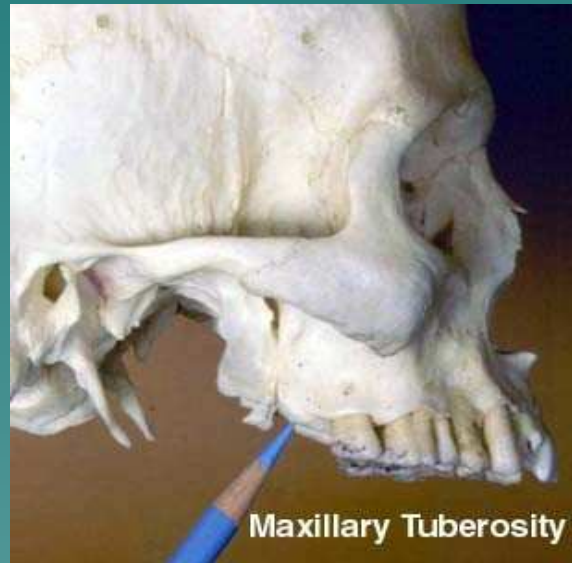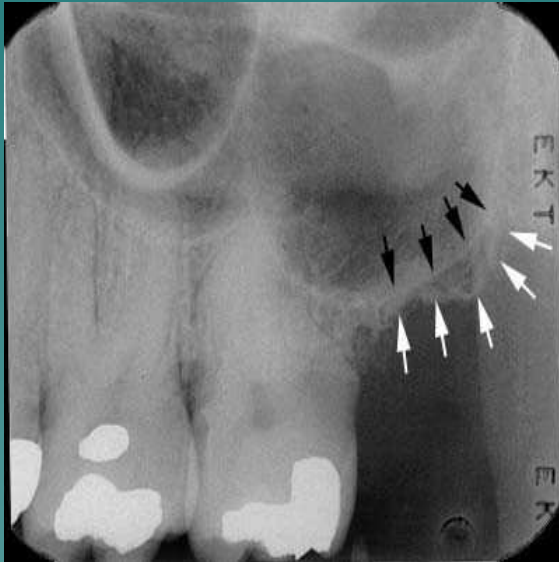
RESIDUAL ALVEOLAR RIDGE

RUGAE

A stylized silhouette of a mountain range in shades of teal, located in the bottom right corner of the slide.

PRIMARY SUPPORTING STRUCTURES

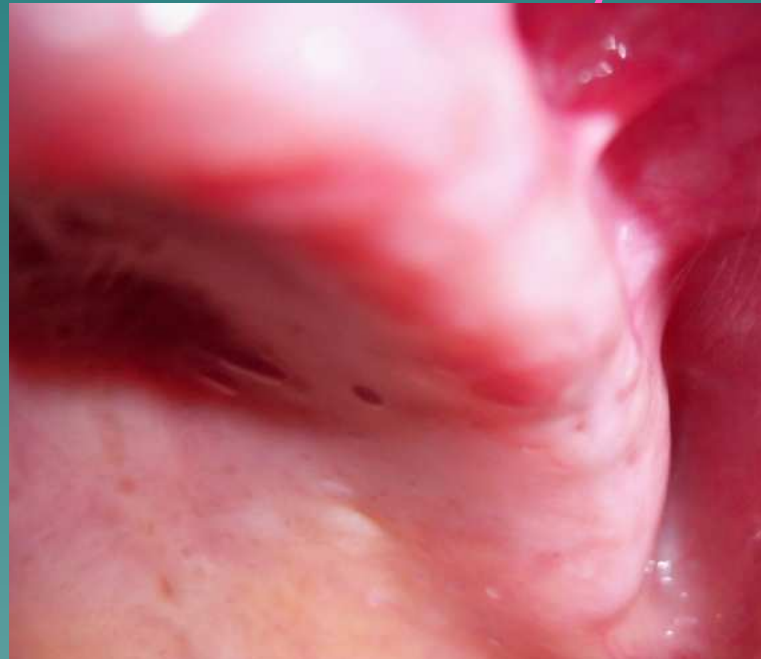MAXILLARY TUBEROSITY



PRIMARY SUPPORTING STRUCTURES

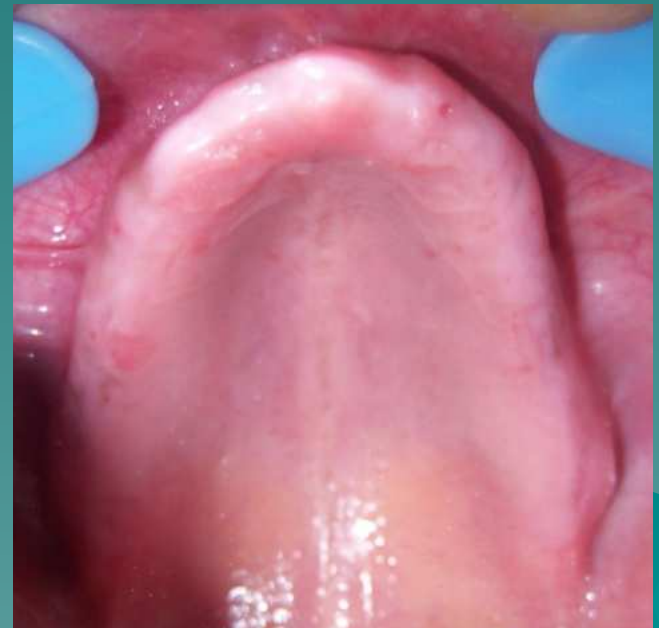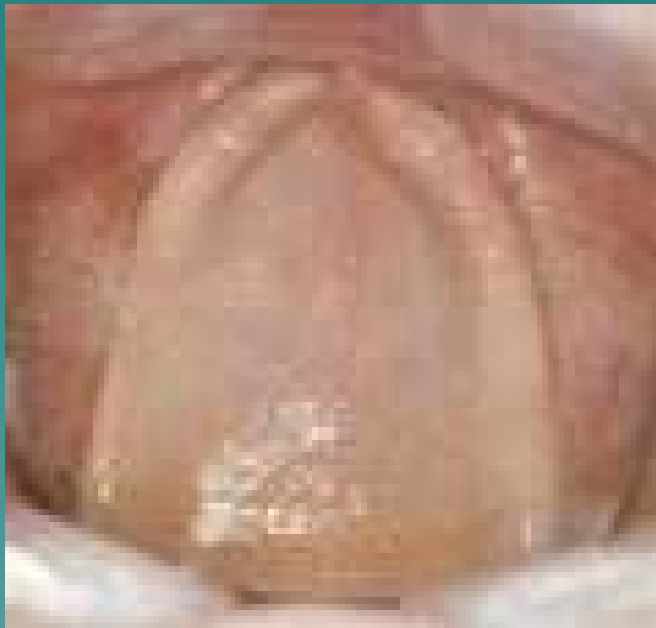MAXILLARY TUBEROSITY

- Bulbous extension of the alveolar ridge
- Location
- Muscle
- Significance



PRIMARY SUPPORTING STRUCTURES

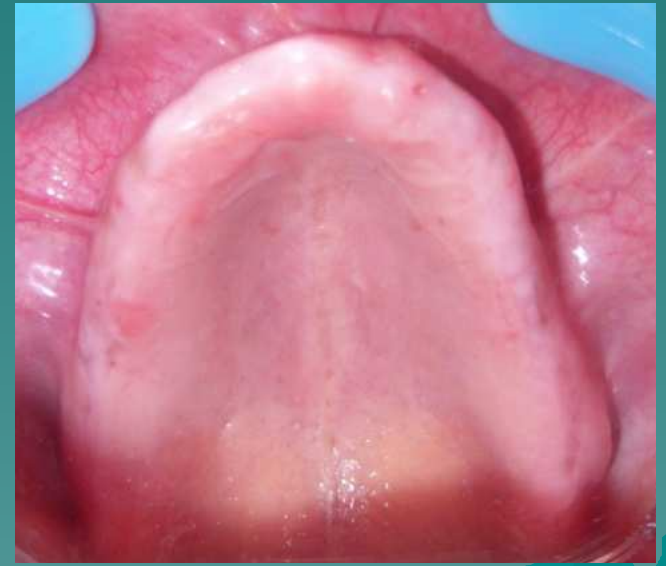HARD PALATE



PRIMARY SUPPORTING STRUCTURES

HARD PALATE

- Bones involved
- Effect of resorption
- function



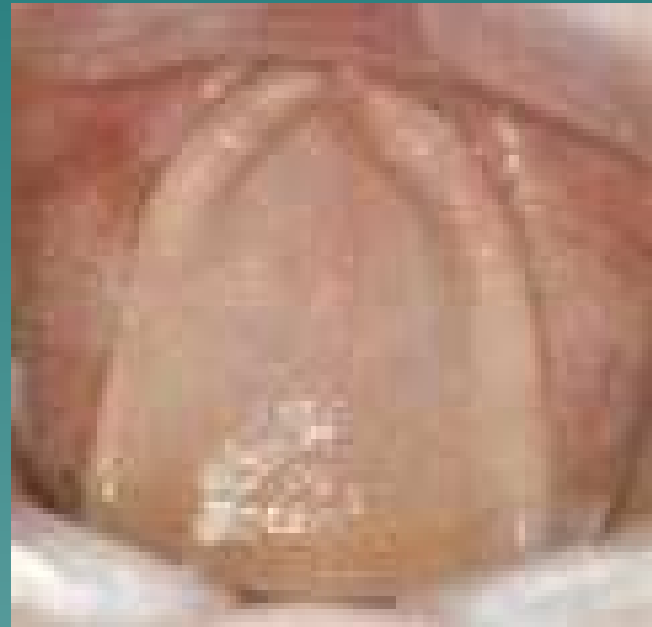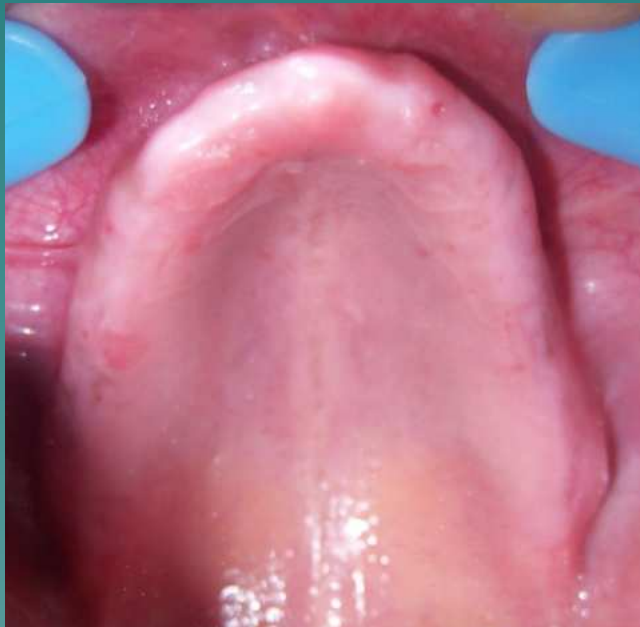PRIMARY SUPPORTING STRUCTURE

HARD PALATE

- 4 zones
- Firm attachment by dense bands & trabeculae of fibrous CT
- filled by adipose & glandular tissue
- Distance between LP & Periosteum is more in posterior region

SECONDARY SUPPORTING STRUCTURES

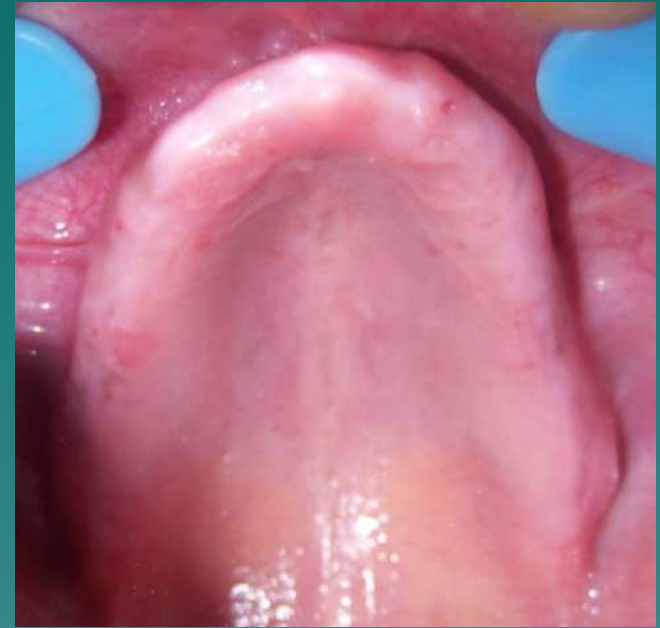
RESIDUAL ALVEOLAR RIDGE



SECONDARY SUPPORTING STRUCTURES

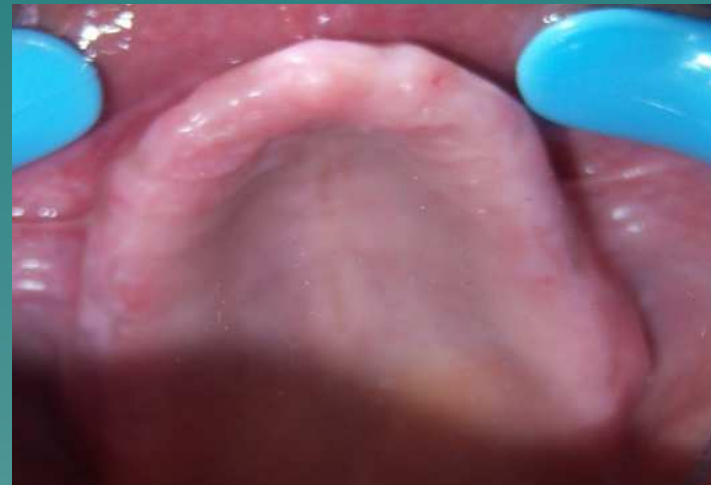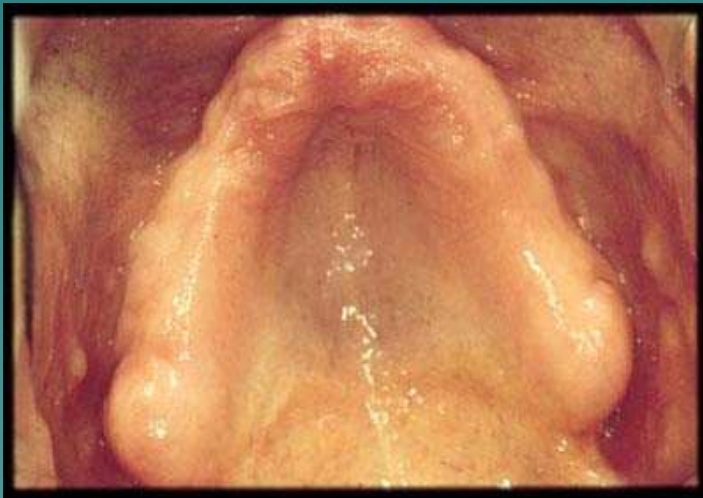RESIDUAL ALVEOLAR RIDGE

- Shape
- Effect of resorption
- Surface area
- Epithelium thin, non-keratinized
- Epithelial ridges low or missing
- Loosely attached to the periosteum by well defined submucous layer of loose CT.




SECONDARY SUPPORTING STRUCTURES

RUGAE



SECONDARY SUPPORTING STRUCTURES

RUGAE

- Transverse fibrous CT ridges
 - Dense CT with fine interwoven fibers seen
 - Clinical importance
- 

RELIEF AREAS



RELIEF AREAS

INCISIVE PAPILLA

CUSPID EMINENCE

MID-PALATINE RAPHAE

MALAR PROCESS

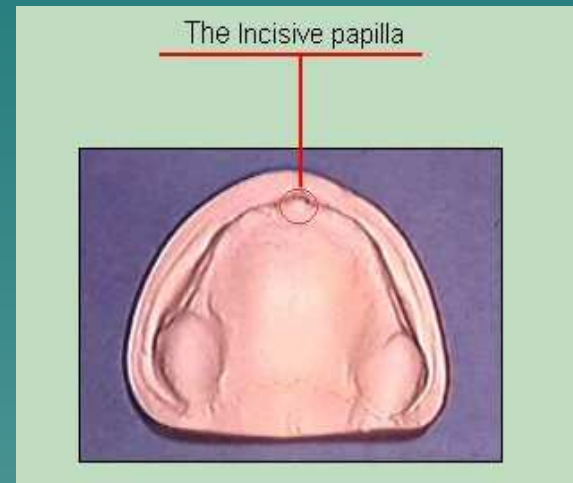
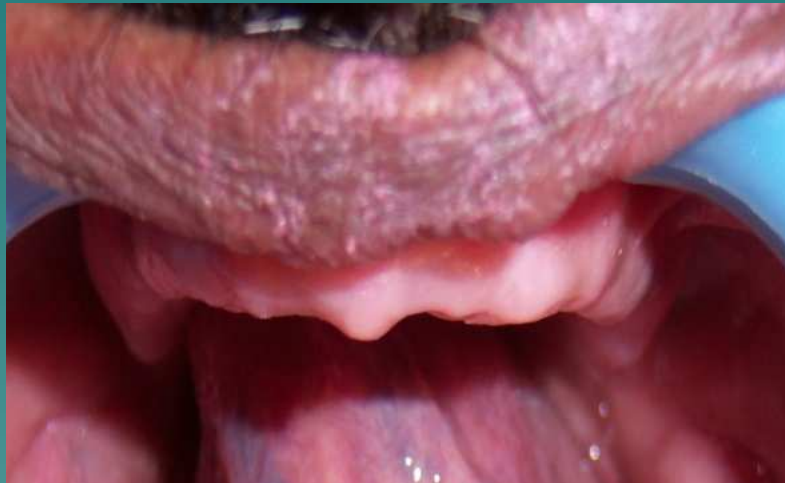SHARP SPINY SPICULES

TORUS PALATINUS



RELIEF AREAS

INCISIVE PAPILLA

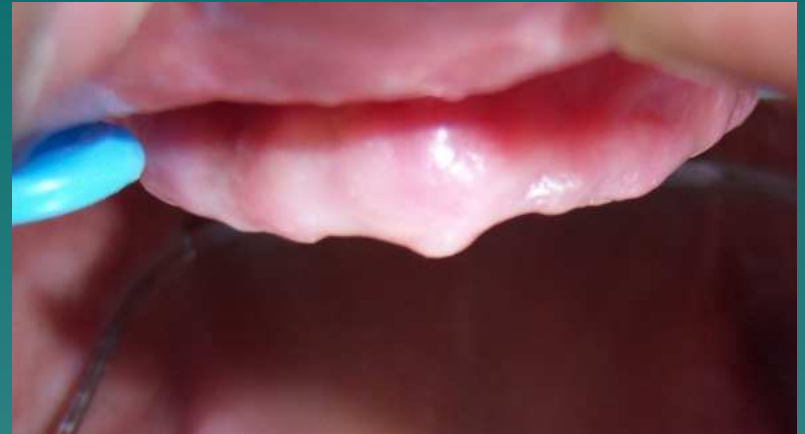

RELIEF AREAS

INCISIVE PAPILLA

➤ LOCATION

➤ CONTENTS



-dense CT & oral part of vestigial nasopalatine nerve & vessels

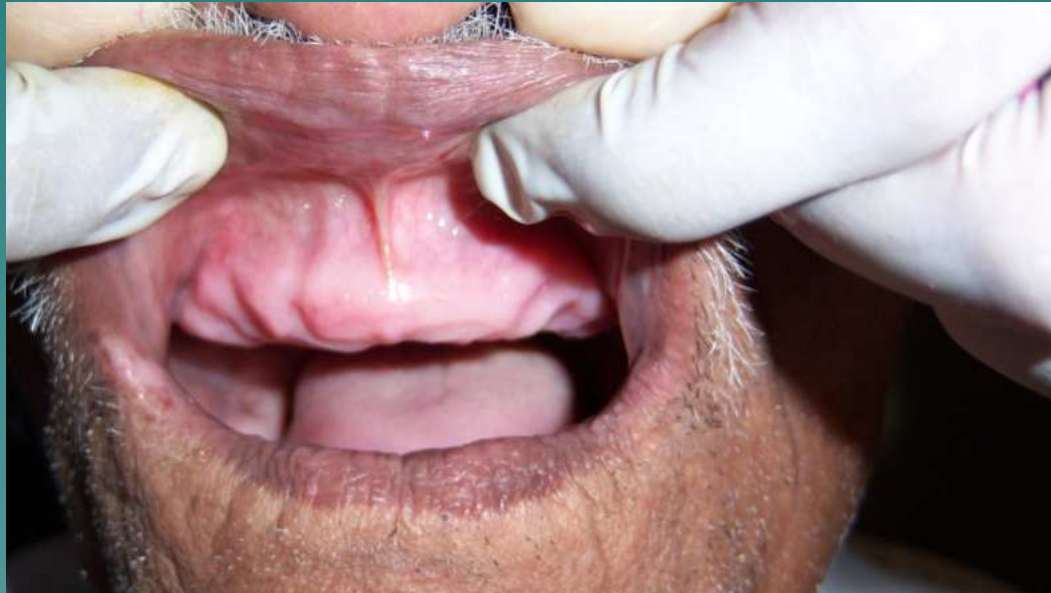-nasopalatine duct is lined by pseudostratified columnar epithelium > rich in Goblet cells

-cartilage sometimes found

➤ CLINICAL SIGNIFICANCE

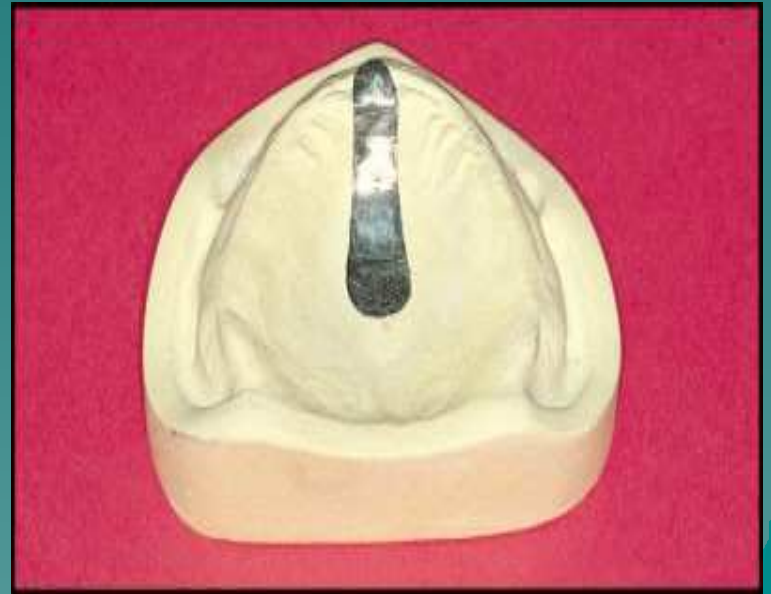
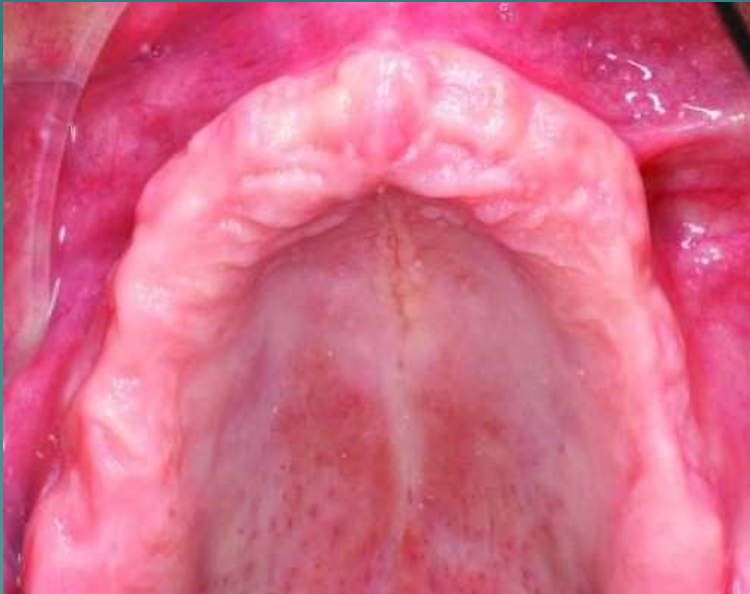RELIEF AREAS

CUSPID EMINENCE



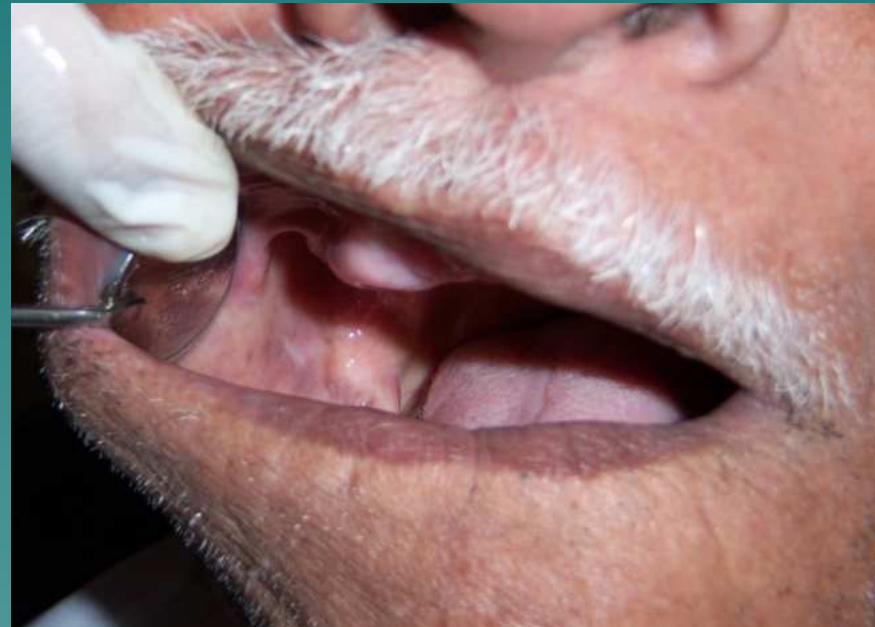RELIEF AREAS

MID-PALATINE RAPHAEE



RELIEF AREAS

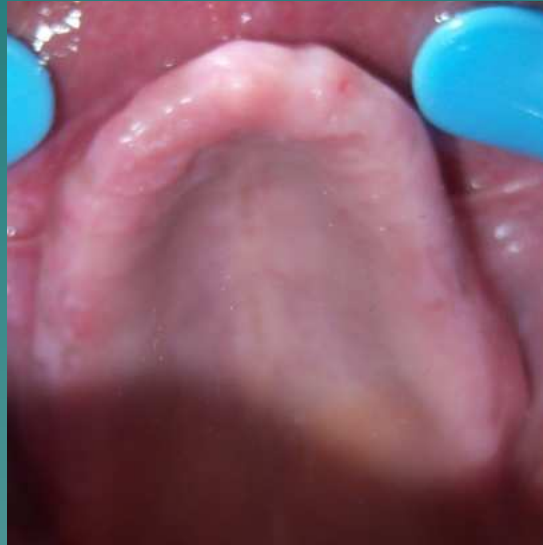MALAR PROCESS



RELIEF AREAS

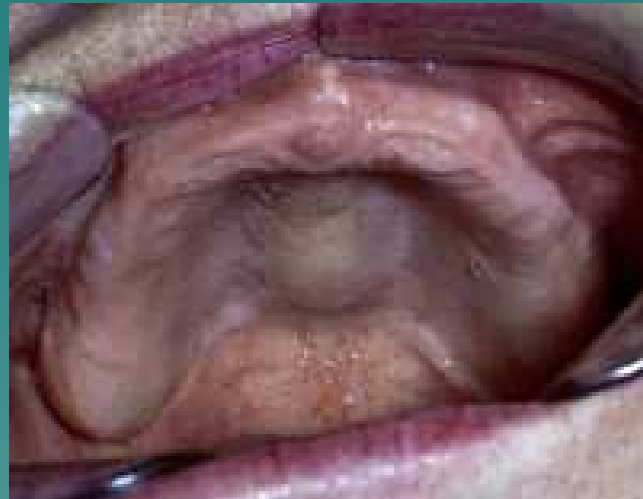SHARP SPINY SPICULES

➤ LOCATION



RELIEF AREAS

TORUS PALATINUS



RELIEF AREAS

TORUS PALATINUS

- Slowly growing ,flat-based bony protuberance in the midline of the palate
- Women more frequently affected{2:1}
- Shape:flat ,spindle-shaped,nodular or lobular
- Overlying mucosa appears blanched
- Occur at any age>reach its peak incidence shortly before 30 years of age
- Visible on I/O palatal roengenogram

ANATOMICAL LANDMARKS IN THE MANDIBLE



ANATOMICAL LANDMARKS IN THE MANDIBLE

LIMITING STRUCTURES

SUPPORTING STRUCTURES

RELIEF AREAS



ANATOMICAL LANDMARKS IN THE MANDIBLE

LIMITING STRUCTURES



ANATOMICAL LANDMARKS IN THE MANDIBLE

LIMITING STRUCTURES

LABIAL FRENUM

LABIAL VESTIBULE

BUCCAL FRENUM

BUCCAL VESTIBULE

LINGUAL FRENUM

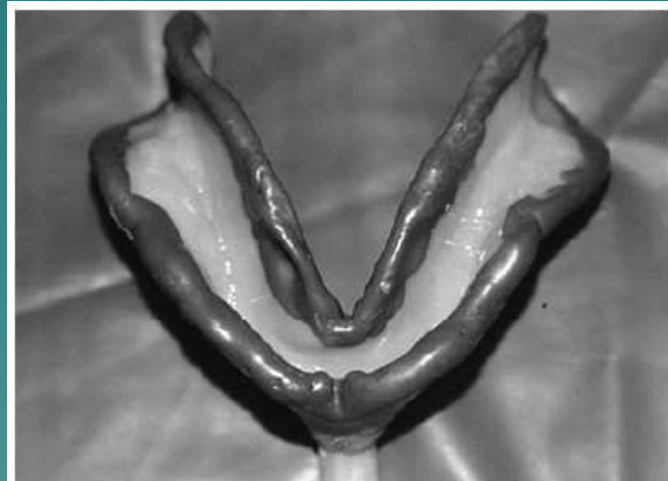ALVEOLOLINGUAL SULCUS

RETROMOLAR PAD

PTERIGOMANDIBULAR RAPHAE

LIMITING STRUCTURES

LABIAL FRENUM



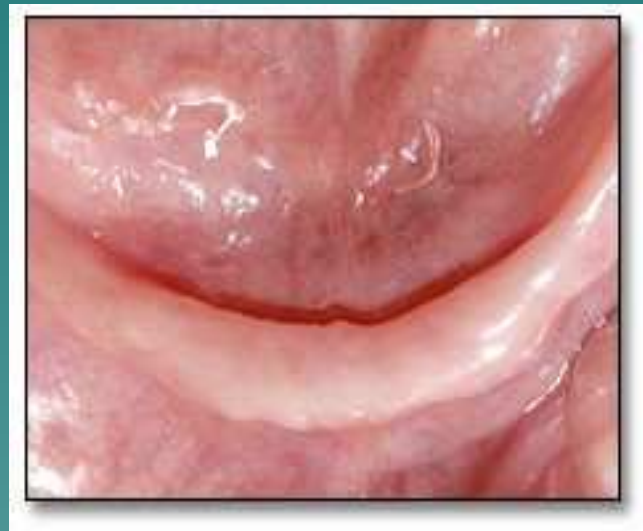LIMITING STRUCTURES

LABIAL FRENUM

- LOCATION
- MUSCLES: MENTALIS
- METHOD TO RECORD

LIMITING STRUCTURES

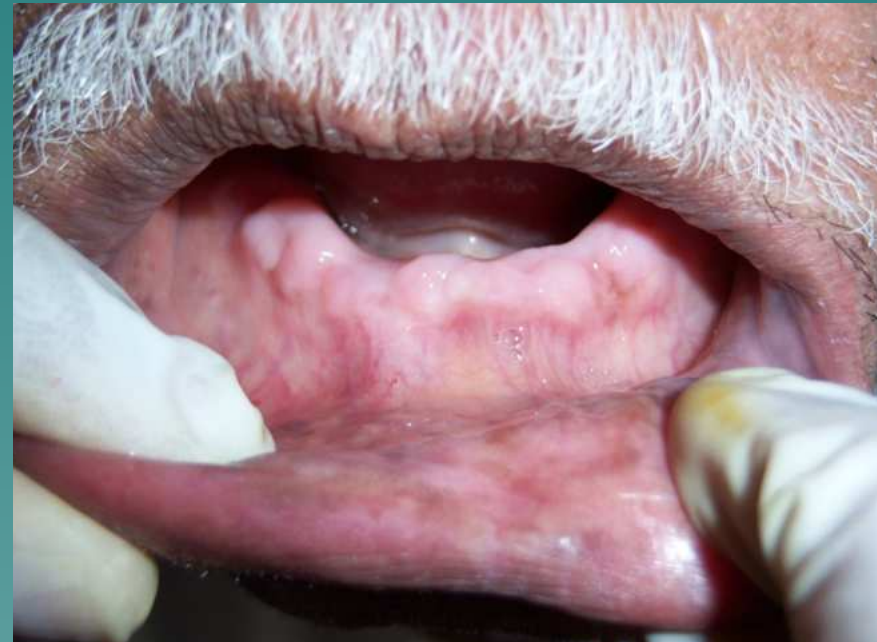LABIAL VESTIBULE



LIMITING STRUCTURES

LABIAL VESTIBULE

- Extent
- Boundaries
- Muscles
- Method to record



LIMITING STRUCTURES

LABIAL VESTIBULE

➤ Muscles : MENTALIS

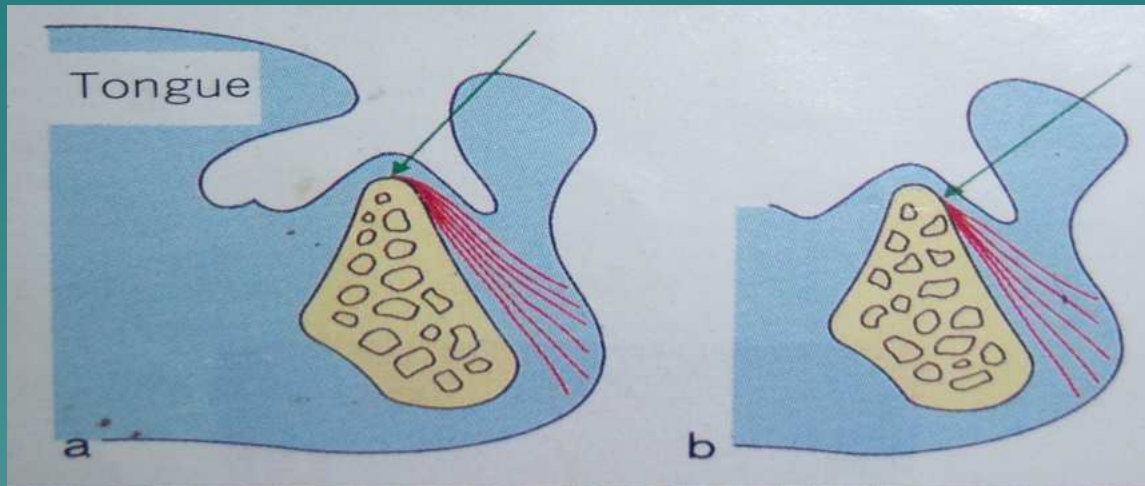
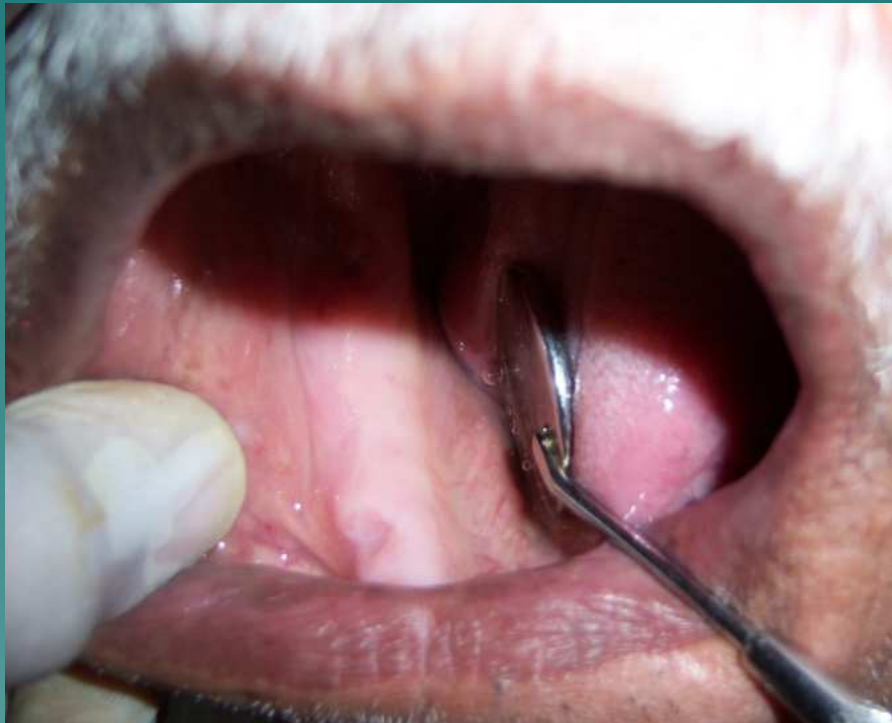

Fig. 17. Origin and attachment of mentalis muscle. Mentalis muscle originates either from the top of alveolar ridge (**a**), or anterior to the alveolar ridge (**b**), and attaches to the mentalis region. The original location is higher than the attachment, thus ridge resorption leads to shallow anterior trough.


LIMITING STRUCTURES

BUCCAL FRENUM



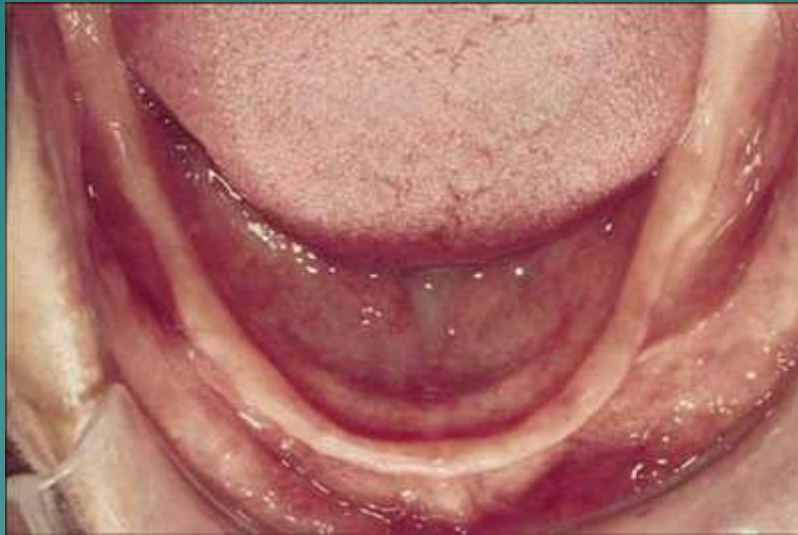LIMITING STRUCTURES

BUCCAL FRENUM

- Location
 - Number
 - Shape
 - Muscles
 - Method to record
- 
- A decorative silhouette of a mountain range in shades of teal, located in the bottom right corner of the slide.

LIMITING STRUCTURES

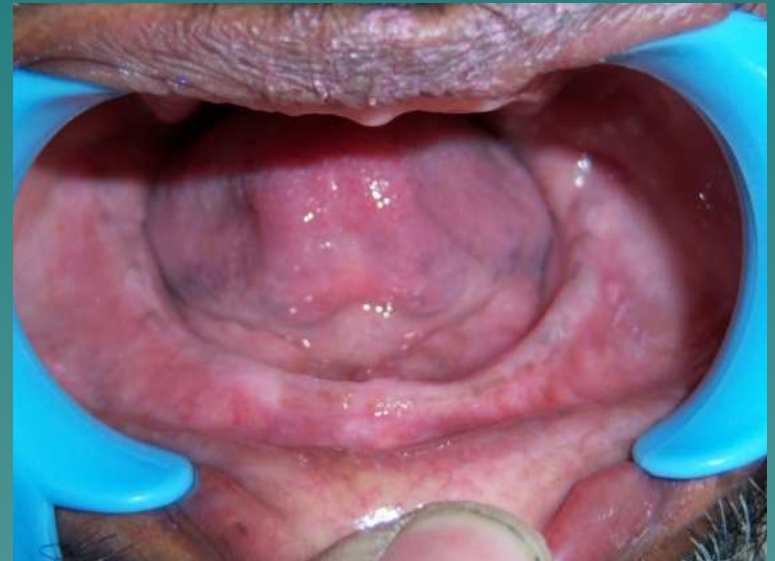BUCCAL VESTIBULE



LIMITING STRUCTURES

BUCCAL VESTIBULE

- Extent
- Boundaries
- Muscles
- Method to record



LIMITING STRUCTURES

BUCCAL VESTIBULE

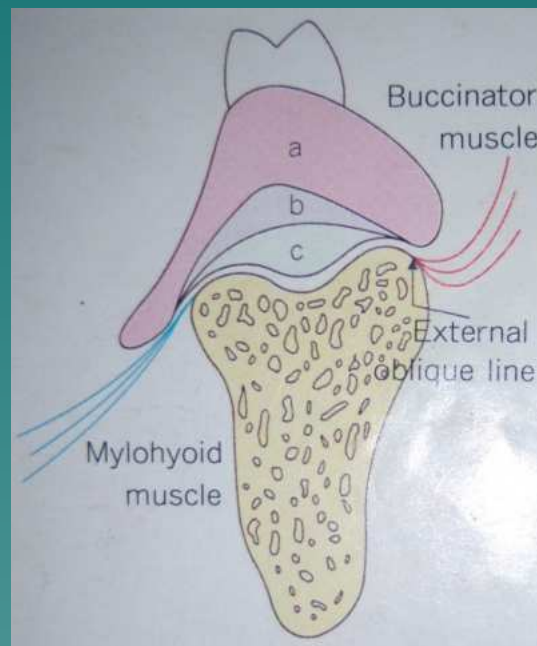
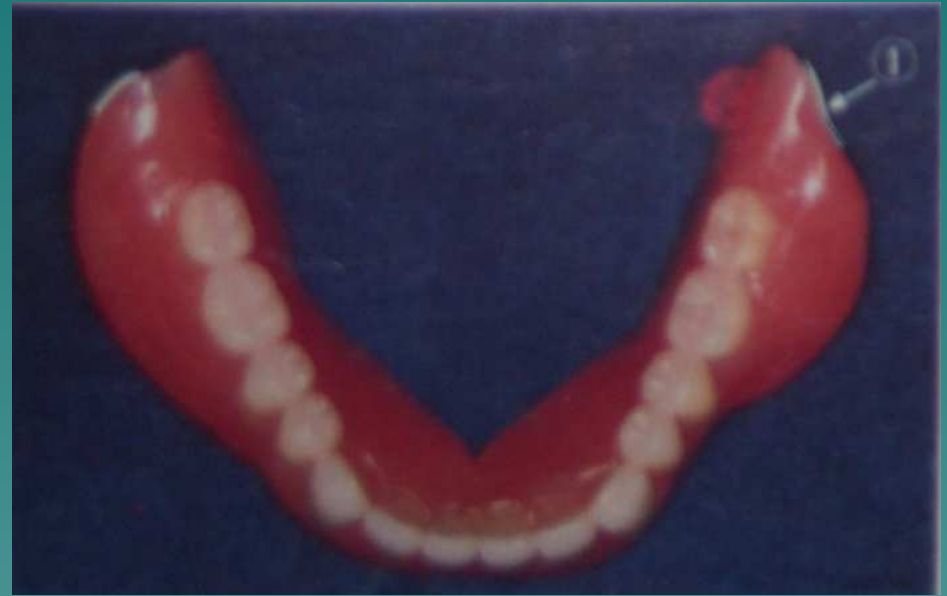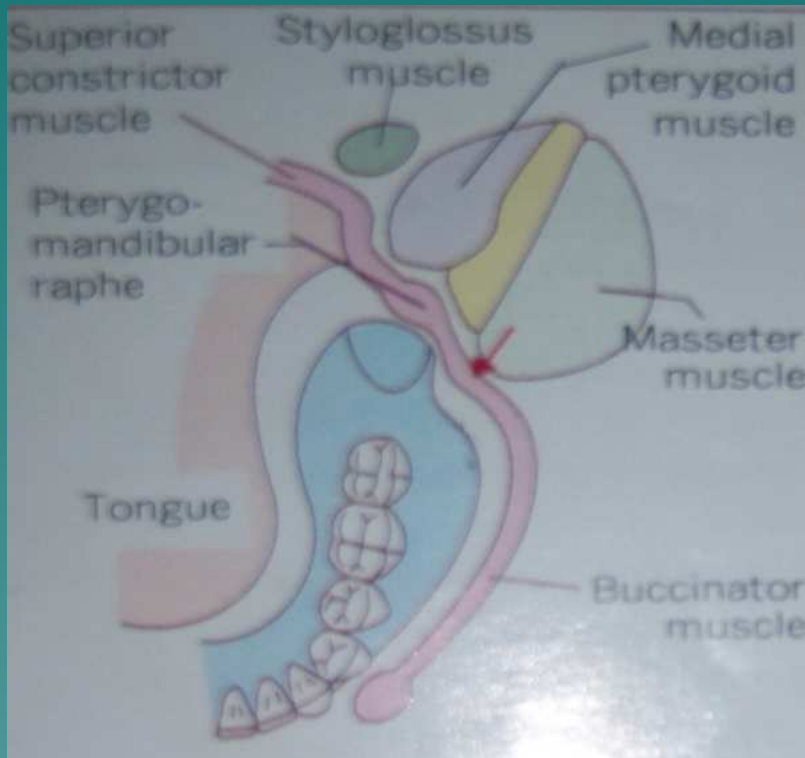


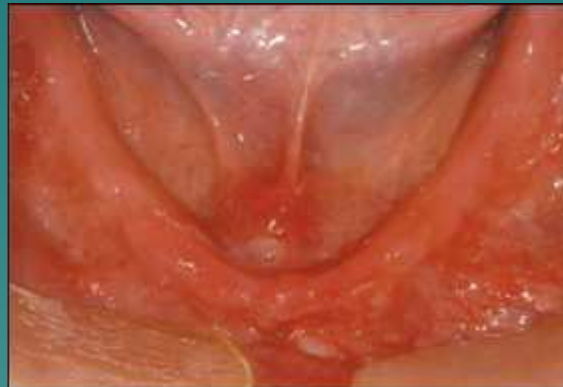Fig. 5. In the molar area, the denture margin should be set beyond the external oblique line buccally, and the mylohyoid muscle line lingually. By doing so, irregardless of the ridge resorption degree (a, b, c), the denture form is a constant.

MASSETRIC NOTCH AREA



LIMITING STRUCTURES

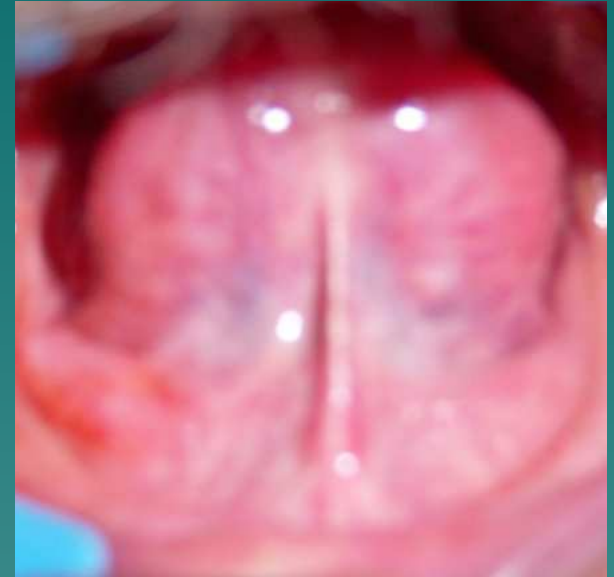LINGUAL FRENUM



LIMITING STRUCTURES

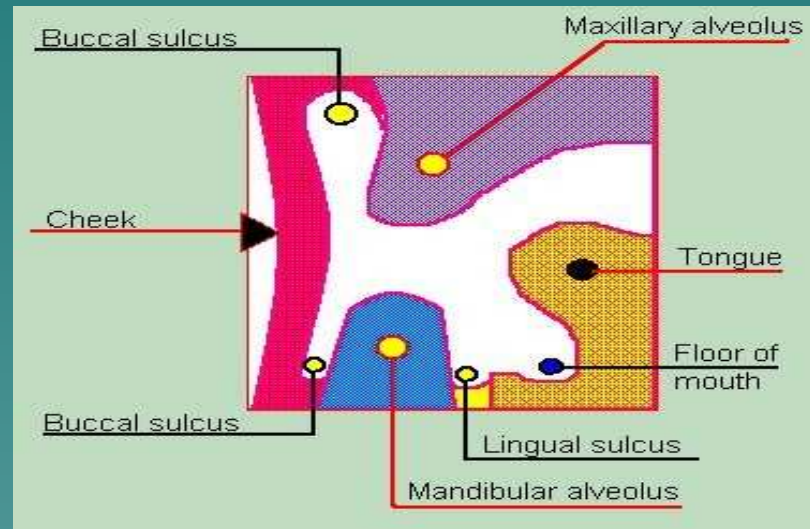
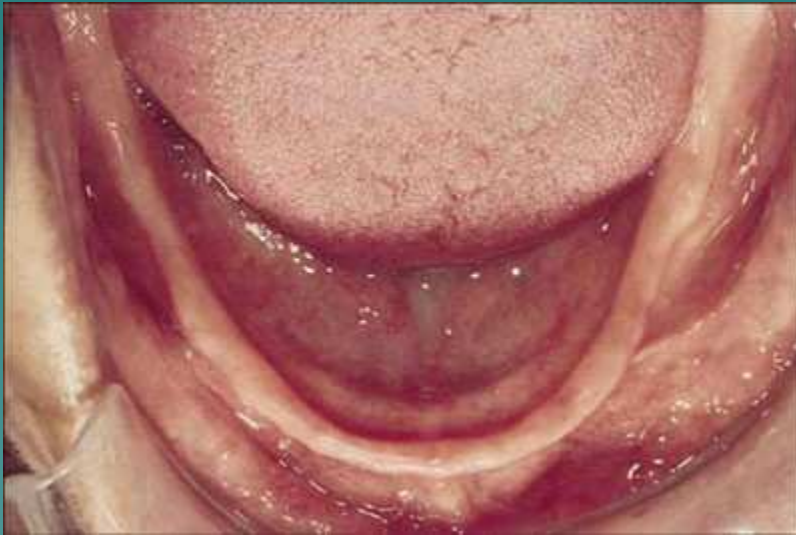
LINGUAL FRENUM

- Location
- Very active
- Registered at function
- Genioglossus muscle located below it
- While recording ,avoid shorting of adjacent denture border



LIMITING STRUCTURES

ALVEOLOLINGUAL SULCUS



LIMITING STRUCTURES

ALVEOLOLINGUAL SULCUS

3 Regions

Anterior

Middle

Posterior

LIMITING STRUCTURES

ALVEOLOLINGUAL SULCUS

Anterior Region

2 PARTS

- SUBLINGUAL CRESCENT AREA
- PREMYLOHYOID FOSSA

LIMITING STRUCTURES

ALVEOLOLINGUAL SULCUS

Anterior Region

Sublingual crescent area

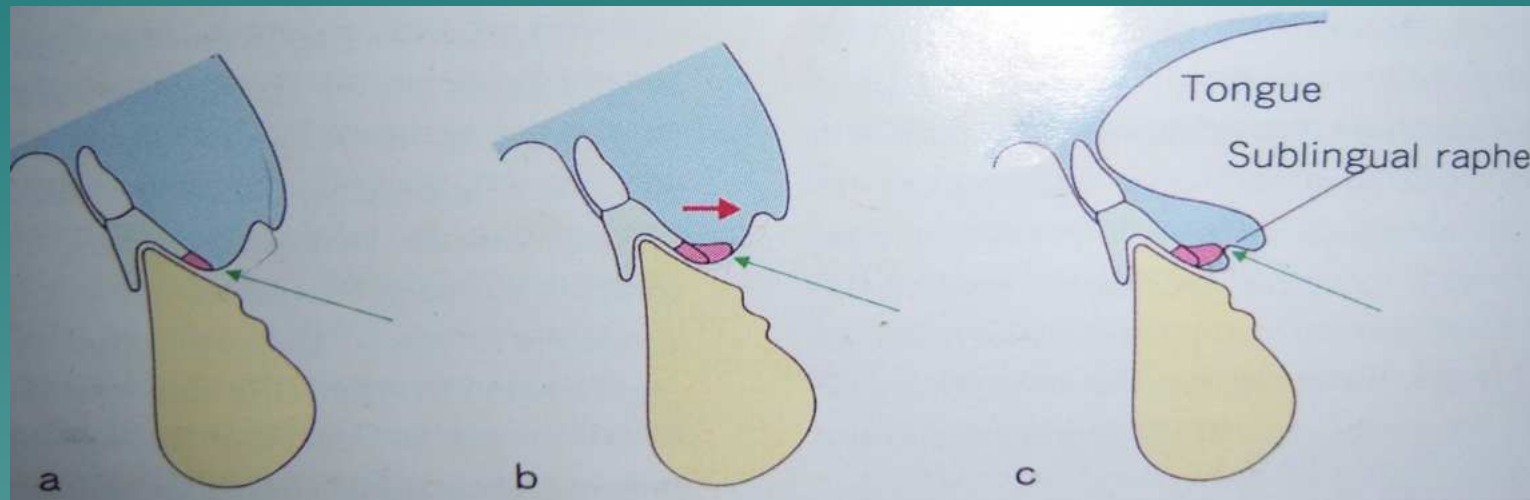


Fig. 30. Impression method for sublingual region according to Lawson (Lawson figure). Lift tongue to obtain raised floor of mouth impression(a). Next, extend compound horizontally(b). When tongue is relaxed and at rest, floor of mouth is lowered with concomitant lowering of sublingual raphe in anteroinferior direction which contacts denture margin resulting in marginal seal(c).

LIMITING STRUCTURES

ALVEOLOLINGUAL SULCUS

Anterior Region

Sublingual gland region

- Extends from lingual frenum to pre-mylohyoid fossa
- Critical for retention
- While recording, openings of salivary glands should not be covered

LIMITING STRUCTURES

ALVEOLOLINGUAL SULCUS

Anterior Region

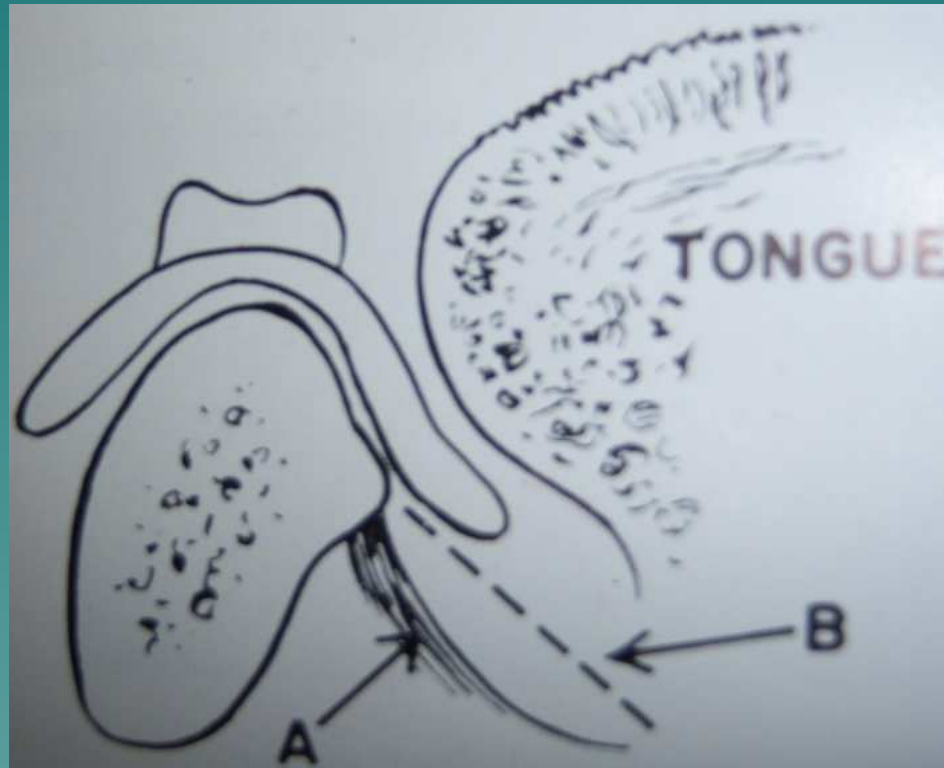
Premylohyoid fossa

- Shallowest part on the floor of mouth
- Passamonti's notch
- Junction of sublingual gland region & mylohyoid line
- Midpoint of " s-curve "

LIMITING STRUCTURES

ALVEOLOLINGUAL SULCUS

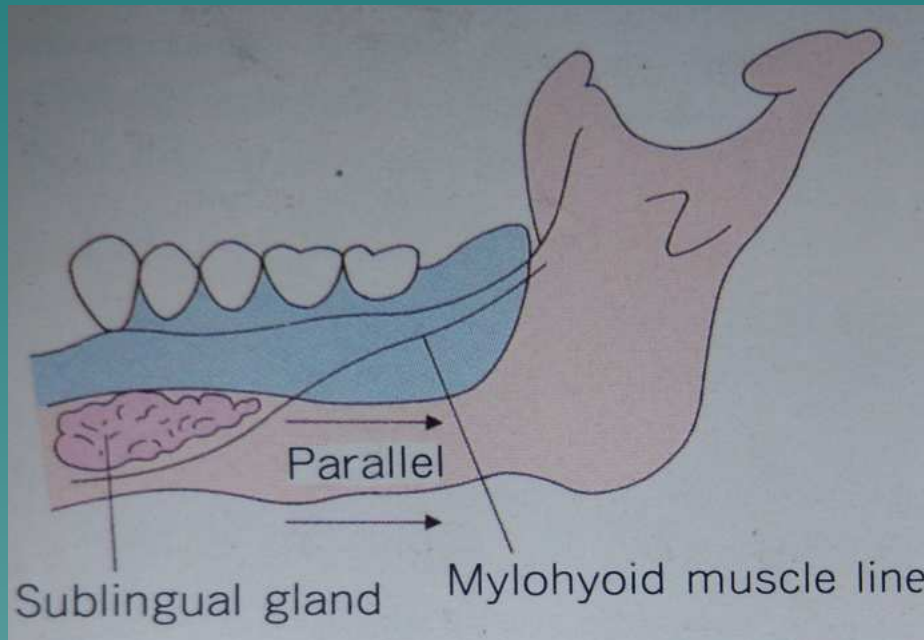
Middle Region



LIMITING STRUCTURES

ALVEOLOLINGUAL SULCUS

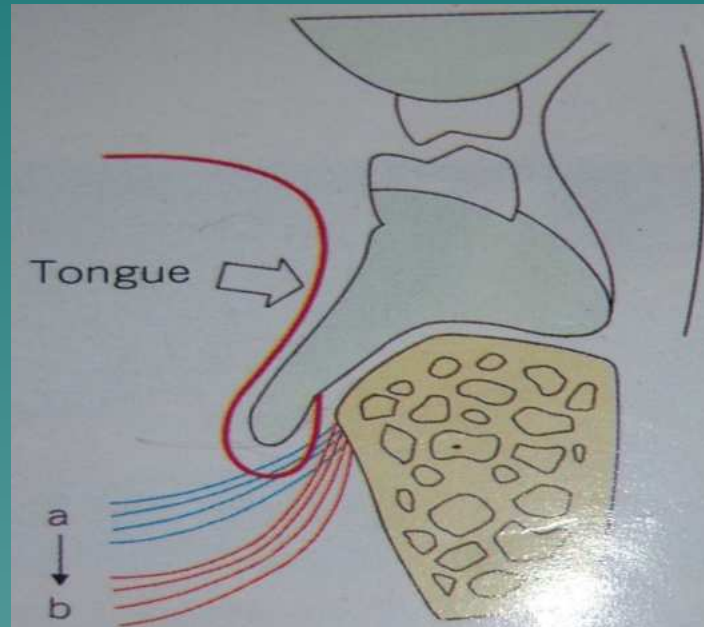
➤ MIDDLE REGION



LIMITING STRUCTURES

ALVEOLOLINGUAL SULCUS

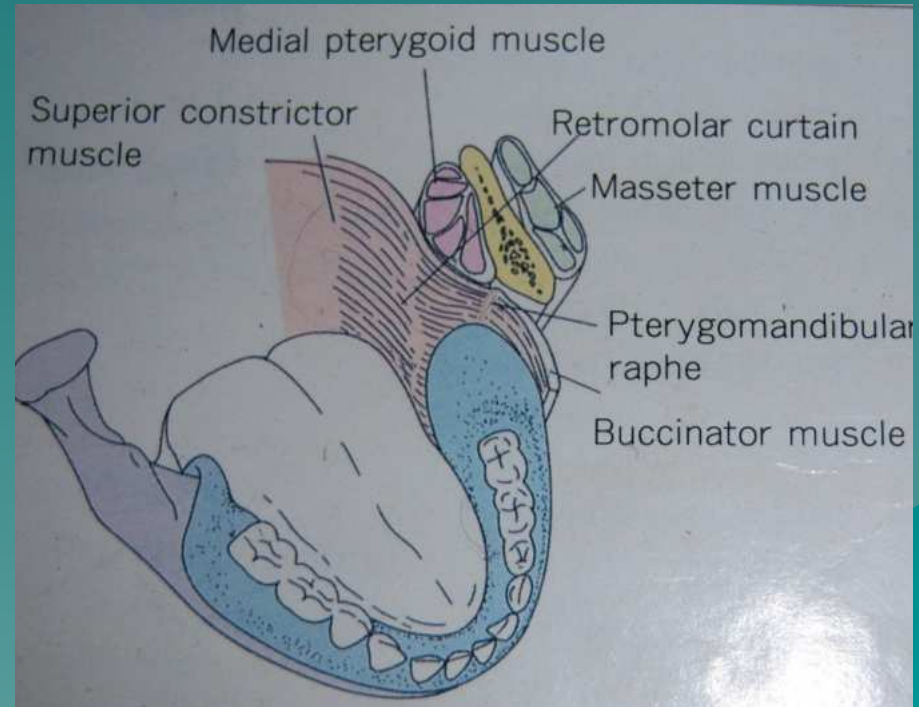
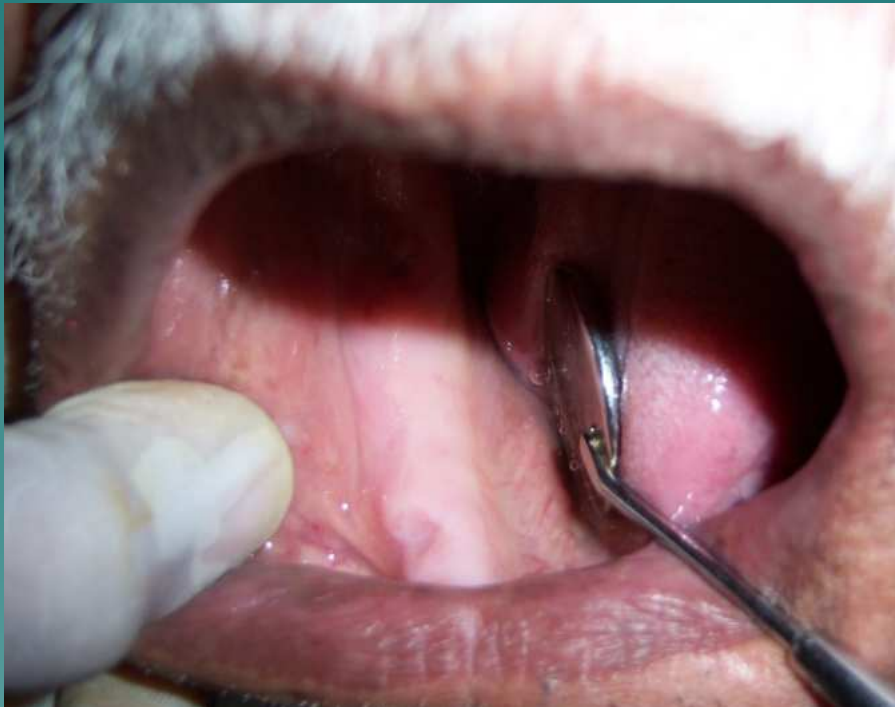MIDDLE REGION



LIMITING STRUCTURES

ALVEOLOLINGUAL SULCUS

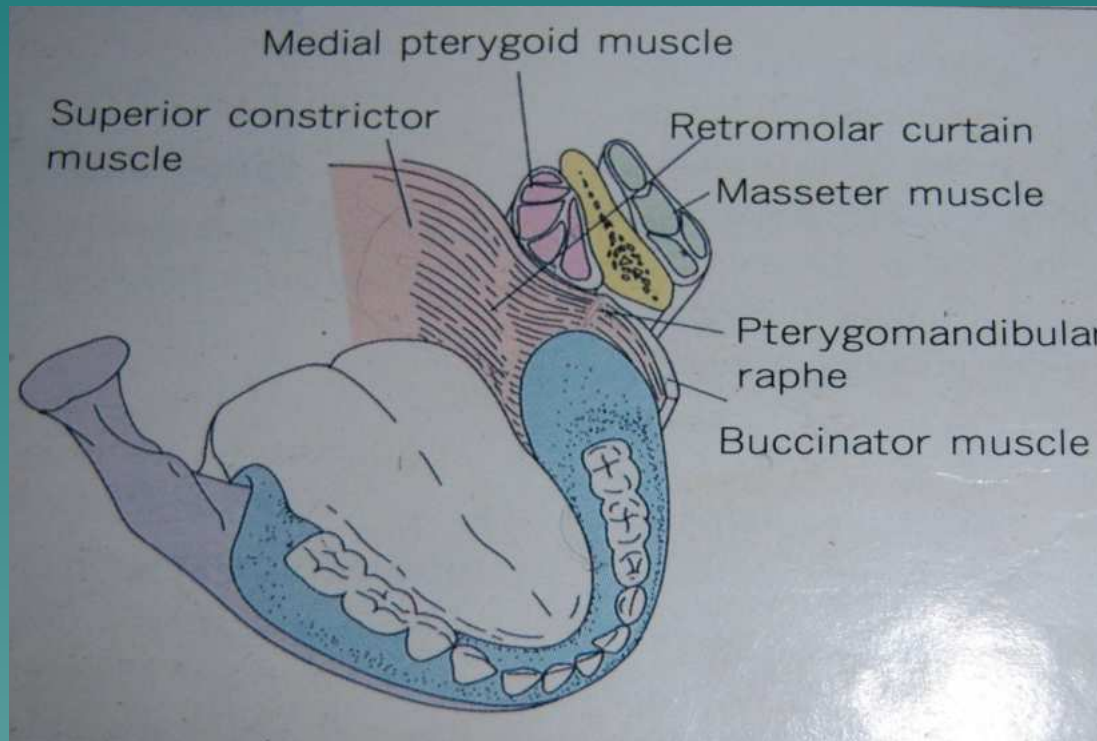
Posterior region



LIMITING STRUCTURES

ALVEOLOLINGUAL SULCUS

Retromylohyoid fossa



LIMITING STRUCTURES

ALVEOLOLINGUAL SULCUS

Retromylohyoid fossa

- Boundaries
- Retromylohyoid curtain
- Muscles
- Method to record

CLASSIFICATION OF LATERAL THROAT FORM

Neil has classified this area according to the tonicity, activity & anatomic attachment of adjacent structures as:

CLASS 1: Anatomical structures which will accommodate fairly long & wide flange.

CLASS 2: Lies intermediate between other two classes. The flange has minimum length & thickness. The border usually ends 2-3mm below the mylohyoid ridge.

Most edentulous mouths have class 1 & 2 lateral throat forms.

CLASS 3: The border ends at or near the mylohyoid ridge leaving minimum space for the flange. It is very rare.

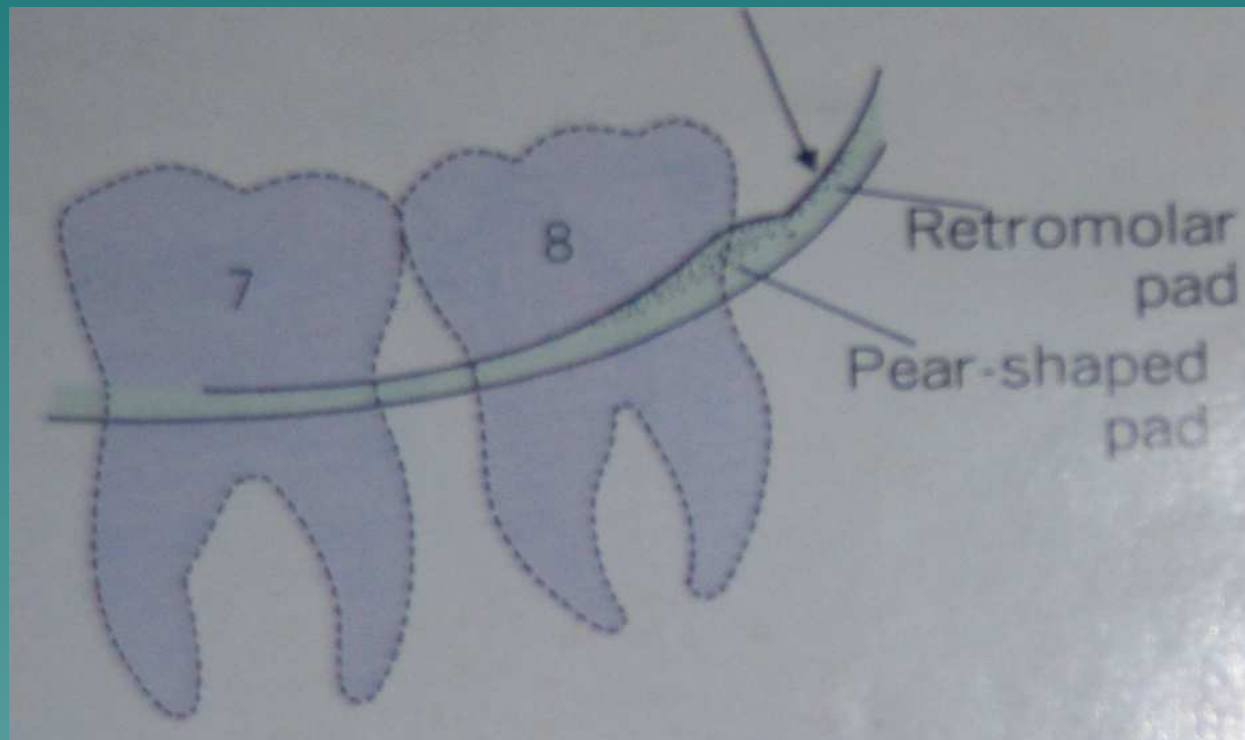
LIMITING STRUCTURES

RETROMOLAR PAD

- Pear-shaped pad of soft tissue located at the distal end of the lower ridge.
- Campbell: fibrous & glandular structure together as a 'pear shaped pad'.
- Swanson: distal portion glandular & proximal portion at the position of the last third molar as fibrous in structure.
- Cradlock: Retromolar pad – glandular
Pear shaped pad - fibrous mass to be developed as a scar in position of the last molar coming to include the smaller retromolar papilla

LIMITING STRUCTURES

RETROMOLAR PAD



LIMITING STRUCTURES

RETROMOLAR PAD

- According to GPT 5TH edition retromolar pad is divided into 2 parts:
 - Anterior: Retromolar papilla
 - posterior: Retromolar pad
- **BOUNDARIES:** Facially- Buccinator muscle
 - Lingually- Superior constrictor muscle
 - Postero-supero-medially:- Pterygomandibular raphae

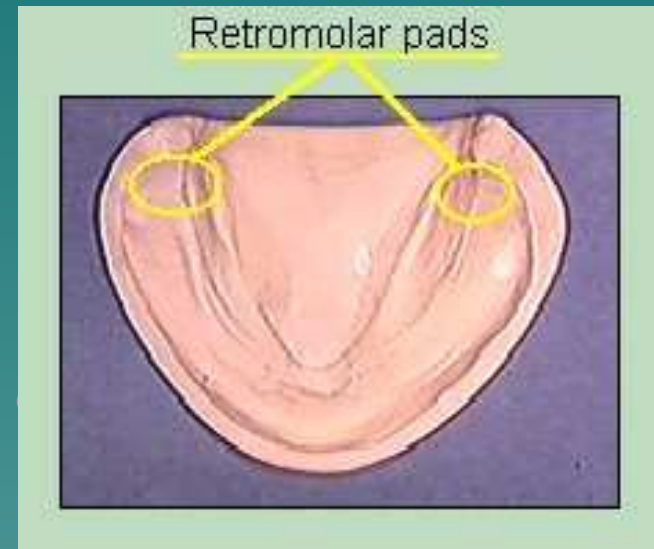
LIMITING STRUCTURES

RETROMOLAR PAD

➤ Contents

➤ Importance

- Fairly constant position
- secondary stress bearing
- maintains peripheral seal
- guidance for occlusal plane



LIMITING STRUCTURES

DISTAL EXTENT OF THE DENTURE

- Ramus of the mandible
- Buccinator
- Superior constrictor
- Sharpness of the lateral bony boundaries

LIMITING STRUCTURES

PTERYGOMANDIBULAR RAPHAE

- Location
- Extent
- Muscles : buccinator , medial pterygoid
- Method to record

SUPPORTING STRUCTURES



SUPPORTING STRUCTURES

PRIMARY:-

BUCCAL SHELF AREA

RETROMOLAR PAD

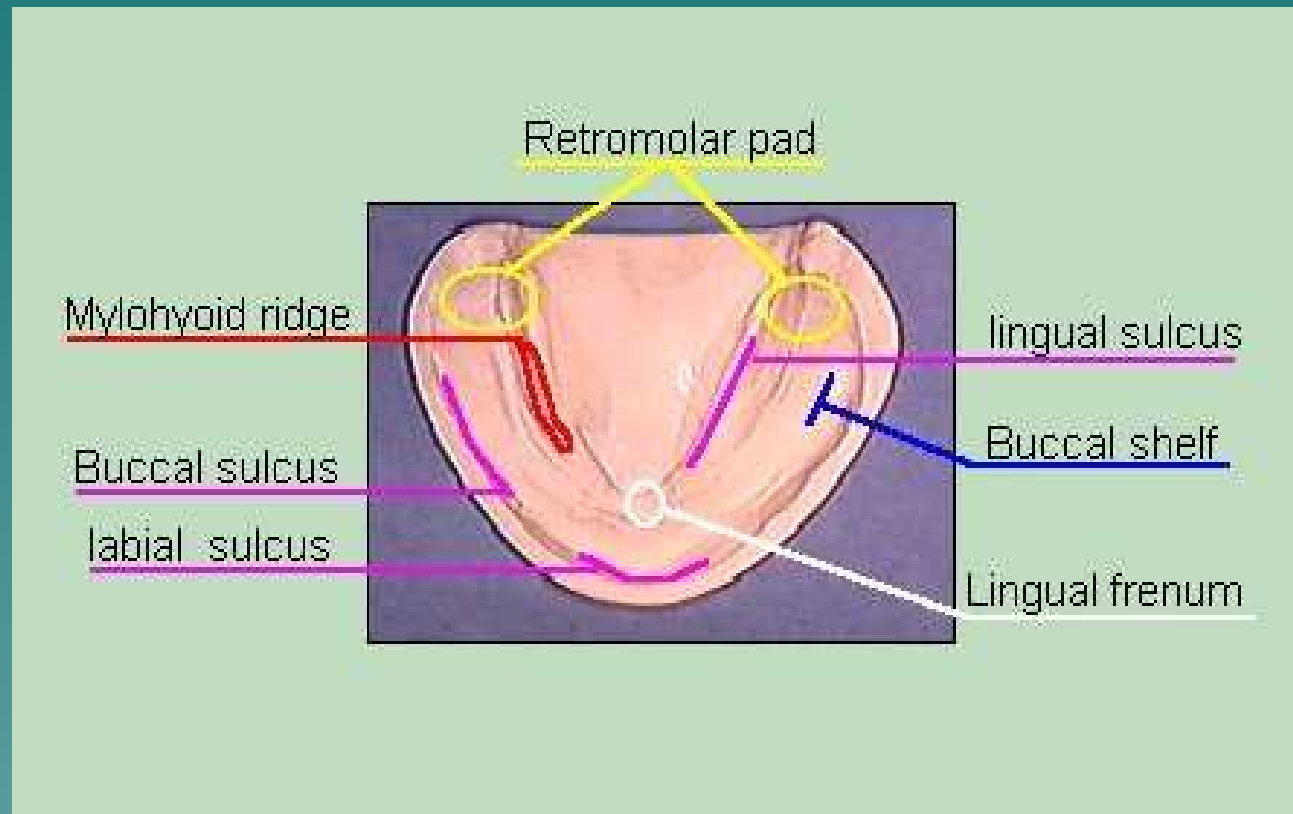
SECONDARY:-

RESIDUAL ALVEOLAR RIDGE

A stylized silhouette of a mountain range in shades of teal, located in the bottom right corner of the slide.

SUPPORTING STRUCTURES

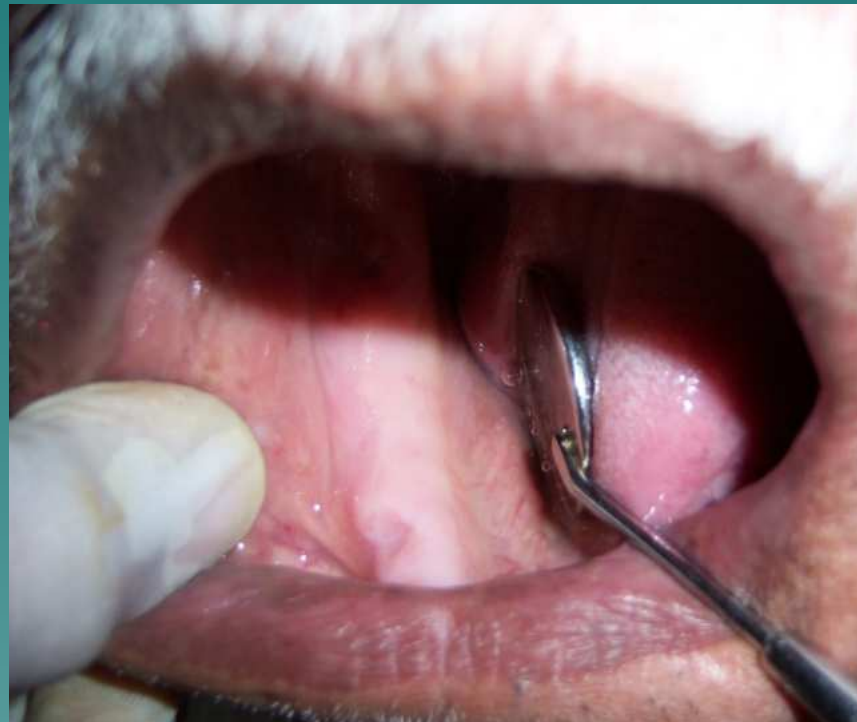BUCCAL SHELF AREA



SUPPORTING STRUCTURES

BUCCAL SHELF AREA

- Location
- Boundaries
- Function
- Muscle



SUPPORTING STRUCTURES

BUCCAL SHELF AREA

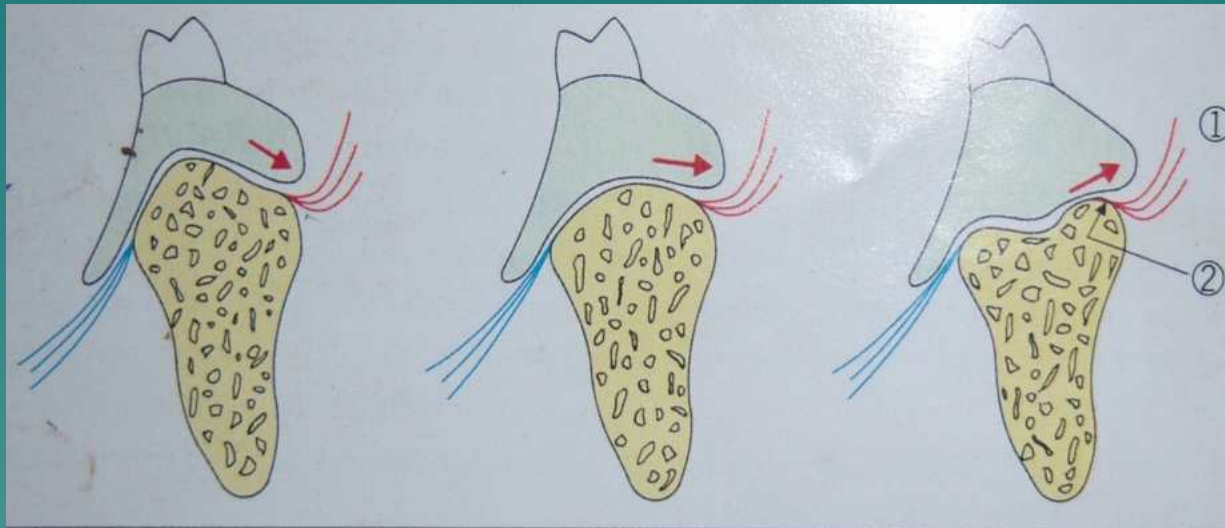


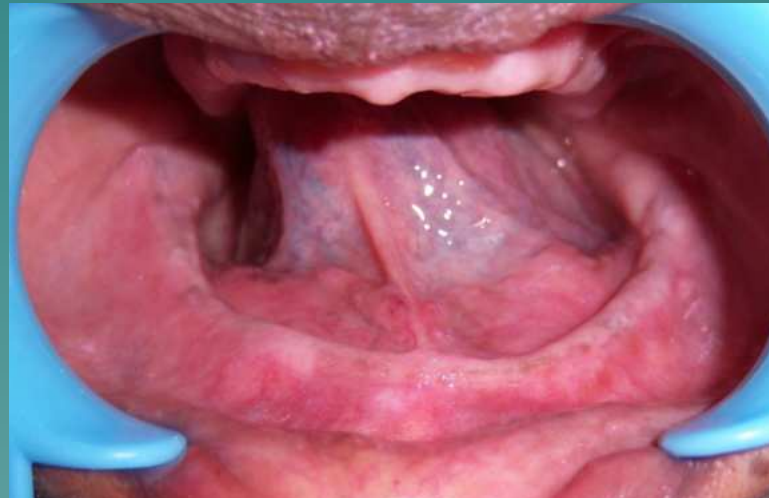Fig. 12. Buccal extension tips covering external oblique line. In good ridge the direction is downward, flat ridge is horizontal and poor ridge is upward.

1. Buccinator muscle 2. External oblique line

SUPPORTING STRUCTURES

RESIDUAL ALVEOLAR RIDGE

- Surface area
- Rate of resorption
- Pathological variations



RELIEF AREAS



RELIEF AREAS

KNIEF-EDGED RESIDUAL ALVEOLAR RIDGE

MENTAL FORAMEN

GENIAL TUBERCLES

MYLOHYOID RIDGE

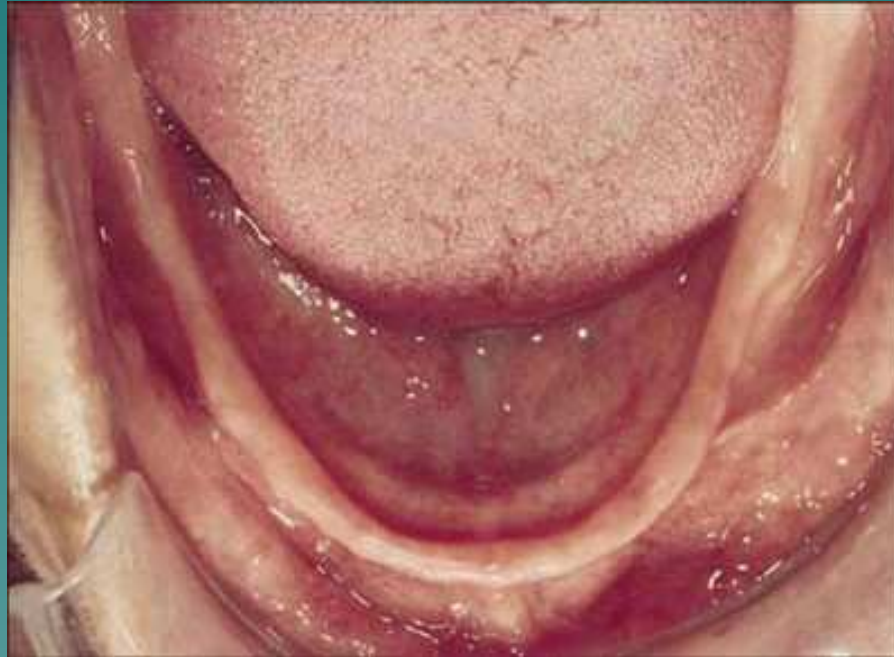
TORUS MANDIBULARIS

LINGUAL LEDGE

A stylized, dark teal silhouette of a mountain range with jagged peaks, located in the bottom right corner of the slide.

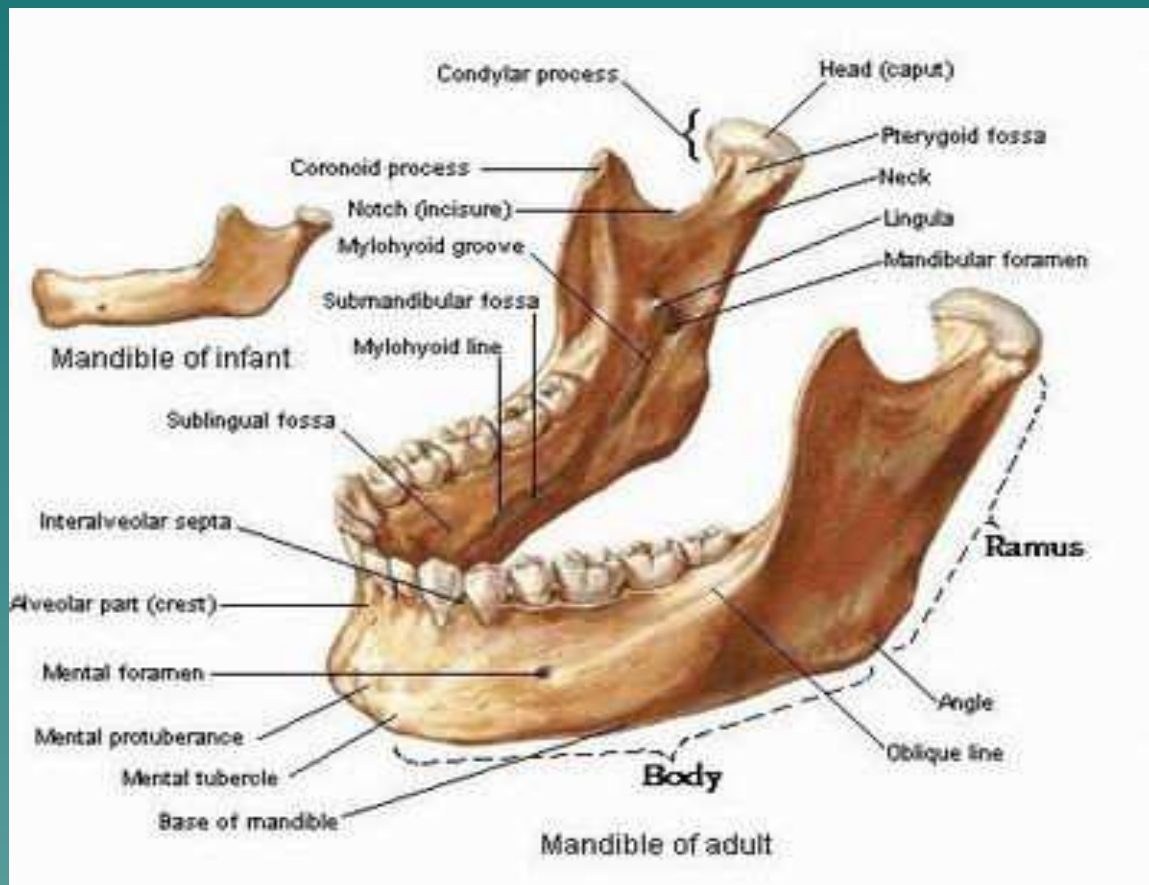
RELIEF AREAS

KNIEF-EDGED RESIDUAL ALVEOLAR RIDGE



RELIEF AREAS

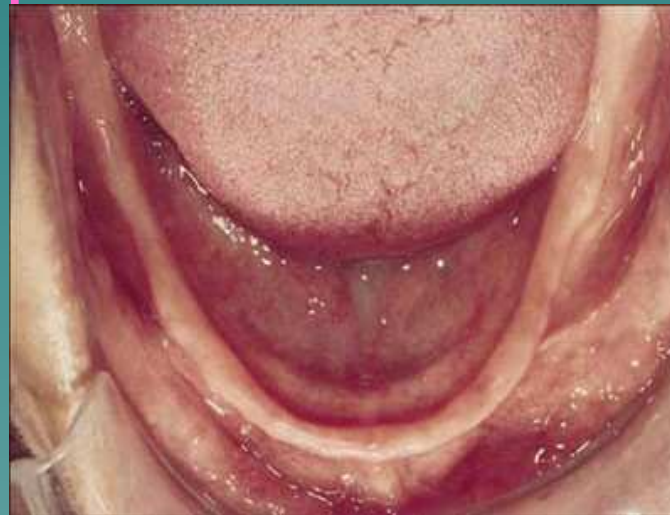
MENTAL FORAMEN



RELIEF AREAS

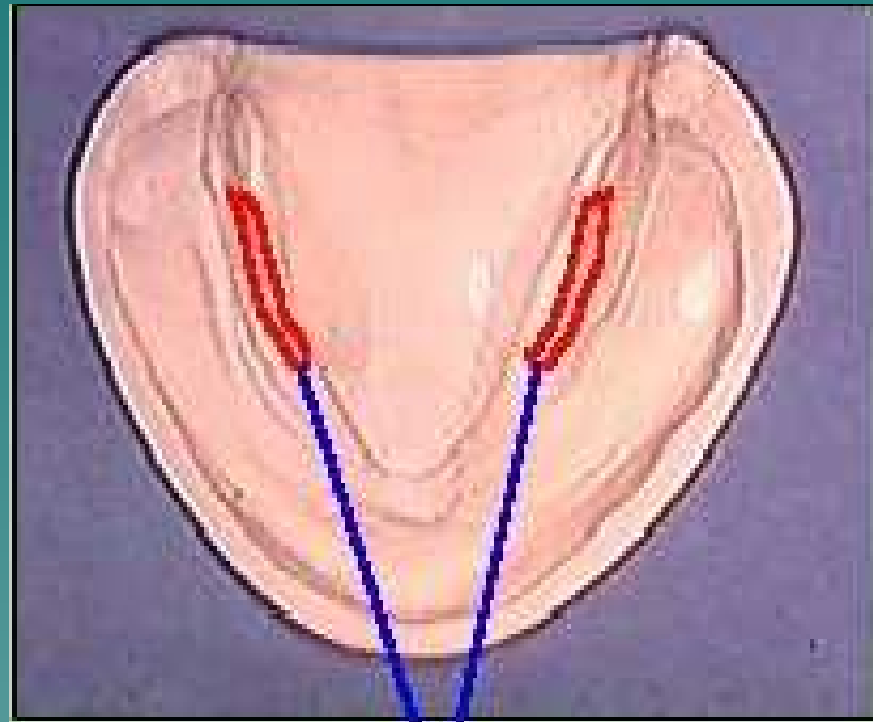
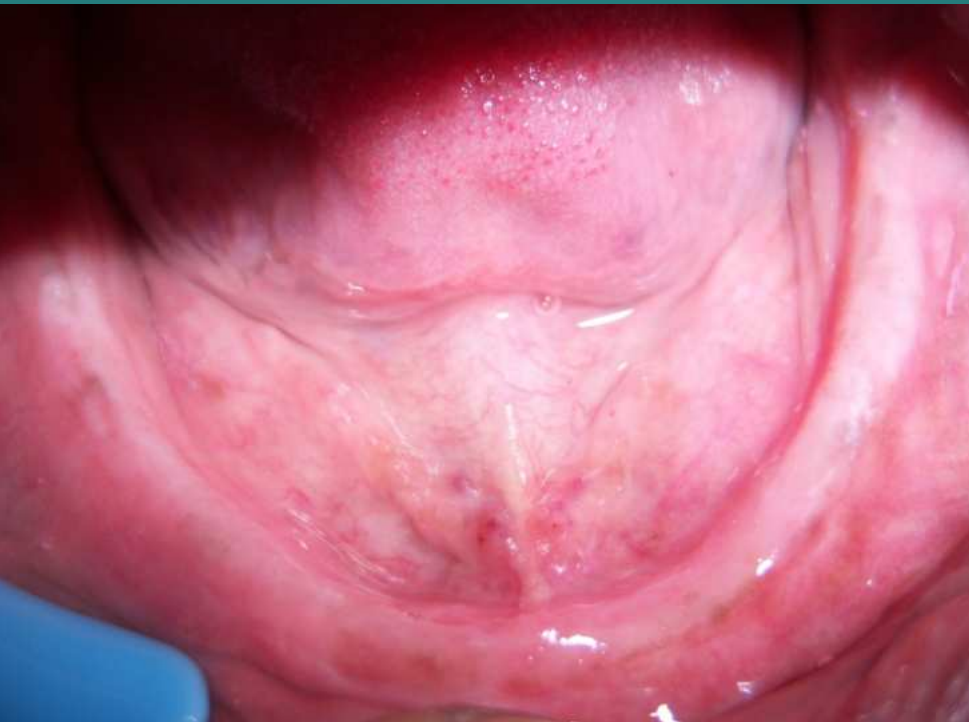GENIAL TUBERCLES

- Location
- Number
- Muscles
- Clinical importance




RELIEF AREAS

MYLOHYOID RIDGE




RELIEF AREAS

LINGUAL LEDGE

- Present on either side of the genial tubercles
 - Projects horizontally towards the tongue
 - Crescent-shaped
 - If not relieved, abrasions & small ulcerative lesions can occur
- 

RELIEF AREAS

MYLOHYOID RIDGE

- Position
 - Shape
 - Muscle
 - Clinical significance
- 

RELIEF AREAS

TORUS MANDIBULARIS

- An exostosis or outgrowth found on the lingual surface
- Above the mylohyoid line
- Opposite bicuspid teeth
- Usually bilateral
- Single or multiple
- Seen on roengenogram
- IF covered under denture > tongue space narrowed

REFERENCES

1. Zarb, Bolender, Carlson – Boucher's prosthodontic treatment for edentulous patients, 12th edition
2. Sharry J.J. – Complete denture prosthodontics; ed. 3. New York, 1974
3. Heartwell Charles – syllabus for complete dentures Ed. 4, Philadelphia
4. Sheldon Winkler – Essentials of complete denture Prosthodontics, ed. 2
5. O Boucher – Swenson's complete denture Prosthodontics, ed. 6

REFERENCES

6. Benard Levin – Impression for complete dentures, Chicago QUIENTESSENCE publishing, 1984
7. Neil E.-the upper and lower, Coe laboratories, Inc. 1941
8. Academy of denture prosthetics-Glossary of Prosthodontic terms, 1999
9. Ming Shah Chen – Reliability of the fovea palatini for determining the posterior border of maxillary denture. JPD 1980, 43:133-137
10. Lye T.L-The significance of fovea palatini in complete denture Prosthodontics, JRPD, 1975, 33:504-507

REFERENCES

11. Benard Lynn, Detriot, Mich – Significance of anatomic landmarks in complete denture service, JPD, 1964, 14:456-459
12. H.R. Kolb-Variable denture limiting structures of the edentulous mouth, Part 1 ,maxillary border areas, JPD 1966, 16:194-204
13. H.R. Kolb-Variable denture limiting structures of the Edentulous mouth , part 2, mandibular areas, JPD 1966, 16:202-211
14. Levin – the dynamic impression of lower denture space, JPD 1965, 15:401-418

REFERENCES

15. Colie H Millsap-The posterior palatal seal area for complete denture.DCNA,Nov.1964,663
16. Sidney,Wheeler – Structure of the mouth in mandibular Molar region and its relation to the denture.JPD 1962,12:835-836
17. Nallaswamy-Textbook of prosthodontics,ed. 1
18. Inderbir Singh-Textbook of human histology with colour atlas,ed.3
19. Orban-Oral histology & embryology,ed.10
20. Elinger-synopsis of complete denture prosthodontics,ed.1